

Anti-Inflammatory Potency of Oral Disulfiram Compared with Dexamethasone on Endotoxin-Induced Uveitis in Rats

Kazutaka KANAI^{1)*}, Naoyuki ITOH¹⁾, Yoshimasa ITO²⁾, Noriaki NAGAI²⁾, Yasutomo HORI¹⁾, Seishirou CHIKAZAWA¹⁾, Fumio HOSHI¹⁾ and Seiichi HIGUCHI¹⁾

¹⁾Department of Small Animal Internal Medicine, School of Veterinary Medicine, University of Kitasato, Towada, Aomori 034-8628 and

²⁾Department of Advanced Design for Pharmaceuticals, School of Pharmacy, University of Kinki, Higashi-Osaka, Osaka 577-8502, Japan

(Received 3 June 2010/Accepted 22 November 2010/Published online in J-STAGE 6 December 2010)

ABSTRACT. To investigate potency of oral disulfiram (DSF) compared with that of dexamethasone (Dexa), on endotoxin-induced uveitis (EIU) in rats. The oral administration with 750 mg/kg DSF suppressed the number of inflammatory cells, protein concentration, and levels of tumor necrosis factor (TNF)- α , Nitric oxide (NO) and prostaglandin (PG) E2 in the aqueous humor and improved the histologic status of the ocular tissue at 24 hr after lipopolysaccharide (LPS) injection. The anti-inflammatory potency of DSF oral administration was as strong as that observed with 0.5 mg/kg Dexa in the present study. The results suggest that DSF might pave the way for a novel therapeutic agent for the management of uveitis.

KEY WORDS: anti-inflammatory potency, dexamethasone, diethyldithiocarbamate, disulfiram, endotoxin-induced uveitis.

J. Vet. Med. Sci. 73(4): 517–520, 2011

Endotoxin-induced uveitis (EIU) is an animal model for acute ocular inflammation [17]. In general, cellular inflammation in EIU starts 4 hr after injection of LPS, with maximum infiltration after 18–24 hr [24]. Although the contributions of tumor necrosis factor (TNF)- α are pleiotropic [10, 16, 18], the TNF- α , Interleukin (IL)-1 β and IL-6 are considered to be particularly essential in the pathogenesis of EIU [3, 4, 25]. Nitric oxide (NO) [8] and prostaglandin (PG) E2 [1] are also involved in the pathogenesis of EIU. Disulfiram (DSF), as a prodrug of diethyldithiocarbamate (DDC), has long been used for the treatment of alcoholic syndrome without severe side effects [14]. DSF is cleaved into DDC within the gastrointestinal tract by oral administration. DSF has been reported to have multiple biological properties, including anti-inflammatory [23], anti-cataract [7], and anti-tumor properties [2]. We previously reported that oral DSF administration significantly reduced the development of EIU in a dose-dependent manner and 750 mg/kg DSF was most effective in inhibiting LPS-induced elevation of number of infiltrating cells, protein concentration and inflammatory mediators in aqueous humor [9], but did not compare DSF with corticosteroids which was the primary treatments available for uveitis. In our present study, therefore, we focused our attention on the anti-inflammatory potency of 750 mg/kg DSF compared with that of 0.5 mg/kg dexamethasone (Dexa).

Seven-week-old male Lewis rats were used. The rats weighed 180–220 g. After appropriately anesthetized with isoflurane, EIU was induced by injection into one footpad of 200 μ g of LPS from *Salmonella typhimurium* (Sigma-Aldrich, St. Louis, MO, U.S.A.) that had been diluted in 0.1 ml

of phosphate buffered saline (pH 7.4 PBS). Rats were orally administered 750 mg/kg of DSF (Sigma-Aldrich) diluted in 0.4 ml of 0.5% w/v dimethyl sulfoxide (DMSO; Sigma-Aldrich). DSF was orally administered 1 hr prior to LPS injection via gastic gavage. For the LPS and control group, 0.4 ml of 0.5% w/v DMSO was given orally on the same schedule as the DSF group. Dexa was administered in rats as described previously [15]. Briefly, animals were systemically treated with Dexa (subcutaneously in the posterior neck region) 4 hr before LPS. In preliminary study about the dose of Dexa, either 0.2, 0.5 or 1.0 mg/kg Dexa was injected subcutaneously, and the effect of 0.5 mg/kg Dexa on the number of infiltrating cells and protein concentration in aqueous humor was almost the same as that for the 750 mg/kg DSF group (data not shown). In our present study, therefore, 0.5 mg/kg Dexa was injected 4 hr before LPS. Animals were handled and cared for according to the ARVO statement on the Use of Animals in Ophthalmic and Vision Research. The rats were euthanized 24 hr after LPS injection, and the aqueous humor (20–25 μ l/rat) was collected from both eyes immediately by an anterior chamber puncture using a 30-gauge needle under a surgical microscope. For cell counting, the aqueous humor was suspended in an equal amount of Türk stain solution, and the cells were counted using a hemocytometer under light microscopy. The number of cells per field (an equivalent of 0.1 μ l) was obtained by averaging the results of four fields from each sample. The aqueous humor samples were then centrifuged at 2,500 rpm for 5 min at 4°C to obtain the supernatant. The total protein concentration in the aqueous humor samples was measured with a bicinchonmic acid (BCA) protein assay kit (Pierce, Rockford, IL, U.S.A.).

Twenty-four hours after LPS injection, rats were deeply anesthetized with isoflurane and the eyes were fixed by an intracardiac perfusion of 4% cold paraformaldehyde in

* CORRESPONDENCE TO: KANAI, K., Department of Small Animal Internal Medicine, School of Veterinary Medicine, Kitasato University, Towada, Aomori 034-8628, Japan.
e-mail: kanai@vmas.kitasato-u.ac.jp

phosphate buffer saline (PBS). The eyes were enucleated and immersed in the same fixative for 24 hr at 4°C and then the eyes were embedded in paraffin. Sagittal sections 5 μ m thick were cut near the optic nerve head and stained with hematoxylin and eosin (HE). Anterior chamber, iris-ciliary body and vitreous were observed by a masked pathologist under light microscopy. The number of infiltrating inflammatory cells in four sections per an eye, of eight eyes from different animals, was averaged. Histopathologic evaluation of inflammation was scored by grades of 0–3. A grade 0 represents no infiltrating cells, grade 1 represents mild cell infiltration (equal to or less than 75 more greatly than 0 inflammatory cells) and grade 2 represents moderate cell infiltration (equal to or less than 150 more greatly than 75 inflammatory cells). A grade 3 represents severe cell infiltration with severe anterior chamber exudates (more than 150 inflammatory cells).

The total level of nitrate plus nitrite in the aqueous humor was measured by using a total nitrite colorimetric assay kit (Oxis International, Portland, OR, U.S.A.) according to the manufacturer's instruction. The levels of TNF- α and PGE2 in the aqueous humor were assessed using a commercially available enzyme-linked immunosorbent assay kit (TNF- α and PGE2: R&D Systems, Minneapolis, MN, U.S.A.) according to the manufacturer's instructions.

All data are expressed as mean \pm SD. Parametric data were analyzed by variance (ANOVA) and the Tukey test was used for *ad hoc* comparison between the two treatment groups. Non-parametric data were analyzed by Kruskal-Wallis, and the Newman-Keuls test was used for *ad hoc* comparison to between the two treatment groups. $P < 0.05$ was considered to be statistically significant.

In this study, the clinical onset of EIU was observed 18 to 24 hr after LPS injection. Although the movements of animals became slower for 1 hr after 750 mg/kg DSF oral administration, no other side effects or toxicity were observed for 24 hr after LPS and autopsy. In the LPS group, the number of inflammatory cells in the aqueous humor 24 hr after LPS injection, was $57.5 \pm 6.6 \times 10^5$ cells/ml (mean \pm SD, $n=8$) and the protein concentration was 28.2 ± 3.2 mg/ml. The groups treated with DSF and Dexamethasone showed a significantly reduced number of inflammatory cells compared with LPS group and protein concentration ($P < 0.001$; $n=8$; Table 1). No infiltrating cells were detected in the aqueous humor of non-LPS injection rats (control group) and the level of protein detectable was 1.0 ± 0.2 mg/ml ($n=6$). The effect of 750 mg/kg DSF on the aqueous humor cell number

and protein concentration did not differ significantly from that of 0.5 mg/kg Dexamethasone effect. The mean of histopathologic grading in the LPS group was 2.8 ± 0.3 . The histological findings in the groups treated with DSF and Dexamethasone showed significantly lower grading compared to the LPS group ($P < 0.01$; $n=8$; Fig. 1B). Treatment with DSF showed no significant difference from that of Dexamethasone group. Considerable production of NO, TNF- α and PGE2 in the aqueous humor was seen in LPS group. DSF and Dexamethasone treatment significantly reduced their concentrations in aqueous humor ($P < 0.001$; $n=8$; Table 2). There was no significant difference between the levels of NO, PGE2 and TNF- α in the DSF group and the Dexamethasone group.

In this study, 750 mg/kg DSF and 0.5 mg/kg Dexamethasone reduced LPS-induced infiltrating cells, protein concentration, TNF- α , NO and PGE2 levels in aqueous humor as well as histopathologic manifestation of EIU. The anti-inflammatory potency of DSF oral administration was as strong as that observed with Dexamethasone. The treatment available for uveitis primarily includes corticosteroids, with suggested topical or systemic application. However, corticosteroids have severe side effects and may cause cataract, glaucoma, and susceptibility to microbial infections and may decrease patient quality of life [5]. Given these restrictions, there is an obvious demand for the development of new therapeutic strategies. Indeed, many alternative approaches, including antioxidants [11, 12, 26] and anticytokine therapies (such as anti-TNF) have been shown to prevent ocular inflammation in experimental animals [11, 12]. DSF has long been used to treat alcoholic syndrome without severe side effects [14]. DSF is a powerful antioxidant that scavenges reactive oxygen species such as hydroxyl radical, superoxide anion, and peroxynitrite, and is an inhibitor of NF- κ B [20]. The LD₅₀ of DSF given orally in rats and dogs are 8.6 and 3.5 g/kg, respectively. Although the movements of animals became slower for 1 hr after 750 mg/kg DSF oral administration, no other side effects or toxicity were observed for 24 hr after LPS and autopsy. However, the clinical dose for an adult human is typically 100–500 mg/day DSF. If one assumes that the human is 70 kg then the dose would be under 10 mg/kg/day for use in alcohol treatment. Consequently, one potential problem for the clinical use of oral (systemic) DSF administration as an anti-inflammatory drug might be the relatively high doses required for strong anti-inflammatory effects compared with Dexamethasone and might be the side effects induced by medium and long term administrations of high doses of DSF. Ishiyama *et al.* reported that over 800

Table 1. Effects of disulfiram and dexamethasone on cellular infiltration and protein concentration in aqueous humor

Group	Infiltrating cells ($\times 10^5$ cells/ml)	Protein concentration (mg/ml)
Control	0	1.0 ± 0.2
LPS	57.5 ± 6.6	28.2 ± 3.2
DSF	$9.0 \pm 6.1^*$	$17.8 \pm 2.8^*$
Dexa	$9.1 \pm 7.1^*$	$16.9 \pm 4.7^*$

Each value represents the mean \pm SD ($n=8$). * $P < 0.001$, compared with the LPS group.

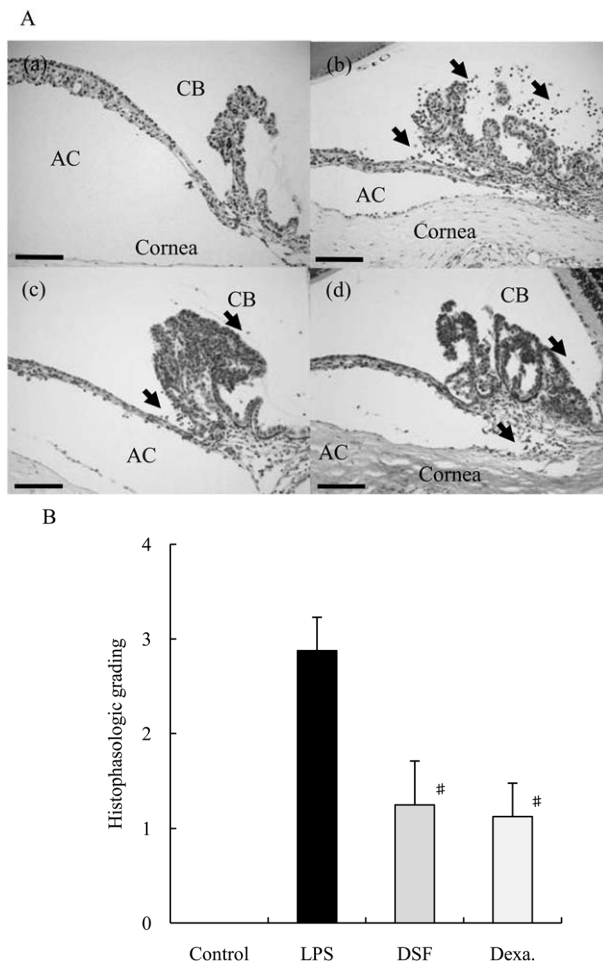


Fig. 1. Histologic evaluation of EIU treated with disulfiram. A: histologic changes in the anterior segment of the eye in an animal 24 hr after LPS injection. Rats without LPS injection (a) showed no inflammation (control group). Severe inflammatory cell infiltration was observed in the LPS injected rats (b). A significant reduction in inflammation was the reduction in the anterior segment of rats treated with 750 mg/kg DSF (c) and 0.5 mg/kg DEXA (d). AC: anterior chamber; CB: ciliary body; HE staining; Bars: 100 μ m; Arrows: inflammatory cells. B: effect of 750 mg/kg disulfiram and 0.5 mg/kg DEXA on histologic grading of EIU. Each value represents the mean \pm SD (n=8). [#] $P < 0.01$, compared with the LPS group.

mg/kg DDC treatment showed remarkable elevation of plasma transaminase activities and histologically, submassive necrosis in the liver after 24 hr in rats [6]. In addition, neurotoxic effects have been reported after high doses of oral DSF treatment (580 mg/kg/day DSF for three weeks) in rats [19]. While studies on side effects in humans during long term administration of high doses of DSF and DDC are not yet available, short term treatment with intravenous infusion of up to 150 mg/kg/day DDC was tolerated by cancer human patients [13]. In addition, over 500 patients with nickel carbonyl poisoning have received DDC both orally and

Table 2. Effects of disulfiram and dexamethasone on NO, TNF- α and PGE2 levels in the aqueous humor

Group	NO (μ M)	TNF- α (pg/ml)	PGE2 (pg/ml)
Control	8.8 \pm 4.8	ND	ND
LPS	153.2 \pm 40.2	224.3 \pm 41.6	7693.5 \pm 1396.5
DSF	64.5 \pm 24.1*	47.7 \pm 18.1*	3583.4 \pm 1418.7*
Dexa	59.4 \pm 17.3*	50.1 \pm 23.5*	3087.4 \pm 1382.8*

Each value represents the mean \pm SD (n=6 or 8). * $P < 0.001$, compared with the LPS group. ND=no detected.

parenterally at doses up to 25 mg/kg/day without occurrence of toxicity [21, 22]. To overcome this problem, we expected that the application of DSF eyedrops was an effective approach, and our further experiments demonstrated instillation of 0.5% DSF eyedrops (DSF and hydroxypropyl- β -cyclodextrin inclusion complex) were as strong as that observed with 0.05% DEXA on the same schedule as DSF eyedrops (unpublished data).

In conclusion, this study suggests that the anti-inflammatory potency of 750 mg/kg DSF oral administration was as strong as that observed with 0.5 mg/kg DEXA. The results suggest that DSF might pave the way for a novel therapeutic agent for the management of ocular inflammation.

ACKNOWLEDGMENT. This study was supported in part by a Kitasato University Research Grant for Scientific Research (No. 2948).

REFERENCES

- Bellot, J. L., Palmero, M., Garcia-Cabanes, C., Espi, R., Hariton, C. and Orts, A. 1996. Additive effect of nitric oxide and prostaglandin-E2 synthesis inhibitors in endotoxin-induced uveitis in the rabbit. *Inflamm. Res.* **45**: 203–208.
- Brar, S. S., Grigg, C., Wilson, K. S., Holder, W. D. Jr., Dreau, D., Austin, C., Foster, M., Ghio, A. J., Whorton, A. R., Stowell, G. W., Whittall, L. B., Whittle, R. R., White, D. P. and Kennedy, T. P. 2004. Disulfiram inhibits activating transcription factor/cyclic AMP-responsive element binding protein and human melanoma growth in a metal-dependent manner in vitro, in mice and in a patient with metastatic disease. *Mol. Cancer Ther.* **3**: 1049–1060.
- de Vos, A. F., Klaren, V. N. and Kijlstra, A. 1994. Expression of multiple cytokines and IL-1RA in uveitis in the rat. *Invest. Ophthalmol. Vis. Sci.* **35**: 3873–3883.
- de Vos, A. F., van Haren, M. A., Verhagen, C., Hoekzema, R. and Kijlstra, A. 1994. Kinetics of intraocular tumor necrosis factor and interleukin-6 in endotoxin-induced uveitis in the rat. *Invest. Ophthalmol. Vis. Sci.* **35**: 1100–1106.
- Dukes, M. N. G. 1996. Corticotrophins and corticosteroids. pp. 1189–1209. In: *Meyler's Side Effects of Drugs* (Dukes, M. N. G. ed.), Elsevier, Amsterdam.
- Ishiyama, H., Ogino, K., Shimomura, Y., Kanbe, T. and Hobara, T. 1990. Hepatotoxicity of diethyldithiocarbamate in rats. *Pharmacol. Toxicol.* **67**: 126–430.
- Ito, Y., Cai, H., Koizumi, Y., Nakao, M. and Terao, M. 1999. Correlation between prevention of cataract development by

- disulfiram and fates of selenium in selenite-treated rats. *Curr. Eye Res.* **18**: 292–299.
8. Jacquemin, E., Kozak, Y., Thillaye, B., Courtois, Y. and Goureau, O. 1996. Expression of inducible nitric oxide synthase in the eye from endotoxin-induced uveitis rats. *Invest. Ophthalmol. Vis. Sci.* **37**: 1187–1196.
 9. Kanai, K., Itoh, N., Yoshioka, K., Yonezawa, T., Ikadai, H., Hori, Y., Ito, Y., Nagai, N., Chikazawa, S., Hoshi, F. and Higuchi, S. 2010. Inhibitory effects of oral disulfiram on endotoxin-induced uveitis in rats. *Curr. Eye Res.* **35**: 892–899.
 10. Kasner, L., Chan, C. C., Whitcup, S. M. and Gery, I. 1993. The paradoxical effect of tumor necrosis factor- α (TNF- α) in endotoxin-induced uveitis. *Invest. Ophthalmol. Vis. Sci.* **34**: 2911–2917.
 11. Murphy, C. C., Ayliffe, W. H., Booth, A., Mankanjuola, D., Andrews, P. A. and Jayne, D. 2004. Tumor necrosis factor α blockade with infliximab for refractory uveitis and scleritis. *Ophthalmology* **111**: 352–356.
 12. Prendiville, C., O'Doherty, M., Moriarty, P. and Cassidy, L. 2008. The use of infliximab in ocular inflammation. *Br. J. Ophthalmol.* **92**: 823–825.
 13. Qazu, R., Chang, A. Y. C., Borch, R. F., Montine, T., Dedon, P., Loughner, J. and Bennett, J. M. 1988. Phase I clinical and pharmacokinetic study of diethyldithiocarbamate as a chemoprotector from toxic effects of cisplatin. *J. Natl. Cancer Inst.* **80**: 1486–1488.
 14. Rall, T. W. 1990. Disulfiram. pp. 378–379. In: *The Pharmacological Basis of Therapeutics*, 8th ed. (Gilman, A. G., Rall, T. W., Nies, A. S. and Taylor, P. eds.), Pergamon Press, New York.
 15. Rodrigues, G. B., Passos, G. F., Di Giunta, G., Figueiredo, C. P., Rodrigues, E. B., Grumman, A. Jr., Medeiros, R. and Calixto, J. B. 2007. Preventive and therapeutic anti-inflammatory effects of systemic and topical thalidomide on endotoxin-induced uveitis in rats. *Exp. Eye Res.* **84**: 553–560.
 16. Rosenbaum, J. T. and Boney, R. S. 1994. Failure to inhibit endotoxin-induced uveitis with antibodies that neutralize tumor necrosis factor. *Regul. Immunol.* **5**: 299–303.
 17. Rosenbaum, J. T., McDevitt, H. O., Guss, R. B. and Egbert, P. R. 1980. Endotoxin-induced uveitis in rats as a model for human disease. *Nature* **286**: 611–613.
 18. Rosebaum, J. T., Howes, E. L. Jr., Rubin, R. M. and Samples, J. R. 1998. Ocular inflammatory effects of intravitreally injected tumor necrosis factor. *Am. J. Pathol.* **133**: 47–53.
 19. Savoinen, K., Hervonen, H., Lehto, V. P. and Mattila, M. J. 1984. Neurotoxic effects of disulfiram on autonomic nervous system in rat. *Acta Pharmacol. Toxicol.* **55**: 399–344.
 20. Schreck, R., Meier, B., Männel, D. N., Dröge, W. and Baeruerle, P. A. 1992. Dithiocarbamates as potent inhibitors of nuclear factor kappa B activation in intact cells. *J. Exp. Med.* **175**: 1181–1194.
 21. Sunderman, F. W. 1990. Use of sodium dithiocarbamate in the treatment of nickel carbonyl poisoning. *Ann. Clin. Lab. Sci.* **20**: 12–21.
 22. Sunderman, F. W., Paynter, O. E. and George, R. B. 1967. The effects of protracted administration of chelating agent, sodium diethyldithiocarbamate (Dithiocarb). *Am. J. Med. Sci.* **254**: 46–56.
 23. Voll, R. E., Mikulowska, A., Kalden, J. R. and Holmdahl, R. 1999. Amelioration of type II collagen induced arthritis in rats by treatment with sodium diethyldithiocarbamate. *J. Rheumatol.* **26**: 1352–1358.
 24. Yang, P., de Vos, A. F. and Kijlstra, A. 1996. Macrophages in the retina of normal Lewis rats and their dynamics after injection of lipopolysaccharide. *Invest. Ophthalmol. Vis. Sci.* **37**: 77–85.
 25. Yoshida, M., Yoshimura, N., Hangai, M., Tanihara, H. and Honda, Y. 1994. Interleukin-1 α , Interleukin-1 β , and tumor necrosis factor gene expression in endotoxin-induced uveitis. *Invest. Ophthalmol. Vis. Sci.* **35**: 1107–1113.
 26. Zhang, X. Y., Hayasaka, S., Hayasaka, Y., Cui, H. S. and Chi, Z. L. 2007. Effect of N-acetylcysteine on lipopolysaccharide-induced uveitis in rats. *Jpn. J. Ophthalmol.* **51**: 14–20.