

The Effect of Tiletamine/Zolazepam (Zoletile®) Combination with Xylazine or Medetomidine on Electroencephalograms in Dogs

Hwan-Soo JANG¹⁾, Young-Sam KWON¹⁾, Maan-Gee LEE²⁾ and Kwang-Ho JANG^{1)*}

¹⁾Department of Veterinary Surgery, College of Veterinary Medicine, Kyungpook National University, Daegu 702-701 and ²⁾Department of Pharmacology, School of Medicine, Kyungpook National University, Daegu 700-422, Republic of Korea

(Received 10 February 2003/Accepted 14 January 2004)

ABSTRACT. The effects of xylazine or medetomidine on tiletamine/zolazepam (Zoletile®) anesthesia were evaluated by changes in the canine electroencephalogram (EEG). Experimental groups were three: the group treated with 10 mg/kg of Zoletile intravenously (TZ), the group treated with 1.1 mg/kg of xylazine intramuscularly and 10 mg/kg of Zoletile intravenously (XTZ), and the group treated with 30 µg/kg of medetomidine intramuscularly and 10 mg/kg of Zoletile intravenously (MTZ). EEG recording electrode was positioned at Cz, which was applied to International 10-20 system. For all recording times, the powers of each band (band 1: 1-2.5 Hz, band 2: 2.5-4.5 Hz, band 3: 4.5-8 Hz, band 4: 8-13 Hz, band 5: 13-20 Hz, band 6: 20-30 Hz, band 7: 30-50 Hz, band 8: 1-50 Hz) were calculated. In TZ, at 10 min after Zoletile injection, the powers of bands 3, 4, 5 and 8 significantly decreased. At 20 min after Zoletile injection, the powers of band 1 and 8 were significantly decreased. After Zoletile injection, there were significant decreases in bands 1, 4, 5, 6, 7 and 8 in XTZ, and in bands 1, 3, 4, 5, 6, 7 and 8 in MTZ. These significant changes disappeared in all band powers in TZ and MTZ in the last 1 min just prior to the dogs showing head-up movement. But, in XTZ, all band powers, except band 2, were significantly reduced. EEG power spectral analysis revealed the differences in band powers on awakening, even though the same kind of drugs were used. We thought that was a useful method to compare the effect of xylazine and medetomidine on Zoletile-induced anesthesia in dogs.

KEY WORDS: canine, EEG, medetomidine, tiletamine/zolazepam, xylazine.

J. Vet. Med. Sci. 66(5): 501-507, 2004

Although there are many volatile anesthetics, the injection anesthesia remains an interesting technique for many practitioners because of the relatively simple procedure, the relatively low equipment cost and the limited number of staff required [15]. It is often used in diagnostic procedures and minor surgeries, such as myelography, ear flushing, skin suturing, ovariohysterectomy and castration [7, 14, 17].

Zoletile® (Virvac, Carros, France) which is a drug combination of tiletamine and zolazepam for intramuscular or intravenous use in dogs and cats produces sedation at low doses and anesthesia at high doses. It can be used as an intravenous induction agent, and sometimes as a maintenance agent [3, 14]. Zoletile anesthesia is characterized by stable cardiorespiratory function and an uneventful, yet at times prolonged, recovery from anesthesia [1]. Using Zoletile as a sole agent, however, cannot provide an adequate surgical anesthesia or visceral analgesia in dogs and cats. If it is used repeatedly, the quality of recovery in dogs worsens [14, 17]. To accomplish surgery in dogs under adequate surgical anesthesia with Zoletile and to avoid the side effects seen in recovery by its repeated dosing, the combination with other anesthetics was needed [2-4, 11, 14, 17]. Xylazine and medetomidine, (2-adrenoceptor agonists, have been commonly used sedatives, analgesics and preanesthetics in veterinary medicine [2, 11, 18, 19]. Especially since xylazine and medetomidine have their appropriate antagonists, control of the depth and duration of anesthesia is possible.

It is clear that sedatives and anesthetics change the activity of the central nervous system (CNS). It is difficult to evaluate objectively the effects of CNS acting drugs on the brain with clinical signs or behavioral changes [16]. For assessing the neurophysiological alteration during sedation and anesthesia objectively, quantified indices are needed. Some techniques have been tested in attempts to find an adequate method of monitoring unconsciousness. Among them, quantitative electroencephalogram analysis has been proven to be a valuable and sensitive method in assessing brain function in dogs during anesthesia [13]. As the electroencephalogram (EEG) varies according to the drug used, each drug requires drug-specific interpretation of the EEG [9].

In this study, the effects of α_2 -agonists, xylazine or medetomidine, on Zoletile anesthesia in dogs were investigated by changes in the EEG. We compared the changes in band powers in each group, and tried to find a connection between the depth of anesthesia and EEG.

MATERIALS AND METHODS

Animals: This study was approved by the Kyungpook National University Animal Ethics Committee. Fifteen vaccinated, clinically healthy, adult mongrel dogs (nine males and six females) with a mean weight of 4.21 ± 0.55 kg (mean \pm standard deviation) were used. They were housed individually and fed commercial dry food and water *ad libitum*. Food, but not water, was withheld for at least 12 hr before the experiments. Experimental groups were divided into three and each group contained 5 dogs. Each group was

* CORRESPONDENCE TO: JANG, K. H., Department of Veterinary Surgery, College of Veterinary Medicine, Kyungpook National University, Daegu 702-701, Republic of Korea.

treated with Zoletile (TZ), the combination of xylazine-Zoletile (XTZ), and medetomidine-Zoletile (MTZ) combination, respectively.

Procedures: The sites whereby needle electrodes would be inserted for EEG recording in the head and ears were clipped, then 2% lidocaine was injected subcutaneously at the sites, and atropine (0.04 mg/kg, subcutaneously) was given. After that, the dogs were caged in a copper cage, which was done for electrical shielding. Five min after the lidocaine injection, the EEG electrodes were inserted, and the EEG was recorded.

Medications: Ten min after atropine injection, normal saline (1 ml intramuscularly (IM)), xylazine (1.1 mg/kg IM) or medetomidine (30 μ g/kg IM) were administered to each group. Ten min after one of these substances was given, each dog received tiletamine/zolazepam (10 mg/kg intravenously (IV)).

Test items: EEG and behavioral changes were measured. The EEG was recorded continuously until the dog awakened from the anesthesia. A one min EEG in the pre-administration state (control), 10, 20, 40 and 60 min after Zoletile injection, and then 1 min just prior to the dogs showing head-up movement was used in statistical analysis. Each group had its own control. In XTZ and MTZ, 10 min after these sedatives were administered, an EEG was also recorded in addition to 10, 20, 40 and 60 min after Zoletile injection. Showing head-up movement was considered to indicate awakening from the anesthesia.

1) Electroencephalography

A one-channel system and needle electrodes were used. The recording electrode was positioned at Cz, which was according to the International 10–20 system. The reference and the ground electrodes were inserted in both ears. The electrodes were connected to a polygraph (Model 74K, Grass instrument Co., West Warwick, R.I., U.S.A.). The measured EEG was digitalized by an A/D converting interface (Model MP100ACE, Biopac system. Inc., Santa Barbara, C.A., U.S.A.) synchronized with the EEG recordings, which was accomplished at the speed of 200 Hz. It was then recorded on a hard disk by means of a data acquisition program.

2) Behavioral changes

Mean head-up time (MHT) which was the mean time for dogs showing head-up movement after Zoletile injection, and mean walking time (MWT) which was the mean time for dogs walking after Zoletile injection were measured. Scrambling was not regarded as walking in evaluating MWT.

Statistical analysis: A noise-free 1 min period for each stage of EEG data was used in statistical analysis. The data were analyzed by one-way analysis of variance between groups (ANOVA) and Student's *t*-test. Data compared amongst stages and the control stage showed significant differences within treatment group. During all recording times, the power for each band (the band 1: 1–2.5 Hz, band 2: 2.5–4.5 Hz, band 3: 4.5–8 Hz, band 4: 8–13 Hz, band 5: 13–20 Hz, band 6: 20–30 Hz, band 7: 30–50 Hz, band 8: 1–

50 Hz) was calculated with an analysis program (Matlab R12 version 6.0). Behavioral changes were analyzed with ANOVA, and significant differences were $p < 0.05$.

RESULTS

Raw EEG: The representative raw EEG, mean spectral power and mean band power of the control stage are shown in Fig. 1. In TZ, after Zoletile injection, slow and high amplitude waves with low amplitude spikes were observed. The amplitudes, however, increased as time went on (Fig. 2). In XTZ and MTZ, after α_2 -agonists, xylazine or medetomidine, injection, slow and high waves appeared. After Zoletile injection, the amplitude increased more than those after α_2 -agonists injection. These waves changed to the fast waves with low amplitude as awakening neared (Figs. 3 and 4).

Mean band power: All band powers decreased as the drugs were administered. In TZ, at 10 min after Zoletile injection, the powers of bands 3, 4, 5 and 8 significantly decreased. At 20 min after Zoletile injection, the powers of band 1 and 8 significantly decreased, but there was no significant decrease in the last min just prior to the dogs showing head-up movement (Fig. 5). In XTZ and MTZ, after xylazine or medetomidine injection, there were significant decreases in the powers of bands 1, 5, 6, 7 and 8. At 10 min after Zoletile injection, there were significant decreases in bands 1, 4, 5, 6, 7 and 8 in XTZ, and in bands 1, 3, 4, 5, 6, 7 and 8 in MTZ. These significant changes disappeared in all band powers in the records for 1 min prior to the dogs showing head-up movement in TZ and MTZ. In XTZ, however, all band powers, except band 2, were significantly reduced at the same stage (Figs. 6 and 7).

Behavioral changes: Mean head-up time (MHT) was 23.4 ± 8.8 min in TZ, 50.5 ± 3.4 min in XTZ and 67.3 ± 7.0 min in MTZ. In XTZ and MTZ, MHT was significantly extended compared with that in TZ. Mean walking time (MWT) was 44.8 ± 10.2 min in TZ, 67.3 ± 8.0 min in XTZ and 82.3 ± 5.4 min in MTZ. In XTZ and MTZ, MWT was significantly extended compared with that in TZ.

DISCUSSION

Balanced anesthesia is often used for deep and safe anesthesia. Information on each drug combination is important to select appropriate anesthetic combinations suited for a certain type of surgery. For example, information on the depth and duration of anesthesia is helpful to prevent the patient's movement during surgery and to reduce the post-operative monitoring time of anesthetized patients. In many studies, the effects of balanced anesthesia were assessed by clinical signs, hemodynamic changes and/or behavioral changes and so on [2, 15, 16, 19]. But these results were a little subjective and were found similarly even though different drugs were used. The evaluation of depth of anesthesia by behavioral changes may be done after the recovery of consciousness and the movements of patients which inhibit

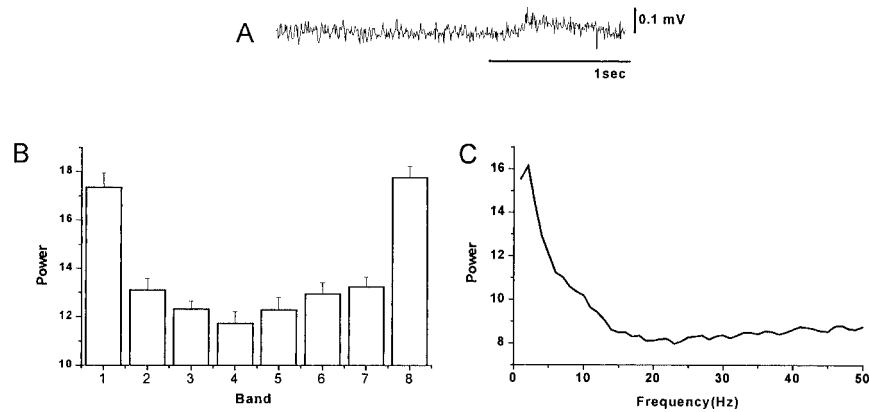


Fig. 1. Raw electroencephalogram (EEG) of a dog in the control state. Raw EEG (A), Power bands (B), and Power spectrum (C).

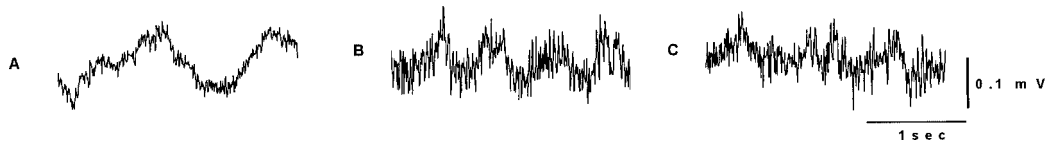

Fig. 2. The raw EEG in dogs treated with tiletamine/zolazepam (Zoletile). A: 10 min after Zoletile injection, B: 20 min after Zoletile injection, C: 1 min prior to dog showing head-up movement.

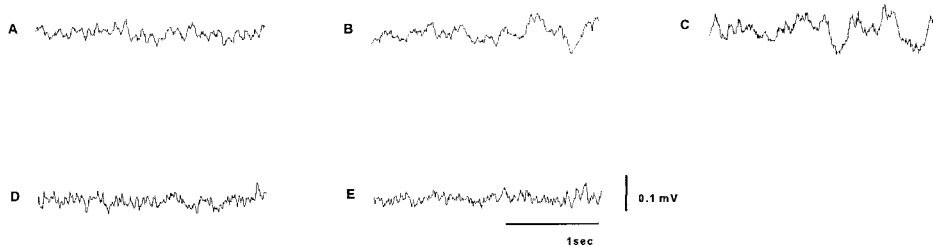


Fig. 3. Raw EEG in dogs treated with xylazine and tiletamine/zolazepam (Zoletile). A: 10 min after xylazine injection, B: 10 min after Zoletile injection, C: 20 min after Zoletile injection, D: 40 min after Zoletile injection, E: 1 min prior to dog showing head-up movement.

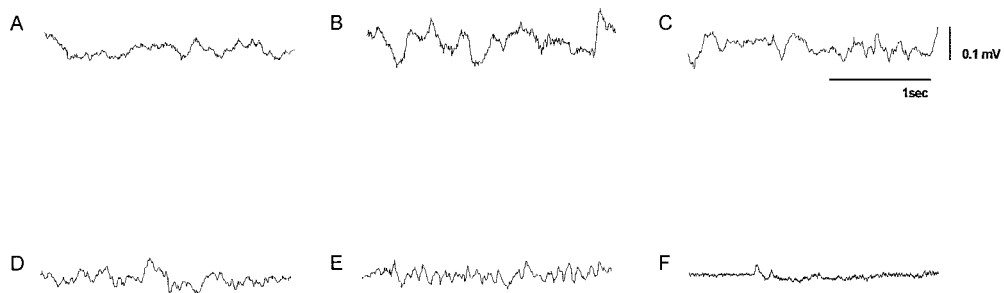


Fig. 4. The EEG in dogs treated with medetomidine and tiletamine/zolazepam (Zoletile). A: 10 min after medetomidine injection, B: 10 min after Zoletile injection, C: 20 min after Zoletile injection, D: 40 min after Zoletile injection, E: 60 min after Zoletile injection, F: 1 min prior to dog showing head-up movement.

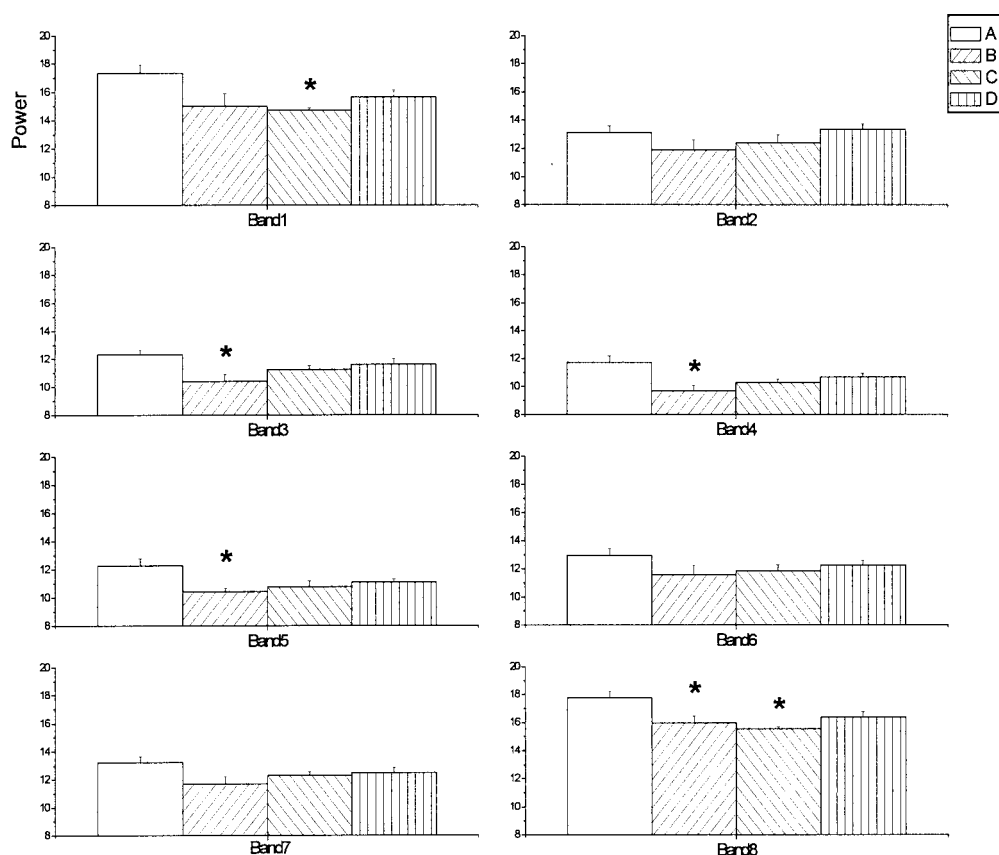


Fig. 5. Mean power bands in dogs treated with Zoletile. A: resting state, control, B: 10 min after Zoletile injection, C: 20 min after Zoletile injection, D: 1 min prior to dog showing head-up movement. *Significantly different from control state ($p < 0.05$).

the surgical procedures. Because the analysis of EEG can assess the level of anesthesia before movements occur, it is useful to maintain the surgical anesthesia. Although a system using amplitude analysis of the EEG and computerized analysis of the animal EEG has been developed for investigating the effects of CNS acting drugs on the brain [5], there are few studies comparing the effects of them by EEG. So, in this study, for evaluating the effects of xylazine or medetomidine on Zoletile anesthesia objectively, changes in the band powers were used.

Lin *et al.* reported that an intravenous injection of Telazol (4 mg/kg) in calves changed the EEG toward electric silence, which was followed by a short period of high-amplitude-slow-frequency activity [12]. Similar EEG patterns were reported in cases of tiletamine (20 mg/kg IM)-zolazepam (10 mg/kg IM) administration to cats [10]. Another study on tiletamine-zolazepam-xylazine in calves reported that after the drug injection, the EEG was changed to slow frequency and high amplitude waves. Similar EEG changes, but of shorter duration, were seen in calves given tiletamine-zolazepam alone. They insisted that the tiletamine-zolazepam-xylazine combination induced a longer

duration of anesthesia because EEG activity changed to a slow frequency and high amplitude under general anesthesia [11]. After Zoletile injection, the slow and high waves were observed in all groups. These patterns lasted longer in XTZ and MTZ, and changed gradually to the low and fast waves as awakening neared. From these findings, it is certain that the slow and high waves are related to the duration of anesthesia. In this study, an electric silence was not observed, which was suspected to be due to different species and injection doses. In TZ, slow and high amplitude waves with low amplitude spikes were observed clearly after Zoletile injection, and were similar to 'ketamine complex' [6]. We thought these were related to the effect of tiletamine.

The decreases in band powers indicate indirectly the reduction in brain activity, that is, the increase of depth of anesthesia in this study. In TZ, the powers of bands 3, 4, 5 and 8 were significantly reduced at 10 min after Zoletile injection. At the same stage, there were significant decreases in range from the low frequency band to the high frequency band in XTZ and MTZ. We guessed these were related to the short and weak anesthesia with Zoletile alone. In other words, premedication with xylazine or

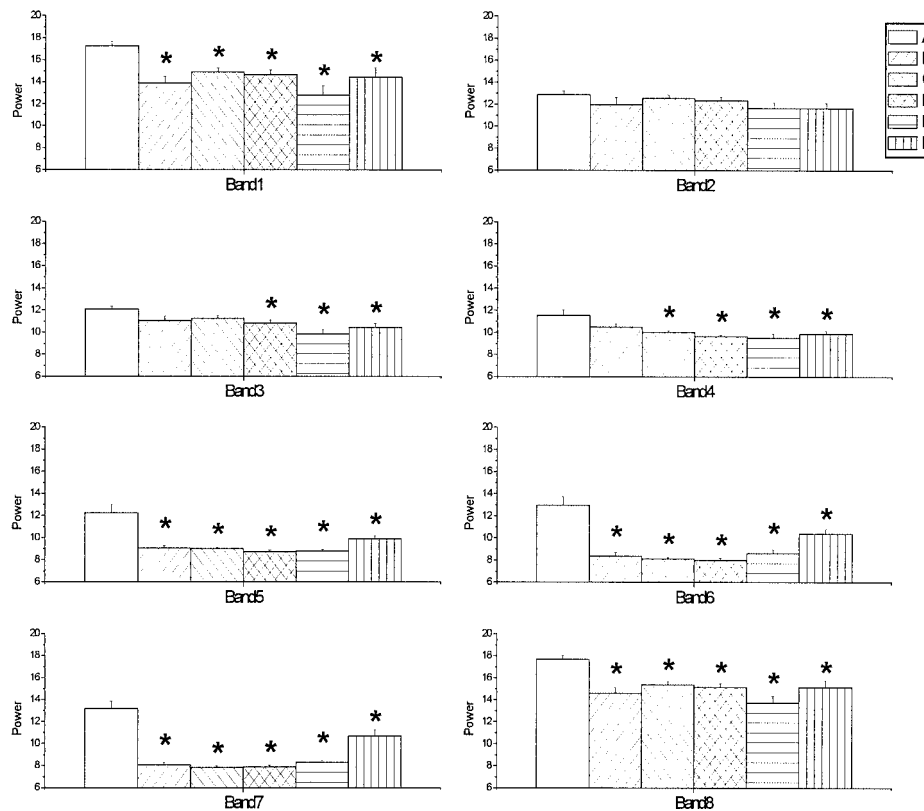


Fig. 6. Mean power bands in dogs treated with xylazine and tiletamine/zolazepam (Zoletile). A: resting state, control, B: 10 min after xylazine injection, C: 10 min after Zoletile injection, D: 20 min after Zoletile injection, E: 40 min after Zoletile injection, F: 1 min just prior to dog showing head-up movement. * Significantly different from control state ($p < 0.05$).

medetomidine on Zoletile anesthesia seems to produce longer and more adequate anesthesia. Although MHT in MTZ was longer than that in XTZ, the changes in band powers at 60 min after Zoletile injection in MTZ were not significant. From these, it seemed that the surgical anesthesia in MTZ was not maintained up to 60 min after Zoletile injection. Although it is difficult to decide which one is more potent only by the changes in the EEG, it is doubtful whether the addition of medetomidine will induce more potent and longer surgical anesthesia than xylazine. It is thought that additional studies about them are needed.

In this study, the changes in bands 6 and 7 seemed to be closely related to the depth of anesthesia. Xylazine or medetomidine injection significantly reduced the powers of bands 6 and 7 in Zoletile anesthesia. If additional study about the aspects of changes in bands 6 and 7 with the passage of time are accomplished, these will be valuable in determining the level of anesthesia and predicting the residual time of anesthesia and the patient's awakening.

In XTZ and MTZ, there were the same significant band changes at 20 min after Zoletile injection. It was suggested that these changes resulted from a similar depth of anesthe-

sia.

There were no significant decreases in all bands in TZ and MTZ for 1 min prior to the point when the dog showed head-up movement. On the contrary, all band powers in XTZ, except band 2, were significantly reduced in the same period. From these, it was found that the reduction of brain activity lasted to the awareness in XTZ, which was related to the effect of xylazine. Comparing previous studies in which premedication was needed to avoid the rough recovery from Zoletile anesthesia [2, 11, 14, 17] with the results of this study, it assumed that the addition of xylazine is more effective in preventing rough recovery in Zoletile anesthesia than the addition of medetomidine. But it was difficult to judge from the results because the visual analogue scale concerning recovery was not used. It is considered that further study is needed.

The EEG recording was stopped when the dog recovered from anesthesia. And we considered that recovery was reached when the dog showed head-up movement. In recovery, most anesthetics induce emergence struggling, and this sometimes damaged patients. Zoletile, in particular, has adverse effects in recovery such as rough and pro-

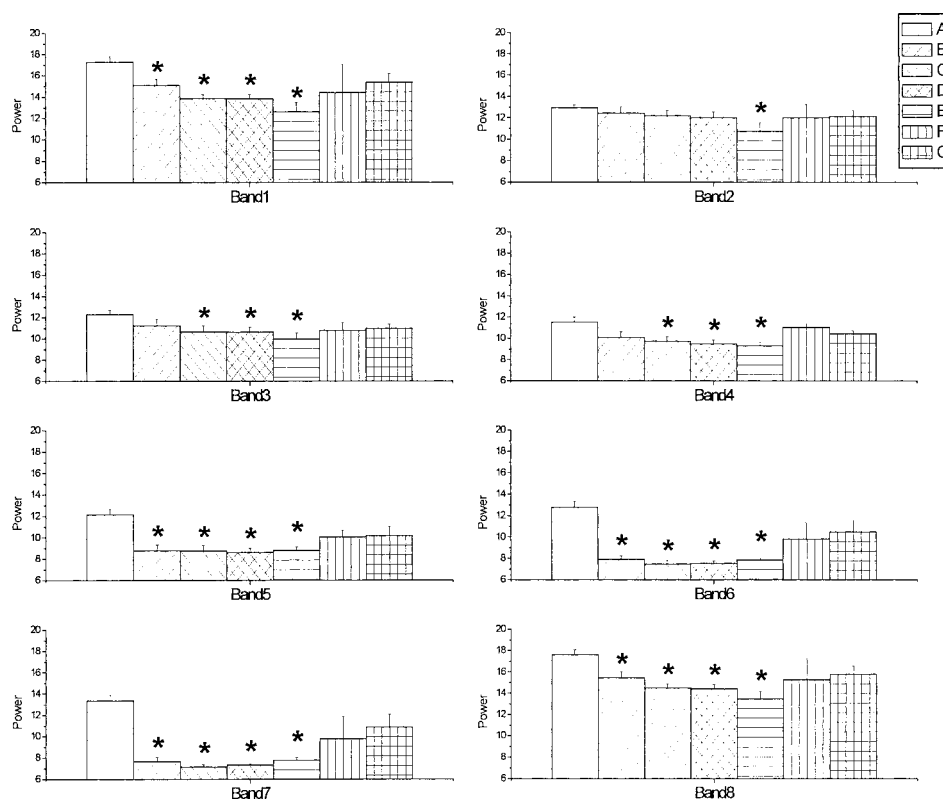


Fig. 7. Mean power bands in dogs treated with medetomidine and tiletamine/zolazepam (Zoletile). A: resting state, control, B: 10 min after medetomidine injection, C: 10 min after Zoletile injection, D: 20 min after Zoletile injection, E: 40 min after Zoletile injection, F: 60 min after Zoletile injection, G: 1 min prior to dog showing head-up movement. * Significantly different from control state ($p < 0.05$).

longed recovery, head rocking, vocalization, involuntary muscular twitching, hypertonia and muscle rigidity [14], which made it impossible to record the EEG without artifacts during recovery.

In this study, we installed a recording electrode at Cz, a midpoint between nasion and inion, which was described in the International 10–20 system. It was selected in order to avoid recording electrical noises produced by neck, eye or ear movements.

In XTZ and MTZ, the duration of anesthesia was significantly longer than that of the control group. But, the difference between MHT and MWT in each group showed little difference. These suggested that the addition of xylazine or medetomidine to Zoletile anesthesia in dogs did not affect the period of recovery.

In conclusion, premedication with xylazine or medetomidine in Zoletile anesthesia significantly reduced most band powers. Especially bands 6 and 7 were valuable parameters to decide the depth of anesthesia in all groups and to predict the awareness of the patient in MTZ. But in the awakening of dogs anesthetized with a xylazine and Zoletile combination, it was difficult to predict by changes in the band powers. Different changes in band powers at awakening were

found despite using the same kind of drugs, and were hard to distinguish only by clinical signs or behavioral changes.

It is thought that additional studies about the anesthetic effect of various doses of Zoletile or medetomidine and effective antagonists in dogs are needed.

REFERENCES

1. Bednarski, R. M. and Tracy, C. H. 1989. The effects of tolazoline, doxapram, Ro 15–1788 on the depressant action of Telazol. *Vet. Med.* **84**: 1016–1022.
2. Caulkett, N. A., Cattet, M. R. L., Cantwell, C. S., Cool, N. and Olsen, W. 2000. Anesthesia of wood bison with medetomidine-zolazepam/tiletamine and xylazine-zolazepam/tiletamine combinations. *Can. Vet. J.* **41**: 49–53.
3. Cullen, L. K. and Reynoldson, J. A. 1997. Effects of tiletamine/zolazepam premedication on propofol anesthesia in dogs. *Vet. Rec.* **140**: 363–366.
4. Donaldson, L. L., Mcgrath, C. J. and Tracy, C. H. 1989. Testing low doses of intravenous Telazol in canine practice. *Vet. Med.* **84**: 1202–1207.
5. Emilien, G. 1990. Effects of clonidine, yohimbine and eserine on the quantified EEG of rats. *Arch. Int. Pharmacodyn.* **304**: 105–124.

6. Hatch, R. C., Booth, N. H., Kitzman, J. V., Wallner, B. M. and Clark, J. D. 1983. Antagonism of ketamine anesthesia in cats by 4-aminopyridine and yohimbine. *Am. J. Vet. Res.* **44**: 417–423.
7. Hatch, R. C., Clark, J. D., Jernigan, A. D. and Tracy, C. H. 1988. Serching for a safe, effective antagonist to Telazol overdose. *Vet. Med.* **83**: 112–117.
8. Itamoto, K., Taura, Y., Wada, N., Takuma, T., Matsumura, H. and Miyara, T. 2001. Effect of medetomidine on electroencephalography and use of a quantitative electroencephalograph for evaluating sedation levels in dogs. *J. Vet. Med. A* **48**: 525–535.
9. Katoh, T., Suzuki, A. and Ikeda, K. 1998. Electroencephalographic derivatives as a tool for predicting the depth of sedation and anesthesia induced by sevoflurane. *Anesthesiology* **88**: 642–650.
10. Lin, H. C. 1996. Dissociative anesthetics. pp. 241–296. *In*: Veterinary Anesthesia (Thurmon, J. C., Tranquilli, W. J. and Benson, G. J. eds.), Williams & Wilkins, Baltimore, U.S.A.
11. Lin, H. C., Thurmon, J. C., Tranquilli, W. J. and Benson, G. J. 1991. Hemodynamic response of calves to tiletamine-zolazepam-xylazine anesthesia. *Am. J. Vet. Res.* **52**: 1606–1610.
12. Lin, H. C., Thurmon, J. C., Benson, G. J., Tranquilli, W. J. and Olson, W. A. 1989. The hemodynamic responses of calves to tiletamine-zolazepam anesthesia. *Vet. Surg.* **18**: 328–334.
13. Moore, M. P., Greene, S. A., Keegan, R. D., Gallagher, L., Gavin, P. R., Kraft, S. L., Deltaan, C. and Klappenbach, K. 1991. Quantitative electroencephalography in dogs anesthetized with 2.0% end-tidal concentration of isoflurane anesthesia. *Am. J. Vet. Res.* **52**: 551–560.
14. Pablo, L. S. and Bailey, J. E. 1999. Etomidate and telazol. *Vet. Clin. North Am. Small Anim. Pract.* **29**: 779–792.
15. Pypendop, B., Serateyn, D. and Verstegen, J. 1996. Hemodynamic effects of medetomidine-midazolam-butorphanol and medetomidine-midazolam-buprenorphine combination and reversibility by atipamezole in dogs. *Am. J. Vet. Res.* **57**: 724–730.
16. Pypendop, B., Poncelet, L. and Verstegen, J. 1999. Use of mid-latency auditory-evoked potentials as indicator of unconsciousness in the dog: characterization of the effects of acepromazine-thiopentone, medetomidine-thiopentone and medetomidine-butorphanol-midazolam combinations. *Res. Vet. Sci.* **67**: 35–39.
17. Short, C. E. 1989. Talking about Telazol, Roundtable. *Vet. Med.* **84**: 1–8.
18. Short, C. E. 1991. Effects of anticholinergic treatment on the cardiac and respiratory systems in dogs sedated with medetomidine. *Vet. Rec.* **129**: 310–313.
19. Verstegen, J., Fargetton, X., Donnay, I. and Ectors, F. 1991. An evaluation of medetomidine/ketamine and other drug combinations for anesthesia in cats. *Vet. Rec.* **128**: 32–35.