

A Case of a Ruptured Pheochromocytoma with an Intratumoral Aneurysm Managed by Coil Embolization

Ji-HYUN PARK, KYUNG-PYO KANG, SUNG-JOONG LEE, CHONG-HWA KIM, TAE-SUN PARK
AND HONG-SUN BAEK

Division of Endocrinology and Metabolism, Department of Internal Medicine, Chonbuk National University Medical School, Chonju 561-712, Korea

Abstract. Although the spontaneous rupture of adrenal pheochromocytoma is rare, it can be lethal because it can induce serious changes in the circulation. We describe a 32 year old man with bilateral pheochromocytoma presenting as abdominal pain. In the emergency room, an abdominal MRI showed an aneurysmal vessel in the right adrenal mass and accompanying hemorrhage around the tumor capsule. The bleeding site was found by transfemoral abdominal angiography. Coil embolization was done in the bleeding vessels, specifically branches of the right adrenal artery. The hemorrhage was successfully controlled and vital signs of the patient were restored. Following emergency care, biochemical and imaging studies showed compatible findings of a bilateral adrenal pheochromocytoma. Postoperative histologic findings confirmed these observations. A ruptured pheochromocytoma should be considered as a cause of acute abdomen in cases of a concomitant adrenal mass. Intratumoral aneurysmal bleeding may be a cause of ruptured tumor, and careful angiographic intervention will help to ensure safe control of bleeding in such an emergency situation, even in cases of bilateral tumor.

Key words: Pheochromocytoma, Aneurysm, Rupture, Angiography, Embolization

(*Endocrine Journal* 50: 653–656, 2003)

THE spontaneous rupture of adrenal pheochromocytoma is very rare. The mechanism of rupture is unknown, but high intracapsular pressure may play a role [1]. Elective resection of a ruptured pheochromocytoma following pharmacological control has a low mortality rate. However, emergency surgery in undiagnosed cases is associated with a high mortality rate [2]. This case report describes a patient with bilateral pheochromocytoma presenting as acute abdominal pain. In addition, this case study describes the management of a ruptured pheochromocytoma which allows for the subsequent endocrinologic work-up and careful surgical planning. To our knowledge,

this case is the first report showing an intratumoral aneurysm and safe coil embolization in bilateral pheochromocytoma.

Case report

A 32-year-old man presented himself to the emergency room complaining he had suddenly experienced right abdominal pain for the past 48 hours. The pain began in the right abdominal area, radiated to the right flank area, and was associated with nausea, vomiting, and a febrile sensation. Five years prior, he had been diagnosed with hypertension and taken intermittent over-the-counter medication. He had visited another hospital, and undergone abdominal computerized tomography (CT), which demonstrated bilateral adrenal masses with hemorrhage in the right adrenal. He was then referred to our hospital. Upon admittance, he appeared pale and acutely ill. A physical examination

Received: February 13, 2003

Accepted: April 22, 2003

Correspondence to: Hong-Sun BAEK, M.D., Ph.D., Division of Endocrinology and Metabolism, Department of Internal Medicine, Chonbuk National University Medical School, 634-18, Keum-Am Dong, Dukjin Gu, Chonju, Chonbuk, 561-712, Korea

revealed a distended abdomen with tenderness on the right upper quadrant and knocking tenderness on the right flank area. Bowel sounds were decreased. During his visit to the hospital, his blood pressure was 170/100 mmHg, pulse rate was 90 beats per minute (bpm), and his body temperature was 37.0°C. A plain abdominal X-ray revealed multiple dilated small bowel loops without free air. The patient's white blood cell count was 11,900/ μ l (normal: 4,800 to 10,800/ μ l), hemoglobin was 11.3 g/dl (normal: 13 to 18 g/dl), hematocrit was 34.0% (normal: 42 to 52%), and serum electrolytes, liver function and renal functions were found to be normal. In the emergency room, he complained of continuing abdominal pain. Abdominal magnetic resonance imaging (MRI) showed a 7 cm-sized heterogeneous signal intensity mass above the right kidney and acute or subacute stage hemorrhagic signal intensity around the mass (Fig. 1A). A heterogeneous mass was shown following contrast enhancement, and an enhanced aneurysmal vascular lesion was noted in the mass (Fig. 1B). The left adrenal mass was 3.8 cm in size, well-circumscribed, and heterogeneous (Fig. 1A). However, it was difficult to confirm that the abdominal mass was a pheochromocytoma without a biochemical analysis. The patient's blood pressure had decreased from 170/100 mmHg to 100/50 mmHg. In a follow-up

examination, hemoglobin and hematocrit levels were found to have decreased to 8.5 g/dl and 27.4%, respectively, despite transfusion of 3 units of packed red cells (PRC). We decided to perform an abdominal angiography, which located the bleeding vessel. Angiography was performed via a right femoral artery approach. The selective cannulation of the right adrenal artery was performed with a 5-French Yashiro Catheter (Glidecath, Terumo, Tokyo, Japan). The tumor vascularity was shown only in its medial and inferior portion. The non-visualization of the superior and lateral aspect of the tumor margin suggested to us a tearing of the tumor capsule (Fig. 2A). An aneurysmal vessel was noted in the superior portion of the tumor, and the extravasation of contrast dye (Visipaque 320, Nycomed Amersham, Cork, Ireland) from the vessel was identified (Fig. 2A). Coil embolizations were then performed with 3 in the medial and 5 micro coils in the lateral branches of the right adrenal artery using a 3-French microcatheter (Progreat, Terumo, Tokyo, Japan). Subsequent contrast injection demonstrated no further tumor vascularity (Fig. 2B). Following embolization, his vital signs stabilized.

The results of hormone examination were as follows: plasma epinephrine, 68.0 pg/ml (normal: 0 to 110 pg/ml); norepinephrine level, 8529.0 pg/ml (normal: 70 to 750 pg/ml); urine vanillylmandelic acid,

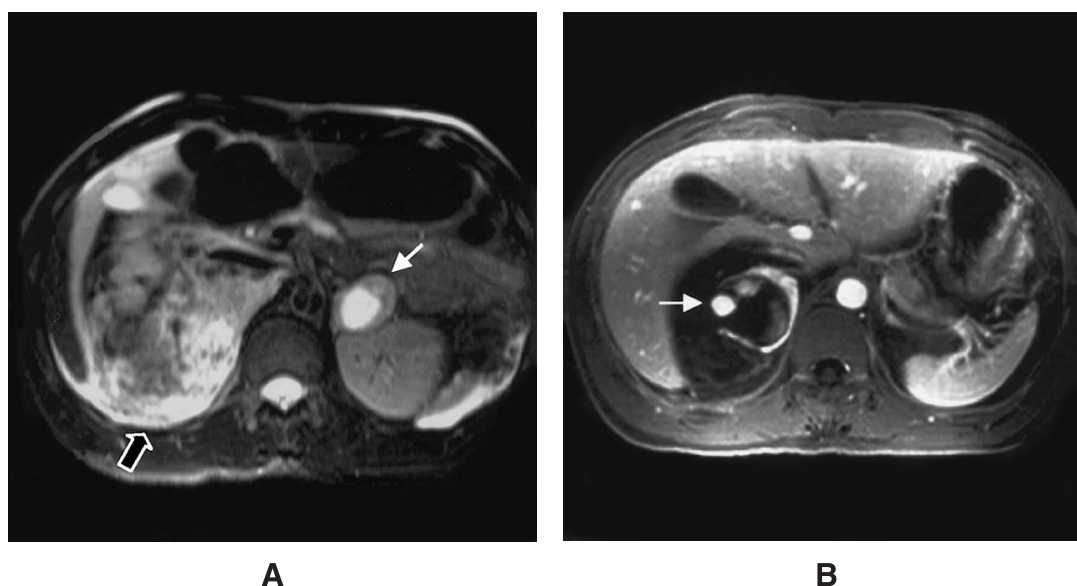


Fig. 1. Abdominal MRI. (A) T2-weighted image shows heterogeneous high signal intensity (open arrow) suggestive of retroperitoneal bleeding around the right kidney, and also shows a 3.8 cm-sized high signal mass (thin arrow) in the left adrenal gland. (B) T1-weighted image after the injection of contrast media shows an aneurysmal enhanced vascular lesion (thin arrow) and areas of high signal intensity in the right adrenal mass.

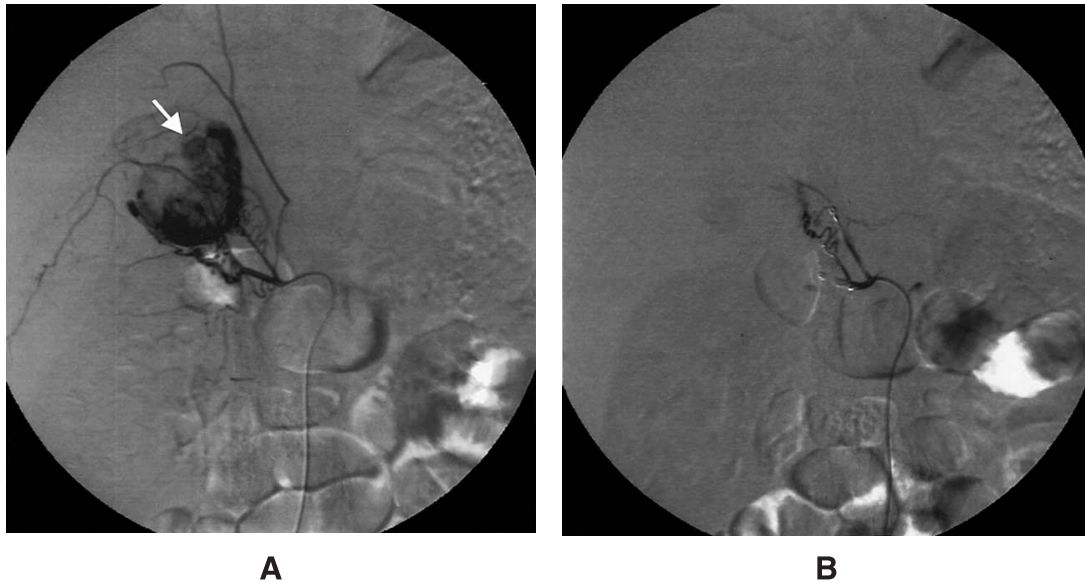


Fig. 2. The embolization of the right adrenal artery. (A) Selective right adrenal angiogram demonstrates an extravasation focus from an aneurysmal vessel (thin arrow), which is located in the superior portion of the stained right adrenal tumor. (B) Following embolization with 8 micro coils (seven 3 mm \times 2 cm coils and one 4 mm \times 2 cm coil), a repeat right adrenal angiogram shows no more tumor staining.

33.1 mg/day (normal: 0 to 8 mg/day); urine epinephrine and norepinephrine 12.9 μ g/day (normal: 0 to 20 μ g/day) and 506.1 μ g/day (normal: 15 to 80 μ g/day), respectively; urine metanephrine, 8.2 mg/day (normal: 0 to 1.2 mg/day). High performance liquid chromatography (HPLC) was used to measure the levels of plasma and urine catecholamines and catecholamine metabolites. The serum levels of cortisol, aldosterone, and pituitary hormones were within normal limits. The thyroid function test was also normal. Because of the bilaterality of the tumor, MEN 2A was suspected in this case. We checked the patient's serum calcitonin and carcinoembryonic antigen levels and the status of RET proto-oncogene, which were all negative. Using samples of peripheral blood, mutation analysis of RET proto-oncogene was performed by direct sequencing of RET exons 10, 11, and 16. Using immunoradiometric assay (IRA), parathyroid hormone (PTH) level was found to be 41.5 pg/ml (normal: 9 to 55 pg/ml).

21 days following the patient's initial visit the hospital, resection of an adrenal hematoma on the right side and a left adrenalectomy were performed via a transabdominal approach with proper preoperative treatment. A very large hematoma and severe adhesions around the right adrenal gland hampered a complete right adrenalectomy. Pathological findings

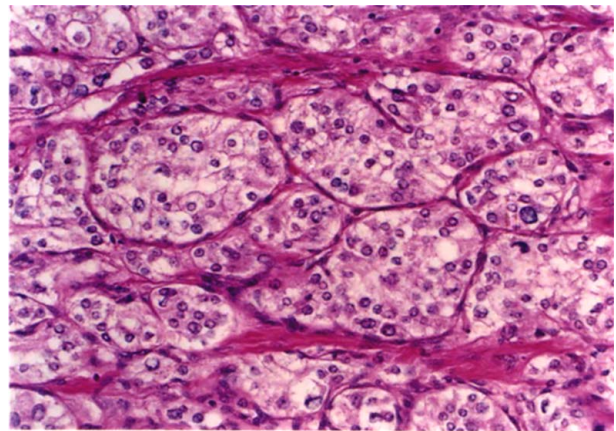


Fig. 3. The histologic finding of the adrenal mass. The section revealed alveolar (zellballen) arrangement of tumor cells. The cytoplasm of the tumor cells is lightly eosinophilic and finely granular (H & E stain, \times 100).

confirmed the diagnosis of an adrenal pheochromocytoma (Fig. 3). Treatment using high dose iodine-¹³¹metaiodobenzylguanidine has been planned for the remaining right adrenal pheochromocytoma.

Discussion

The diagnosis of pheochromocytoma is usually sug-

gested by its clinical symptoms. The classic triad consist of headache, palpitation, and diaphoresis. When these three symptoms are present and associated with hypertension, a diagnosis of pheochromocytoma is indicated with a specificity of 93.8% and a sensitivity of 90.8% [3]. The patient in our case was found to have only hypertension and abdominal pain. We suspected pheochromocytoma from our radiological findings. However, pheochromocytoma presenting itself as a spontaneous rupture and not an intratumoral hemorrhage is extremely unusual.

The exact mechanism of a pheochromocytoma rupture is unknown but the high intracapsular pressure may tear the capsule and also cause necrosis of the tumor [1]. From this case, we suggest that bleeding from the aneurysmal vessel may be the cause for an elevated intracapsular pressure in pheochromocytoma rupture.

Angiography is rarely indicated in the diagnosis of pheochromocytoma with classic symptoms and may impose a significant risk of a serious hypertensive crisis [3]. Contrast-induced adrenergic crises during arteriography or venography have been reported [4, 5]. Raisanen *et al.* noticed a substantial increase in norepinephrine levels after the injection of an ionic contrast media in five of eight patients [6]. Based

upon these reports, our case may have been more risky because our patient had another mass on the left side. Nonetheless, our patient had undergone coil embolization without any adverse events. Actually, a recent study has shown that selection of noncontrast media such as iohexol did not have an impact on catecholamine release [7]. Iohexol was also used for angiography in this case. We have identified two reported cases describing the angiographic approach for single pheochromocytoma with retroperitoneal hemorrhage [8, 9]. The angiographic dye and embolization material used in these cases could not be identified. Adverse events related to the angiography occurred in neither of these two cases. Conclusions may be tentatively drawn from one of the two cases that embolization might have caused the tumor to be falsely endocrinologically inactive [9].

In summary, bleeding from an aneurysmal vessel in pheochromocytoma may result in a rupture. Angiographic intervention using noncontrast media may be a useful procedure in diagnosing retroperitoneal hemorrhage under emergency conditions, even in cases in which bilateral tumor exist. It is crucial to control bleeding in such a situation and decrease the chances of mortality via an emergency operation.

References

1. Tanaka K, Noguchi S, Shuin T, Kinoshita Y, Kubota Y, Hosaka M (1994) Spontaneous rupture of adrenal pheochromocytoma: a case report. *J Urol* 151: 120–121.
2. Sumino Y, Tasaki Y, Satoh F, Mimata H, Nomura Y (2002) Spontaneous rupture of adrenal pheochromocytoma. *J Urol* 168: 188–189.
3. Harry R Keiser (2001) Pheochromocytoma and related tumors In: Leslie J, DeGroot J, Larry Jameson (eds) *Endocrinology*. Philadelphia, Saunders, vol. 3: 1862–1883.
4. Brueckel J, Boehm BO (1998) Crisis after angiography. *Lancet* 352: 1278.
5. Gold RE, Wisinger BM, Geraci AR, Heinz LM (1972) Hypertensive crisis as a result of adrenal venography in a patient with pheochromocytoma. *Radiology* 102: 579–580.
6. Raisanen J, Shapiro B, Glazer GM, Desai S, Sisson JC (1984) Plasma catecholamines in pheochromocytoma: effect of urographic contrast media. *Am J Roentgenol* 143: 43–46.
7. Mukherjee JJ, Peppercorn PD, Reznick RH, Patel V, Kaltsas G, Besser M, Grossman AB (1997) Pheochromocytoma: effect of nonionic contrast medium in CT on circulating catecholamine levels. *Radiology* 202: 227–231.
8. Hendrickson RJ, Katzman PJ, Queiroz R, Sitzmann JV, Koniaris LG (2001) Management of massive retroperitoneal hemorrhage from an adrenal tumor. *Endocr J* 48: 691–696.
9. Ito K, Nagata H, Miyahara M, Saito S, Murai M, Narimatsu Y (1997) Embolization for massive retroperitoneal hemorrhage from adrenal pheochromocytoma: a case report. *Hinyokika Kiyo* 43: 571–575.