

Revisiting Orthodromic Temporalis Transfer in Treating Long-Standing Facial Paralysis

Amir S. Elbarbary, M.D.,¹ Mostafa Hemeda, M.D.,¹ and Adel H. Amr, M.D.¹

ABSTRACT

The treatment of long-standing facial paralysis through temporalis muscle transfer has stood the test of time. Herein, we present a modification in temporalis muscle transfer for lower facial reanimation. Instead of the traditional stripping of the temporalis muscle from its origin, its insertion is stripped from the coronoid process through an intraoral approach. The detached fibers were then sutured to a fascia lata graft, which was passed and secured to the orbicularis oris to reanimate the corner of the mouth. The procedure is less extensive and provides a direct “orthodromic” line of pull with good muscular excursion and power. This simple procedure has been applied to 12 consecutive cases with long-standing complete facial paralysis presenting to the Plastic and Reconstructive Surgery Clinic at the Ain-Shams University Hospital over the past 2 years. In addition to symmetry at rest, this easy procedure allowed for good movement of the corner of the mouth with restoration of a balanced smile.

KEYWORDS: Temporalis, orthodromic, facial paralysis

The transposition of regional muscles to treat long-standing facial paralysis has been known for almost a century¹ with an objective of transfer of a muscle innervated by a nerve other than the facial nerve. The goal is facial symmetry at rest and with voluntary smiling.² The muscle used most frequently is the temporalis muscle,^{3,4} innervated by the trigeminal nerve, and thus not compromised by a facial nerve lesion or injury.

Gillies⁵ was the first to propose stripping of temporalis from its origin followed by its inversion over the zygomatic arch. A graft of fascia lata bridged the muscle to the nasolabial sulcus. This antidromic transposition resulted in an extra bulge over the zygomatic arch and caused a distinct facial asymmetry. Several modifications were introduced to overcome this problem.^{6–9} However, it was only in 1953 that McLaughlin¹⁰ proposed inline “orthodromic” transpo-

sition of the temporalis muscle without changing its direction. Preserving the muscle direction (i.e., orthodromic) results in good muscular excursion and power. The muscle was freed inferiorly, by osteotomy of the coronoid process, through an intraoral approach. The muscle was passed below the zygomatic arch and extended by a fascia lata graft sutured to the orbicularis oris muscle, thus pulling at the corner of the mouth. The inconvenience of the intraoral route, operating through a small window with a bone saw, stimulated Breidahl et al¹¹ to perform a similar procedure, using an extraoral approach. However, this necessitated a partial resection of the zygomatic arch to visualize the muscle tendon. This method resulted in greater facial symmetry and depression at the arch because of the absence of bone.² Recently, Viterbo and de Paula Faleiros² recommended the orthodromic transposition without removing the

¹Department of Plastic and Reconstructive Surgery, Ain-Shams University, Cairo, Egypt.

Address for correspondence and reprint requests: Amir S. Elbarbary, M.D., Department of Plastic and Reconstructive Surgery, Ain-Shams University, 25 Ahmed Fuad Street, Heliopolis, Cairo 11361, Egypt (e-mail: amir_elbarbary@yahoo.com).

Craniomaxillofac Trauma Reconstruction 2010;3:17–23. Copyright

© 2010 by Thieme Medical Publishers, Inc., 333 Seventh Avenue, New York, NY 10001, USA. Tel: +1(212) 584-4662.

Received: August 8, 2009. Accepted: October 10, 2009. Published online: March 11, 2010.

DOI: <http://dx.doi.org/10.1055/s-0030-1249370>.

ISSN 1943-3875.

bone of the zygomatic arch and with minimal muscle manipulation. Although theoretically appealing, it is technically difficult to reach to the insertion without cutting the arch. Quite often, the arch had to be removed before it was repositioned and fixed back at the end of the procedure.¹² This adds to the surgical time with increased risks of both intraoperative bleeding and injuring the temporalis innervations, and the external scars are always undesirable.

Trying to improve on these methods, a modification in the orthodromic transposition of the temporalis muscle was developed. It included essentially McLaughlin's¹⁰ intraoral approach but without performing the osteotomy of the coronoid process. This modification makes use of the advantage of the orthodromic transposition of the temporalis muscle in terms of better muscle excursion and power. In addition, it renders this technique simple to use with good aesthetic results and lesser surgical time.

The aim of this follow-up study is to evaluate the clinical usefulness of a modified orthodromic transposition of the temporalis muscle in treating long-standing facial palsy through stripping its insertion off the coronoid process using an intraoral approach.

PATIENTS AND METHODS

In 12 consecutive patients suffering from long-standing facial paralysis, a modified technique in orthodromic transposition of the temporalis muscle through an intraoral approach was applied at the Department of Plastic and Reconstructive Surgery, Ain-Shams University Hospital over the past 2 years. All patients in the study population were managed using the same protocol. The risk of developing corneal ulcers was ruled out first by testing for Bell's phenomenon (Fig. 1). The power of the temporalis muscle was confirmed by asking the patients to clench their teeth. The direction and extent of smile on the normal side was analyzed (Fig. 2). This was done to apply the vector of pull on the reconstructed side mimicking, as much as surgically feasible, the movement on the patient's normal side. The exclusion criteria included patients with the primary smile vector in the direction of pull of the buccinators-risorius com-

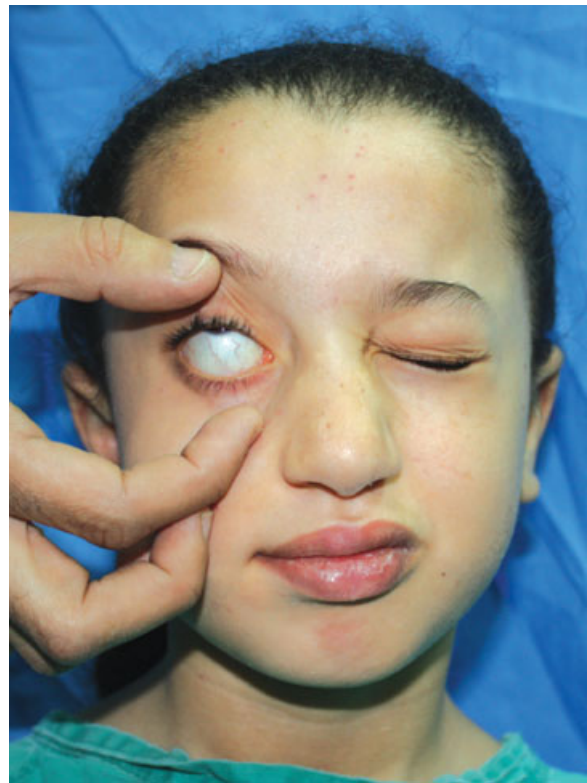

Figure 1 Eyeball drifting upward on the paralyzed side while attempting voluntary closure of eyelids allows coverage of cornea during sleep and indicates a positive Bell phenomenon.

plex because they are better managed by masseter transposition. Patients at risk of developing corneal ulcers were managed primarily for reconstruction of the eyelids prior to attempting oral commissure reanimation.

Treatment was undertaken under general anesthesia with nasoendotracheal intubation. The position of the patient was supine, with the face turned toward the normal side. A bite block was inserted between the molars of the normal side to maintain mouth opening during intraoral component of the procedure. The coronoid process with the insertion of the temporalis muscle was exposed using an intraoral incision made over the anterior border of the ascending ramus. The incision was carried down through the periosteum and

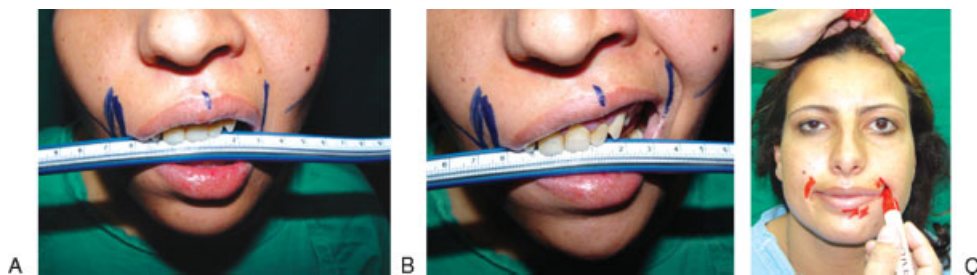


Figure 2 Analysis of the direction and extent of smile on the normal side. Measuring the distance from the interincisal point to commissure: (A) at rest and (B) during smiling in a case of right-sided palsy. (C) Marking of the vector of pull and nasolabial crease at the paralyzed side in a case of left-sided palsy.

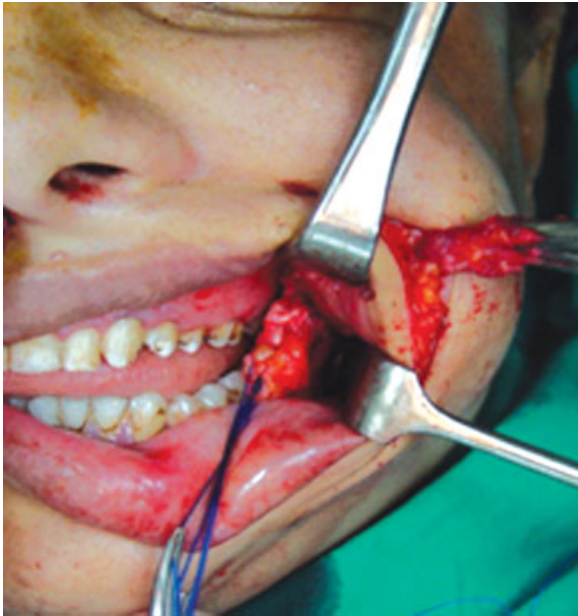

Figure 3 A fascia lata graft sutured to the insertion of the temporalis intraorally and passed through a supra-SMAS tunnel to reach the nasolabial crease.

extended no more superior than the occlusal plane of the mandibular teeth to help prevent herniation of the buccal fat pad into the surgical field. Subperiosteal dissection was done superiorly till the glistening insertion of temporalis at the coronoid was reached. Stripping the insertion of the muscle was done meticulously while holding it with several prolene 3/0 sutures to avoid its cephalad retraction. A 3-cm incision at the nasolabial fold was made where the orbicularis oris muscle was exposed. Wide subcutaneous undermining was performed cephalad creating a tunnel superficial to the superficial musculoaponeurotic system (SMAS), which was then connected to the intraoral incision (Fig. 3). A fascia lata graft, 3 × 10 cm, was harvested and sutured to the insertion of the temporalis. The graft was passed into the subcutaneous tunnel and its caudal end was sutured

with overcorrection to the modiolus at the corner of the mouth. At this point, the graft was split and each half passed for a few centimeters into the corresponding lip (Fig. 4) and sutured along multiple superficial and deep points into the orbicularis oris using prolene 4/0 sutures. The graft was also sutured into the dermis at the nasolabial fold.

During the immediate postoperative period, a soft diet was recommended for 30 days. The patients were instructed to consciously clench their teeth in front of a mirror in conjunction with smiling. They were also instructed to exercise maximum mouth opening and closure several times a day to overcome any anticipated scarring at the site of muscle insertion detachment at the coronoid.

The duration and causes of facial paralysis were recorded. Outcomes measured included patient satisfaction, objective measurements of oral commissure elevation with smiling, and physician grading of preoperative and postoperative patient photographs. The grading classification by Viterbo and de Paula Faleiros² and May^{3,13} was adopted: 1, excellent (patient smiles voluntarily with exposure of the teeth); 2, good (discreet smile, pulling up the corner of the mouth); 3, average (facial asymmetry at rest); and 4, bad (no change). Postoperative complications were evaluated.

RESULTS

The study population included nine female patients and three male patients with old unilateral complete facial paralysis. The average age of patients at the time of reconstruction was 16.4 years (range, 7 to 45 years). The average duration of paralysis was 9.8 years (range, 3 to 21 years). The causes of facial paralysis included four posttraumatic cases, three congenital cases, and three cases of Bell's palsy; in the remaining two cases it occurred following tumor resection. All patients were ruled out for the risk of developing corneal ulcers prior to reanimating the corner of the mouth.

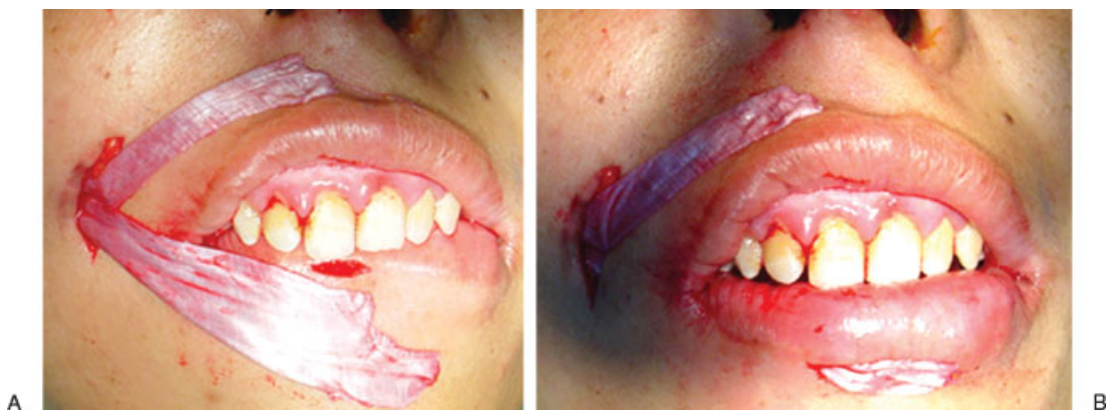

Figure 4 The fascia lata graft was split and each half passed for a few centimeters into a subcutaneous tunnel to the corresponding lip.

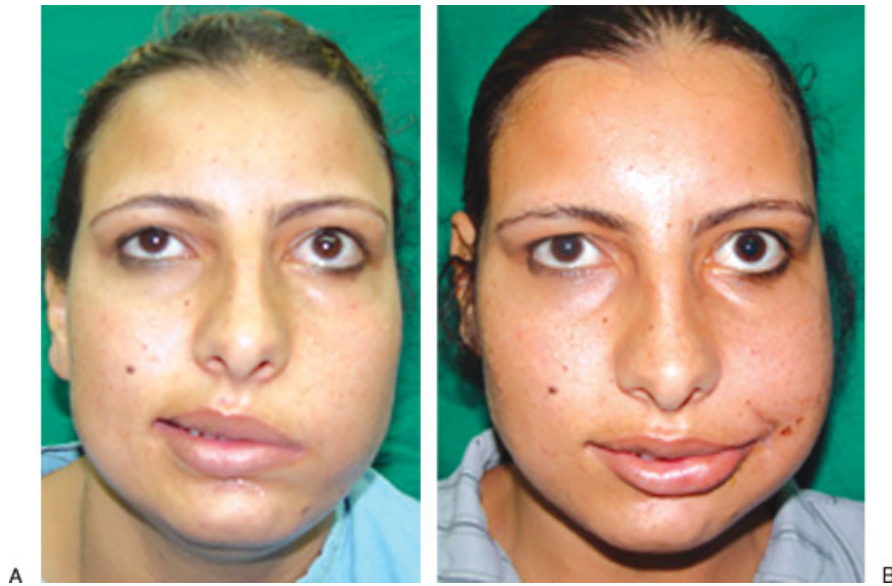

Figure 5 A case of left-sided congenital facial palsy. (A) Before surgery. (B) Three weeks following orthodromic temporalis transfer.

In the first week after surgery, the patients showed edema and in some cases ecchymoses, which generally cleared by the end of the second week. Approximately a couple of months later, any overcorrection resolved and the corner of the mouth descended to a normal position (Figs. 5–7).

Patient satisfaction was high, with a mean score of 8.2 (out of 10). Seven patients were physician graded as good. Three patients were rated as having excellent postoperative results. One patient was rated as having an average result and the remaining one as poor. Movement was identified in every patient and ranged from 2.5 to 11.0 mm, with an average movement of the oral commissure of 8.7 mm. Only one patient developed

postoperative infection at the nasolabial fold incision and was treated with antibiotics. No complaints of paresthesia, hyposthesia, or scar on the donor leg were noticed. The patient with the poor result was readjusted by further tightening, otherwise none of the patients required a revision of surgery for unacceptable contour or asymmetry. No muscle compromise has been observed because innervation and vascularity were maintained.

DISCUSSION

Whereas facial expression is imperative to communication, facial paralysis has serious physical and emotional ramifications.¹⁴ When the mouth is affected, facial

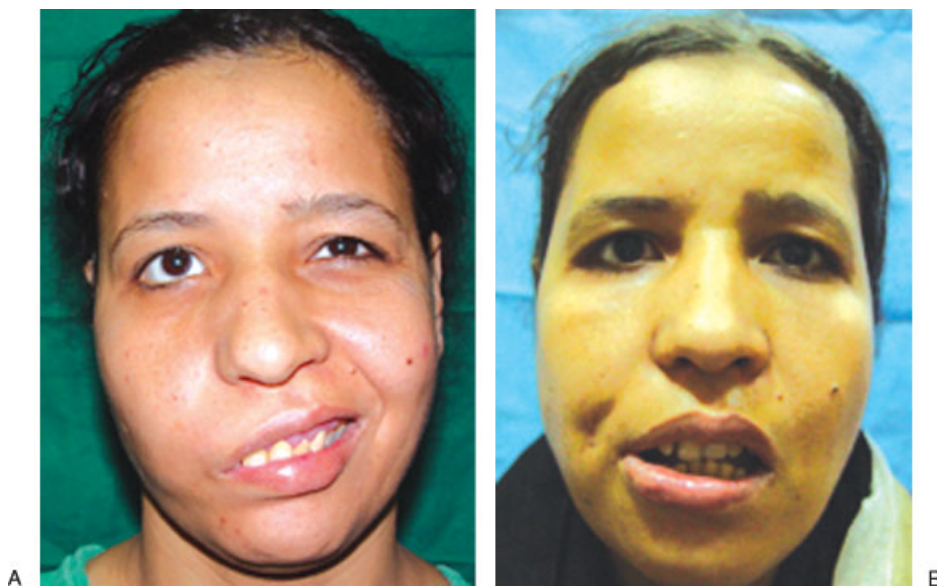

Figure 6 A case of right-sided congenital facial palsy. (A) Before surgery. (B) Nine months following orthodromic temporalis transfer.

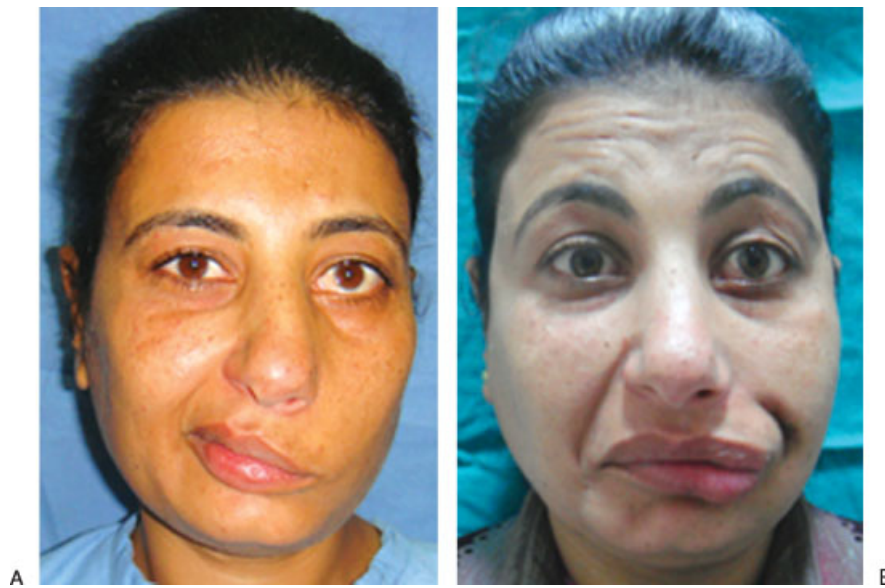

Figure 7 A case of left-sided posttraumatic facial palsy. (A) Before surgery. (B) Three months following orthodromic temporalis transfer.

paralysis hinders the patient's ability to smile symmetrically. Paralysis of the orbicularis oris muscle leads to incompetence, which manifests as an ipsilateral spillage of food and liquids along with a difficulty in pronunciation of words that require pursing of the lips. Loss of tone in the buccinator muscle leads to masticatory problems due to the difficulty with clearance of food from the ipsilateral gingival buccal sulcus and may cause trauma to the mucosa.¹⁵

Many techniques have been proposed for the treatment of long-standing facial paralysis. This denotes that there is not yet one universal method for its treatment.² The major objectives of lower facial reanimation are to achieve symmetry at rest, oral sphincteric competence, and facial movement.³ Static slings achieve symmetry at rest.^{16,17} However, it is the preservation of facial muscles that maintains a symmetry upon smiling. Unfortunately, facial muscles of expression are atrophied in cases of long-standing paralysis, and nerve grafting procedures alone do not represent an appropriate line of treatment. In these cases, transplants or muscle transpositions are indicated. Muscle transplant surgery is demanding, requiring microsurgical techniques and the training of a surgical team. On the other hand, a muscle transposition presents a simpler procedure with predictable results.¹⁸

Temporalis and masseter muscle transpositions have long been used in attempts to reanimate the face in long-standing facial paralysis.^{13,19–22} The choice of the appropriate muscle for transfer is based on the main vector of the contralateral smile.^{23,24} In all patients included in this study, the principal vector of the contralateral smile was superolateral in the direction of pull of the zygomaticus major muscle. Therefore, transposition to reanimate the corner of the mouth allowing a

smile was done using the temporalis muscle. In one patient, who was encountered during the study but not included, the primary vector was in the direction of pull of the buccinators-risorius complex, and he was managed by masseter transposition.

All patients exhibited positive Bell's phenomenon and were sent to an ophthalmologist for gold weight²⁵ application to close the eyelids rather than using the temporalis. This is in accordance with Casler and Conley's²⁶ "dual reanimation" system, addressing the eye and mouth with independent surgical procedures. It was found that if a single muscle was used to reanimate more than one anatomic region, mass action becomes unavoidable. The old saying "mass action is better than no action" is no longer true for these patients.¹⁴ The best functional and cosmetic outcomes are provided when using the dual-system reanimation.²⁶ Furthermore, May and Drucker,³ who have reported one of the largest series of temporalis transfers in the literature, concluded that a better reanimation of the eye was achieved by techniques other than temporalis transfer. They use temporalis transfer exclusively for lower facial reanimation.

The antidromic transposition of the temporalis muscle with traditional stripping from its origin was first proposed by Gillies.⁵ A graft of fascia lata bridged the muscle to the oral commissure. Thus, when the patient would bite, the temporal muscle would contract, pulling up the corner of the mouth and mimicking a smile. Andersen⁶ used deep temporal fascia, instead of the fascia lata, a method further proposed by Rubin.⁷ Baker and Conley⁸ used the pericranium in continuity with the origin of the temporalis muscle to increase the length of the flap, avoiding grafts of fascia. In all these antidromic temporalis transpositions, the muscle requires an extensive dissection and folding it inferiorly produced a bulge

over the zygomatic arch. This bulge was further accentuated by the unattractive hollowness in the temple at the site of harvest causing distinct facial asymmetry and thus a major aesthetic loss.^{9,11} Furthermore, expanded surgical time is required, and there are the associated risks of intraoperative bleeding and injury to the temporalis innervation. May⁹ modified the technique, transposing the middle third of the temporalis muscle to minimize the bulging at the zygomatic arch. He used Gore-Tex tape to reach the corner of the mouth. May and Drucker³ advocated a wider tunnel to accommodate the muscle to lie flat within it, thus decreasing the residual asymmetry.

The osteotomy of the coronoid through the mouth and the traction of the muscle around the mouth, proposed by McLaughlin¹⁰ represent an advancement in terms of transposition of the temporal muscle. Preserving the muscle direction (i.e., orthodromic) results in good muscular excursion and power. However, because of using a bone saw through a small intraoral operating window, the procedure was never popular.² Breidahl et al¹¹ tried to solve this problem by performing an extraoral approach and osteotomy of the zygomatic arch to visualize the temporalis muscle tendon. This method led to a greater facial asymmetry because the bulge at the arch was rather replaced by a depression. The modification of the extraoral orthodromic transposition by Viterbo and de Paula Faleiros² is technically demanding whereas the muscle lengthening proposed by Labbé and Huault¹² needs a greater muscle manipulation.

The modification presented in this study takes into account the advantages of the orthodromic (i.e., inline transposition of the temporalis muscle) in terms of better muscle excursion and power,² without removing the bone of the zygomatic arch or the coronoid, and with minimal muscle manipulation. The intraoral incision is a well-hidden scar and provides good access to the operative field. It offers simplicity to the technique with good aesthetic results and lesser surgical time. Finally, detaching the temporalis insertion intraorally avoids injuring innervations of the muscle that could result when performing it extraorally.²⁷

Placing an incision externally in the nasolabial fold was done to enhance symmetry as advocated by Baker and Conley.⁸ Suturing the fascia lata to the dermis at the nasolabial fold was done to enhance accentuation of the fold when the muscle was activated by clenching of the teeth as promoted by Anderson.¹⁴ Attaching the fascial bands to the modiolus and to multiple superficial and deep points along the orbicularis oris was done to improve the overall aesthetic result in agreement with Duckert and Cummings.²² This is in opposition to Viterbo and de Paula Faleiros,² who believed that double fixation of the fascia to both lower and upper lips could result in an undesirable opening of the mouth. Unlike the technique of Viterbo and de Paula Faleiros² that

sutured the graft to the temporalis last, suturing the fascia to the temporalis tendon was done first in this study. This was technically more feasible when ensuring the overcorrection because the intraoral approach was used.

In this study, good movement of the corner of the mouth with restoration of smile was achieved upon clenching. Anderson¹⁴ believed that the success rate is almost guaranteed provided the patient is consciously contracting the transposed muscle in conjunction with smiling. However, an interesting phenomenon of trigeminal neo-neurotization may be responsible for several cases reported in the literature in which patients achieved mimetic and more organized facial movement than would be expected following segmental temporalis muscle transfer alone.²⁸ Rubin et al²⁹ reported 27 patients who after temporalis or masseter transfer could smile spontaneously without clenching their teeth. If this phenomenon were more predictable and reproducible, it would be useful in the management of patients with facial paralysis.³⁰

On the basis of the results of this study with a limited number of patients, the orthodromic temporalis transposition through an intraoral approach proved satisfactory. This technique could be applied safely and effectively on a larger number of cases with long-standing facial palsy and may well be tested to augment facial nerves grafting in cases with either recent or old facial palsies.

CONCLUSION

Orthodromic temporalis tendon transfer through an intraoral approach to reanimate the lower face in long-standing facial paralysis cases is a relatively easy procedure to perform. It has distinct advantages compared with other forms of facial reanimation. This procedure takes into account the advantages of the orthodromic transposition in terms of better muscle excursion and power. Thus, it allows for good movement of the corner of the mouth with restoration of the smile, in addition to symmetry at rest. It is performed in a minimally invasive manner and eliminates the facial asymmetry typically produced by antidromic temporalis transfer.

REFERENCES

1. Lexer E, Eden R. Über die chirurgische Behandlung der peripheren Facialis Lahmung. *Beitr Klin Chir* 1911;73:116
2. Viterbo F, de Paula Faleiros HR. Orthodromic transposition of the temporal muscle for facial paralysis: made easy and better. *J Craniofac Surg* 2005;16:306–309
3. May M, Drucker C. Temporalis muscle for facial reanimation. A 13-year experience with 224 procedures. *Arch Otolaryngol Head Neck Surg* 1993;119:378–382

4. Clark JM, Shockley WW. Management and reanimation of the paralyzed face. In: Papel ID, ed. *Facial Plastic and Reconstructive Surgery*. New York: Thieme; 2002:660–685
5. Gillies H. Experiences with fascia lata grafts in the operative treatment of facial paralysis: (Section of Otolaryngology and Section of Laryngology). *Proc R Soc Med* 1934;27:1372–1382
6. Andersen JG. Surgical treatment of lagophthalmos in leprosy by the Gillies temporalis transfer. *Br J Plast Surg* 1961; 14:339–345
7. Rubin LR. *Reanimation of the Paralyzed Face*. St. Louis, MO: CV Mosby; 1977
8. Baker DC, Conley J. Regional muscle transposition for rehabilitation of the paralyzed face. *Clin Plast Surg* 1979; 6:317–331
9. May M. Muscle transposition for facial reanimation. *Facial Plast Surg* 1992;8:115–120
10. McLaughlin CR. Surgical support in permanent facial paralysis. *Plast Reconstr Surg* (1946) 1953;11:302–314
11. Breidahl AF, Morrison WA, Donato RR, Riccio M, Theile DR. A modified surgical technique for temporalis transfer. *Br J Plast Surg* 1996;49:46–51
12. Labbé D, Huault M. Lengthening temporalis myoplasty and lip reanimation. *Plast Reconstr Surg* 2000;105:1289–1297
13. May M. Muscle transposition for facial reanimation. Indications and results. *Arch Otolaryngol* 1984;110:184–189
14. Anderson RG. Facial nerve disorders and surgery. *Select Read Plast Surg* 2001;9:1–39
15. Clark JM, Shockley WW. Management and reanimation of the paralyzed face. In: Papel ID, ed. *Facial Plastic and Reconstructive Surgery*. New York: Thieme; 2002:660–685
16. Freeman BS. Review of long-term results in supportive treatment of facial paralysis. *Plast Reconstr Surg* 1979; 63: 214–218
17. Konior RJ. Facial paralysis reconstruction with Gore-Tex soft-tissue patch. *Arch Otolaryngol Head Neck Surg* 1992; 118:1188–1194
18. Byrne PJ, Kim M, Boahene K, Millar J, Moe K. Temporalis tendon transfer as part of a comprehensive approach to facial reanimation. *Arch Facial Plast Surg* 2007;9:234–241
19. Adams WM. The use of the masseter, temporalis and frontalis muscles in the correction of facial paralysis. *Plast Reconstr Surg* 1946;1:216
20. Owens N. Implantation of fascial strips through the masseter muscle for surgical correction of facial paralysis: a report of 11 cases. *Plast Reconstr Surg* 1947;2:25–36
21. De Castro Correia P, Zani R. Masseter muscle rotation in the treatment of inferior facial paralysis. *Anatomical and clinical observations*. *Plast Reconstr Surg* 1973;52:370–373
22. Duckert LG, Cummings CW. “How I do it” - plastic surgery. Practical suggestions on facial plastic surgery. The temporalis myofascial dynamic sling. *Laryngoscope* 1981;91: 1963–1965
23. Rubin LR. The anatomy of a smile: its importance in the treatment of facial paralysis. *Plast Reconstr Surg* 1974;53: 384–387
24. Paletz JL, Manktelow RT, Chaban R. The shape of a normal smile: implications for facial paralysis reconstruction. *Plast Reconstr Surg* 1994;93:784–789
25. Jobe RP. A technique for lid loading in the management of the lagophthalmos of facial palsy. *Plast Reconstr Surg* 1974;53:29–32
26. Casler JD, Conley J. Simultaneous “dual system” rehabilitation in the treatment of facial paralysis. *Arch Otolaryngol Head Neck Surg* 1990;116:1399–1403
27. Balaji SM. A modified temporalis transfer in facial reanimation. *Int J Oral Maxillofac Surg* 2002;31:584–591
28. Cheney ML, McKenna MJ, Megerian CA, West C, Elahi MM. Trigeminal neo-neurotization of the paralyzed face. *Ann Otol Rhinol Laryngol* 1997;106:733–738
29. Rubin LR, Rubin JP, Simpson RL, Rubin TR. The search for the neurocranial pathways to the fifth nerve nucleus in the reanimation of the paralyzed face. *Plast Reconstr Surg* 1999; 103:1725–1728
30. Dellon AL, Mackinnon SE. Reanimation following facial paralysis by adjacent muscle neurotization: experimental model in the primate. *Microsurgery* 1989;10:251–255