

Histopathology of Enzootic Ataxia in Sika deer (*Cervus nippon* Temminck)

Hiroyasu YOSHIKAWA, Hirokazu SEO, Takashi OYAMADA¹⁾, Toshimi OGASAWARA²⁾, Toshifumi OYAMADA, Takashi YOSHIKAWA, Xubin WEI³⁾, Shueqin WANG³⁾, and Yangxian. LI³⁾

Departments of Veterinary Pathology, ¹⁾Veterinary Parasitology, ²⁾Animal Teaching Hospital, Faculty of Veterinary Medicine and Animal Sciences, Kitasato University, Towada City, Aomori 034, Japan, and ³⁾Department of Veterinary Medicine, Changchun University of Agriculture and Animal Sciences, Changchun, China

(Received 30 January 1996/Accepted 14 May 1996)

ABSTRACT. Thirteen Sika deer (*Cervus nippon* Temminck) showing ataxia on a stock farm in the north eastern district of China were examined histopathologically. The principal pathological changes were spongy vacuolation and myelin deficiency in the white matter of the spinal cord and brain stem, fibrosis and rupture of the elastic lamina of the spinal arterioles, and mesothelial hyperplasia in the spinal arachnoid. Other findings included defective formation of the elastic laminae of the aorta, and the blood vessels in the kidney and lung, hemosiderosis in the spleen and liver, and lymphocyte depletion in the systemic lymph nodes. Copper concentrations were low in the serum and liver. In the white matter of the spinal cord and brain stem, demyelination appeared to coexist with dysmyelination and secondary myelin breakdown. It was inferred that decreased activity of copper containing enzyme induced various lesions. The possible role of copper deficiency in the pathogenesis of the ataxic conditions is discussed. — **KEY WORDS:** copper deficiency, deer, enzootic ataxia, pathology.

J. Vet. Med. Sci. 58(9): 849–854, 1996

Enzootic ataxia in deer has been described in New Zealand [1, 19, 38, 42], Australia [26], Europe [3, 20, 22, 30, 37] and USA [11, 13], but there have been no previous reports of this disease occurring in China. This disease is characterized by ataxia and incoordination of hindquarters, in addition to anemia, retarded growth, depigmentation of hair, reduced reproduction, osteochondrosis, antler anomalies and other symptoms. Histologically, bilateral demyelination of the spinal cord and brain stem is well defined [3, 20, 26, 37, 42]. The syndrome in deer closely resembles swayback in sheep, but there are some differences between deer and sheep: the ataxia in deer occurs in young adult and mature, whereas newborn or young in sheep [4, 5, 17, 34]. Etiologically this disease has been considered to be associated with copper deficiency [9, 39], but the pathogenesis of this disease is still obscure. This paper deals with histopathology of enzootic ataxia in Sika deer (*Cervus nippon* Temminck), encountered on a stock farm in the north eastern district of China.

MATERIALS AND METHODS

Sika deer: The animals were obtained from a ranch with about 1,500 deer, on which enzootic ataxia had occurred continuously since 1985. The clinical signs of the disease, which affected approximately 10% of all animals, were progressive hind limb weakness, posterior wobbling, and/or unsteady gait. In severe cases, growth was retarded, and depigmentation of hair and alopecia, especially around eyes, were observed. In some cases deformity of the extremities and bone fractures were present. The disease was judged to be due to copper deficiency from the following chemical analyses of the sera and livers of affected deer and healthy deer from a non-affected ranch. The analyses were made

by the atomic absorption spectrometry. Serum copper in affected males was 5.88 ± 0.19 mmol/l, in affected females 5.56 ± 0.22 mmol/l, in normal males 16.49 ± 0.69 , and normal females 7.55 ± 0.19 mmol/l. Serum ceruloplasmin in affected males was 34.00 ± 14.04 U/l, in affected females 20.98 ± 7.59 U/l, in normal males 184.52 ± 21.09 U/l, and in normal females 33.20 ± 0.19 U/l. Liver copper in affected males was 28.12 ± 6.81 mg/kg d.w., in affected females 23.61 ± 4.63 mg/kg d.w., in normal males 65.87 ± 7.93 mg/kg d.w., and in normal females 59.66 ± 10.74 mg/kg d.w.

Thirteen affected deer (8 males aged 4–9 years and 5 females aged 4–6 years) that showed ataxia and incoordination of hindquarters (Fig. 1) were selected at random and necropsied, and the samples were examined chemically and histopathologically.

Copper assay: Three of the affected animals (Case Nos. 8, 11 and 13) were measured for copper contents in the sera and livers by the atomic absorption spectrometry (Model AA-1100: Varian Techtron Co.) [36].

Pathological examination: The brain, spinal cord and selected major visceral organs were fixed in Lillie's 10% buffered formalin immediately after necropsy and were embedded in paraffin wax after conventional dehydration schedule. Sections were cut at 4 μ m and stained with hematoxylin and eosin (HE). Selected sections were stained with azan, elastica van Gieson (EVG), luxol fast blue (LFB), or Bodian's stain. Specimens for electron microscopy were prefixed in 1.5% paraformaldehyde and 0.5% glutaraldehyde in phosphate buffer (pH 7.4), postfixed with 1% osmic acid and embedded in Epok 812 resin by means of standard procedure. Ultra-thin sections were cut and double-stained with 1% uranyl acetate and Reynold's lead citrate, and were observed with Hitachi H-7000 electron microscope.




Fig. 1. Affected female Sika deer (*Cervus nippon* Temminck) shows incordination such as weakness of hindquarters, posterior wobbling and unsteady gait.

RESULTS

Copper assay: Atomic absorption spectrometry revealed a low concentration of copper, 6.03 (Case No. 8), 6.26 (Case No. 11), and 5.19 (Case No. 13) mmol/l in the sera and 30.18 (Case No. 8), 33.60 (Case No. 11), and 35.41 (Case No. 13) mg/kg d.w. in the livers.

Pathological examination: There were no consistent gross lesions. Histologically, the lesions occurred in the spinal cord and brain stem. The following characteristic lesions were recognized: Spongy vacuolation and demyelination in the white matter of the spinal cord and brain stem, thickening of collagenous fibers and rupture of elastic fibers of branches of the spinal arteries, and mesothelial hyperplasia in the spinal arachnoid.

A spongy appearance of the white matter was apparent at the same degree throughout the whole length of the cord. The lesions were most severe in the lateral funiculi beneath the dorsal spinal nerve root and in the ventral funiculi adjacent to the ventral median fissure (Fig. 2). Although the degree and severity differed from case to case, lesions were always bilateral and symmetrical. The peripheral white matter tracts were severely and diffusely affected. In affected areas, there was a distinct deficit of stainable myelin sheaths and appeared as pale, ill-defined areas in HE sections (Fig. 3), and those myelin sheaths were more clearly demonstrated in LFB sections. Numerous dilated spaces in some areas gave the tissue a polycystic appearance. There was no evidence of inflammation. Similar lesions were observed in the pyramidal tract of the mid brain, pons and medulla oblongata. Almost all these dilated myelin sheaths

contained axons, but in large vacuoles swollen axons were rarely observed (Fig. 3) and some sheaths contained macrophages. In longitudinal sections stained with Bodian's stain, axons retained their original shape, but some axons were fragmented or swollen (Fig. 4). Spheroids were often observed in large vacuoles. Increased numbers of fibrous astroglia and fibrosis were relatively common around arterioles in the spinal white matter. Electron microscopically, macrophages that attached to the degenerated myelin sheaths were observed in lesions, and they contained lipid droplets in their cytoplasm (Fig. 5). The degenerated myelin sheaths lost their lamellar structures, and a number of glial filaments were present around the periphery of the lesions.

In the subarachnoid cavity of the spinal cord, increased collagen fibers were observed, and many arteries and arterioles in the white matter were fibrotic and resulted in stenosis (Fig. 6). In addition, internal elastic laminae of spinal arteries were fragmented and discontinuous (Fig. 7). Proliferation of mesothelial cells, sometimes accompanied by various sized nodules containing amorphous material, was recognized in the arachnoid membrane (Fig. 8). These materials were positive to PAS stain, and consisted of both collagen which was positive on azan stain and elastic fiber which stained black with EVG stain. In the gray matter of the central nervous system (CNS), the neuronal cells were not degenerated, and no significant lesions were observed in the cerebrum and cerebellum.

Defective formation of the elastic laminae was observed in the aorta and blood vessels of the kidney and lung. The elastic laminae of the arterial walls were discontinuous, and intimal fibrosis and aneurysm were also frequently present. As to the other organs examined, in almost every case, hemosiderin-laden macrophages were present in the spleen and liver, and these pigments were also present within hepatocytes. In the lymphatic tissue, atrophic follicles, decreased numbers of lymphocytes and amyloid deposition were often observed.

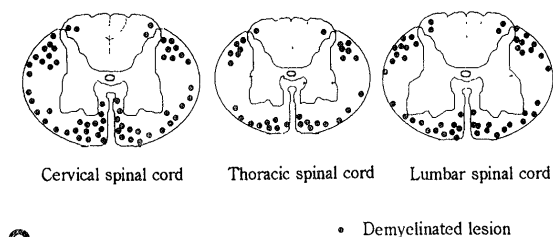
DISCUSSION

The histopathology of affected deer found in the north eastern district in China (Jilin province) was similar to that had been described in deer with enzootic ataxia and in sheep with swayback [4, 5, 17, 34]. There is little doubt about that the present deer suffered from copper deficiency clinically and histologically. The finding of decreased serum copper supports a possible relationship of demyelination with copper deficiency.

The pathogenesis of myelin deficiency and disintegration may be explained by two events, one is decreased activity of copper containing enzyme, and another is circulatory disturbance of the blood and cerebrospinal fluid. Spongy vacuolation of the spinal white matter and brain stem may have resulted from myelin deficiency recognizable by LFB stain. The pathogenesis of demyelination associated with copper deficiency is still obscure, but the lesion of myelin

sheath has been thought to be linked with decreased activity of copper containing enzyme, cytochrome oxidase [8, 9, 14, 15, 39]. In domestic animals some investigators have suggested that demyelination may be due to myelin hypoplasia (primary demyelination), since lowered cytochrome oxidase activity led to depressed synthesis of phospholipid, which is the major component of myelin [25, 27, 35, 38]. The other investigators suggested that decreased cytochrome oxidase in neurons led to chromatolytic change or degeneration of nerve cells, resulting in axonal degeneration and demyelination (secondary demyelination) [6, 34, 43]. In our study there was no evidence of neuronal degeneration in CNS, and the majority of axons in demyelinated nerve fibers remained intact. If the lesions in the spinal cord were secondary degeneration occurred before or immediately after the birth of deer, axonal changes might be more severe. So, we believe that the axonal changes followed demyelination, and that the myelin deficiency may have resulted from hypomyelination.

Demyelination in the spinal white matter tended to



2

distribute more frequently in the lateral funiculus and its marginal region, particularly close to the anterior and posterior roots of the spinal nerves. The location of lesions in the spinal cord seemed to be related to distribution of the spinal vessels. The increased number of astroglia and fibrosis around vessels and stenosis of arterioles seemed to be progressive and persistent, and led to demyelination, as a

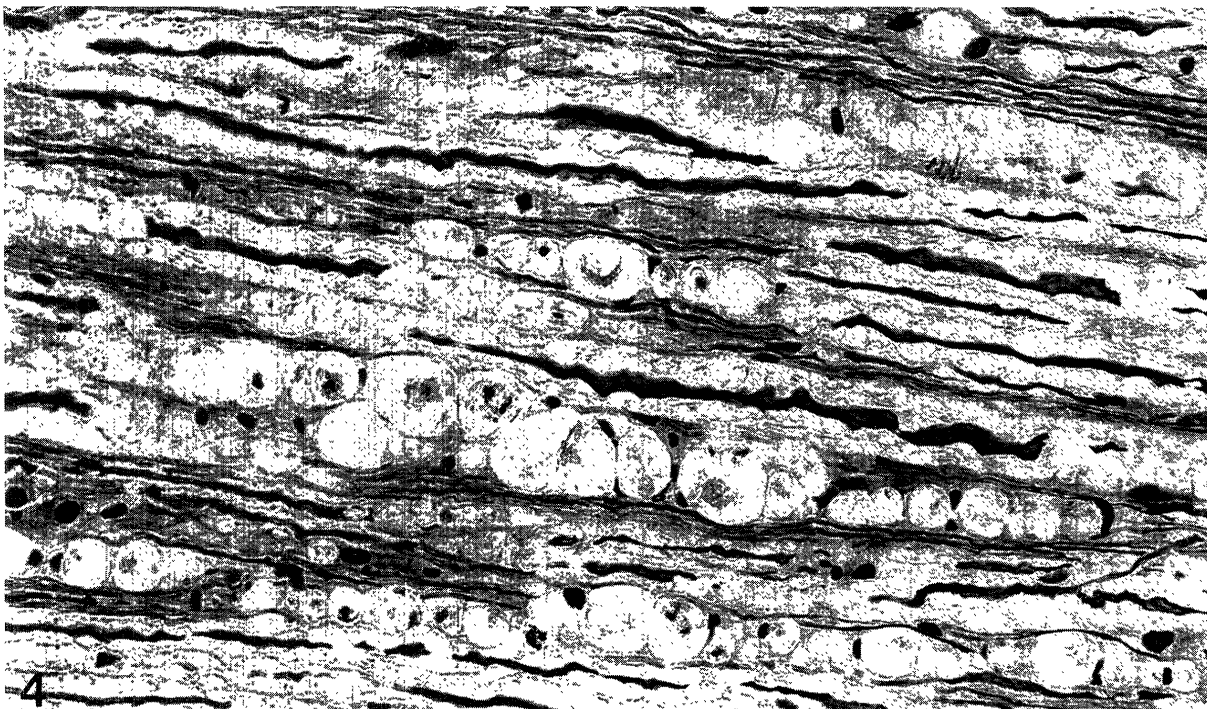
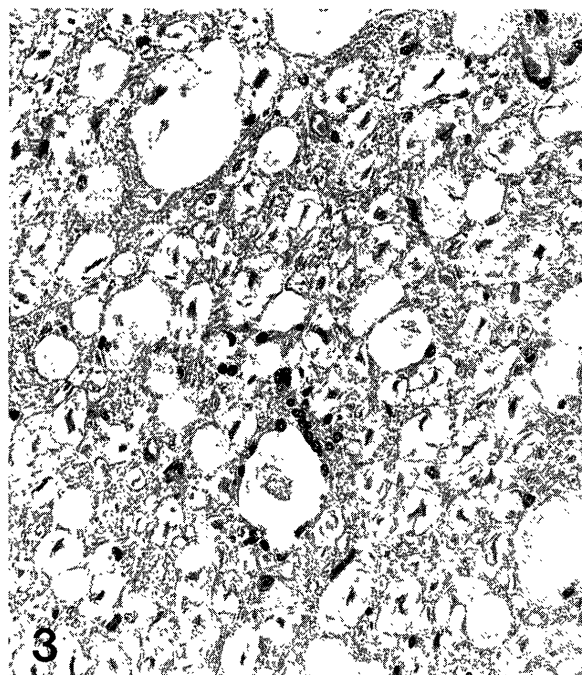


Fig. 2. Schematic distribution of demyelinated lesions in the spinal cord.

Fig. 3. Cervical intumescence of the spinal cord. Transverse section of the ventral funiculus of the cervical spinal cord showing a distinct deficit of stainable myelin with numerous vacuoles containing axons, while some axons are degenerative. HE stain. $\times 320$.

Fig. 4. Cervical intumescence of the spinal cord. Longitudinal section of the ventral funiculus of the cervical spinal cord showing ballooning of myelin sheaths, breakup and swelling of axons and infiltration by macrophages. Bodian's stain. $\times 400$.

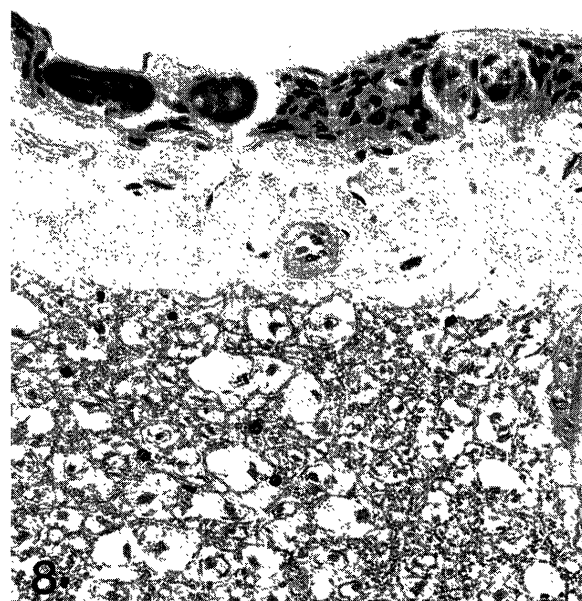
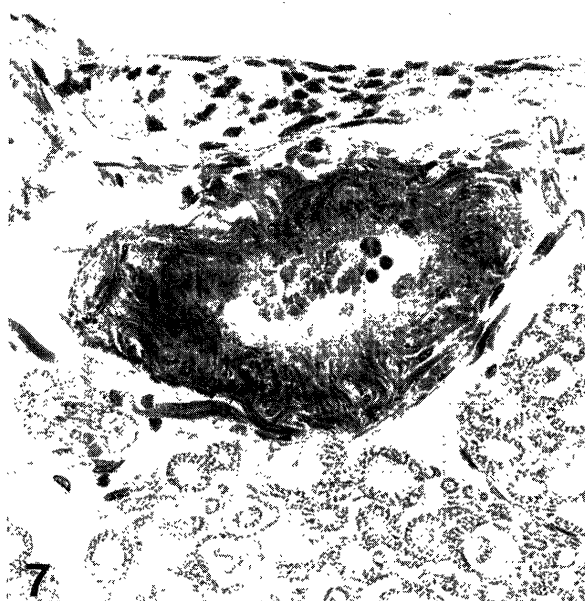
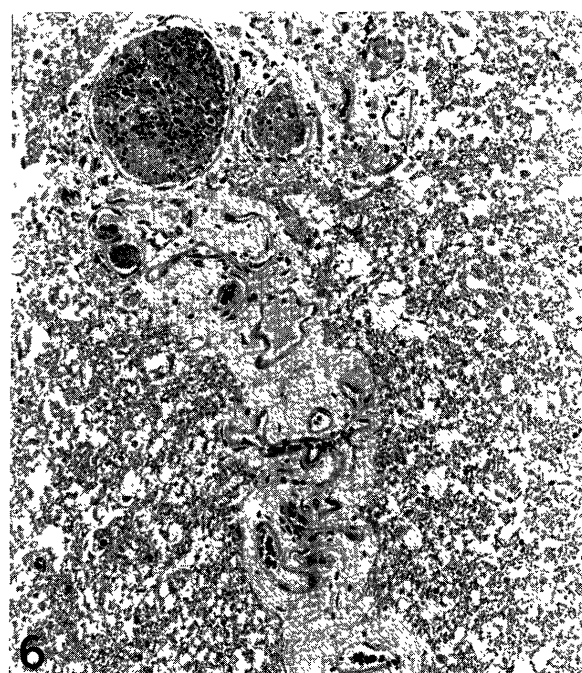
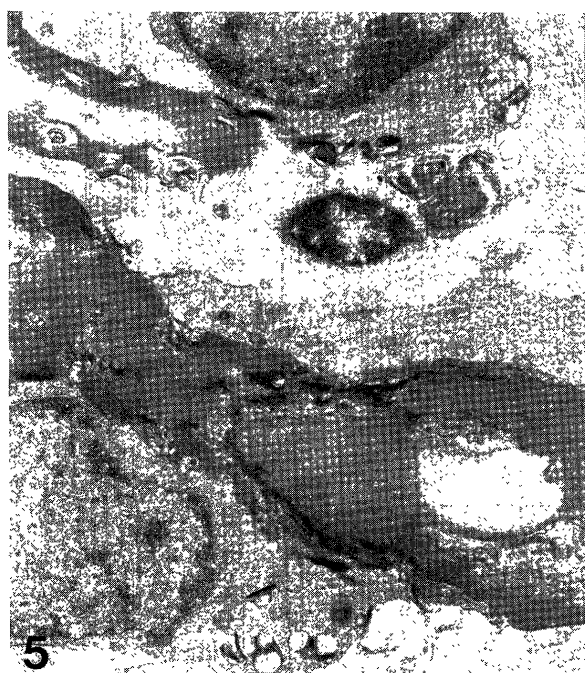

Fig. 5. Electron micrograph of the ventral funiculus of the cervical spinal cord. Macrophages attach to degenerated myelin and contain lipid droplets in the cytoplasm. $\times 6,000$.

Fig. 6. Thoracic spinal cord. Transverse section of the ventral funiculus showing periarterial fibrosis and stenosis of the arterioles in the white matter. HE stain. $\times 175$.

Fig. 7. Spinal artery in the cervical intumescence shows fibrosis and fragmentation of internal elastic lamina. Elastic van Gieson stain. $\times 400$.

Fig. 8. Thickened arachnoid shows hyperplasia of mesothelial cells and formation of nodules containing amorphous materials. HE stain. $\times 320$.

result of circulatory disturbance of blood. There were a few reports on demyelination induced by vascular lesion in CNS [23]. In Menkes kinky hair disease, which is a genetic copper deficiency syndrome of man, circulatory disturbance

of CNS was observed [40]. Vascular changes of the spinal cord in our cases may be one of the causative factors for demyelination. The changes of elastic laminae were also recognized in the aorta and in the blood vessels in the kidney

and lung. Copper deficiency causes swelling, fragmentation and disappearance of the elastic laminae of the aorta and arteries in various animals [9, 39]. It has been thought that the changes were caused by decreased synthesis of elastin and collagen due to the depressed activity of copper containing enzymes, lysyl oxidase [9, 27, 39]. From these observations on our cases, the coexistence of dysmyelination, demyelination, and myelin breakdown secondary to neural destruction caused by circulatory disturbances could not be ruled out.

The proliferation of mesothelial cells including various sized nodules and fibrosis in the arachnoids may suggest the prolonged disturbance of cerebrospinal fluid circulation related to insufficiency of the spinal vessels. The nodules may be degenerated arachnoid granulations.

Pathological changes of the spinal cord and brain stem in the present cases appeared distinctive to enzootic ataxia and suggest the pathogenesis of ataxia. The clinical findings such as loss of pigmentation and alopecia around eyes may have been caused by the inhibition of copper containing enzyme, tyrosinase, required for the production of melanin [9, 39].

In the major visceral organs, hemosiderin deposition was observed in the spleen and liver. The change may have resulted from defective erythrocytes and disturbed iron-protein metabolism brought about by depression of ceruloplasmin [9]. It is known that copper deficiency diminishes an immune response in mice, although the mechanism was unclear [28, 29]. Lymphopenia and amyloid deposition in the present cases may be related to the impaired immune response.

Concerning the etiology of ataxia, various factors have been described, such as parasite infestation, virus infection and plant poisoning, etc. [16, 20, 21, 24], but such factors appeared not exist in our cases. From this study we deduced that the present disease might be related to decreased activity of copper containing enzyme. However, the exact pathogenesis remains to be solved by further studies.

Enzootic ataxia caused by copper deficiency in the other species of animals has been reported by many authors [2, 6, 18, 27, 32, 33, 41, 43]. It has been considered that the regional environment, genetic predisposition, different breeds and individual specificity, and degree or persistent period of copper deficiency affected the onset of symptom [7, 10, 12, 31, 39]. It has been reported that wapiti (*Cervus canadensis*) and wapiti × red (*Cervus elaphus*) deer hybrids appeared to be more prone to copper deficiency [20]. As to an influential factor it has been recognized that a period of myelin synthesis and, requirement and excretion of copper were different between various animals [39]. Based on the results shown here, we suppose that copper deficiency plays an important role in the development of the enzootic ataxia in deer.

ACKNOWLEDGMENT. This study was supported in part by Grant-in-Aid for the International Scientific Research Program No. 04045047 from the Ministry of Education,

Science and Culture of Japan.

REFERENCES

1. Audigé, L., Wilson, P. R., Morris, R. S., and Davidson, G. W. 1995. Osteochondrosis, skeletal abnormalities and enzootic ataxia associated with copper deficiency in a farmed red deer (*Cervus elaphus*) herd. *N. Z. Vet. J.* 43: 70–76.
2. Banton, M. I., Lozano-Alarcon, F., Nicholson, S. S., Jowett, P. L., Fletcher, J., and Olcott, B. M. 1990. Enzootic ataxia in Louisiana goat kids. *J. Vet. Diagn. Invest.* 2: 70–73.
3. Barlow, R. M., Butler, E. J., and Purves, D. 1964. An ataxic condition in red deer (*Cervus elaphus*). *J. Comp. Pathol.* 74: 519–529.
4. Barlow, R. M., Purves, D., Butler, E. J., and Macintyre, I. J. 1960. Swayback in south-east Scotland II. Clinical, pathological and biochemical aspects. *J. Comp. Pathol.* 70: 411–428.
5. Cancilla, P. A. and Barlow, R. M. 1968. Structural changes of the central nervous system in swayback (enzootic ataxia) of lambs. IV. Electron microscopy of the white matter of the spinal cord. *Acta Neuropathol.* 11: 294–300.
6. Cordy, D. R. and Knight, H. D. 1978. California goat with a disease resembling enzootic ataxia or swayback. *Vet. Pathol.* 15: 179–185.
7. Cowie, R. S. 1976. Copper levels in red deer. *Vet. Rec.* 98: 434.
8. Evans, G. W. 1973. Copper homeostasis in the mammalian system. *Physiol. Rev.* 53: 535–570.
9. Fell, B. F. 1987. The pathology of copper deficiency in animals. pp. 1–28. In: *Copper in Animals and Man* (Howell, J. McC. and Gawthorne, J. M. eds.), CRC Press, Boca Raton, FL, U.S.A.
10. Fields, M. and Lewis, C. 1987. Genetic factors in copper deficiency. *Nutr. Rev.* 45: 223–224.
11. Flynn, A., Franzmann, A. W., Arneson, P. D., and Oldemeyer, J. L. 1977. Indications of copper deficiency in a subpopulation of Alaskan moose. *J. Nutr.* 107: 1182–1189.
12. Freudenberger, D. O., Familton, A. S., and Sykes, A. R. 1987. Comparative aspect of copper metabolism in silage-fed sheep and deer (*Cervus elaphus*). *J. Agric. Sci.* 108: 1–7.
13. Gogan, P. J., Jessup, D. A., and Barrett, R. H. 1988. Antler anomalies in tule elk. *J. Wildl. Dis.* 24: 656–662.
14. Gooneratne, S. R., Buckley, W. T., and Christensen, D. A. 1989. Review of copper deficiency and metabolism in ruminants. *Can. J. Anim. Sci.* 69: 819–845.
15. Hartmann, H. A. and Evenson, M. A. 1992. Deficiency of copper can cause neuronal degeneration. *Med. Hypotheses* 38: 75–85.
16. Hooper, P. T., Best, S. M., and Campbell, A. 1974. Axonal dystrophy in the spinal cords of cattle consuming the cycad palm, *Cycas media*. *Aust. Vet. J.* 50: 146–149.
17. Howell, J. McC., Davison, A. N., and Oxberry, J. 1969. Observation on the lesions in the white matter of the spinal cord of swayback sheep. *Acta Neuropathol.* 12: 33–41.
18. Lofstedt, J., Jakowski, R., and Sharko, P. 1988. Ataxia, arthritis, and encephalitis in a goat herd. *J. Am. Vet. Med. Assoc.* 193: 1295–1298.
19. Mackintosh, C. G. 1992. Observation on the relative susceptibility to disease of different species of deer farmed in New Zealand. pp. 113–119. In: *The Biology of Deer* (Brown, R. D. ed.), Springer-Verlag, New York, U.S.A.
20. McDiarmid, A. 1975. Some disorders of wild deer in the

- United Kingdom. *Vet. Rec.* 97: 6–9.
21. McKenzie, R. A. and McMicking, L. I. 1977. Ataxia and urinary incontinence in cattle grazing sorghum. *Aust. Vet. J.* 53: 496–497.
 22. McTaggart, H. S., Low, V. P. W., Barden, P. J., and Gellatly, J. B. M. 1981. Copper status of red deer on the island of Rhum. *Vet. Rec.* 22: 155–157.
 23. Nyström, S. H. M. 1968. Studies of the effect of experimental hypocupremia on the rabbit circulatory system, with special reference to vessels of the neck and the base of the brain. *Acta Neuropathol.* 10: 209–217.
 24. Palmer, A. C. and Woodman, C. B. 1975. Derengue, a paralysis of cattle in El Salvador ascribed to ingestion of Melochia pyramidata. *Vet. Rec.* 21: 547–548.
 25. Patterson, D. S. P., Foulkes, J. A., Sweasey, D., Glancy, E. M., and Terlecki, S. 1974. A neurochemical study of field cases of the delayed spinal form of swayback (enzootic ataxia) in lambs. *J. Neurochem.* 23: 1245–1253.
 26. Peet, R. L. and Hepworth, K. 1993. Enzootic ataxia in red deer, *Cervus elaphus*. *Aust. Vet. J.* 70: 395–396.
 27. Pletcher, J. M. and Banting, L. F. 1983. Copper deficiency in piglets characterized by spongy myelopathy and degenerative lesions in the great blood vessels. *J. S. Afr. Vet. Assoc.* 54: 43–46.
 28. Prohaska, J. R., Downing, S. W., and Lukasewycz, O. A. 1983. Chronic dietary copper deficiency alters biochemical and morphological properties of mouse lymphoid tissues. *J. Nutr.* 113: 1583–1590.
 29. Prohaska, J. R. and Lukasewycz, O. A. 1981. Copper deficiency suppresses the immune response of mice. *Science* 213: 559–561.
 30. Reh binder, C. and Petersson, L. 1994. Cerebellar abiotrophy in a moose (*Alces alces* L.) related to copper deficiency. *Acta Vet. Scand.* 35: 103–106.
 31. Reid, T. C., McAllum, H. J. F., and Johnstone, P. D. 1980. Liver copper concentration in red deer (*Cervus elaphus*) and wapiti (*C canadensis*) in New Zealand. *Res. Vet. Sci.* 28: 261–262.
 32. Richards, R. B. and Edwards, J. R. 1986. A progressive spinal myelinopathy in beef cattle. *Vet. Pathol.* 23: 35–41.
 33. Sanders, D. E. and Koestner, A. 1980. Bovine neonatal ataxia associated with hypocupremia in pregnant cows. *J. Am. Vet. Med. Assoc.* 176: 728–730.
 34. Smith, R. M., Fraser, F. J., and Robertson, J. S. 1978. Enzootic ataxia in lambs: absence of detectable neuronal pathology in foetal and neonatal spinal cord. *J. Comp. Pathol.* 88: 401–408.
 35. Smith, R. M., Osborne-White, W. S., and O'Dell, B. L. 1976. Cytochromes in brain mitochondria from lambs with enzootic ataxia. *J. Neurochem.* 26: 1145–1148.
 36. Stevens, B. J. 1972. Biological application of carbon rod atomizer in atomic absorption spectroscopy. 2. Determination of copper in small samples of tissue. *Clin. Chem.* 18: 1379–1384.
 37. Terlecki, S., Done, J. T., and Clegg, F. G. 1964. Enzootic ataxia of Red deer. *Br. Vet. J.* 120: 311–321.
 38. Thompson, K. G., Audigé, L., Arthur, D. G., Julian, A. F., Orr, M. B., McSporran, K. D., and Wilson, P. R. 1994. Osteochondrosis associated with copper deficiency in young farmed red deer and wapiti × red deer hybrids. *N. Z. Vet. J.* 42: 137–143.
 39. Underwood, E. J. 1971. Copper. pp. 57–115. In: Trace Elements in Human and Animal Nutrition, 3rd ed., Academic Press, New York, U.S.A.
 40. Uno, H. and Arya, S. 1987. Neuronal and vascular disorders of the brain and spinal cord in Menkes kinky hair disease. *Am.J. Med. Genet. (Suppl.)* 3: 367–377.
 41. Wikse, S. E., Herd, D., Field, R., and Holland, P. 1992. Diagnosis of copper deficiency in cattle. *J. Am. Vet. Med. Assoc.* 200: 1625–1629.
 42. Wilson, P. R., Orr, M. B., and Key, E. L. 1979. Enzootic ataxia in red deer. *N. Z. Vet. J.* 27: 252–254.
 43. Wouda, W., Borst, G. H., and Gruys, E. 1986. Delayed swayback in goat kids, a study of 23 cases. *Vet. Q.* 8: 45–56.