

Barium Peritonitis in Small Animals

Jae Jin KO^{1)*} and F. A. (Tony) MANN¹⁾

¹⁾Department of Veterinary Medicine and Surgery, University of Missouri-Columbia Veterinary Medical Teaching Hospital, Columbia, MO 65201, U.S.A.

(Received 30 April 2013/Accepted 29 December 2013/Published online in J-STAGE 16 January 2014)

ABSTRACT. Barium peritonitis is extremely rare, but is difficult to treat and may be life-threatening. Barium suspension leakage from the gastrointestinal tract into the abdominal cavity has a time-dependent and synergistically deleterious effect in patients who have generalized bacterial peritonitis. The severity of barium peritonitis is dependent on the quantity of barium in the abdominal cavity. Barium sulfate leakage results in hypovolemia and hypoproteinemia by worsening the exudation of extracellular fluid and albumin. Abdominal fluid analysis is a useful and efficient method to diagnose barium peritonitis. Serial radiographs may not be a reliable or timely diagnostic technique. Initial aggressive fluid resuscitation and empirical broad-spectrum antibiotic treatment should be instituted promptly, followed quickly by celiotomy. During exploratory surgical intervention, copious irrigation and direct wiping with gauze are employed to remove as much barium as possible. Omentectomy should be considered when needed to expedite barium removal. Despite aggressive medical and surgical treatments, postoperative prognosis is guarded to poor due to complications, such as acute vascular shock, sepsis, diffuse peritonitis, hypoproteinemia, electrolyte imbalance, cardiac arrest, small bowel obstruction related to progression of granulomas and adhesions in the abdominal cavity. Therefore, intensive postoperative monitoring and prompt intervention are necessary to maximize chances for a positive outcome. For those that do survive, small bowel obstruction is a potential consequence due to progression of abdominal adhesions.

KEY WORDS: acute abdomen, barium contrast study, barium peritonitis, exploratory celiotomy, small animal.

doi: 10.1292/jvms.13-0220; *J. Vet. Med. Sci.* 76(5): 621–628, 2014

In the field of small animal practice, a barium sulfate contrast study has long been regarded as an essential tool for diagnosis of digestive tract diseases [34, 65]. A commonly accepted contraindication for barium administration is the suspicion of gastrointestinal (GI) perforation, whereby barium would exacerbate peritonitis. Despite barium's common use for a contrast study in digestive tracts of small animals, few barium peritonitis cases have been described in the veterinary literature. In the English veterinary literature, there are three case reports of barium peritonitis associated with GI perforation. The causes of barium peritonitis in these case reports included a foreign body, the use of nonsteroidal antiinflammatory drugs and suspicious pre-existing jejunal perforation with T-cell lymphoma [17, 24, 54]. Much of the knowledge related to barium peritonitis is derived from human medicine and research animal models [1, 2, 37, 63, 68], but descriptions of barium peritonitis and clinical complications are found in veterinary textbooks [34, 65]. Barium suspension leakage from the GI tract has a time-dependent and synergistically deleterious effect in patients with generalized secondary septic peritonitis [27]. Accidental introduction of barium sulfate suspension into the abdominal cavity causes a severe peritonitis with high morbidity and mortality [1, 66]. The severity of barium peritonitis is dependent on

the quantity of barium that leaks into the abdominal cavity [66]. Prompt diagnosis and urgent treatment are essential for barium peritonitis cases to prevent life-threatening complications, such as hypovolemia, hypoalbuminemia, hypoproteinemia, worsening peritonitis, abdominal adhesions and granulomas [1, 27, 66].

PATHOPHYSIOLOGY

Barium sulfate complicates bacterial peritonitis by worsening the exudation of extracellular fluid and albumin resulting in hypovolemia and hypoproteinemia [1, 27, 66]. Free barium sulfate in the abdominal cavity aggregates as nodules on the serosal surface of the abdominal wall, peritoneum, intestine and other visceral organs. Partial or complete phagocytosis of barium sulfate aggregates occurs, depending on the quantity of barium spilled. These barium sulfate aggregates incite fibroblastic proliferation and vascularization on the periphery of resultant nodules. Fibroplasia on the intestinal serosa results in fibrous adhesion to adjacent bowel or contiguous organs. Extensive adhesion leads to fibroblastic encapsulation [68]. A study using a canine model reported that after irrigation to remove barium from the abdominal cavity, residual barium mixed with GI contents remained in the omentum and mesentery of the small intestine [66]. Within several hours, the viscera clump together in fibrinous exudates, and barium sulfate becomes encapsulated within firm and fibrinous adhesions. Marked leukocytic infiltration was noted in a thin fibrin membrane 2 hr after intraabdominal injection of barium [66]. These granulomas that form in response to barium sulfate eventually trap intestinal contents and bacteria [13]. Eventually, the spillage

*CORRESPONDENCE TO: Ko, J. J., VIP Animal Hospital, 147, Dong-somun-dong 6-ga, Seongbuk-gu, Seoul 136-036, South Korea. e-mail: jaejin0419@gmail.com

©2014 The Japanese Society of Veterinary Science

This is an open-access article distributed under the terms of the Creative Commons Attribution Non-Commercial No Derivatives (by-nc-nd) License <<http://creativecommons.org/licenses/by-nc-nd/3.0/>>.

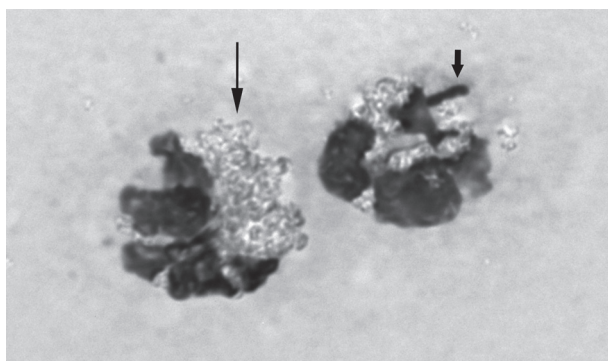


Fig. 1. Cytologic examination of abdominal fluid in canine barium peritonitis. Cytologic examination of abdominal fluid from the dog in this case reveals a neutrophil containing an intracellular bacterium (short arrow) and refractile granules of barium sulfate (long arrow). Barium sulfate granules are also noted in the background (Wright's-Giemsa; 100X). (Reprinted with permission from Mark D. Dunbar *et al.*: Dunbar, M. and Alleman, A. 2009. A challenging case: Abdominal effusion in a dog. *Veterinary Medicine*. **104**: 244-247.)

of barium in conjunction with GI perforation causes severe adverse side effects, such as acute vascular shock, cardiac arrest and fibrinous adhesions [10, 25, 26, 31, 49, 59]. During surgical intervention for barium removal, edema and congestion of the abdominal surfaces have been noted [49]. In experimental research in rabbits, barium sulfate suspension injections caused severe secondary diffuse hemorrhagic peritonitis with numerous adhesions and granulomas in the abdominal cavity [59].

CLINICAL SIGNS

Clinical signs of barium peritonitis may include pain on abdominal palpation, vomiting, anorexia, lethargy, hypotension, tachypnea and abdominal distension [46]. In a dog with barium peritonitis associated with a perforating foreign body, clinical signs included normal vital signs, lethargy, markedly tense abdomen, palpable abdominal fluid and abdominal pain [17].

DIAGNOSTIC TESTS

After initial diagnostics, such as complete blood count, blood chemistries, electrolytes and urinalysis, abdominal fluid is obtained by abdominocentesis or diagnostic peritoneal lavage. The abdominal fluid sample should be evaluated for color, packed cell volume (PCV), white blood cell count (WBC), cytologic features and, in selected cases, bacterial culture and susceptibility. Abdominal fluid analysis (e.g., abdominocentesis or diagnostic peritoneal lavage) will help establish a diagnosis of peritonitis and the urgent need for exploratory celiotomy [46, 52, 53]. If antibiotic therapy is to be initiated before surgical samples can be obtained, aerobic and anaerobic bacterial cultures are appropriate. However, the best bacteriologic sample is inflammatory tissue obtained

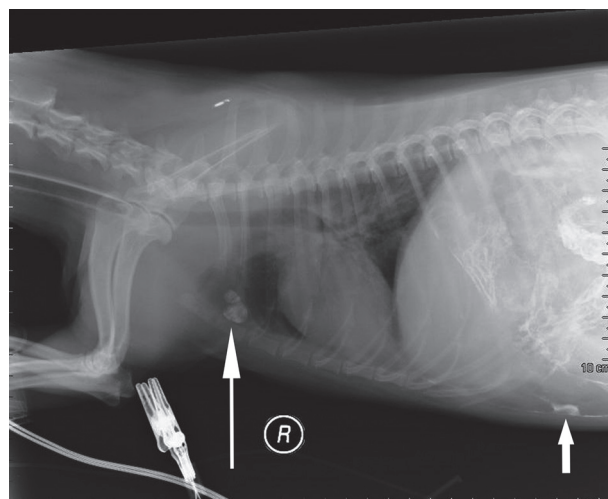


Fig. 2. Radiographic finding in canine barium peritonitis. A right lateral thoracic radiograph of a dog reveals free contrast medium in the abdomen (short arrow) and contrast uptake in a sternal lymph node (long arrow). (Reprinted with permission from Mark D. Dunbar *et al.*: Dunbar, M. and Alleman, A. 2009. A challenging case: Abdominal effusion in a dog. *Veterinary Medicine*. **104**: 244-247.)

intraoperatively; therefore, abdominal fluid is rarely cultured [46]. Factors used to assess the severity of peritonitis include volume of effusion, character of effusion (e.g., opacity, color, odor), presence of gross contamination (fecal contents, food, and hair), serosal changes of abdominal organs (erythema and encapsulation with fibrinous adhesions), distribution of contamination and extent of peritonitis (localized or generalized) [3]. In addition, a minimum database should include blood gas analysis, serum lactate measurement, coagulation panel (e.g., prothrombin time and partial thromboplastin time) and radiographic examination of the abdomen. The minimum database is similar to the diagnostic methods for acute abdomen [15, 46].

Neutrophils containing intracellular bacteria and refractile granules of barium sulfate were noted in abdominal fluid analysis of two reported cases [17, 54] (Fig. 1). Hypocalcemia has been attributed to the low albumin concentration. Difference of glucose and lactate concentrations between serum and abdominal fluid is expected to be within the criteria of septic peritonitis [17]. On analysis, the abdominal fluid may be similar to extracellular fluid in electrolyte and protein content [66].

Abdominal radiography can reveal barium sulfate dispersion in the abdominal cavity and poor serosal detail. The spillage of barium tends to accumulate in the cranial abdomen around most of the small intestine and omentum [17]. However, serial radiographic findings may not be a useful or efficient diagnostic technique, as barium peritonitis could not be identified in a timely manner in three clinical cases [17, 24, 54]. If GI tract perforation is suspected in an acute abdomen case, a contrast barium study should be avoided [46] (Figs. 2 and 3). To avoid the complications of intra-abdominal barium, amidotrizoate sodium meglumine or io-

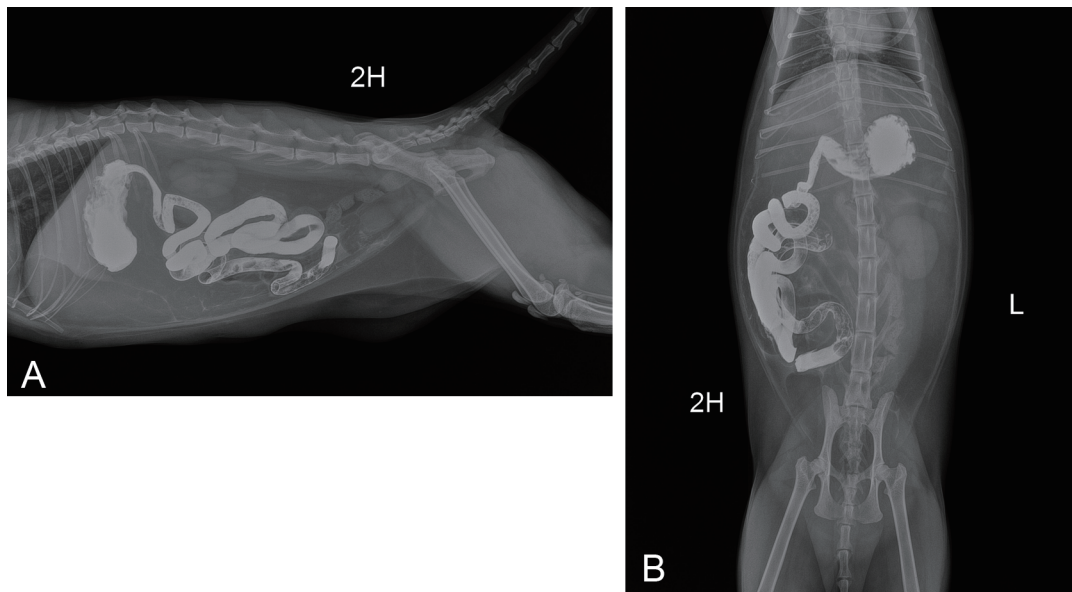


Fig. 3. Radiographic finding in feline barium peritonitis. Leakage of barium contrast medium is revealed in a feline abdominal cavity 2 hr after initiation of the contrast study.

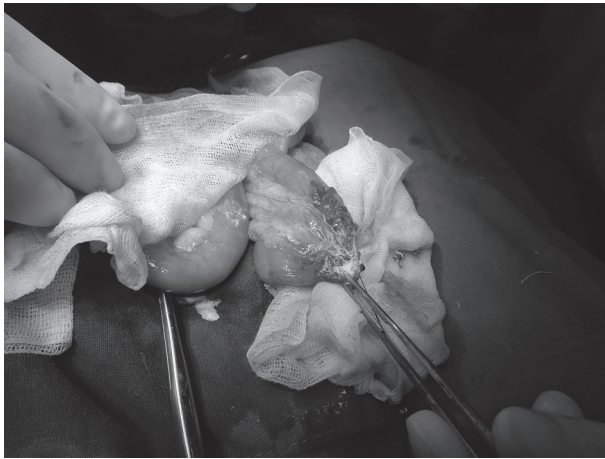


Fig. 4. Intraoperative surgery in feline barium peritonitis. Exploratory celiotomy was performed immediately after definitive radiographic diagnosis of intra-abdominal barium in this cat. Leakage of barium contrast medium was observed in the abdominal cavity and is noted on the mesentery and intestinal serosa.

hexol can be used as alternative oral contrast media [65]. To avoid leakage of contrast agents altogether, abdominal fluid analysis may be used to determine, if there is gastrointestinal leakage. Abdominal ultrasound can aid in the detection of abdominal fluid and acquisition of fluid for analysis [7]. In human cases, abdominal computed tomography allows accurate depiction of the extent of barium extravasation that is not appreciated on plain radiographs [22, 45, 61].

MEDICAL AND SURGICAL TREATMENTS

Treatment of barium peritonitis parallels that of septic peritonitis. Once barium peritonitis has been diagnosed, pre-surgical stabilization includes aggressive intravenous fluid therapy, broad-spectrum antibiotics, pain management and oxygen supplementation as initial treatments. Early aggressive fluid therapy in barium peritonitis should be considered as the most important treatment option to decrease the risk of mortality [49, 66]. Hypovolemic shock and metabolic changes should be corrected by volume replacement fluid therapy using isotonic crystalloid fluids. However, if the patient is hypoproteinemic or hypoalbuminemic, colloids can be helpful to prevent and correct decreased oncotic pressure. Initially, empirical broad-spectrum antimicrobials should be administered as soon as possible. Generally recommended antibiotics in septic peritonitis include combinations of β -lactam and an aminoglycoside or a fluoroquinolone until bacterial culture and susceptibility testing are completed. Metronidazole as an additional antibiotic with enhanced antianaerobic activity can also be used while awaiting these tests [3, 4, 6, 21, 41].

After stabilizing the patient, exploratory celiotomy should be performed as soon as possible. Intraoperatively, abdominal fluid contaminated with barium sulfate suspension, leakage of GI contents and bacteria should be removed as thoroughly as possible (Fig. 4). A sample of inflammatory tissue should be obtained for bacterial culture and antibiotic susceptibility testing. Resection and anastomosis of the affected regions in the GI tract should be performed. After resection and anastomosis, the integrity of the anastomosis site may be evaluated by intraluminal injection of sterile saline solution before performing the next procedure [46].

Barium sulfate suspension adheres to parietal and visceral surfaces in the abdominal cavity very rapidly and is not easily removed. Within hours of barium's presence in the abdominal cavity, irrigation to remove barium sulfate becomes ineffective [13, 36, 66, 67]. Therefore, various options, such as copious irrigation, direct wiping with gauze and/or omentectomy, can be considered. Some authors recommended that gentle manipulation, irrigation of the abdominal cavity with normal saline solution and removal of the greater omentum may minimize adhesion formation in dogs [13, 49, 59]. Although omentectomy helps to diminish the time for barium sulfate removal and reduce the likelihood of adhesion formation, surgeons should consider the loss of the omentum's benefits, such as provision of blood supply to intestinal incisions and provision of a seal to prevent intestinal leakage [5, 47]. Omentectomy may be performed, if dispersion and adhesion of barium sulfate is severe, making barium sulfate difficult to remove. Alternatively, urokinase, streptokinase and urokinase-activated plasmin have been used in human medicine to remove the adherent barium particles [14, 23, 67]. Concentrated urokinase (7,200 IU in 500 ml of normal saline) with irrigation and wiping was successfully applied to removal of clumps of barium sulfate from the serosal surface of the abdominal cavity in a human patient [67].

POSTOPERATIVE COMPLICATIONS AND MANAGEMENT

Postoperatively, intensive monitoring must be employed. Respiratory and cardiovascular evaluation should be closely monitored. Practitioners should be vigilant for complications, such as acute vascular shock, sepsis, diffuse peritonitis, hypoproteinemia, electrolyte imbalance, cardiac arrest, small bowel obstruction related to progression of granulomas and adhesions in the abdominal cavity [13, 17, 24, 49, 59, 66].

Closed suction drainage, open peritoneal drainage or vacuum-assisted drainage can be utilized for small animal barium peritonitis cases [9, 12, 32, 35, 41, 48, 60]. If significant postoperative abdominal fluid production is anticipated, the surgeon must consider which abdominal drainage technique is appropriate. Open abdominal drainage or closed-suction drainage rather than closure without additional drainage should be considered to remove gross contamination and reduce suspected progression of adhesions [3]. Most of the contrast medium in one canine study drained within 6 hr after open abdominal drainage and within 24 to 48 hr after sump-penrose drainage [33]. Meanwhile, complete encasement of sump-penrose drains and partial occlusion of entirely exposed abdominal incisions by omentum with adhesion to the abdominal wound edges were observed at necropsy [33].

Measurements of hydration status and fluid therapy are crucial for patient management. The use of an indwelling urinary catheter can be helpful to monitor urine production and to keep the patient clean [15, 53]. If severe hypotension occurs, intravenous fluids (e.g., crystalloid or colloid) alone may be ineffectual, and vasopressors may be necessary. Intravenous broad-spectrum antibiotic therapy should be

applied and adjusted according to the results of intraoperative bacterial culture and susceptibility testing. If hypoproteinemia becomes severe (albumin <1.5 mg/dl, total solids <3.0 mg/dl), intravenous colloids can be administered [53].

Early enteral nutritional support after surgery helps diminish the risk of hypoproteinemia [11]. In septic peritonitis cases in dogs, early nutritional support is associated with a shorter hospitalization length [42]. In human medicine, early enteral nutritional support has demonstrated additional advantages (e.g., increased anastomotic strength and rapid healing, positive nitrogen balance and decreased bacterial translocation through a compromised GI mucosal barrier) as well [16]. Early postoperative enteral feeding by jejunostomy is feasible in human patients with nontraumatic perforation and peritonitis and reduces septic morbidity, and early nutritional support in peritonitis had fewer septic complications, such as wound infection, intraabdominal abscess and bronchopneumonia compared with a control group [58].

Additional abdominal fluid analysis can be a useful monitoring tool. The number of toxic and/or degenerate neutrophils should decrease progressively after surgery, and no bacteria should be seen after 3 days [55]. Through cytologic examination and susceptibility testing procedures, the choice of antimicrobial therapy and/or second exploratory celiotomy can be determined.

PROGNOSIS

Prognosis for barium peritonitis is guarded to poor. Mortality rate of barium peritonitis is higher than that of generalized septic peritonitis, because barium with GI contents has a time-dependent and synergistically deleterious effect. Dogs that were injected with 30 ml of nonsterile barium sulfate into the abdominal cavity were all quite ill within hr after injection, and 7 of the 10 were dead within 2 weeks [1, 13]. In experimental studies, once barium sulfate was mixed with GI contents in the abdominal cavity, mortality was 100% within 24 hr. Barium sulfate can cause high mortality rate secondary to diffuse hemorrhagic peritonitis, and survivors may commonly have numerous adhesions and granulomas in the abdominal cavity [13, 62]. When barium sulfate was mixed with GI contents in the abdominal cavity, deleterious effects were worse due to accompanying infection [13, 59]. In a canine study, peritonitis by exposure to a mixture of feces and barium was more lethal than peritonitis by exposure to feces alone or barium alone [1]. However, if treated urgently and aggressively, patient outcome can be good [24, 54].

DISCUSSION

In an *ex vivo* experiment, the effect on leukocytic response of radiographic contrast agents including barium and water-soluble contrast agents, Conray 30 and Cysto Conray II, was examined [29]. Barium sulfate was a significant activator of phagocytic cells in this study. Interestingly, when additional phagocytic challenges were induced by standard Zymosan particles (polysaccharide extract from the wall of *yeast sp.*) and several bacteria (e.g., *Staphylococcus epidermidis*,

Streptococcus faecalis and *Escherichia coli*.), depression of phagocytic activity by barium sulfate was worse compared to the two other water-soluble contrast agents [29]. Therefore, it is possible that the enhanced effect of barium observed in patients with fecal peritonitis could be based upon interference with the normal immunologic phagocytic response to bacterial invasion of the abdominal cavity. In adult guinea pigs, barium incurred the most significant deleterious short- and long-term effects in fecal peritonitis. The authors concluded that dilute water-soluble contrast agents have much greater margin of safety [28].

Regarding the effect of sterile barium sulfate on intestinal anastomosis, coating of intestinal mucosa and serosa with barium sulfate did not influence the progression of healing or end result of anastomosis [50]. Although the presence of sterile barium sulfate without leakage of GI contents produced an intense leukocytic inflammatory reaction, this reaction had no unexpected effect on the outcome of the anastomosis in an experimental study [50]. Similarly, the effect of barium on visceral wound transmural healing in the GI tract of the rat was minimal [57].

If contrast barium studies are inevitable, other contrast agents (e.g., iodinated contrast agents) instead of barium sulfate may be suitable for diagnosis [8, 20, 40, 51]. Meanwhile, most of the ionic agents with higher osmolality are hypertonic and cause an influx of fluid into the GI tract, which could worsen a hypovolemic state [8, 44, 56].

Intraabdominal circulation has been thoroughly investigated in normal dogs, and patterns of fluid dispersion and drainage have been documented. After injection of oil-based contrast agents intraperitoneally, the contrast agents dispersed throughout the abdominal cavity 15 to 30 min after cranial injection and 1 to 2 hr after caudal injection [33]. Similarly, some researchers observed that an accumulation of fluid in the abdominal cavity occurred within 1 or 2 hr after injection of barium [49, 66]. When barium sulfate suspension and feces were percutaneously injected into the abdominal cavity, immediate dispersal of the contrast agents occurred [13]. In addition, with abdominal radiography, barium sulfate was observed over 3.5 to 4 months. Meanwhile, other contrast agents (e.g., iodinated contrast agents) disappeared within 48 hr [1].

Omentectomy may be performed to remove adherent barium particles. Nonetheless, surgeons should consider omentectomy only when they cannot effectively remove barium particles from the omentum. In an experimental group treated by irrigation of the abdominal cavity and removal of the greater omentum, lesser adhesions were observed when compared to non-omentectomized groups [66]. After omentectomy in dogs, 90% mortality rates with intestinal anastomoses were reported [47]. If the omentum is devitalized or more substantial mechanical reinforcement is required, intestinal serosal patching can be performed [18]. In three barium peritonitis cases, omentectomy was not applied [17, 24, 54]. In equine practice, omentectomy has been used to decrease the overall incidence of postoperative intraabdominal adhesion. Complications associated with the omentectomy procedure itself did not occur when 80% to

90% of the omentum was removed in horses [39]. The effects of complete omentectomy and partial omentectomy techniques were compared in human beings with gastric cancer. In that study, authors reported that partial omentectomy may become a surgical option to avoid side effects of complete omentectomy, such as longer operation time and low serum albumin concentration on the first postoperative day [38]. Some researchers have attempted to investigate that the effect of the surgical removal of the greater omentum is associated with insulin action [19, 30, 43, 64]. However, the effects of omentectomy to improve insulin sensitivity are controversial. In an experimental study, the removal of the greater omentum may improve insulin sensitivity in nonobese dogs [43]. Meanwhile, other researchers found that omentectomy did not improve insulin sensitivity for obese adults [19, 30].

In one case associated with barium peritonitis caused by a stick foreign body, seven days before presentation, the dog had undergone a cystotomy for calcium oxalate urolith removal at a referring veterinarian's clinic. Two days before presentation, a barium contrast study had been performed. Postoperatively, Jackson-Pratt closed suction drainage was applied. Postoperative complications included diffuse peritonitis, acute vascular shock and cardiac arrest on postoperative day 9. The patient was resuscitated. Later, sepsis and progression of abdominal adhesion developed. Eventually, the dog had severe diffuse peritonitis, and euthanasia was performed per the owner's wishes because of poor prognosis. At necropsy, evidence of leakage at the anastomosis was noted [17]. Based on experimental evidence, dogs should be monitored for 2 weeks after surgery, because mortality rate was highest within 2 weeks [1, 13]. In the case report associated with barium peritonitis caused by postoperative nonsteroidal antiinflammatory drugs, abdominal lavage with a sump-penrose drain was discontinued 60 hr after surgery. The dog was discharged 4 days after surgery and survived. After the 10th day, abdominal drainage stopped. Fifteen months after surgery, the dog was reported to be in excellent health [24]. In the barium peritonitis case caused by suspicious pre-existing perforation with T-cell lymphoma, a barium contrast study was performed the day before presentation. Through abdominal exploratory surgery, 3 liters of serosanguineous, icteric fluid, perforated mid-jejunum and a hepatic nodule were revealed. Jejunal resection and liver biopsy were performed. Bacterial culture of abdominal fluid was negative. The dog recovered very well postoperatively. In this case report, additional details of surgical procedures or postoperative management were not elucidated [54]. In a feline barium peritonitis case caused by a piece of plastic wrap foreign body, leakage of barium contrast medium is revealed in a feline abdominal cavity 2 hr after initiation of the contrast study (Fig. 3). In this case, exploratory celiotomy was performed immediately after definitive radiographic diagnosis of intra-abdominal barium in this cat. Leakage of barium contrast medium was observed in the abdominal cavity and is noted on the mesentery and intestinal serosa (Fig. 4). During hospitalization, abdominal drainage was not performed, and there was no postoperative complication. The cat was discharged 7 days after surgery and survived.

SUMMARY

There are several interesting observations in barium peritonitis: (1) Abdominal fluid analysis including cytologic examination can efficiently provide definitive diagnostic results. Therefore, practitioners should be familiar with cytological interpretation (e.g., marked suppurative inflammation with intracellular barium sulfate). Meanwhile, serial radiography after a barium contrast study may not provide a timely diagnosis. (2) Initial aggressive fluid therapy should be performed immediately before surgical removal of barium from the abdominal cavity to decrease the mortality risk. (3) Once the patient's cardiovascular status is stabilized by aggressive intravenous fluid therapy, urgent exploratory celiotomy is recommended within 1 to 2 hr after the leakage of barium sulfate. Surgical removal of barium sulfate beyond 3 to 6 hr after barium spillage may not reduce the mortality rate. (4) Surgical techniques to reduce barium sulfate and gross contamination include copious irrigation and gentle wiping with a gauze sponge. However, it may be difficult to remove barium debris from the abdominal cavity. If needed, omentectomy should be considered to remove barium contents and reduce surgical operation time. (5) Barium peritonitis patients must be monitored carefully for at least 2 weeks postoperatively, because mortality rate is the highest during this time. (6) Distinctive complications in barium peritonitis include hypovolemia, hypoalbuminemia, hypoproteinemia, severe peritonitis, multiple abdominal adhesions and granuloma.

CONCLUSION

Barium peritonitis is rare, but life-threatening, and poses a therapeutic challenge. Moreover, highly time-dependent diagnosis and treatment are essential within 2 hr after barium leakage occurs. More clinical cases and study are required to develop definitive treatment guidelines.

REFERENCES

- Almond, C. H., Cochran, D. Q. and Shucart, W. A. 1961. Comparative study of the effects of various radiographic contrast media on the peritoneal cavity. *Ann. Surg.* **154** Suppl.: 219–224. [Medline] [CrossRef]
- Beddoe, H. L., Kay, S. and Kaye, S. 1954. Barium granuloma of the rectum; report of a case. *J. Am. Med. Assoc.* **154**: 747–749. [Medline] [CrossRef]
- Bentley, A. M. and Holt, D. 2008. Drainage techniques for the septic abdomen. In: Kirk's Current Veterinary Therapy (Bonagura, J.D. Kirk, R.W. Twedt, D.C. eds.), Elsevier Saunders, St. Louis.
- Bentley, A. M., Otto, C. M. and Shofer, F. S. 2007. Comparison of dogs with septic peritonitis: 1988–1993 versus 1999–2003. *J. Vet. Emerg. Crit. Care* **17**: 391–398. [CrossRef]
- Birchard, S., Chew, D., Crisp, M. and Fossum, T. 1988. Modified technique for placement of a column disc peritoneal dialysis catheter. *J. Am. Anim. Hosp. Assoc.* **24**: 663.
- Boothe, D. M. 2011. Small Animal Clinical Pharmacology & Therapeutics. Elsevier Health Sciences, St. Louis.
- Boysen, S. R., Tidwell, A. S. and Penninck, D. G. 2003. Ultrasonographic findings in dogs and cats with gastrointestinal perforation. *Vet. Radiol. Ultrasound* **44**: 556–564. [Medline] [CrossRef]
- Brawner, W. R. Jr. and Bartels, J. E. 1983. Contrast radiography of the digestive tract. Indications, techniques, and complications. *Vet. Clin. North Am. Small Anim. Pract.* **13**: 599–626. [Medline]
- Buote, N. J. and Havig, M. E. 2012. The use of vacuum-assisted closure in the management of septic peritonitis in six dogs. *J. Am. Anim. Hosp. Assoc.* **48**: 164–171. [Medline] [CrossRef]
- Cariou, M., Lipscomb, V. J., Brockman, D. J., Gregory, S. P. and Baines, S. J. 2009. Spontaneous gastroduodenal perforations in dogs: a retrospective study of 15 cases. *Vet. Rec.* **165**: 436–441. [Medline] [CrossRef]
- Cavanaugh, R. P., Kovak, J. R., Fischetti, A. J., Barton, L. J. and Bergman, P. 2008. Evaluation of surgically placed gastrojejunostomy feeding tubes in critically ill dogs. *J. Am. Vet. Med. Assoc.* **232**: 380–388. [Medline] [CrossRef]
- Cioffi, K. M., Schmiedt, C. W., Cornell, K. K. and Radlinsky, M. G. 2012. Retrospective evaluation of vacuum-assisted peritoneal drainage for the treatment of septic peritonitis in dogs and cats: 8 cases (2003–2010). *J. Vet. Emerg. Crit. Care (San Antonio)* **22**: 601–609. [Medline] [CrossRef]
- Cochran, D. Q., Almond, C. H. and Shucart, W. A. 1963. An experimental study of the effects of barium and intestinal contents on the peritoneal cavity. *Am. J. Roentgenol. Radium Ther. Nucl. Med.* **89**: 883–887. [Medline]
- Collins, D. L. and Sandy, J. T. 1965. Peritoneal Adhesions. Experimental Use of Fibrinolysin to Prevent Reformation. *Arch. Surg.* **91**: 413–418. [Medline] [CrossRef]
- Culp, W. T. and Holt, D. 2010. Septic Peritonitis. *Compend. Contin. Educ. Vet.* **32**: E1–E15. [Medline]
- Derveniz, C., Smailis, D. and Hatzitheoklitos, E. 2003. Bacterial translocation and its prevention in acute pancreatitis. *J. Hepatobiliary Pancreat. Surg.* **10**: 415–418. [Medline] [CrossRef]
- Dunbar, M. and Alleman, A. 2009. A challenging case: Abdominal effusion in a dog. *Vet. Med.* **104**: 244–247.
- Ellison, G. W. 2011. Complications of gastrointestinal surgery in companion animals. *Vet. Clin. North Am. Small Anim. Pract.* **41**: 915–934 vi. [Medline] [CrossRef]
- Fabbrini, E., Tamboli, R. A., Magkos, F., Marks-Shulman, P. A., Eckhauser, A. W., Richards, W. O., Klein, S. and Abumrad, N. N. 2010. Surgical removal of omental fat does not improve insulin sensitivity and cardiovascular risk factors in obese adults. *Gastroenterology* **139**: 448–455. [Medline] [CrossRef]
- Foley, M. J., Ghahremani, G. G. and Rogers, L. F. 1982. Reappraisal of contrast media used to detect upper gastrointestinal perforations: comparison of ionic water-soluble media with barium sulfate. *Radiology* **144**: 231–237. [Medline]
- Gardiner, H. and Miller, R. E. 1973. Barium peritonitis. A new therapeutic approach. *Am. J. Surg.* **125**: 350–352. [Medline] [CrossRef]
- Gardner, D. J. and Hanson, R. E. 1990. Computed tomography of retroperitoneal perforation after barium enema. *Clin. Imaging* **14**: 208–210. [Medline] [CrossRef]
- Gervin, A. S., Puckett, C. L. and Silver, D. 1973. Serosal hypofibrinolysis. A cause of postoperative adhesions. *Am. J. Surg.* **125**: 80–88. [Medline] [CrossRef]
- Gfeller, R. W. and Sandors, A. D. 1991. Naproxen-associated duodenal ulcer complicated by perforation and bacteria- and barium sulfate-induced peritonitis in a dog. *J. Am. Vet. Med. Assoc.* **198**: 644–646. [Medline]
- Grobmyer, A. J. 3rd., Kerlan, R. A., Peterson, C. M. and Dragst-

- edt, L. R. 2nd. 1984. Barium peritonitis. *Am. Surg.* **50**: 116–120. [[Medline](#)]
26. Hardy, T. G. Jr., Hartmann, R. F., Aguilar, P. S. and Stewart, W. R. 1983. Survival after colonic perforation during barium-enema examination. Modified radical surgical debridement. *Dis. Colon Rectum.* **26**: 116–118. [[Medline](#)] [[CrossRef](#)]
27. Henrich, M. H. 1986. Barium peritonitis in animal experiments (rat, dog). *Chirurg.* **57**: 801–804. [[Medline](#)]
28. Hernanz-Schulman, M., Foster, C., Maxa, R., Battles, G., Dutt, P., Stratton, C., Holburn, G., Schulman, G., Neblett, W. W., Shyr, Y., Hakim, R. R., Vanholder, R. and Heller, R. M. 2000. Experimental study of mortality and morbidity of contrast media and standardized fecal dose in the peritoneal cavity. *Pediatr. Radiol.* **30**: 369–378. [[Medline](#)] [[CrossRef](#)]
29. Hernanz-Schulman, M., Vanholder, R., Waterloos, M. A., Hakim, R. and Schulman, G. 2000. Effect of radiographic contrast agents on leukocyte metabolic response. *Pediatr. Radiol.* **30**: 361–368. [[Medline](#)] [[CrossRef](#)]
30. Herrera, M. F., Pantoja, J. P., Velazquez-Fernandez, D., Cabiedes, J., Aguilar-Salinas, C., Garcia-Garcia, E., Rivas, A., Villeda, C., Hernandez-Ramirez, D. F., Davila, A. and Zarain, A. 2010. Potential additional effect of omentectomy on metabolic syndrome, acute-phase reactants, and inflammatory mediators in grade III obese patients undergoing laparoscopic Roux-en-Y gastric bypass: a randomized trial. *Diabetes Care* **33**: 1413–1418. [[Medline](#)] [[CrossRef](#)]
31. Hinton, L. E., McLoughlin, M. A., Johnson, S. E. and Weisbrode, S. E. 2002. Spontaneous gastroduodenal perforation in 16 dogs and seven cats (1982–1999). *J. Am. Anim. Hosp. Assoc.* **38**: 176–187. [[Medline](#)]
32. Hosgood, G., Salisbury, S. K. and DeNicolla, D. B. 1991. Open peritoneal drainage versus sump-Penrose drainage: clinicopathological effects in normal dogs. *J. Am. Anim. Hosp. Assoc.* **115**.
33. Hosgood, G., Salisbury, S. K., Cantwell, H. D. and DeNicola, D. B. 1989. Intraperitoneal circulation and drainage in the dog. *Vet. Surg.* **18**: 261–268. [[Medline](#)] [[CrossRef](#)]
34. Hudson, J. A. 2002. Abdominal Radiology for the Small Animal Practitioner. Teton NewMedia, Jackson.
35. Johnson, M. D. and Mann, F. A. 2006. Treatment for pancreatic abscesses via omentalization with abdominal closure versus open peritoneal drainage in dogs: 15 cases (1994–2004). *J. Am. Vet. Med. Assoc.* **228**: 397–402. [[Medline](#)] [[CrossRef](#)]
36. Karanikas, I. D., Kakoulidis, D. D., Gouvas, Z. T., Hartley, J. E. and Koundourakis, S. S. 1997. Barium peritonitis: a rare complication of upper gastrointestinal contrast investigation. *Postgrad. Med. J.* **73**: 297–298. [[Medline](#)] [[CrossRef](#)]
37. Kay, S. and Choy, S. H. 1955. Results of intraperitoneal injection of barium sulfate contrast medium; an experimental study. *AMA Arch. Pathol.* **59**: 388–392. [[Medline](#)]
38. Kim, M. C., Kim, K. H., Jung, G. J. and Rattner, D. W. 2011. Comparative study of complete and partial omentectomy in radical subtotal gastrectomy for early gastric cancer. *Yonsei Med. J.* **52**: 961–966. [[Medline](#)] [[CrossRef](#)]
39. Kuebelbeck, K. L., Slone, D. E. and May, K. A. 1998. Effect of omentectomy on adhesion formation in horses. *Vet. Surg.* **27**: 132–137. [[Medline](#)] [[CrossRef](#)]
40. Lamb, C. R. 1999. Recent developments in diagnostic imaging of the gastrointestinal tract of the dog and cat. *Vet. Clin. North Am. Small Anim. Pract.* **29**: 307–342. [[Medline](#)]
41. Lanz, O. I., Ellison, G. W., Bellah, J. R., Weichman, G. and VanGilder, J. 2001. Surgical treatment of septic peritonitis without abdominal drainage in 28 dogs. *J. Am. Anim. Hosp. Assoc.* **37**: 87–92. [[Medline](#)]
42. Liu, D. T., Brown, D. C. and Silverstein, D. C. 2012. Early nutritional support is associated with decreased length of hospitalization in dogs with septic peritonitis: a retrospective study of 45 cases (2000–2009). *J. Vet. Emerg. Crit. Care (San Antonio)* **22**: 453–459. [[Medline](#)] [[CrossRef](#)]
43. Lottati, M., Kolka, C. M., Stefanovski, D., Kirkman, E. L. and Bergman, R. N. 2009. Greater omentectomy improves insulin sensitivity in nonobese dogs. *Obesity (Silver Spring)* **17**: 674–680. [[Medline](#)] [[CrossRef](#)]
44. Maddox, T. G. 2002. Adverse reactions to contrast material: recognition, prevention, and treatment. *Am. Fam. Physician* **66**: 1229–1234. [[Medline](#)]
45. Maniatis, V., Chrysikopoulos, H., Roussakis, A., Kalamara, C., Kavadias, S., Papadopoulos, A., Andreou, J. and Stringaris, K. 2000. Perforation of the alimentary tract: evaluation with computed tomography. *Abdom. Imaging* **25**: 373–379. [[Medline](#)] [[CrossRef](#)]
46. Mann, F. A. 2008. Acute abdomen: Evaluation and Emergency Treatment. In: Bonagura, J.D. Kirk, R.W. Twedt, D.C. Kirk's Current Veterinary Therapy. Elsevier Saunders, St. Louis.
47. McLachlin, A. D. and Denton, D. W. 1973. Omental protection of intestinal anastomoses. *Am. J. Surg.* **125**: 134–140. [[Medline](#)] [[CrossRef](#)]
48. Mueller, M. G., Ludwig, L. L. and Barton, L. J. 2001. Use of closed-suction drains to treat generalized peritonitis in dogs and cats: 40 cases (1997–1999). *J. Am. Vet. Med. Assoc.* **219**: 789–794. [[Medline](#)] [[CrossRef](#)]
49. Nahrwold, D. L., Isch, J. H., Benner, D. A. and Miller, R. E. 1971. Effect of fluid administration and operation on the mortality rate in barium peritonitis. *Surgery* **70**: 778–781. [[Medline](#)]
50. Najjar, F. B., al-Khalil, I. and Noltinius, H. 1973. The effect of barium on intestinal anastomosis. *Am. J. Proctol.* **24**: 307–311. [[Medline](#)]
51. Ott, D. J. and Gelfand, D. W. 1983. Gastrointestinal contrast agents. Indications, uses, and risks. *JAMA* **249**: 2380–2384. [[Medline](#)] [[CrossRef](#)]
52. Ragetly, G. R., Bennett, R. A. and Ragetly, C. A. 2011. Septic peritonitis: etiology, pathophysiology, and diagnosis. *Compend. Contin. Educ. Vet.* **33**: E1–E7. [[Medline](#)]
53. Ragetly, G. R., Bennett, R. A. and Ragetly, C. A. 2011. Septic peritonitis: treatment and prognosis. *Compend. Contin. Educ. Vet.* **33**: E1–E6. [[Medline](#)]
54. Renschler, J., Tarigo, J., Neel, J. and Grindem, C. 2008. What is your diagnosis? Particulate material in peritoneal fluid from a dog. *Vet. Clin. Pathol.* **37**: 129–132. [[Medline](#)] [[CrossRef](#)]
55. Rosin, E., Greenfield, C. and Hosgood, G. 1998. Peritoneum and abdominal wall. In: Current Techniques in Small Animal Surgery (Borjab, M.J., Slocum, B. and Ellison, G.W. eds.), Williams & Wilkins, Baltimore.
56. Seltzer, S. E., Jones, B. and McLaughlin, G. C. 1979. Proper choice of contrast agents in emergency gastrointestinal radiology. *CRC Crit. Rev. Diagn. Imaging* **12**: 79–99. [[Medline](#)]
57. Shackleton, K. L., Stewart, E. T., Henderson, J. D. Jr., Demeure, M. J. and Telford, G. L. 2000. Effect of barium sulfate on wound healing in the gastrointestinal tract of the rat. *Radiology* **214**: 563–567. [[Medline](#)] [[CrossRef](#)]
58. Singh, G., Ram, R. P. and Khanna, S. K. 1998. Early postoperative enteral feeding in patients with nontraumatic intestinal perforation and peritonitis. *J. Am. Coll. Surg.* **187**: 142–146. [[Medline](#)] [[CrossRef](#)]
59. Sisel, R. J., Donovan, A. J. and Yellin, A. E. 1972. Experimental fecal peritonitis. Influence of barium sulfate or water-soluble radiographic contrast material on survival. *Arch. Surg.* **104**:

- 765–768. [\[Medline\]](#) [\[CrossRef\]](#)
60. Staatz, A. J., Monnet, E. and Seim, H. B. 3rd. 2002. Open peritoneal drainage versus primary closure for the treatment of septic peritonitis in dogs and cats: 42 cases (1993–1999). *Vet. Surg.* **31**: 174–180. [\[Medline\]](#) [\[CrossRef\]](#)
 61. Steinman, R. M., Torres, G. and Stoupis, C. 1994. CT of abdominal barium intravasation. *J. Comput. Assist. Tomogr.* **18**: 149–151. [\[Medline\]](#) [\[CrossRef\]](#)
 62. Subramanyam, K., Rajan, R. T. and Hearn, C. D. 1988. Barium granuloma of the sigmoid colon. *J. Clin. Gastroenterol.* **10**: 98–100. [\[Medline\]](#) [\[CrossRef\]](#)
 63. Thomas, J. C. 1936. The disposal of barium sulphate in the abdominal cavity. *J. Pathol. Bacteriol.* **43**: 285–298. [\[CrossRef\]](#)
 64. Thörne, A., Lonnqvist, F., Apelman, J., Hellers, G. and Arner, P. 2002. A pilot study of long-term effects of a novel obesity treatment: omentectomy in connection with adjustable gastric banding. *Int. J. Obes. Relat. Metab. Disord.* **26**: 193–199. [\[Medline\]](#) [\[CrossRef\]](#)
 65. Thrall, D. E. 2012. Textbook of Veterinary Diagnostic Radiology. Saunders Elsevier, St. Louis.
 66. Westfall, R. H., Nelson, R. H. and Musselman, M. M. 1966. Barium peritonitis. *Am. J. Surg.* **112**: 760–763. [\[Medline\]](#) [\[CrossRef\]](#)
 67. Yamamura, M., Nishi, M., Furubayashi, H., Hioki, K. and Yamamoto, M. 1985. Barium peritonitis. *Dis. Colon Rectum.* **28**: 347–352. [\[Medline\]](#) [\[CrossRef\]](#)
 68. Zheutlin, N., Lasser, E. C. and Rigler, L. G. 1952. Clinical studies on effect of barium in the peritoneal cavity following rupture of the colon. *Surgery* **32**: 967–979. [\[Medline\]](#)