

A Case of Neonatal Calf with Meningitis Associated with *Klebsiella oxytoca* Infection

Yukio SEIMIYA, Kan-ichi OHSHIMA¹⁾, Hiroshi ITOH, Ryu-koh MURAKAMI, and Makoto HARITANI²⁾

Morioka Livestock Hygiene Service Center, Takizawa-mura, Iwate-gun, Iwate 020-01, ¹⁾Iwate Veterinary Medical Association, Morioka 020, and ²⁾National Institute of Animal Health, Tsukuba 305, Japan

(Received 20 July 1992/Accepted 3 October 1992)

ABSTRACT. A 16-days-old calf exhibited pyrexia, difficulty to stand and walk, cloudiness of the ocular aqueous humor, and swelling of the shoulder joints. The primary pathological lesion was fibrinopurulent meningitis with Gram-negative small bacilli, and which was concurrently accompanied with endophthalmitis, polyarthritis, and purulent inflammation in several visceral organs. *Klebsiella oxytoca* was isolated from the brain and spinal cord. These results suggest that this is a rare case of meningitis with septicemic *K. oxytoca* infection in neonatal calf.—**KEY WORDS:** *Klebsiella oxytoca*, meningitis, neonatal calf.

J. Vet. Med. Sci. 55(1): 141–143, 1993

Bacterial meningoventriculitis in neonatal ungulates is usually concurrent with septicemia, and characterized by a peculiarly surface-related inflammation of the meninges, choroid plexuses, and ventricular walls with rare involvement of the underlying parenchyma [1]. The term, meningitis, can be also used for this condition, since the inflammation is usually more prominent in the meninges [1, 12–14]. The disease in neonatal ruminants is most often caused by *Escherichia coli* [1, 11, 13], and less frequently by *Pasteurella* [15], *Streptococcus pneumoniae* [17], *S. bovis* [14], or *Listeria monocytogenes* [7, 12]. However, there are few reports on *Klebsiella* meningitis in neonatal ruminants. The purpose of this report is to describe pathological findings in a neonatal calf suffering from meningitis with septicemic *K. oxytoca* infection.

A calf of Japanese Black breed had made no attempt to suck colostrum, and exhibited depression and anorexia since the birth. The calf showed pyrexia of about 40°C, difficulty to stand and walk, reluctance to move, and bilateral cloudiness of the ocular aqueous humor, but did not respond to the treatments with ampicillin and electrolytes tried at the age of 2 and 3 days. Later, the swollen shoulder joints were observed at the age of 7 days. The animal became fatal and was killed by euthanasia for necropsy at the age of 16 days.

Macroscopically, there was an increase of cloudy cerebrospinal fluid. Congestion, petechiae, and cloudy areas were present in the meninges. The lesions were more prominent at the ventral side of the brain stem and at the upper cervical part of the spinal cord. The lateral ventricles and mesencephalic aqueduct were dilated. On the cut surface of eye balls, aqueous humors were cloudy. There was an increase of cloudy synovial fluids in many joints of the limbs, especially in the shoulder joints. Other findings were fibrinous exudate on the peritoneum and atrophic thymus.

Microscopically, the lesions in the brain and spinal cord were fibrinopurulent inflammation (Fig. 1) limited to the meninges, choroid plexuses, and ventricular walls, and more prominent in the meninges throughout the brain and spinal cord. Fibrinous thrombi and loosening or hyalinous degeneration of arteriolar walls were occasionally seen in the affected meninges of the mesencephalon and pons.

Involvement of the choroid plexuses and ventricular walls included mild infiltration of neutrophils and mono-

nuclear cells, occasional epithelial desquamation, subependymal capillarization with edema, occasional desquamation of the ependymal cells, and small amount of fibrinopurulent exudate in the ventricular lumens. The parenchymatous lesions in the brain were minimal and limited to the superficial molecular layer and perivascular spaces in the deeper gray and white matters of the cerebrum and cerebellum. Fibrinopurulent exudate was found in the meninges covering the hypophysis and perineural tissues of the trigeminal ganglia.

Fibrinopurulent endophthalmitis with frequent thrombosis was bilaterally seen with mild extension to the orbital adipose tissue (Fig. 2). There were fibrinopurulent peritonitis, and purulent hepatitis and splenitis. Vasculitis characterized by infiltration of neutrophils and mononuclear cells on the degenerated walls, or fibrinous thrombi were occasionally found in the kidneys, tongue, and lungs. Other findings were catarrhal typhlocolitis and mucosal

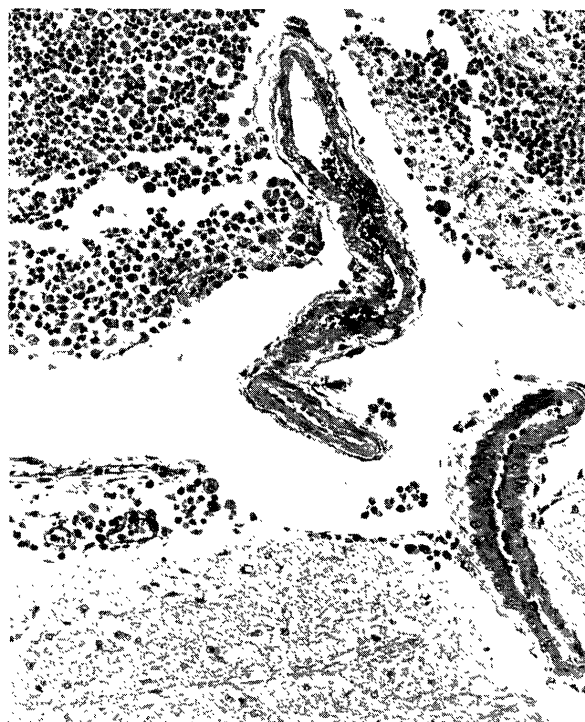


Fig. 1. Infiltration of neutrophils, macrophages, and lymphocytes as well as fibrinous exudate are observed in the meninges of the pons. HE stain. $\times 100$.




Fig. 2. There are congestion, perivascular hemorrhages, fibrinous thrombi, and cellular infiltration in the inner retina, and fibrinopurulent exudate in the ocular cavity. HE stain. $\times 100$.



Fig. 3. Numerous Gram-negative small bacilli (arrows) are present in and around macrophages infiltrating into the meninges of the pons. Gram stain. $\times 400$.

erosions of the gallbladder as well as a decrease in number of lymphocytes in the lymphatic tissues such as the spleen, thymus, several lymph nodes, and intestinal lymphonodules. Numerous Gram-negative small bacilli were found in and around macrophages infiltrating into the purulent lesions of the whole body by Gram stain (Fig. 3). Unfortunately, no joint was histologically examined.

By the avidin-biotin-complex immunoperoxidase technique (ABCIT) [6] using rabbit hyperimmune sera against many serotypes of *E. coli* (0-8, 9, 15, 45, 78, 88, 101, 117, and 153), no *E. coli* antigen was detected in the brain and spinal cord.

The brain, upper cervical part of the spinal cord, and synovial fluid from the shoulder joint were cultured aerobically on tryptic soy agar supplemented with 5% sheep blood, or anaerobically on GAM agar using a gas generating kit (Oxoid Limited, England) at 37°C for 48 hr. Both aerobic and anaerobic cultures yielded *Klebsiella oxytoca* from the brain and spinal cord.

Klebsiellae are generally considered to be opportunistic pathogens that cause diseases when some factors lower the defense mechanisms of the host [8, 16, 18]. The organisms are classified into four species; *K. pneumoniae*, *K. oxytoca*, *K. terrigena*, and *K. planticola* [9]. Of these species, *K. pneumoniae* is known to cause pneumonia [5, 10], septicemia [19], and meningitis [3, 4] in animals or man, especially in nonhuman primates. *K. oxytoca* can be also isolated from various pathological conditions [2].

The primary pathological change observed here was fibrinopurulent meningitis, and which was concurrently

accompanied with endophthalmitis, polyarthritis, and purulent inflammation in several other organs and tissues. Numerous Gram-negative small bacilli in the lesions and isolation of *K. oxytoca* suggest that the present case was in the process of septicemia associated with *K. oxytoca* infection.

The characteristic involvements of fibrinopurulent inflammation in the meninges, choroid plexuses, ventricular walls, joints, and peritoneum were similar to those of neonatal calves with meningitis due to *E. coli* [1, 11, 13], *S. bovis* [14], or *L. monocytogenes* [12] infections. Infarct of the cerebral parenchyma was not found in the present case, while that is sometimes or frequently seen in *E. coli*-infected neonatal calves [1, 13]. This might have been related to fewer frequency of thrombi in the cerebral parenchyma or meninges. In addition, concurrent endophthalmitis, being almost invariably of streptococcal origin [17], occurred in the present case. The result suggests that *Klebsiellae* infection should be paid an attention at diagnosis of neonatal calves with similar lesional combination. Because all *Klebsiella* strains are resistant to ampicillin [9], the present case did not respond to the chemotherapy with the drug.

The present case may have been affected with a so-called weak calf syndrome since the clinical abnormalities. Lymphocytic depression and an inadequate ingestion of colostrum might have contributed to the infection. The typhlocolitis or mucosal erosions of the gallbladder suggests that the gut may have been a possible portal of entry.

ACKNOWLEDGEMENTS. We were grateful to Dr. Masanori Okutomo and Dr. Shūichi Tanaka in Morioka Livestock Hygiene Service Center for their help in bacteriological examination, and Dr. Muneo Nakazawa in National Institute of Animal Health for providing anti-*E. coli* sera.

REFERENCES

1. Cordy, D. R. 1984. *Vet. Pathol.* 21: 587-591.
2. Davis, J. K., Gaertner, D. J., Cox, N. R., Lindsey, J. R., Cassell, G. H., Davidson, M. K., Kervin, K. C., and Rao, G. N. 1987. *Lab. Anim. Sci.* 37: 159-166.
3. Fox, J. G. and Rohovsky, M. W. 1975. *J. Am. Vet. Med. Assoc.* 167: 634-636.
4. Fox, J. G. and Rohovsky, M. W. 1976. *J. Am. Vet. Med. Assoc.* 168: 276.
5. Good, R. C. and May, B. D. 1971. *Infect. Immun.* 3: 87-93.
6. Hus, S., Raine, L., and Fanger, H. 1981. *J. Histochem. Cytochem.* 29: 557-580.
7. Jack, E. J. 1961. *Vet. Rec.* 73: 826 & 846.
8. Kageruka, P., Mortelmans, J., and Vercruysse, J. 1971. *Acta Zool. Pathol. Antverp.* 52: 83-88.
9. Orskov, I. 1984. pp. 461-465. In: *Bergey's Manual of Systematic Bacteriology*, vol. 1 (Krieg, N. R. and Holt, J. G. eds.), Williams & Wilkins, Baltimore.
10. Schmidt, R. E. and Butler, T. M. 1971. *Lab. Anim. Sci.* 21: 946-949.
11. Sato, S., Ohshima, K., Ichikawa, M., and Minamidate, K. 1988. *J. Jpn. Vet. Med. Assoc.* 41: 49-53 (in Japanese with English summary).
12. Seimiya, Y., Ohshima, K., Itoh, H., and Murakami, R. 1992. *J. Vet. Med. Sci.* 54: 1205-1207.
13. Seimiya, Y., Ohshima, K., Itoh, H., Ogasawara, N., Okutomo, M., and Tanaka, S. 1992. *J. Vet. Med. Sci.* 54: 767-768.
14. Seimiya, Y., Ohshima, K., Itoh, H., Ogasawara, N., Okutomo, M., and Tanaka, S. 1992. *J. Vet. Med. Sci.* 54: 871-874.
15. Shand, A. and Markson, L. M. 1953. *Br. Vet. J.* 109: 491-495.
16. Snyder, S. B., Lund, J. E., Bone, J., Soave, O. A., and Hirsch, D. C. 1970. *J. Am. Vet. Med. Assoc.* 157: 1935-1939.
17. Sullivan, N. D. 1985. pp. 278-282. In: *Pathology of Domestic Animals*, vol. 1, 3rd ed. (Jubb, K. V. F., Kennedy, P. C., and Palmer, N. eds.), Academic Press, New York.
18. Weil, A. J., Ramchand, S., and Arias, M. E. 1966. *New Engl. J. Med.* 275: 17-22.
19. Wyand, D. S. and Hayden, D. W. 1973. *J. Am. Vet. Med. Assoc.* 163: 589-591.