

## EFFICACY OF TYLOSIN TARTRATE ON *MYCOPLASMA* INFECTIONS AND EGG SHELL APEX ABNORMALITIES IN LAYER HENS UNDER FIELD CONDITIONS

<sup>1</sup>Konstantinos C. Koutoulis, <sup>2</sup>George Kefalas,  
<sup>3</sup>Niki Mouttotou, <sup>4</sup>Koen De Gussem and <sup>5</sup>Dimitris Theodosiou

<sup>1</sup>Department of Avian Medicine, Faculty of Veterinary Science,  
School of Health Sciences, University of Thessaly, 43100 Karditsa, Greece

<sup>2</sup>Nuevo SA, 34600 New Artaki, Greece

<sup>3</sup>Institute Veterinary Laboratory, Ministry of Rural Development and Food, 34100 Chalkida, Greece

<sup>4</sup>Huvepharma, Uitbreidingstraat 80, 2600 Antwerp, Belgium

<sup>5</sup>A. Mintikkis Farm Ltd, Cy-1687 Nicosia, Cyprus

Received 2013-12-09; Revised 2013-12-10; Accepted 2013-12-20

### ABSTRACT

The aim of this report was to describe a clinical case of concurrent infection with *Mycoplasma Gallisepticum* (MG) and *Mycoplasma Synoviae* (MS) in layers, complicated with *Escherichia coli* and *Pasteurella multocida*, as well as to evaluate the efficacy of tylosin tartrate treatment (Pharmasin® 100% WSG, Huvepharma) on *Mycoplasma* under field conditions. A flock of 18,500 ISA Brown pullets, 21 weeks of age and MS positive, showed an increase in weekly mortality, with no influence on egg production. At 24 weeks of age, post mortem was carried out and blood samples were collected, as well as samples for microbiological cultures from the lesions. In necropsy, several findings of pericarditis, airsacculitis of posterior thoracic sacs, prolapse and egg yolk peritonitis were found. Sporadic neurological signs were also apparent and post mortem examination revealed yellow caseous exudate accumulations in cranial bones. Although egg production was not influenced, Eggshell Apex Abnormalities (EAA) were increased with a significant number of both broken and misshapen eggs together with discoloration. Elisa serological examinations for Infectious Bronchitis Virus (IBV) and Newcastle Disease Virus (NDV) were within vaccination program limits, but MS, MG and Avian Rhinotracheitis (ART) results showed a significant seroconversion. Microbiology also revealed the presence of *Escherichia coli* and *Pasteurella multocida*. On week 25, a drug treatment with tylosin tartrate was applied at a dose of 105 mg kg<sup>-1</sup> body weight in drinking water for five consecutive days. Three days after treatment, misshapen, broken and discolored eggs were decreased. The mortality was also significantly decreased within a week since the beginning of tylosin administration and at 30 weeks of age was within acceptable levels. Post mortem evaluation confirmed the absence of previously gross lesions in primary organs. In summary, tylosin treatment in complicated *Mycoplasma* spp. infections under field conditions improved egg shell quality and decreased mortality, thus the economic losses linked to decreased egg production and labor costs were reduced.

**Keywords:** *Mycoplasma Gallisepticum*, *Mycoplasma Synoviae*, Eggshell Apex Abnormalities, Tylosin, Layer Hens

### 1. INTRODUCTION

*Mycoplasmas* remain one of the most important diseases in modern intensive poultry production, causing

great economic losses and affecting performance of the birds. Economic losses in chickens are attributable not only to overt respiratory disease but also to poor weight gain, downgrading of broilers at slaughter due to

**Corresponding Author:** Konstantinos C. Koutoulis, Department of Avian Medicine, Faculty of Veterinary Science, School of Health Sciences, University of Thessaly, 43100 Karditsa, Greece Tel: +30-24410-66015 Fax: +30-24410-66041

airsacculitis and loss of egg production in layers (Bradbury and Morrow, 2008). *Mycoplasma gallisepticum* and *Mycoplasma synoviae* are the most relevant for commercial chickens from a clinical and an economical point of view. In the last decade MG infections are rare, except for multi-age egg production sites, whereas MS infections became very frequent in poultry flocks in European countries (Bradbury *et al.*, 2005).

*Mycoplasma Gallisepticum* (MG) is a common pathogen of chickens and turkeys that predominantly causes respiratory diseases, including sinusitis, tracheitis, pneumonia and airsacculitis (Ley, 2008). Occasionally, MG infection causes tenosynovitis, salpingitis, sternal bursitis and myocarditis in chickens (Riddell, 1987) and encephalitis in turkeys (Chin *et al.*, 1991). Severe airsacculitis in chickens with MG infection is often complicated by respiratory viruses, i.e., Newcastle Disease Virus (NDV) and Infectious Bronchitis Virus (IBV), or other microorganisms, usually *Escherichia coli* (Gross, 1990).

*Mycoplasma synoviae* is considered the second most important *mycoplasma* affecting chickens (Kleven and Ferguson-Noel, 2008). It causes respiratory disease and subsequent condemnations due to airsacculitis, although most respiratory tract infections seem to be subclinical. *M. synoviae* also causes synovitis in chickens and turkeys (Landman and Feberwee, 2004). The effect of *M. synoviae* infections on egg production by layer chickens remains unclear. In one report a cumulative egg production loss of 10% was seen in flocks infected with *M. synoviae* (Morrow *et al.*, 1990), but in another study no association was seen between *M. synoviae* infection and egg production (Mohammed *et al.*, 1987). However, from the year 2000 onwards also *M. synoviae* strains with oviduct tropism able to induce or associated with Eggshell Apex Abnormalities (EAA) have been increasingly found (Catania *et al.*, 2010; Feberwee *et al.*, 2009; Ranck *et al.*, 2010; Strugnell *et al.*, 2011). EAA are characterized by altered shell surface, shell thinning, increased translucency and the occurrence of cracks and breaks. EAA were first described in white layers housed in cages, but were later also seen in brown layers housed in cages and in both types of birds kept in other housing systems.

Different antimicrobials, especially antibiotics have been used to treat flocks infected with MG and MS in order to reduce severity of clinical signs, lesions and production losses (Bebear and Kempf, 2005). Such treatment can reduce severity of disease, economic losses, populations of *Mycoplasmas*, but does not eliminate MG and MS from the infected poultry flock.

One of the most widely used molecules in medication programs is tylosin, a macrolide antibiotic. Catania *et al.* (2009) reported that tylosin treatment improved egg shell quality and this reduced the economic losses linked to labor costs and moreover the increased average weight of eggs from treated birds contributed to improve production performances.

We recently observed a clinical case of concurrent infection with *Mycoplasma gallisepticum* and *Mycoplasma synoviae* in layers, complicated with *Escherichia coli* and *Pasteurella multocida*. The purpose of this report was to evaluate the efficacy of tylosin tartrate treatment (Pharmasin® 100% WSG, Huvepharma) on *Mycoplasma* infections and EAA in layers under field conditions.

## 2. CASE REPORT

### 2.1. Flock Details

The reported case occurred in a layers farm located in Nicosia, Cyprus. A flock of 18,500 ISA Brown pullets, 15 weeks of age, imported from Greece, was introduced in one house under intensive and controlled environment system. No major disease problems were previously recorded in the farm. The farm was completely isolated, with high standards of biosecurity and held complete records of feed and water consumption, daily production data and veterinary instructions.

### 2.2. Clinical History

During the rearing period, the flock was fully vaccinated against Infectious Bronchitis Virus (IBV) and Newcastle Disease Virus (NDV), whereas vaccination against MG, MS and ART was not applied.

The first day of arrival (15 weeks of age), layers already laid the first eggs reaching 2% at the age of 16 weeks. The flock was also found serologically positive in MS and negative in MG at the time of arrival. Production data, feed consumption and mortality were accordingly to the breed specifications, with the exception of layers body weight which was 100 g heavier than the breed standard. No signs of any disease manifestation were shown and no production problems were observed up to 21 weeks of age, even though the flock was tested MS positive. At the onset of 21st week of age, the average weekly mortality was raised gradually up to 0.98% in a period of five weeks (26 weeks of age), the egg production was not influenced, but the percentage of broken and misshapen eggs rapidly increased (Fig. 1).

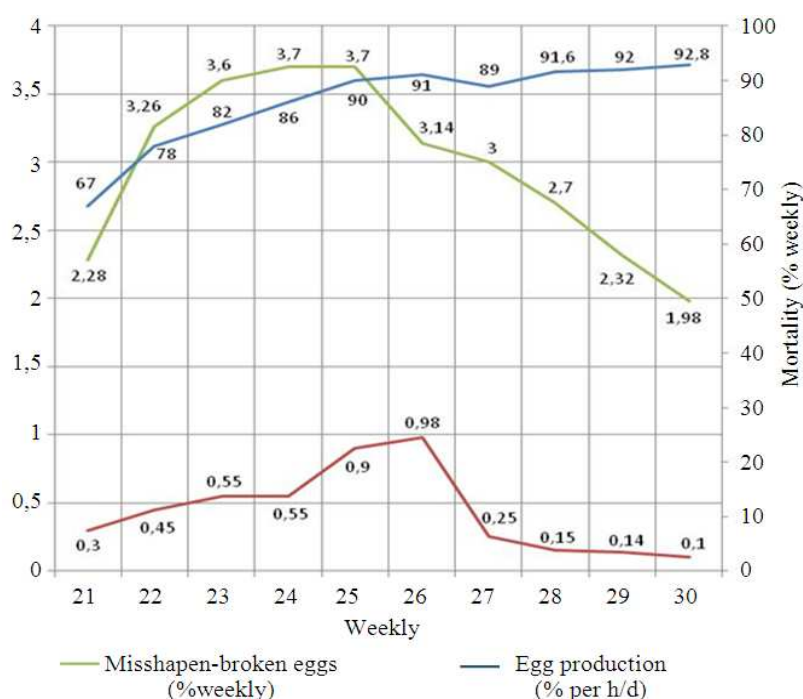


Fig. 1. Production data before and after treatment with tylosin tartrate at 25 weeks of age

### 2.3. Clinical Examination

At 21st week of age there was a slight increase in mortality which was first attributed to prolapse (Fig. 2) and peritonitis (Fig. 3) due to early production. Due to an outbreak of ND in broilers at that time and to strict biosecurity measures, no post mortem examination was carried out.

At week 24, clinical inspection and post mortem examination was carried out. During the clinical inspection of the flock, the main symptoms observed were unilateral or bilateral swelling of the eyelids and facial skin, with no other major symptoms. Primary lesion findings were pericarditis-air sacculitis of posterior thoracic air sacs (Fig. 4) and at a later stage, post mortem examination revealed yellow caseous exudate accumulations in cranial bones (Fig. 5) with apparent, but very sporadic, neurological signs (Fig. 6). Egg quality parameters were also compromised with increased number of misshapen and broken eggs, together with discoloration of brown eggs (Fig. 7).

### 2.4. Sample Collection and Laboratory Examination

At week 24, blood samples were also collected, as well as samples from the lesions for microbiological analysis. The results revealed *E. coli* isolation from

infected air sacs, heart and egg yolk, as well as *Pasteurella multocida* in the case of purulent inflammation of cranial bones. Elisa analysis (Biochek, Holland) showed high positive titres for MG, MS and ART, indicating infection with a field strain, whereas NDV and IBV seroconversion was indicative of a vaccination (Mean Titer and CV according to Biochek baselines) well implemented (Table 1).

### 2.5. Treatment

On week 25, a treatment with tylosin tartrate (Pharmasin® 100% WSG, Huvepharma) was applied at a dose of  $105 \text{ mg kg}^{-1}$  (3.5 bags of 1.1 kg each per day with bird average body weight of 1.8 kg) in drinking water for five consecutive days.

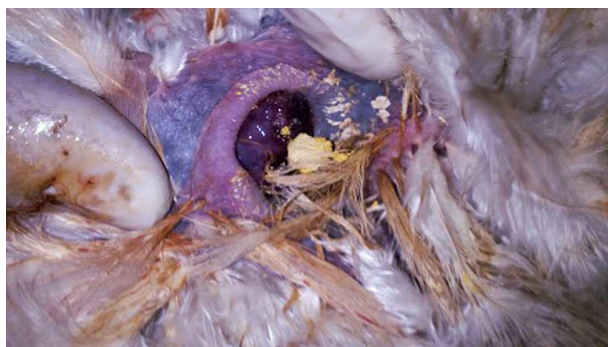### 2.6. Outcome

Three days after start of treatment, the numbers of misshapen, broken and discolored eggs were decreased. The mortality was also significantly decreased at the time that administration of tylosin was finished and at 30 weeks of age was within acceptable levels. Post mortem evaluation confirmed the absence of previously gross lesions in primary organs. After the treatment, the flock recovered normally with a major improvement in health and production data and with no evidence of gross lesions.

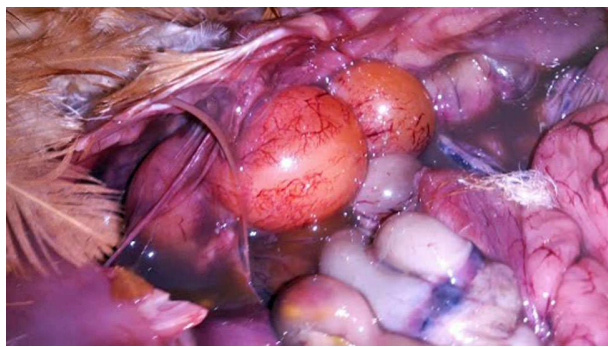


**Table 1.** Elisa results for MG, MS, ART, IBV and NDV carried out at 24 weeks of age

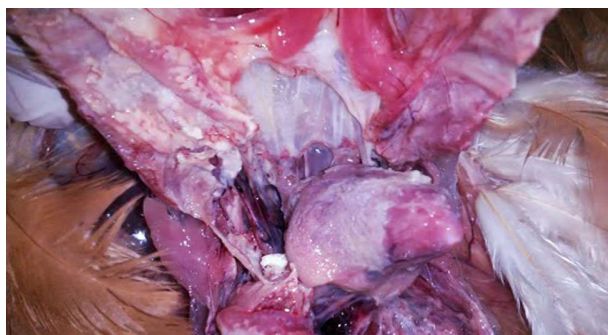Disease	No of samples	Neg/Sus/Pos	Mean titer	Min-max titer	GMT	CV%
MG	16	0/0/16	3340	741-8509	2821	60
MS	16	0/0/16	10637	6209-15250	10316	25
ART	16	0/0/16	10646	2053-20367	9213	46
IBV	14	0/0/14	7514	4064-12539	7125	34
NDV	14	0/0/14	10596	6510-16596	10221	28



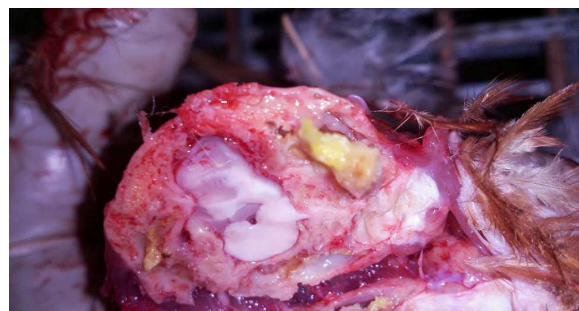**Fig. 2.** Prolapse



**Fig. 3.** Peritonitis



**Fig. 4.** Pericarditis-Airsacculitis of posterior thoracic air sacs



**Fig. 5.** Purulent inflammation of cranial bones



**Fig. 6.** Torticollis



**Fig. 7.** Discoloration of brown eggs

### 3. DISCUSSION

A clinical case of *Mycoplasma gallisepticum* and *Mycoplasma synoviae* in layers under field conditions was studied. *Mycoplasmas* remain one of the most important diseases in modern intensive poultry production causing great economic and health impact worldwide. The most economic effects of MG infections are well known and measures for the control and eradication are included in European Union legislation (EEC, 1990; CEU, 2009; EC, 2011) which prohibits intra-community trade in live poultry or hatching eggs derived from infected flocks. The economic impact of MS infection is less well understood but the organism is becoming more and more widespread in commercial birds, especially layers and broiler-breeders.

It is well known that the effects of *Mycoplasma* in uncomplicated infection may be minimal but are often enhanced in the presence of other respiratory pathogens such as pathogenic serotypes of *E. coli* and the viruses of ND and IBV, even vaccine strains (Ley, 2008). In this study, MG, *Escherichia coli*, *Pasteurella multocida* and ART were identified as factors that further complicated the infection with MS found at the time of arrival, whereas IBV and NDV seroconversion was a clear indication of proper vaccine implementation. The role of MS infection in the layer chicken industry is still unclear and under debate, but it is also well known that the effects of MS in uncomplicated infection may be minimal (Ley, 2008). This report is in agreement with the clinical findings of the present study up to 21 weeks of age, when obviously the increase of mortality coincided with the infection with MG and the other pathogens. Up to that time, no clinical findings were observed due to the presence of MS. The microbiological and serological results at 24 weeks of age revealed the co-infection and the severity of the disease was enhanced in the presence of the identified respiratory pathogens such as MG, ART and the presence of pathogenic serotypes of *E. coli* and *Pasteurella multocida*. Drual *et al.* (1992) attributed significant respiratory disease, synovitis and high mortality in commercial broilers to a dual infection of MS and an atypical strain of *Pasteurella gallinarum*. In addition, the higher MS titers compared to MG titers at 24 weeks of age indicated that the flock was infected with MG a few weeks later than MS. Unfortunately, due to NDV biosecurity measures was not able to identify the exact time of infection. In all such mixed infections the timing of the infections with respect

to each other and to the age of the bird may well influence the outcome and the disease severity. Furthermore it is apparent that there are more complex interactions between some pathogens whereby a mixture of three agents could cause more severe respiratory disease than any two of them combined. MG infection in chickens with *E. coli* and respiratory vaccine viruses is one such example (Nakamura *et al.*, 1994).

The clinical inspection and necropsy revealed symptoms and gross lesions in agreement to those found in previous studies (Stipkovits and Kempf, 1996; Kleven and Ferguson-Noel, 2008). In addition, some of the infected laying hens appeared to exhibit neurological signs such as torticollis, due to purulent inflammation of cranial bones. Such conditions have been described in turkeys (Chin *et al.*, 1991), but description of such neurological signs is scarce in chickens. Although the *mycoplasma* infections, specially complicated with other pathogens, are associated with loss in egg production (Stipkovits and Kempf, 1996; Landman, 2013), the egg production in the present study was not influenced by the severity of the infection. Our data are in agreement with another study which found no association between MS infection and egg production (Mohammed *et al.*, 1987). A decrease in egg production was noted at 27 week of age which was attributed to a 2% drop of crude protein in layers feed, due to a shortage of soya and maize and subsequent replacement in the ratio with wheat and soya concentrated proteins. Nevertheless, the possibility of tylosin efficacy on retaining the high level of egg production by controlling *mycoplasma* infections should not be excluded.

The last few years, a novel eggshell pathology, characterized by an altered shell surface, thinning, increased translucency and cracks and breaks in the eggshell apex, has become increasingly common in layer flocks of various breeds in Netherlands (Feberwee *et al.*, 2009), in Italy (Catania *et al.*, 2010) and other countries (Ranck *et al.*, 2010; Strugnelli *et al.*, 2011). Eggshell Apex Abnormalities (EAA) are characterized by altered shell surface, shell thinning, increased translucency and the occurrence of cracks and breaks and has been induced or associated with *M. synoviae* strains with oviduct tropism (Landman, 2013). In the present study, the infection with MS and complicated pathogens showed an increase in broken and misshapen eggs together with discoloration. The time of EAA increase coincided with the increase in egg production and concurrent infection of MG and other pathogens. Landman (2013) reported that the proportion of affected eggs varied between flocks, from a few percent up to 25% and after onset, abnormal eggs were produced throughout

the remainder of the laying period. Catania *et al.* (2010) found that approximately 1.3% to 1.8% of eggs with EAA resulted in great deal of breakage and spoilage of healthy eggs. In the present study, broken and misshapen eggs reached 3.7% per week and decreased to 1.98% per week in a period of 5 weeks after the tylosin treatment.

Different antimicrobials, especially antibiotics have been used to treat flocks infected with MG and MS in order to reduce severity of clinical signs, lesions and production losses (Bencina, 2005). One of the most widely used molecules in medication programs is tylosin, a macrolide antibiotic. There are several very recent studies that provide evidence of tylosin efficacy under field or experimental conditions. Treatment with tylosin, administered in the drinking water for 5 days, resulted in an immediate improvement of eggshell quality and egg weight in flocks of multi-age layer hens chickens housed on farms in Northern Italy with eggshell abnormalities in the apex of eggs under field conditions, (Catania *et al.*, 2010; 2009). De Gussem *et al.* (2013) concluded that in a challenge study, using a particular MG strain, tylosin proved to be efficacious in protecting against the detrimental consequences of the challenge and there were no significant differences in efficacy of the 35 mg kg<sup>-1</sup> BW group compared to the 100 mg kg<sup>-1</sup> BW group for most parameters, e.g., clinical respiratory score. Vereecken *et al.* (2013) investigated the sensitivity for tylosin of 10 European *Mycoplasma synoviae* strains, isolated out of clinical diseased poultry. The researchers calculated the MIC 90 and MIC 50 values (0.12 and <0.015 µg mL<sup>-1</sup> respectively) and found that tylosin can be used effectively under field conditions as a therapeutic for *Mycoplasma synoviae* infections in poultry. In the presented study and under severe field conditions, a dosage of 105 mg kg<sup>-1</sup> BW tylosin tartrate (Pharmasin® 100% WSG, Huvepharma) was efficient enough to reduce the severity of *Mycoplasma* infection. The choice to select the maximum dosage was imperative due to increased mortality and the risk of deterioration of the flock's health status. De Gussem *et al.* (2013) stated that "there are important differences in official registered dosage across countries and even more important are the inconsistencies in actual given dosages that can be found all over the world. These differences in actually used dosages cannot solely be attributed to regional differences in susceptibility of MG to tylosin. This means that either under dosing or overdosing, or both are a real problem". Therefore, more research is needed under field conditions in order to establish a dosage that would be efficient and, at the same time, cost effective.

## 4. CONCLUSION

In conclusion, *Mycoplasma* spp causes severe health and production problems in layers. Tylosin tartrate treatment in right time and dosage under field conditions can be used to treat the disease, to improve egg shell quality, to increase average weight of eggs from treated birds and to improve production performances by reducing the economic losses linked to labor costs.

## 5. REFERENCES

- Bebear, C.M. and I. Kempf, 2005. Antimicrobial Therapy and Antimicrobial Resistance. In: *Mycoplasmas: Molecular Biology Pathogenicity and Strategies for Control*, Blanchard, A. and G. Browning, (Eds.), CRC Press, ISBN-10: 0849398614, pp: 535-568.
- Bencina, D., 2005. *Mycoplasma* infections. Proceedings of XVIth International Congress of the World Veterinary Poultry Association, Aug. 22-26, Istanbul, Turkey, pp: 99-109.
- Bradbury, J.M. and C. Morrow, 2008. Avian *Mycoplasmas*. In: *Poultry Diseases*, Pattison, M., P.F McMullin, J. Bradbury and D. Alexander (Eds.), Saunders Elsevier, Philadelphia, USA., ISBN-10: 0702028622, pp: 220-234.
- Bradbury, J.M., L. Stipkovits, J. Biro, G. Czifra and A. Feberwee *et al.*, 2005. Workshop of European *Mycoplasma* Specialists-Diagnostic problems associated with testing day-old birds. *World's Poultry Sci. J.*, 61: 355-357.
- Catania, S., D. Bilato, F. Gobbo, A. Granato and C. Terregino *et al.*, 2010. Treatment of eggshell abnormalities and reduced egg production caused by *Mycoplasma synoviae* infection. *Avian Dis.*, 54: 961-964. PMID: 20608549
- Catania, S., D. Bilato, F. Gobbo, L. Iob and R.A.J. Nicholas, 2009. Isolation of *Mycoplasma synoviae* in eggshell apex abnormality in laying hens flock: Economic impact and drug management. Proceedings of 15th International Congress of the World Veterinary Poultry Association, Nov. 8-12, Marrakesh, Morocco, pp: 131-131.
- CEU, 2009. On animal health conditions governing intra-Community trade in and imports from third countries of, poultry and hatching eggs. Official J. EU.
- Chin, R.P., B.M. Daft, C.U. Meteyer and R. Yamamoto, 1991. Meningoencephalitis in commercial meat turkeys associated with *Mycoplasma gallisepticum*. *Avian Diseases*, 35: 986-993. PMID: 1786029.



- De Gussem, K., W. Depondt and M. Vereecken, 2013. Efficacy of tylosin tartrate at different dose levels in controlling *Mycoplasma gallisepticum* in a challenge model in chickens. Proceedings of XVIIIth International Congress of the World Veterinary Poultry Association, Aug. 19-23, Nantes, France, pp: 247-247.
- Druel, R., H.L. Shivaprasad, C.U. Meteyer, D.P. Shapiro and R.L. Parker, 1992. Severe mortality in broiler chickens associated with *Mycoplasma synoviae* and *Pasteurella gallinarum*. Avian Dis., 36: 803-807. PMID: 1417618.
- EC, 2011. Commission Decision of 1 April 2011 amending Annexes II to IV to Council Directive 2009/158/EC on animal health conditions governing intra-community trade in and imports from third countries of, poultry and hatching eggs. Official J. EU.
- EEC, 1990. Council Directive on animal health conditions governing intra-Community trade in and imports from third countries of, poultry and hatching eggs. Official J. EU.
- Feberwee, A., J.J. De Wit and W.J. Landman, 2009. Induction of eggshell apex abnormalities by *Mycoplasma synoviae*: Field and experimental studies. Avian Pathol., 38: 77-85. DOI: 10.1080/03079450802662772.
- Gross, W.B., 1990. Factors affecting the development of respiratory disease complex in chickens. Avian Dis., 34: 607-610. PMID: 2241688
- Kleven, H.S. and N. Ferguson-Noel, 2008. *Mycoplasma synoviae* Infection. In: Diseases of Poultry, Saif, Y.M., A.M. Fadly, J.R. Glisson, L.R. McDougald and L.K. Nolan *et al.* (Eds.), Blackwell Publishing, pp: 845-856.
- Landman, W.J.M. and A. Feberwee, 2004. Aerosol-induced *Mycoplasma synoviae* arthritis: The synergistic effect of infectious bronchitis virus infection. Avian Pathol., 33: 591-598. PMID: 15763728
- Landman, W.J.M., 2013. Is *Mycoplasma synoviae* outrunning *M. Gallisepticum*. Proceedings of 18th International Congress of the World Veterinary Poultry Association, Aug. 19-23, Nantes, France, pp: 29-34.
- Ley, H.D., 2008. *Mycoplasma gallisepticum* Infection. In: Diseases of Poultry, Saif, Y.M., A.M. Fadly, J.R. Glisson, L.R. McDougald and L.K. Nolan *et al.* (Eds.), Blackwell Publishing, pp: 807-834.
- Mohammed, H.O., T.E. Carpenter and R. Yamamoto, 1987. Economic impact of *Mycoplasma gallisepticum* and *M. synoviae* in commercial layer flocks. Avian Dis., 31: 477-482. PMID: 3675423
- Morrow, C.J., I.G. Bell, S.B. Walker, P.F. Markham and B.H. Thorp *et al.*, 1990. Isolation of *Mycoplasma synoviae* from infectious synovitis of chickens. Aus. Vet. J., 67: 121-124. PMID: 2375719
- Nakamura, K., H. Ueda, T. Tanimura and K. Noguchi, 1994. Effect of mixed live vaccine (Newcastle disease and Infectious bronchitis) and *Mycoplasma gallisepticum* on the chicken respiratory tract and on *Escherichia coli* infection. J. Comparative Pathol., 111: 33-42. PMID: 7962725
- Ranck, M.F., V. Schmidt, H.C. Philipp, M. Voss and J. Kacza *et al.*, 2010. *Mycoplasma synoviae*-associated eggpole shell defects in laying hens. Berl. Munch. Tierarztl. Wochenschr., 123: 111-118. PMID: 20329643
- Riddell, C, 1987. Avian Histopathology. University of Pennsylvania.
- Stipkovits, L. and I. Kempf, 1996. Mycoplasmosis in poultry. Rev. Sci. Tech., 15: 1495-1525. PMID: 9190023
- Strugnell, B.W., P. McMullin, A.M. Wood, R.A. Nicholas and R.M. Irvine *et al.*, 2011. Unusual eggshell defects in a free-range layer flock in Great Britain. Vet. Record, 169: 237-238. PMID: 21873397
- Vereecken, M., W. Depondt, M. Geerinckx, K. De Gussem and F. Gobbo *et al.*, 2013. Tylosin susceptibility of European *Mycoplasma synoviae* isolates collected out of diseased poultry in Europe. Proceedings of XVIIIth International Congress of the World Veterinary Poultry Association, Aug. 19-23, Nantes, France, pp: 260-260.