

Transoral reduction of irreducible posteriorly displaced odontoid fracture

Ting Wang · Bingfang Zeng · Jianguang Xu

Received: 11 March 2010/Revised: 21 July 2010/Accepted: 25 September 2010/Published online: 20 October 2010
© Springer-Verlag 2010

Abstract A case of type II odontoid fracture with irreducible posterior dislocation is presented. Cervical traction was employed but reduction could not be achieved with up to 15 kg of traction. The patient was treated with intraoperative transoral open reduction combined with anterior–posterior fixation. Rigid fixation and bone union were obtained without any complication in the 12-month follow-up. The patient has restricted C-spine rotation but no neck pain with movement. Transoral open reduction may be considered in patients with irreducible posteriorly displaced odontoid fracture.

Keywords Odontoid fracture · Posterior displacement · Transoral

Introduction

The treatment of type II odontoid fracture continues to be controversial. Nonoperative management of this fracture can lead to an increased incidence of nonunion, especially with the displaced fracture. Surgical treatment consists of stabilizing the fracture directly from the anterior route or indirectly from the posterior approach. If the odontoid process is displaced, it is imperative that adequate

reduction be achieved before operative fixation. Reduction may be performed with preoperative or intraoperative traction and manipulation of the neck under fluoroscopic guidance. Inability to reduce and realign the fracture is a relative contraindication to screw fixation [1]. While transoral close reduction of anteriorly displaced odontoid fracture has previously been described [2, 3], we present a case of utilizing transoral open reduction in the treatment of a completely posteriorly dislocated type II odontoid fracture. To our knowledge, such operative procedure has not been reported.

Case report

A 57-year-old man fell from hill and had his head stricken. He did not lose consciousness and presented with neck pain and numbness of both upper extremities. On admission, neurological examination revealed a motor deficit of his upper limbs with 4 of 5 motor strength. In addition, the patient had a decrease in light touch sensation bilaterally from the level of the fifth to seventh cervical nerve root. Cervical spine film after the accident revealed posterior displacement of the dens (Fig. 1). Subsequent computed tomography and sagittal reconstruction demonstrated a type II odontoid fracture that displaced completely posterior to the body of the axis (Fig. 2). MRI revealed the spinal cord edema at the upper cervical region (Fig. 3).

Gardner-Well tongs skull traction in supine position was applied to attempt a gradual reduction by continuous longitudinal traction. Portable radiographs of lateral cervical spine were taken immediately at the time of traction and then once a day to evaluate the degree of potential reduction. Anatomical realignment could not be achieved despite the application of traction weighting up to 15 kg a week

T. Wang
Department of Spinal Surgery, Affiliated Hospital,
Medical College of Qingdao University,
Jiangsu Road 16, Qingdao 266003, China

B. Zeng · J. Xu (✉)
Department of Orthopaedics,
Sixth People's Hospital (Affiliated to Shanghai Jiaotong
University), Yishan Road 600, Shanghai 200233, China
e-mail: xu.jianguang@hotmail.com

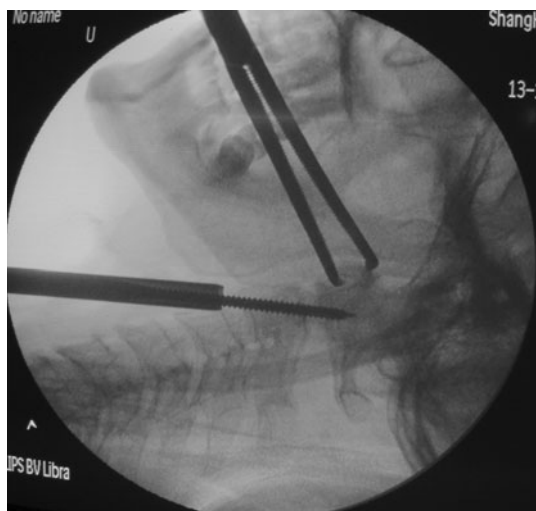


Fig. 4 While under the anterior traction via the Kocher clamp, odontoid screw was placed

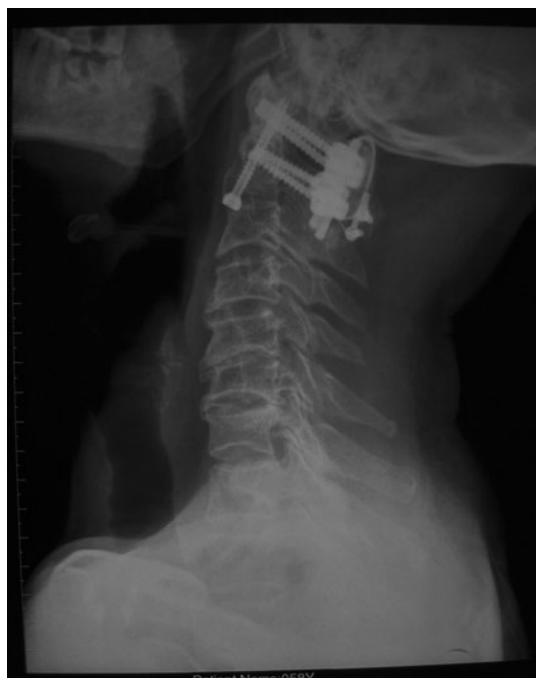

Fig. 5 Lateral cervical film at 12 months after surgery demonstrates a healed fracture and arthrodesis of the C1–C2

related to the procedure. A simple neck collar was used for 3 months. Cervical film at 12 months after surgery demonstrated a healed fracture and arthrodesis of the C1–C2 (Fig. 5).

Discussion

Axis fractures are relatively common traumatic cervical spine injuries [4]. Fractures of C2 represent 17% of acute

cervical spine fractures and odontoid fractures are the most frequent subgroup of axis fractures (55%) [5]. The majority of odontoid fractures are of type II and its treatment is controversial. Many factors, such as the age and the degree of displacement, have been cited as criteria that dictate operative procedure [6]. Hadley et al. [5] suggested that the degree of dens dislocation was the single most important factor when considering surgical therapy. Ekong et al. [7] suggested that patients with odontoid type II fractures with the dens dislocated 6 mm or more had the highest non-union rate, and early surgical fusion was recommended for acute fracture instability. In our case, the den was displaced completely posterior to the body of axis, surgical treatment was indicated.

A variety of options have been described for the operative management of type II odontoid fractures, including anterior odontoid screw fixation and posterior fusion methods with wire, cable, laminar clamp, transarticular screw and Harm C1–2 technique. Reduction of the odontoid fracture is precluding of these techniques. For non-displaced fracture, anterior odontoid screw might be a good choice. But for the displaced odontoid fracture, anatomic or nearly anatomic reduction before final fixation should be performed. For a slight displaced odontoid fracture, good alignment of C2 vertebral body with the odontoid process will be obtained with slight axial traction and appropriate manipulation of the neck under fluoroscopic guidance. For a completely dislocated odontoid fracture, especially accompanied with comminuted fracture, simple axial traction might not succeed. Adding the weight of traction might be used, but it endangers the spinal cord once over-traction occurs. Lewallen et al. [8] described respiratory arrest in four patients of which three died as a consequence of traction for posteriorly displaced odontoid fractures. To avoid over-distraction using skull traction, the lesion, such as occipital–cervical dislocation, Hangman fracture and odontoid fracture, in which all tension-resistant structures are potentially ruptured should be taken into consideration. For completely displaced odontoid fracture, the ligament around the craniocervical junction might be disrupted completely. How much weight of axial traction the instable craniocervical junction can sustain is unknown. As described in our case, completely dislocated odontoid fracture indicated severe atlantoaxial ligamentous disruption. So we abolished skull traction for close reduction after the traction weight up to 15 kg.

Posterior displacement of the odontoid after fracture occurs less frequently than does anterior displacement. Lewallen et al. [8] suggested that anatomic reduction might not be possible for the posteriorly displaced odontoid fracture and prolonged attempts to gain reduction were not advisable. After failure of close reduction, if we try to perform open reduction and fixation only from posterior

approach, it would carry high risk of spinal cord injury for the posteriorly dislocated odontoid fracture because the fractured odontoid cannot be manipulated directly. The spinal cord will be injured between the dislocated odontoid fragment and posterior arch of the atlas when we perform posterior reduction. Reduction of displaced odontoid fracture from anterior transoral approach is under direct vision and it might lower the risk of spinal cord injury. Giving up reduction and fixing the displaced odontoid fracture in situ is unacceptable because of late neurological deficit. So, transoral open reduction of the dislocated odontoid fragment was considered.

The failure of traction reduction might be due to the presence of communicated bone fragment at the junction of the dens and body of the axis. So, the hematoma and bone debris between the fracture fragments was removed before reduction. Without debridement of the fractured site, attempting to reduce the displaced odontoid fracture from posterior approach might be difficult. Because the odontoid fracture is posteriorly dislocated and there is no atlas fracture, we believe that the transverse ligament is intact. So, reduction can be accomplished by anterior traction of anterior tubercle via the Kocher clamp. After getting good alignment via the transoral reduction, we put an anterior odontoid screw to avoid the loss of reduction. Posterior fixation and fusion was considered because of the extreme instability of C1,2. So, the anterior odontoid screw was used as a temporal fixation and it reduced the risk of fatal injury to the spinal cord when turning the patient around for posterior operation. Because the completely displaced odontoid fracture indicates severe instability of C1,2 and a single anterior odontoid screw might not be strong enough to get a good bony fusion, posterior fixation and fusion was considered. After the anatomic reduction and anterior–posterior fixation, a healed fracture and arthrodesis of the C1–C2 was obtained at the 6-month follow-up. After the bone union, the restricted C-spine rotation is one shortage of our procedure. Another choice was that we had performed a temporary posterior fixation according to Harms

and removed the internal instrument after 1-year follow-up providing a CT-documented solid anterior fusion, the rotation C1/C2 would have been restored.

In the present case, we are able to successfully restore anatomic alignment using transoral open manipulation. There are two reports of transoral close manipulation of anteriorly dislocated type II odontoid fracture [2, 3] and no case report about the transoral open reduction of posteriorly displaced odontoid fracture. Our method might be an alternative choice for the irreducible posteriorly dislocated type II odontoid fracture that fails of close manipulation.

Conflict of interest None of the authors has any potential conflict of interest.

References

1. Geisler FH, Cheng C, Poka A, Brumback RJ (1989) Anterior screw fixation of posteriorly displaced type II odontoid fractures. *Neurosurgery* 25:30–38
2. Elias WJ, Ireland P, Chaddock JB (2006) Transoral digitally manipulated reduction of a ventrally displaced Type II odontoid fracture to aid in screw fixation. Case illustration. *J Neurosurg Spine* 4:82
3. Piedra MP, Hunt MA, Nemecek AN (2009) Anterior screw fixation of a dislocated type II odontoid fracture facilitated by transoral and posterior cervical manual reduction. *Acta Neurochir (Wien)* 151:1309–1313
4. Hadley MN, Sonntag VKH (1987) Acute axis fractures. *Contemp Neurosurg* 9:1–6
5. Hadley MN, Browner C, Sonntag VK (1985) Axis fractures: a comprehensive review of management and treatment in 107 cases. *Neurosurgery* 17:281–290
6. Dunn ME, Seljeskog EL (1986) Experience in the management of odontoid process injuries: an analysis of 128 cases. *Neurosurgery* 18:306–310
7. Ekong CE, Schwartz ML, Tator CH, Rowed DW, Edmonds VE (1981) Odontoid fracture: management with early mobilization using the halo device. *Neurosurgery* 9:631–637
8. Lewallen RP, Morrey BF, Cabanela ME (1984) Respiratory arrest following posteriorly displaced odontoid fractures. *Clin Orthop Relat Res* 188:187–190