

Cervical and transdiaphragmatic paraxiphoid thoracoscopy in dogs: evaluation of respiratory response and blood pressure

Toracoscopias cervical e paraxifóide transdiafragmática em cães: aplicação de técnica e avaliação da resposta respiratória e pressão sanguínea

Rogério Luizari Guedes^I João Pedro Scussel Feranti^{II} Fabiane Reginatto dos Santos^{III}
Gustavo Brambatti^{IV} Fernando Variani Tomazzoni^{IV} Marília Teresa de Oliveira^{II}
Maurício Veloso Brun^V Fernando Wiecheteck de Souza^{II}

ABSTRACT

This study evaluated the cervical and transdiaphragmatic thoroscopic approaches regarding their implementation, intrathoracic evaluation and application of a chest tube, using the treatment of pneumothorax as an experimental model. After injection of 20ml kg⁻¹ of air per hemithorax, thoracoscopy was made by transdiaphragmatic paraxiphoid or cervical positions. After cavity examination, a thoracic drain was inserted using the surgical site to drain the pneumothorax. The cardiorespiratory function and arterial blood gas were measured during time of evaluation. The cavity examination allowed visualizing the aspect and function of intrathoracic structures. There were no significant differences between the two approaches when comparing the measurements made in each period evaluated. Both enabled intracavitary exploration and application of thoracic drain. Cervical access shows viability, but resulted in the death of two patients, and it not recommended as a substitute for the latter in the insertion of thoracic drains in dogs.

Key words: canine, chest tube, pneumothorax, video-surgery.

RESUMO

Este estudo avaliou os acessos toracoscópicos cervical e paraxifóide em relação à sua aplicação, avaliação intratorácica e colocação de dreno torácico, utilizando o tratamento de pneumotórax como modelo experimental. Após a injeção de 20ml kg⁻¹ de ar por hemitórax, a toracoscopia foi realizada pelas técnicas cervical ou paraxifóide transdiafragmática. Após a exploração da cavidade, foi inserido um dreno torácico utilizando o acesso cirúrgico para drenar o pneumotórax. A função cardiorrespiratória e a gasometria arterial foram aferidas durante o tempo de avaliação. A exploração da cavidade permitiu visualização do aspecto e função das estruturas

intratorácicas. Não houve diferenças significativas entre os dois acessos quanto aos dados aferidos em cada período de avaliação. Ambos permitiram exploração intracavitária e aplicação do dreno torácico. O acesso cervical demonstra viabilidade, porém resultou na morte de dois pacientes, e não é recomendado como substituta à paraxifóide transdiafragmática para a aplicação de drenos torácicos em cães.

Palavras-chave: canino, dreno torácico, pneumotórax, videocirurgia.

INTRODUCTION

Thoracoscopy is indicated for the general exploration of the thoracic cavity in cases of trauma, pleural effusion, pericardial effusion, spontaneous pneumothorax, intrathoracic masses, primary pulmonary disease, lung lobe torsion, detection of vascular abnormalities and for procedures such as lung biopsy, lobectomy, pericardiectomy, ligation of patent ductus arteriosus and thymectomy (POTTER & HENDRICKSON, 1998; DE ZOPPA et al., 2001). Thoracoscopy is also recommended in the placement of drains as it contributes to a better spatial orientation for the location of masses and abscesses, improving the safety of the procedure (VACHON & FISCHER, 1998).

Among the thoracoscopy methods that have been described, there are the cervical, intercostal and transdiaphragmatic paraxiphoid methods

^IPrograma de Pós-graduação em Ciências Veterinárias, Universidade Federal do Paraná (UFPR), Rua Carlos de Campos, 59/23B, 97105-900, Curitiba, PR, Brasil. E-mail: rogerioguedes@veterinario.med.br. Autor para correspondência.

^{II}Programa de Pós-graduação em Medicina Veterinária, Universidade Federal de Santa Maria (UFSM), Santa Maria, RS, Brasil.

^{III}Programa de Pós-graduação em Medicina Veterinária, Universidade Federal do Rio Grande do Sul (UFRGS), Porto Alegre, RS, Brasil.

^{IV}Médico Veterinário Autônomo, Caxias do Sul, RS, Brasil.

^VDepartamento de Clínica de Pequenos Animais, UFSM, Santa Maria, RS, Brasil.

(BASSO et al., 2010). The same authors assert that the transdiaphragmatic paraxiphoid method is useful for partial pericardiectomy procedures in patients with pericardial effusion. The transdiaphragmatic approach has an advantage over other approaches as it allows ample exploration of the thoracic cavity in both hemithoraces as well as optimal visualization of the pulmonary hilum, mediastinum and ventral structures of the thorax (POTTER & HENDRICKSON, 1998; PIGATTO et al., 2008), whereas the intercostal approach only allows for the exploration of the corresponding hemithorax, therefore causing a delay in the identification of lesions that are located in the contralateral hemithorax (BASSO et al., 2010). The cervical approach is not commonly used: it is recommended to be used in association with the intercostal approach to facilitate procedures in the cranial mediastinum (POTTER & HENDRICKSON, 1998). As it has been little studied in dogs, the actual applications, advantages and disadvantages of this approach have not yet been defined.

This study aimed to comparatively evaluate the cervical and transdiaphragmatic paraxiphoid approaches in order to evaluate the capacity of organs and structures and the diagnosis of changes in the thoracic cavity. It has also evaluated the application of a chest tube through the surgical sites, during the treatment of an induced pneumothorax in dogs, and the viability of cervical thoracoscopy as technique.

MATERIAL AND METHODS

In total, 12 healthy adult dogs of mixed breeds, with an average weight of 9.62 ± 2.99 kg, were used in the study. They were obtained from the Central Vivarium from the Universidade of Passo Fundo. After clinical evaluation, the animals were housed in kennels, where they were fed with a commercial diet and had water *ad libitum*. The experiment was divided into 3 stages: the 1st was the induction of pneumothorax, the 2nd was the treatment of pneumothorax with cavity evaluation by both approaches and the 3rd was the postoperative evaluation.

In the 1st stage, the animals were pre-medicated with midazolam (0.5 mg kg^{-1} , intramuscularly [IM]) and morphine sulfate (0.5 mg kg^{-1} , IM). After 15 minutes, anesthesia was induced with propofol (4.0 mg kg^{-1} , intravenously [IV]) and maintained with isoflurane vaporized in oxygen at 100% in a semi-closed circuit, with assisted breathing. Thirty minutes before the surgical procedure, ampicillin sodium (22 mg kg^{-1}) was administered intravenously. Subsequently, a peripheral venous

catheter (18G) was placed in the right jugular vein of each animal; the access was heparinized and fixed to the skin in a Chinese finger trap suture with 3-0 mono nylon for the measurement of central venous pressure (CVP). The mean arterial pressure (MAP) was obtained by the catheterization of the femoral artery, which was connected to an aneroid manometer with the aid of a surgical approach to identify and puncture the vessel in question. The animals underwent pneumothorax with a 21-gauge scalp needle in the 7th intercostal space (ICS) in both hemithoraces. With the aid of a 60ml syringe coupled with a valve, 20 ml kg^{-1} of air was inserted by each hemithorax.

In the 2nd stage, the animals were placed in dorsal recumbency, and a skin incision of approximately 0.5cm was cut between the xiphoid appendix and the costal arch (paraxiphoid technique; GI) or transversally to the 1st rib (cervical approach; GII;) for the introduction of the 6mm diameter cannula. This technique, also known as thoracic inlet access is briefly described by POTTER & HENDRICKSON (1998), and it's the only description found during this study for this kind of approach in dogs. The cutaneous incision and insertion of portals are made in midway between the trachea medially and the medial aspect of the first rib (Figure 1). The trocar, after a brief subcutaneous access, was directed to a randomly selected hemithorax (GI: three dogs on the left side and three on the right; GII: four dogs on the left and two on the right). The exploration of the corresponding hemithorax was performed with a 5mm diameter and 0° rigid endoscope (Karl Storz Endoskope, Baden-Württemberg, Germany), piercing the mediastinal membrane for contralateral exploration. Subsequently, a thoracic drain (10Fr) was positioned through the portal, without the valve, in the hemithorax corresponding to the site of the incision. The portal was removed, the puncture site was effaced at the skin level and the drain was fixed with 3-0 mono nylon in a horizontal mattress suture pattern. At the end of the procedure, the negative thoracic pressure was restored through a 60ml syringe and valve, with the chest drain being removed in a single movement. At the end of the procedure, the animals received ketoprofen (2 mg kg^{-1} , subcutaneously [SC], *simel in die* [SID]) for three days.

The 3rd stage of the experiment, performed 15 days after the 1st procedure, aimed to explore the thoracic cavity and evaluate the condition of the diaphragmatic and cervical defects by intercostal thoracoscopy on the side where the portal was introduced. After the end of the procedure, the animals received ketoprofen as mentioned above, and

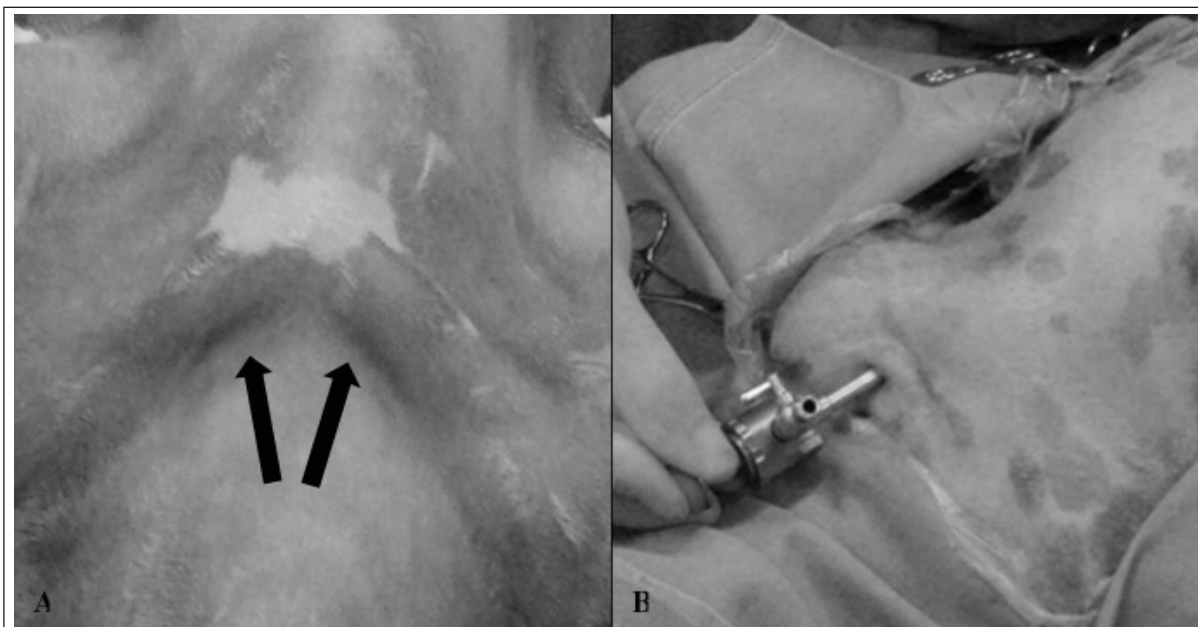


Figure 1 – Positional aspects of cervical approach. A indicates the cranial aspect of thoracic inlet and the insertion points/directions to access left and right hemithoraces (arrows), dorsal to the first ribs. In B, a 5mm portal after his successful placement in the left thoracic inlet.

after the removal of the skin sutures (7th day), they were offered for adoption.

Central venous pressure and MAP measurements were taken during stage 1 and 2, immediately prior to pneumothorax induction (M1), immediately after pneumothorax induction (M2), after introducing the trocar (M3), after inserting the drain (M4) and after draining the cavity and restoring negative pressure (M5). During these instances, the heart rate (HR) and respiratory rate (RR) were also measured. Blood was collected for gas analysis from the femoral artery immediately prior to administration of the pre-anesthesia medication (M0) and also at M1, M3 and M5. During M3, the intrathoracic pressure was measured by a mechanical laparoscopic insufflator (Astus Medical, São Paulo, Brazil).

The CVP values in cmH₂O were converted as defined by AGUIAR et al. (2004) to identify the relationship between the peripheral catheter and central venous catheter. The changes in the physiological parameters for HR and RR, the blood gas values and the surgical time were also correlated, producing a Student's t-test p value below 0.05 between groups. For the individual evaluation of each group, an ANOVA test was carried out, followed by the Tukey test; both required p values below 0.05 to declare significance.

RESULTS

The surgical times in the 2nd stage were 18.8 ± 3.3 minutes for GI and 22.5 ± 13.6 minutes for GII. The longer time in GII was associated with the need for thoracotomy in the 4th ICS in 2 animals in an attempt to treat hemorrhage that was caused by the introduction of the trocar, which progressed to the death of both patients. There were no other complications associated with the thorascopies of either group and both approaches tested in this experiment allowed for the application of the thoracostomy tube through the access incision.

As for the examination of the thoracic cavity, movement of the pulmonary hilum and lobes was observed in 91.7% of patients (the evaluation of these structures was not possible in one patient from GII), and cervical thoracoscopy enabled better visualization of the cranial lobes. Furthermore, both approaches produced a defined outline of the heart surface and allowed for the identification of the auricles, atria and ventricles on the side accessed. The hemidiaphragm was better evaluated by the cervical approach. The cranial and caudal venae cavae, aorta, internal thoracic vein and artery, subclavian arteries, intercostal vessels and nerves were structures that were also visualized during the exploration. There were no communications between the hemithoraces through the mediastinal pleura. In addition, there was a certain

difficulty in rupturing the pleura in the dogs from GII because of the relative parallelism that the mediastinal pleura assumes in relation to the rigid endoscope, which made the counter traction for tissue rupture difficult. The intrathoracic pressure measured in M3 reached 1.0 ± 0 mmHg in GI and 0.5 ± 0.87 mmHg in GII.

In the animals evaluated, there were no significant differences between the two approaches when comparing the blood gas levels (Table 1), CVP, MAP, HR or RR (Table 2) in each period evaluated. When the techniques were evaluated separately, a significant difference ($P < 0.05$) was measured in GII for CVP between M1-M5 and M2-M3-M4. At no time during the experiment did the dogs maintain a MAP above 90 mmHg, a value that is considered normal for the species (HASKINS, 2000). The RR in GII animals was below baseline from M2, but not with statistical significance.

After anesthesia, non-compensated acidosis was observed in both groups, characterized by a statistically significant ($P < 0.001$), gradual decrease in arterial pH and an increase of pCO_2 in M1.

After 15 days, the intercostal thoracoscopy enabled the evaluation of the thoracic cavity in the hemithorax access. In all animals, there was a complete closing of the diaphragmatic and cervical wounds. The transdiaphragmatic approach showed the absence of occlusion of the mediastinal pleura defect in two dogs. In another dog from the same group, there were adhesions on the diaphragm.

DISCUSSION

The difficulty to visualize contralateral hemithoraces was more noticeable in cervical thorascopies, where the movement of the endoscope was more restricted than in the transdiaphragmatic. The proximity of the pulmonary cranial lobes and the width of the base of the heart offered some risks for this maneuver. Therefore, pleural rupture was always obtained caudally to the base of the heart. The authors believe that the visualization of cavity structures, especially with the cervical approach, could be improved with the use of a 30° or 45° instead of a 0° endoscope, which not only reduces the field of view, but also leads to greater mechanical stress of the endoscope, resulting in possible damage to the instrument (POTTER & HENDRICKSON, 1998).

In addition to the visualized tissues in this study, at least not precisely, it's possible to observe the right costocervical vein, the right azygos vein and the frenic nerve (PIGATTO et al., 2008). This shows the need for the surgeon to be better familiarized with both approaches, which will naturally occur with the expansion of casuistry by overcoming the learning curve.

The non significant differences between the two approaches when comparing the blood gas levels, CVP, MAP, HR or RR shows that both approaches, in the absence of vascular or organic lesions, advance with similar hemodynamic conditions.

The CVP mean values remained between -2 and 4 cmH₂O, normal levels for the specie (RAISER, 2005). The decrease in M1 and M5 from both groups may be explained by the increased

Table 1 - Values of arterial blood gasometry: pH, partial pressure of carbon dioxide (pCO_2), partial pressure of oxygen (pO_2), bicarbonate ion (HCO_3), total carbon dioxide (CO_2 Total), base excess (ExBase), oxygen saturation (SatO₂), sodium ion (Na), potassium (K) ion and lactate, measured on different moments [before preanesthetic medication (M0), immediately prior to pneumothorax induction (M1), after introducing the trocar (M3) and after draining the cavity and restoring negative pressure (M5)] in the transdiaphragmatic paraxiphoid (GI) and cervical (GII) thorascopies.

	M0		M1		M3		M5	
	GI	GII	GI	GII	GI	GII	GI	GII
pH	$7.48 \pm 0.23a$	$7.37 \pm 0.01a$	7.21 ± 0.04	7.19 ± 0.06	7.15 ± 0.07	7.16 ± 0.05	7.12 ± 0.05	7.15 ± 0.06
pCO_2	$32.95 \pm 4.84a$	$36.12 \pm 3.37a$	51.23 ± 10.31	62.8 ± 8.46	62.13 ± 12.9	59.13 ± 19.82	62.42 ± 10.02	65.42 ± 12.09
pO_2	96.4 ± 21.21	73.22 ± 12.35	416.5 ± 48.51	434.85 ± 81.44	295.5 ± 131.72	303.33 ± 151.02	336.78 ± 143.32	340.18 ± 121.14
HCO_3	19.61 ± 3.29	$20.76 \pm 2.23a$	20 ± 4.26	23.01 ± 1.55	21.25 ± 5.21	20.67 ± 6.9	19.76 ± 3.34	21.96 ± 3.64
CO_2 Total	20.63 ± 3.37	21.88 ± 2.3	21.58 ± 4.57	24.95 ± 1.61	23.15 ± 5.49	22.3 ± 7.47	21.7 ± 3.58	23.96 ± 3.91
ExBase	1.71 ± 5.11	3.32 ± 1.98	7.95 ± 3.74	6.2 ± 2.35	8.58 ± 5.38	9.21 ± 6.44	10.56 ± 3.48	8.14 ± 3.58
SatO ₂	96.86 ± 1.21	93.44 ± 3.47	99.88 ± 0.04	99.85 ± 0.08	99.41 ± 0.53	99.1 ± 1.33	99.32 ± 1.08	99.66 ± 0.28
Na	142.16 ± 11.16	144 ± 6.96	146.66 ± 4.03	150.33 ± 3.61	146.8 ± 34.71	149.67 ± 3.78	147.6 ± 3.13	149.8 ± 3.9
K	3.81 ± 0.62	4.04 ± 0.34	2.93 ± 0.6	3.38 ± 0.31	3.016 ± 0.71	3.02 ± 1.07	2.98 ± 0.7	3.12 ± 0.23
Lactate	2.76 ± 0.69	2.7 ± 0.53	1.56 ± 0.33	1.67 ± 0.63	1.46 ± 0.41	1.37 ± 0.78	1.06 ± 0.31	1.42 ± 0.72

Table 2 – Values of central venous pressure (CVP), mean arterial pressure (MAP), heart rate (HR) and respiratory rate (RR) measured on different moments [immediately prior to pneumothorax induction (M1), immediately after pneumothorax induction (M2), after introducing the trocar (M3), after inserting the drain (M4) and after draining the cavity and restoring negative pressure (M5)] in the transdiaphragmatic paraxiphoid (GI) and cervical (GII) thoracoscopies.

	----- CVP (cmH ₂ O) -----		----- MAP (mmHg) -----		----- HR (BPM) -----		----- RR (MPM) -----	
	GI	GII	GI	GII	GI	GII	GI	GII
M1	0,61±1,58	0,06±1,02 ^a	69,33±21,30	74,5±35,47	109,83±15,05	119,16±5	13,33±3,27	11,33±6,41
M2	1,16±1,34	1,42±1,46	70,66±16,38	68,5±28,61	99,66±14,67	105,16±13,11	12±7,59	6,66±8,7
M3	1,23±1,57	2,67±3,17	80,66±14,73	73,66±25,43	110,8±39,35	106,66 ± 8,55	17,66±12,42	8,66±3,01
M4	1,16±1,47	2,51±2,31	71±10,86	69±21	113,16±10,52	101,83±12,84	16±10,73	6,66±5,47
M5	1,24±1,17	0,11±2,30 ^a	75±9,10	65,66±23,37	113,16±14,62	101±16,59	12,66±12,24	5±6,16

^a Significantly different for the group ($p < 0,05$).

intrathoracic pressure that is produced by the induced pneumothorax in M2 and that was treated in M5, the interval in which a circulatory obstacle was created, restricting venous flow and creating greater pressure on the vessels.

The registered hypotension could be related to the use of pre-anesthetic drugs (OTERO, 2003) and the use of propofol, as the drugs used could induce vasodilation and reduce the contractility of the myocardium (STOELTING & HILLIER, 2006). Furthermore, the occurrence of cardiac tamponade and the reduction of pulmonary compliance associated with the induced pneumothorax are not ruled out.

The RR was complemented by assisted ventilation after M3, trying to avoid damage to the lung regions in a state of atelectasis preventing hypoxia with more severe hemodynamic changes, such as respiratory acidosis. Despite not showing this type of decompensation, the same tactic was used for GI animals to prevent the aforementioned complications.

The balance of the established acidosis could be achieved via mechanical ventilation to reduce $p\text{CO}_2$ or with an increase in the serum concentration of the bicarbonate ion (DAY, 2002); however, in this study, respiratory support did not allow for the restoration of normal conditions by this process. There was a physiological response with an increase of bicarbonate, but normal values were maintained during the entire experimental period in both groups because it was an acute insult that did not require reparation by the kidneys as occurs in chronic cases of respiratory acidosis (DAY, 2002).

The most common surgical complications in thoroscopic procedures are similar to those described for the closed chest drainage technique (FOSSUM, 2007) and consist of hemorrhage, lung injury and persistent pneumothorax, which occur during the

introduction or removal of devices (POTTER & HENDRICKSON, 1998; LINDER, 2002). The injuries that caused the death of two patients occurred in the cranial mediastinal region at the base of the heart. It is believed that the complication may have occurred at the start of the procedure by the passage of the portal, but the hemorrhage was only apparent after the drainage of air (M5). To perform this approach with one portal, authors believed that an ideal maneuver to insert the trocar is to pass laterally and closer to the thoracic wall and ribs, avoiding vases like internal thoracic vein. Due to the soft tissue extension to pass through, the surgeon needed to apply more strength than transdiaphragmatic approach, possibly dislocating the trocar medially which promotes the mediastinal lesions.

The deaths reported stress the risks of the cervical approach that stem from “blind” puncture in a region that is abundant in important structures and has reduced dimensions. The cervical approach is preferably used as a secondary measure, with the portal being introduced under direct visualization (POTTER & HENDRICKSON, 1998). Because of the death of 33% of the animals, it is suggested that the open introduction of the portal via cervical approach must be better studied in this species. In this study, the high occurrence of vascular access lesions points out the need for thorough training and knowledge of regional anatomy.

The diagnostic failure is attributed partly to the restricted field of view that is available with this approach, which may have hindered the visualization of the bleeding site, and mostly to the position of the cannula, which may have damaged and compressed the vessel during thoracoscopy as there was no evidence of severe bleeding during the exam. In the necropsy, it was not possible to identify exactly which vessels had been damaged (due the tissue lesions promoted by the trans-

operatory attempts to stop the bleeding and *post-mortem* changes), identifying only that the hemorrhage occurred in the cranial mediastinal region. The most important vessels found in this region are the internal and external jugular veins, axillary vein, costocervical, deep cervical, vertebral, left brachiocephalic veins and the cranial vena cava, in addition to the left common carotid, axillary, costocervical trunk, dorsal scapular, deep cervical and superficial cervical arteries (POPESKO, 1997). The risk of injury is related to the internal thoracic vein and artery, brachiocephalic trunk and common carotid artery (POTTER & HENDRICKSON, 1998), however, in both dogs, these vessels were intact. The anatomical complexity of the cranial thoracic region, which is abundant in important structures, and the reduced space for the introduction of the portal, compounded by the lack of experience of the surgeon with the cervical approach, are associated with the occurrence of the complications described. Given these findings, it is considered that cervical thoracoscopy could be associated with the occurrence of severe vascular lesions when done as unique or as first portal.

The intercostal approach is satisfactory for cavity exploration (BECK et al., 2004). Such as an anterior study (PIGATTO et al., 2008), the occurrence of complete healing of diaphragmatic and cervical wounds without the need for sutures, so 6mm punctures was performed. Adherences on the diaphragm were not related to the possible access point that was identified during cavity exploration. This finding could be related to previous changes in the procedures and may not have been observed during the 2nd stage due to a lesion that was not seen during the transdiaphragmatic access.

CONCLUSION

The transdiaphragmatic paraxiphoid and cervical approaches did not show differences between dogs subjected to pneumothorax under the described conditions with respect to the physiological parameters evaluated. Both techniques allow for the examination of the thoracic cavity according to the anatomical configuration of each region using the access wounds for application of a thoracic drain which was conducted successfully. However, due the deaths (33%) presented for the cervical approach, as a primary access, made it a non-safe procedure, and it not recommended as a substitute for transdiaphragmatic paraxiphoid technique in the insertion of thoracic drains and exploration of cavity in dogs.

BIOETHICS AND BIOSECURITY COMMITTEE APPROVAL

This study was submitted to the Research Ethics Committee of Universidade of Passo Fundo (UPF-RS), following the ethical principles of the Colégio Brasileiro de Experimentação Animal (COBEA). Tried and approved in case n. 211/2009.

REFERENCES

- AGUIAR, E.S.V. et al. Mensuração de pressão venosa central por meio de cateteres venosos central e periférico: comparação entre os valores obtidos e elaboração de índice de correção. **Ciência Rural**, v.34, p.1827-1831, 2004. Available from: <http://www.scielo.br/scielo.php?pid=S0103-84782004000600025&script=sci_arttext>. Accessed: Feb. 6, 2012. doi: 10.1590/S0103-84782004000600025.
- BASSO, P.C. et al. Biópsia pulmonar incisional por toracoscopia paraxifóide transdiafragmática com dois portais em cães. **Pesquisa Veterinária Brasileira**, v.30, p.566-572, 2010. Available from: <<http://www.scielo.br/pdf/pvb/v30n7/a10v30n7.pdf>>. Accessed: Mar. 10, 2013. doi: S0100-736X2010000700010.
- BECK, C.A.C. et al. Toracoscopia nas hérnias diafragmáticas: estudo experimental em cães. **Ciência Rural**, v.34, p.1849-1855, 2004. Available from: <http://www.scielo.br/scielo.php?pid=S0103-84782004000600029&script=sci_arttext>. Accessed: Feb. 6, 2012. doi: S0103-84782004000600029.
- DAY, T.K. Blood gas analysis. **Veterinary Clinics of North America: Small Animal Practice**, v.32, p.1031-1048, 2002. Available from: <<http://www.sciencedirect.com/science/article/pii/S0195561602000359>>. Accessed: Feb. 6, 2012. doi: 10.1016/S0195-5616(02)00035-9.
- DE ZOPPA, A.L.V. et al. Toracoscopia em equinos: técnica e emprego como método de avaliação da cavidade pleural. **Ciência Rural**, v.34, p.825-830, 2001. Available from: <http://www.scielo.br/scielo.php?script=sci_arttext&pid=S0103-84782001000500014>. Accessed: Feb. 6, 2012. doi: 10.1590/S0103-84782001000500014.
- FOSSUM, T.W. Surgery of the lower respiratory system: pleural cavity and diaphragm. In: _____. **Small animal surgery**. 3.ed. St. Louis: Mosby, 2007. p.896-929.
- HASKINS, A.J. Table III: approximate normal ranges for common measurements in dogs and cats. In: TILLEY, L.P.; SMITH, F.W.K. **The five-minute veterinary consult**. Philadelphia: Lippincott Williams & Wilkins, 2000. CD-ROM.
- LINDER, A. Video-assisted thoracoscopic surgery for the treatment of pneumothorax. In: **Websurg – World electronic book of surgery**. 2002. Accessed: Out. 2, 2010. Online. Available from: <http://www.websurg.com/ref/Video-assisted_thoracoscopic_surgery_for_the_treatment_of_pneumothorax-ot02en239a.htm>.
- OTERO, P. Administração epidural e espinhal de analgésicos. In: _____. **Dor – Avaliação e tratamento em pequenos animais**. São Caetano do Sul: Interbook, 2005. p.192-211.
- PIGATTO, J. et al. Produção de pneumotórax em cães e manejo por toracoscopia paraxifóide transdiafragmática. **Ciência Rural**,

v.38, p.2210-2217, 2008. Available from: <http://www.scielo.br/scielo.php?script=sci_arttext&pid=S0103-84782008000800019>. Accessed: Fev. 6, 2012. doi: 10.1590/S0103-84782008000800019.

POPESKO, P. **Atlas de anatomia topográfica dos animais domésticos**. Manole: São Paulo, 1997. V.3.

POTTER, L.; HENDRICKSON, D.A. Therapeutic video-assisted thoracic surgery. In: FREEMAN, L.J. **Veterinary endosurgery**. St. Louis: Mosby, 1998. p.169-187.

RAISER, A.G. Choque. In: RABELO, R.C.; CROWE Jr, D.T. **Fundamentos de terapia intensiva veterinária em pequenos**

animais – Condutas no paciente crítico. Rio de Janeiro: L.F. Livros, 2005. p.71-104.

STOELTING, R.K.; HILLIER, S.C. Nonbarbiturate intravenous anesthetic drugs. In: _____. **Handbook of pharmacology and physiology in anesthetic practice**. 2.ed. Philadelphia: Lippincott Williams & Wilkins, 2006. p.151-178.

VACHON, A.M.; FISCHER, A. Thoracoscopy in the horse: diagnostic and therapeutic indications in 28 cases. **Equine Veterinary Journal**, v.30, p.467-475, 1998. Available from: <<http://onlinelibrary.wiley.com/doi/10.1111/j.2042-3306.1998.tb04521.x/pdf>>. Accessed: Fev. 6, 2012. doi: 10.1111/j.2042-3306.1998.tb04521.x.