

Use of the Vertebral Heart Score in Coughing Dogs with Chronic Degenerative Mitral Valve Disease

Carlo GUGLIELMINI^{1)*}, Alessia DIANA²⁾, Marco PIETRA²⁾, Morena DI TOMMASO¹⁾ and Mario CIPONE²⁾

¹⁾Department of Veterinary Clinical Sciences, University of Teramo, Viale Crispi 212, I-64100 Teramo,

²⁾Veterinary Clinical Department, University of Bologna, Via Tolara di Sopra 50, I-40064 Ozzano Emilia (BO), Italy

(Received 18 April 2008/Accepted 4 August 2008)

ABSTRACT. The objective of the present study was to evaluate the usefulness of the vertebral heart score (VHS) in coughing dogs with chronic degenerative mitral valve disease (MVD). Survey thoracic radiographs of 90 dogs with a history of cough and clinical and echocardiographic evidence of MVD were evaluated by 2 independent observers. The observers were asked to first determine the origin of the cough as cardiac, non-cardiac or mixed and then to measure the VHS. Agreement regarding diagnosis of the origin of cough was obtained ($\kappa=0.64$) in 69 dogs. Of these 69 dogs, 28 (41%), 32 (46%) and 9 (13%) had a cough of cardiac, non-cardiac and mixed origin, respectively. The dogs with a cough of non-cardiac origin had a significantly lower VHS (mean \pm SD, 11 ± 0.9) compared with those of dogs with a cough of cardiac or mixed origin (12.8 ± 1 and 12.9 ± 0.9 , respectively). Receiver operating characteristic curve analysis showed that a $VHS \leq 11.4$ is fairly accurate for exclusion of a cough of cardiac origin in dogs with MVD. The results indicate that the VHS may be an additional tool for differentiating the origin of cough in dogs with MVD.

KEY WORDS: canine and feline, cardiology, echocardiography, heart, radiology.

J. Vet. Med. Sci. 71(1): 9–13, 2009

The term “cardiac cough” is frequently used in the clinical setting as well as in veterinary textbooks to define the origin of cough in dogs affected by cardiac disorders. Chronic degenerative mitral valve disease (MVD) with associated mitral regurgitation (MR) is the most common canine cardiovascular disease [5] and coughing is the most common presenting complaint in dogs with MVD [10]. This symptom may be related to different pathophysiological mechanisms secondary to cardiac dilatation and dysfunction caused by MVD. Among the main consequences of MVD are dorsal elevation and compression of the trachea and/or dorsal elevation of the left main stem bronchus by the dilated left atrium, pulmonary congestion and pulmonary interstitial and/or alveolar transudate secondary to increased pulmonary capillary pressure [10]. The above mechanisms may be responsible for cough in dogs with MR [2]. Nevertheless, cough can be a consequence of different respiratory disorders that may concurrently affect dogs with MVD [1]. In particular, the same dogs (i.e., small or middle-sized, aged dogs) most commonly affected by MVD are predisposed to some respiratory disorders leading to cough (e.g., chronic bronchitis, lower airway collapse and interstitial lung disease) [12, 21, 24]. Thus, both respiratory and cardiac diseases may contribute to cough in some cases.

The vertebral heart score (VHS) is a method for objectively evaluating the dimensions of the cardiac silhouette in thoracic radiograms and was first described by Buchanan and Bücheler in the dog [7]. Using this method, the cardiac long and short axis are measured on the lateral thoracic view and are then compared with the thoracic spine. The VHS is

the vertebral scale sum of the long and short axes, each measured caudally from the cranial edge of the 4th thoracic vertebra. Normal VHS values have been established for cats [16] and ferrets [26] as well as for different canine breeds [4, 15, 20]. Furthermore, this method is largely employed for radiographic evaluation of the heart in dogs with different cardiovascular disorders. The aim of the present study was to evaluate whether the results of cardiac measurements using the VHS are a useful indicator of the origin of cough in dogs with MVD.

MATERIAL AND METHODS

The medical records of dogs referred for cardiovascular examination to the Veterinary Clinical Department, University of Bologna, during a 3-year-period were reviewed. Animals were included in the protocol when evaluated for the concurrent presence of cough and a systolic murmur best heard over the mitral area. In each dog, diagnosis of MVD was confirmed based on the results of physical examination and complete echocardiographic (two-dimensional real time and M-mode) and echo-Doppler examination. Patients were excluded from the study if they were receiving any antitussive agent (i.e., bronchodilators, antitussive, anti-inflammatory and/or expectorant drugs) and/or drugs aimed to ameliorate cardiovascular function (i.e., positive inotropes, diuretics and/or vasodilators). Availability of thoracic radiographs in 2 orthogonal views was an additional inclusion criterion, and dogs with poor quality thoracic radiographs were excluded from the study.

Thoracic radiographs were evaluated by two independent observers, one experienced cardiologist (CG), observer A, and one experienced radiologist (MC), observer B. Both observers were informed about the echocardiographic diag-

* CORRESPONDENCE TO: GUGLIELMINI, C., Department of Veterinary Clinical Sciences, University of Teramo, Viale Crispi 212, I-64100 Teramo, Italy.
e-mail: cguglielmini@unite.it

nosis of MVD but were blinded regarding quantitative echocardiographic and echo-Doppler data (i.e., degree of left atrial and ventricular enlargement or quantitative evaluation of mitral regurgitation). The following radiographic parameters were evaluated: shape and size of the overall cardiac silhouette and of the left side of the heart; size of pulmonary vessels; position, shape and luminal diameter of the trachea and left main stem bronchus; presence and characteristics of any bronchial, interstitial and/or alveolar pattern; and distribution of body fat. Furthermore, VHS was calculated on lateral thoracic radiographs according to the method described by Buchanan and Bücheler [7]. Finally, each observer was asked to identify the origin of cough in each subject according to the following classification scheme: dogs showing compression of the left main stem bronchus by a dilated left atrium, pulmonary vein congestion and/or any interstitial or alveolar pattern suggesting cardiogenic pulmonary oedema were diagnosed as having cough of cardiac origin (Group C); dogs without any of the abovementioned radiographic signs were diagnosed as having cough of non-cardiac origin (Group NC); dogs showing the concurrent presence of signs referable to a respiratory origin of cough (e.g., narrowing of the tracheal and/or main bronchial lumen secondary to lower airway collapse, thickening of the bronchial walls and increased radiopacity of the lung fields not attributable to cardiogenic pulmonary oedema) and a cardiac origin of cough (see above) were diagnosed as having cough of mixed origin (Group M).

All statistical analyses were performed using statistical software packages (Statistica for Windows 4.5, StatSoft Inc., and MedCalc®, version 7.3). The values are presented as means \pm standard deviation (SD). Agreement between the observers' interpretation of the origin of cough was measured using the kappa statistics. Further statistical tests were performed on the data (i.e., mean of the VHS values for the two observers) obtained from the dogs for which agreement regarding diagnosis was obtained. In particular, ANOVA was applied to compare values of VHS among the three groups of dogs, and a post hoc test (Least Significant Difference test) was used to point out which group was statistically different. The ability of VHS to distinguish dogs with a cough of cardiac origin (Groups C and M) from those with a cough of non-cardiac origin was evaluated by receiver operating characteristic (ROC) curve analysis. The optimal discriminatory value was identified as the VHS with a combined sensitivity and specificity closest to 100%.

For all the statistical tests, values of $p < 0.05$ were considered significant.

RESULTS

Inclusion and exclusion criteria were met by 90 dogs, 68 (76%) males and 22 (24%) females. Among the dog breeds included, there were 36 mixed-breed dogs, 11 Yorkshire terriers, 9 miniature poodles, 7 English setters, 7 miniature schnauzers, 5 miniature pinschers, 4 shih tzus, 2 drathaars and 2 Bologneses. There was also one specimen for each of

the following breeds: spitz, Chihuahua, Epagneul Breton, Irish terrier, dachshund, basset hound and fox terrier. The mean age was 11.3 ± 2.2 years (range: 5–17 years), and the mean weight was 9.5 ± 6.2 kg (range: 1.5–27 kg).

Good quality right lateral and ventro-dorsal or dorso-ventral thoracic radiographic views were available for all subjects. Both inspiratory and expiratory lateral thoracic radiographic views were available for 36 dogs. Examples of lateral thoracic radiographs of dogs belonging to group C (Fig. 1), NC (Fig. 2) and M (Fig. 3) are provided. According to the evaluations of observer A, 30/90 (33%) dogs had a cough of cardiac origin, 41/90 (46%) dogs had a cough of non-cardiac origin and 19/90 (21%) dogs had a cough of

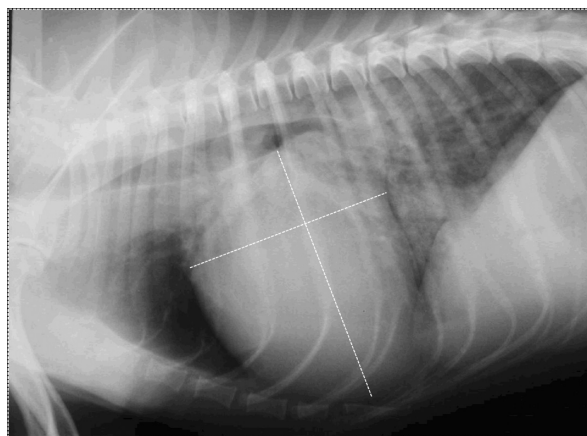


Fig. 1. Right lateral thoracic radiograph of a dog with chronic degenerative mitral valve disease and a cough of cardiac origin. Dotted lines indicate the method of measurement of the vertebral heart score (VHS). Notice the enlarged cardiac silhouette (VHS=12.9) and pulmonary veins associated with a perihilar interstitial-alveolar pattern indicating pulmonary oedema.

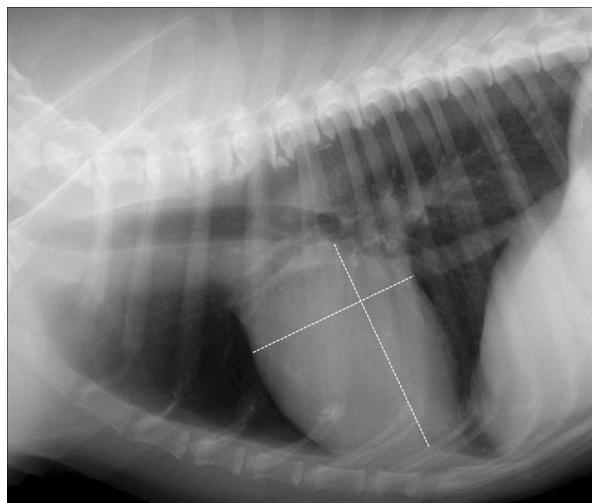


Fig. 2. Right lateral thoracic radiograph of a dog with chronic degenerative mitral valve disease and a cough of non-cardiac origin. Dotted lines indicate the method of measurement of the vertebral heart score (VHS). Notice the moderate and diffuse bronchial pattern with a normal cardiac silhouette (VH =9.9).

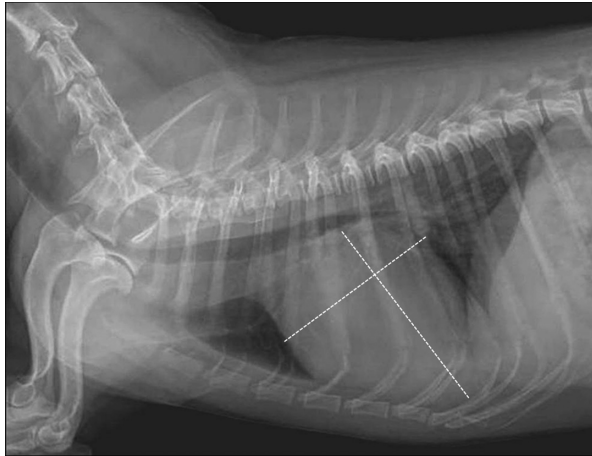

Fig. 3. Right lateral expiratory thoracic radiograph of a dog with chronic degenerative mitral valve disease and a cough of mixed origin. Dotted lines indicate the method of measurement of the vertebral heart score (VHS). Notice the enlarged cardiac silhouette (VHS=11.7) with compression of the left main stem bronchus associated with moderate tracheal collapse at the thoracic inlet.

mixed origin. According to the evaluations of observer B, 39/90 (43%) dogs had a cough of cardiac origin, 35/90 (39%) dogs had a cough of non-cardiac origin and 16/90 (18%) dogs had a cough of mixed origin. Agreement between the observers regarding identification of the origin of cough was obtained in 69 dogs, 28 (41%) from group C, 32 (46%) from group NC and 9 (13%) from group M. The kappa statistic showed an overall substantial agreement ($\kappa=0.64$) between observers. In particular, a higher percentage of concordance (i.e., the percentage ratio between dogs with concordant diagnosis and all dogs allocated in each group by the two observers) was observed for groups C and NC (68% and 73%, respectively) compared with group M (35%). All data regarding diagnosis of cough and the calculated VHSs of the two observers for each group of dogs are reported in Table 1. The VHS of the dogs of group NC (11 ± 0.9) was significantly lower compared with the VHSs of the dogs of groups C (12.8 ± 1 , $p < 0.001$) and M (12.9 ± 0.9 , $p < 0.001$). No statistical difference was found

between the VHSs of the dogs of groups C and M ($p=0.64$).

The general accuracy of VHS for distinguishing the two groups (C + M from NC), as determined by calculating the area under the ROC curve, was 0.92 ± 0.03 (standard error; Fig. 4). The cut-off value of VHS (11.4) showed the best equilibrium between sensitivity (92%) and specificity (75%) for exclusion of a cough of cardiac origin.

DISCUSSION

Different drugs can be employed for treatment of dogs with MR due to MVD including diuretics (e.g., furosemide and spironolactone), vasodilators (e.g., hydralazine and angiotensin-converting enzyme inhibitors) inodilators (i.e., pimobendan) and antitussive agents [10]. The above drugs may ameliorate clinical signs and improve both quality and quantity of life in symptomatic but not asymptomatic canine MVD [3, 13, 17]. Thus, precise evaluation and staging of dogs with MVD is mandatory before administering any therapeutic treatment. Cough and dyspnoea are frequently observed in dogs with MVD and may either suggest an advanced stage of the disease or may be due to concurrent respiratory disorders. Recent studies have investigated the usefulness of determining plasma concentrations of some biomarkers (i.e., endothelin-1, B-type natriuretic peptide, atrial natriuretic factor and cardiac troponin I) for differentiation between a cough of cardiac and respiratory origin and/or dyspnoea in the dog [9, 23, 27]. Evaluation of the above biomarkers may be useful for quick categorisation of dogs with cough and/or dyspnoea in an emergency context, but thoracic radiography still remains one of the higher yield diagnostic tests for evaluation of combined cardiorespiratory function in dogs with MVD [2, 9].

The VHS is a method for objectively determining the size of the canine cardiac silhouette on thoracic radiographs [6]. This technique is particularly useful for evaluating the cardiac enlargement associated with eccentric hypertrophy due to volume overload [14, 22]. It is easy to perform, and the measurements are relatively independent of both patient-related (i.e., thoracic conformation, gender and side of lateral recumbency) and operator-related variables (i.e., level of experience) [6, 11]. The mean VHS of all groups of dogs in the present study was greater than the upper limit for nor-

Table 1. Radiographic diagnosis and vertebral heart scores (VHS, mean \pm SD) calculated by two independent observers (A and B) for 90 coughing dogs with mitral regurgitation. Dogs with cough of cardiac origin (C); dogs with cough of non-cardiac origin (NC); dogs with cough of mixed origin (M)

Groups	Observer A		Observer B		Agreement	
	No (%)	VHS	No (%)	VHS	No (%)	VHS
C	30 (33%)	12.6 ± 1	39 (43%)	12.6 ± 1	28 (41%)	$12.8 \pm 1^*$
NC	41 (46%)	11.1 ± 0.9	35 (39%)	11.1 ± 0.9	32 (46%)	11 ± 0.9
M	19 (21%)	12.4 ± 1	16 (18%)	12.2 ± 1.1	9 (13%)	$12.9 \pm 0.9^*$
Total	90		90		69 ^{a)}	

a) A statistical difference was only displayed for the 69 dogs for which the observers made agreeing diagnoses.

* $p < 0.001$ vs. NC group.

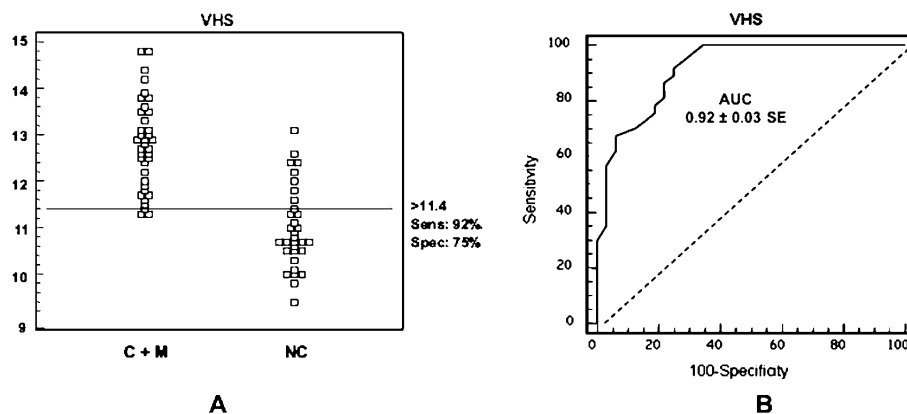


Fig. 4. Vertebral heart scores (VHS) of 69 coughing dogs with mitral valve disease. A: The horizontal line indicates the cut-off point with the best separation (minimal false negative and false positive results) between dogs with a cough of cardiac (C) or mixed (M) origin and those with a cough of non-cardiac (NC) origin. The sensitivity and specificity of VHS at the cut-off value of 11.4 were 92% and 75%, respectively. B: Receiver operating characteristic curve illustrating the accuracy of the VHS for differentiating between the above two groups of dogs.

mal heart size in most canine breeds ($VHS \leq 10.5$) [6]. Values of VHS higher than the above upper limit have been reported for boxers (11.6 ± 0.8), cavalier king Charles spaniels (10.6 ± 0.5), Labrador retrievers (10.8 ± 0.6), whippets (11.0 ± 0.5) and greyhounds (10.5 ± 0.1) [4, 15, 20], but no boxers, cavalier king Charles spaniels, Labrador retrievers, whippets or greyhounds were included in the present study. The mean VHS of our dogs with cardiac or mixed origin of cough was significantly higher compared with the mean VHS of the dogs with a non-cardiac origin of cough. In a study comparing 50 dogs with different cardiac disorders with dogs with other thoracic diseases or no clinical signs of cardio-respiratory disease, a VHS over 10.7 was a moderately accurate sign of cardiac disease [14]. In the above study, some dogs that normally exhibit a higher VHS (i.e., three boxers and four Labrador retrievers) were recruited, and cardiac disorders not associated with eccentric hypertrophy (e.g., cardiac dysrhythmias and aortic stenosis) were also included. The present study was carried out on dogs affected by MVD and MR, a typical volume overload cardiac disease. Therefore, the majority of dogs in the present study had a VHS above the general upper limit of normality (i.e., 10.5). In the above dogs, a $VHS \leq 11.4$ was fairly accurate for exclusion of a cough of cardiac origin with a sensitivity of 92% and a specificity of 75%. However, some dogs (8/32) without reliable radiographic signs of a cough of cardiac origin had a $VHS > 11.4$. Combined right- and left-sided cardiac enlargement was likely responsible for the increased VHS in these subjects.

Radiographic identification of the origin of cough obviously relies on subjective interpretation of different roentgen signs. In the present study, to avoid subjective interpretation, two independent, experienced observers were asked to formulate their diagnoses, and the kappa coefficient of agreement was calculated. The value of kappa reflects the proportion of agreement beyond that expected

by chance between two different observers [8]. Considering only subjects with agreement in relation to diagnosis of the origin of cough, a little more than half of the dogs with MVD in the present study, including those with a cough of either cardiac or mixed origin, showed roentgen signs compatible with a cough of cardiac origin (i.e., compression of the left main stem bronchus by the dilated left atrium and/or signs referable to pulmonary vein congestion and cardiogenic pulmonary oedema). By contrast, 46% of the coughing dogs with MVD did not show any radiographic evidence of a cough of cardiac origin. Recognition of a cough of cardiac origin on thoracic radiographs is arguably easy, since it is based on identification of specific and clearly recognisable roentgen signs. In the absence of the above signs, cough may reasonably be considered to be of non-cardiac origin. Determining the precise origin of non-cardiac cough requires additional diagnostic tests, namely bronchoscopy and laboratory tests [1, 25], but this was beyond the scope of the present study. Our preliminary goal was indeed to rule in or rule out cough of cardiac origin in dogs affected by MVD. Once a cough of cardiac origin could reasonably be excluded, differentiation, for example, between an upper (e.g., laryngitis) or lower airway disorder (e.g., chronic bronchitis) as the inciting cause of cough was considered insignificant. Nevertheless, recognition of roentgen signs suggestive of a concurrent cough of non-cardiac origin was useful for those dogs in the present study classified as having a cough of mixed origin. In the above subjects, the availability of both an inspiratory and expiratory lateral view of the thorax was helpful for recognising dynamic conditions such as lower airway collapse [12]. Chest radiographs can detect tracheal collapse in 59% to 92% of cases [12, 18], while the accuracy of thoracic radiography in the diagnosis of canine chronic bronchitis is limited [19]. For these reasons, underestimation of dogs with a cough of mixed origin and, conversely, overestimation of those with

a cough of cardiac origin may have occurred, thus representing a limitation of the present study. However, it is unlikely that these pitfalls changed the percentage of dogs with a cough of non-cardiac origin. An additional indirect confirmation of the inherent difficulty in recognising dogs with a cough of mixed origin correlated with the lowest percentage of concordance between the observers for this group of subjects.

In conclusion, dogs with MVD and clearly recognizable radiographic signs of a cough of cardiac origin have a higher VHS compared with those with a cough of non-cardiac origin. A VHS ≤ 11.4 may reasonably exclude a cough of cardiac origin in dogs with MVD. However, some dogs with a cough of non-cardiac origin may have a VHS > 11.4 , and, therefore, it is not possible to discriminate the origin of cough above this limit based on the VHS alone.

REFERENCES

- Anderson-Wessberg, K. 2005. Coughing. pp 189–192. In: Textbook of Veterinary Internal Medicine-Disease of the Dog and Cat, 6th ed. (Ettinger, S.J. and Feldman, E.C. eds.), Elsevier Saunders, St. Louis.
- Atkins, C.E. 1994. Evaluation of cough in dogs with mitral valve insufficiency. *Comp. Cont. Educ. Pract. Vet.* **16**: 1547–1552.
- Atkins, C.E., Keene, B.W., Brown, W.A., Coats, J.R., Crawford, M.A., DeFrancesco, T.C., Edwards, N.J., Fox, P.R., Lehmkuhl, L.B., Luethy, M.W., Meurs, K.M., Petrie, J.P., Pipers, F.S., Rosenthal, S.L., Sidley, J.A. and Straus, J.H. 2007. Results of the veterinary enalapril trial to prove reduction in onset of heart failure in dogs chronically treated with enalapril alone for compensated, naturally occurring mitral valve insufficiency. *J. Am. Vet. Med. Assoc.* **231**: 1061–1069.
- Bavegems, V., Van Caelenberg, A., Duchateau, L., Sys, S.U., Van Bree, H. and De Rick, A. 2005. Vertebral heart size ranges specific for whippets. *Vet. Radiol. Ultrasound* **46**: 400–403.
- Buchanan, J. W. (1992) Causes and prevalence of cardiovascular disease. pp. 647–655. In: Kirk's Current Veterinary Therapy XI, Small Animal Practice (Kirk, R. W. and Bonagura J. D. eds.), Saunders, Philadelphia.
- Buchanan, J. W. 2000. Vertebral scale system to measure heart size in radiographs. *Vet. Clin. N. Am. Small Anim. Pract.* **30**: 379–393.
- Buchanan, J.W. and Bücheler, J. 1995. Vertebral scale system to measure canine heart size in radiographs. *J. Am. Vet. Med. Assoc.* **206**: 194–199.
- Chmura Kraemer, H., Periyakoil, V.S. and Noda, A. 2002. Kappa coefficients in medical research. *Stat. Med.* **21**: 2109–2129.
- DeFrancesco, T.C., Rush, J.E., Rozenski, E.A., Hansen, B.D., Keene, B.W., Moore, D.T. and Atkins, C.E. 2007. Prospective clinical evaluation of an ELISA B-type natriuretic peptide assay in the diagnosis of congestive heart failure in dogs presenting with cough or dyspnea. *J. Vet. Intern. Med.* **21**: 243–250.
- Häggsström, J., Kvart, C. and Pedersen, H.D. 2005. Acquired valvular heart disease. pp 1022–1039. In: Textbook of Veterinary Internal Medicine-Disease of the dog and cat, 6th ed. (Ettinger, S.J. and Feldman, E.C. eds.), Elsevier Saunders, St. Louis.
- Hansson, K., Häggström, J., Kvart, C. and Lord, P. 2005. Inter-observer variability of vertebral heart size measurements in dogs with normal and enlarged hearts. *Vet. Radiol. Ultrasound* **46**: 122–130.
- Johnson, L. 2000. Tracheal collapse. Diagnosis and medical and surgical treatment. *Vet. Clin. North Am. Small Anim. Pract.* **30**: 1253–1266.
- Kvart, C., Häggström, J., Pedersen, H.D., Hansson, K., Eriksson, A., Järvinen, A.K., Tidholm, A., Bsenko, K., Ahlgren, E., Ilves, M., Åblad, B., Falk, T., Bjerkås, E., Gundler, S., Lord, P., Wegeland, G., Adolfsson, E. and Corfitzen, J. 2002. Efficacy of enalapril for prevention of congestive heart failure in dogs with myxomatous valve disease and asymptomatic mitral regurgitation. *J. Vet. Intern. Med.* **16**: 80–88.
- Lamb, C.R., Tyler, M., Boswood, A., Skelly, B.J. and Cain, M. 2000. Assessment of the value of the vertebral heart scale in the radiographic diagnosis of cardiac diseases in dogs. *Vet. Rec.* **146**: 687–690.
- Lamb, C.R., Wikeley, H., Boswood, A. and Pfeiffer, D.U. 2001. Use of breed-specific ranges for the vertebral scale as an aid to the radiographic diagnosis of cardiac diseases in dogs. *Vet. Rec.* **148**: 707–711.
- Litster, A.L. and Buchanan, J.W. 2000. Vertebral scale system to measure heart size in radiographs of cats. *J. Am. Vet. Med. Assoc.* **216**: 210–214.
- Lombard, C.W., Jöns, O. and Bussadori, C.M. 2006. Clinical efficacy of pimobendan versus benazepril for the treatment of acquired atrioventricular valve disease in dogs. *J. Am. Anim. Hosp. Assoc.* **42**: 249–261.
- MacReady, D.M., Johnson, L.R. and Pollard, R.E. 2007. Fluoroscopic and radiographic evaluation of tracheal collapse in dogs: 62 cases (2001–2006). *J. Am. Vet. Med. Assoc.* **230**: 1870–1876.
- Mantis, P., Lamb, C.R. and Boswood, A. 1998. Assessment of the accuracy of thoracic radiography in the diagnosis of canine chronic bronchitis. *J. Small Anim. Pract.* **39**: 518–520.
- Marin, L.M., Brown, J., McBrien, C., Baumwart, R., Samii, V.F. and Couto C.G. 2007. Vertebral heart size in retired racing greyhounds. *Vet. Radiol. Ultrasound* **48**: 332–334.
- Mckiernan, B.C. 2000. Diagnosis and treatment of canine chronic bronchitis. *Vet. Clin. North Am. Small Anim. Pract.* **30**: 1267–1278.
- Nakayama, H., Nakayama, T. and Hamlin, R.L. 2001. Correlation of cardiac enlargement as assessed by vertebral heart size and echocardiographic and electrocardiographic findings in dogs with evolving cardiomegaly due to rapid ventricular pacing. *J. Vet. Intern. Med.* **15**: 217–221.
- Prošek, R., Sisson, D.D., Oyama, M.A. and Solter, P.F. 2007. Distinguishing cardiac and noncardiac dyspnea in 48 dogs using plasma atrial natriuretic factor, B-type natriuretic factor, endothelin, and cardiac troponin-I. *J. Vet. Intern. Med.* **21**: 238–242.
- Reinero, C.R. and Cohn, L.A. 2007. Interstitial lung diseases. *Vet. Clin. North Am. Small Anim. Pract.* **37**: 937–947.
- Rozanski, E.A. and Rush, J.E. 2004. Acute and chronic cough. pp 42–45. In: Respiratory Disease in Dogs and Cats (King L.G. ed.), Saunders, St. Louis.
- Stepien, R.L., Benson, K.G. and Forrest, L.J. 1999. Radiographic measurement of cardiac size in normal ferrets. *Vet. Radiol. Ultrasound* **40**: 606–610.
- Tessier-Vetzel, D., Tissier, R., Chetboul, V., Carlos, C., Nicolle, A., Benbaron, D., Dandrieux, J., Thoulon, F., Carayon, A. and Pouchelon, J.L. 2006. Diagnostic and prognostic value of endothelin-1 plasma concentrations in dogs with heart and respiratory disorders. *Vet. Rec.* **158**: 783–788.