

Pathological Analysis of Bone Fractures in Race Horses

Mikihiro KANEKO, Masa-aki OIKAWA, and Toyohiko YOSHIHARA

Pathology Division, Equine Research Institute, Japan Racing Association, 27-7 Tsurumaki 5-chome, Setagaya-ku, Tokyo 154, Japan

(Received 19 May 1992/Accepted 28 October 1992)

ABSTRACT. Pathomorphological analysis was performed on fractured bones of 470 race horses. The most common fracture site was the limb (98% of cases), and the majority of fractures were intra-articular. Focal osteochondral lesions consisting of osteochondrosis, osteonecrosis and osteosclerosis were observed frequently in fractured and non-fractured bones. In the fractured bones, the lesions frequently appeared in the vicinity of the fractured site. Under the influence of antecedent osteochondrosis from the young stage, osteosclerotic and osteonecrotic lesions may have been induced by immoderate exercise and localized ischemia. These morbid conditions may be important as local predisposing factors for bone fracture because the osteosclerotic and osteonecrotic lesions may contribute to diminished resistance to torsion and shearing forces.—**KEY WORDS:** bone fracture, pathology, race horse.

J. Vet. Med. Sci. 55(1): 181–183, 1993

Fractures in race horses are a major problem confronting the racing industry [4, 5]; however, a thorough analysis of race horse fractures in Japan has not been reported.

Previously, our report [6] suggested the fractures were pathologic. The present report provides pathological data related to bone fractures in race horses in the Japan Racing Association (JRA).

Materials were obtained from 307 males, 8 geldings and 155 females and the age of the horses ranged between 2.5 and 7.5 years. All horses were euthanatized as soon as possible after suffering a fracture, and were subsequently necropsied at the Equine Research Institute of the JRA. Pathological examinations were performed on 927 bones from 470 race horses and all sliced bone tissues (3–5 mm in thickness) were fixed in 10% buffered formalin solution, and softradiographs (type SRO-M50, Soken Co., Ltd., Tokyo, Japan) were taken at 40 kvp, 5 mA, and 80 seconds. Following softradiographs the bone slices were decalcified in a rapid decalcification reagent containing highly concentrated hydrochloric acid (R.D.O. solution, Du Page Kinetic Laboratories, Inc., U.S.A.), and embedded in paraffin, sectioned, and stained with Ehrlich's hematoxylin and eosin.

The major fracture site was the forelimb (87% of cases) with most of the remainings located in the hindlimb (12%). Other fracture sites included the skull and vertebral column. The majority of forelimb fractures were intra-articular, i.e., the bones of the carpus and metacarpophalangeal joint. Fractures in the hindlimbs also occurred more frequently within the joint, for example the tarsal joint and metatarsophalangeal joint.

The types of fractures in the 927 bones examined consisted of transverse fracture (31.3%), splintered or comminuted (30.7%), longitudinal (18.8%), chip or slab (10.0%), and miscellaneous (9.2%) (Table 1).

Macroscopically, longitudinal fractures of the third metacarpal bone and third metatarsal bone were located obliquely from the distal end toward the diaphysis. Most fractures occurred in conjunction with focally thickened and discolored articular cartilage, focal brittle and reddish-brown subchondral bone, and osteosclerosis of the surrounding cancellous bone at the distal articular region. Similar findings were also observed in the chip and slab fractures of the dorsal carpal region and in the transverse fractures at the midbody to the distal portions of the proximal sesamoid bones.

Table 1. Materials of fractured bone for pathological examination

Bone / Type	I ^{a)}	II ^{b)}	III ^{c)}	IV ^{d)}	V ^{e)}	Total
Skull & vertebra	12	0	27	17	6	62
Radius	13	0	8	5	0	26
Radial carpal bone	11	0	0	16	1	28
Intermediate carpal bone	5	0	0	15	1	21
Third carpal bone	15	0	0	9	1	25
Third metacarpal bone	3	52	7	12	3	77
Third metatarsal bone	0	41	5	3	0	49
Proximal sesamoid bone	6	42	146	27	1	232
Proximal phalanx	13	11	2	61	2	89
Others	15	29	95	120	69	308
Total	93	175	290	285	84	927
%	10.0	18.8	31.3	30.7	9.2	100

a) Chip or slab fracture.

b) Longitudinal fracture.

c) Transverse fracture.

d) Splintered or comminuted fracture.

e) Others.

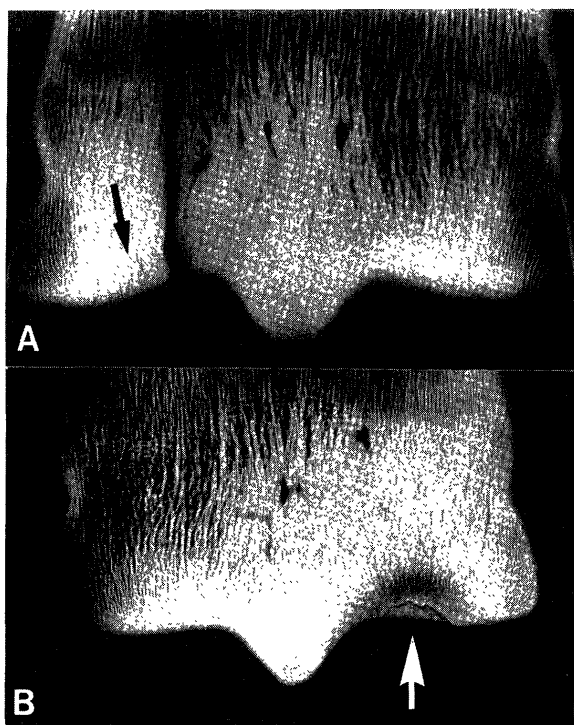


Fig. 1. Soft radiograms of frontal sections (3 mm thick) of the distal region of the third metacarpus (McIII). A: Fracture through area of osteosclerosis with radiolucent area (arrow) (2 year-7-month-old, male, 5 races). B: Proximal sesamoid fracture in left fore limb during race (5 year-2-month-old, male, 11 races). Focal osteosclerosis with radiolucent area (arrow).

The soft radiographic expressions of the gross lesions described above consisted of focal radiolucent areas with osteosclerosis in the adjacent bone beneath the articular cartilage (Fig. 1-A). Similar lesions were observed in the same regions of non-fractured bones (Fig. 1-B).

The incidence of radiolucent areas and osteosclerosis in both fractured and non-fractured bones were approximately 35% and 65%. There were no significant differences in the incidence of focal lesions between fractured and non-fractured bones, but the frequency appeared to increase depending on age, number of races run and period on races (Fig. 2).

Microscopically, the radiolucent area was composed of necrotic bone tissue at the osteochondral junction. The necrotic bone showed eosinophilic homogeneous debris and enlarged lacunae which contained no osteocytes. Fibrous tissue and chondrometaplasia were occasionally found surrounding the necrotic focus. The osteosclerosis consisted of hyperplasia of irregularly sized osteons with narrowing of the Haversian canals and alteration of bone collagen matrix, mosaic arrangement of the cement line, marked thickening of trabeculae, narrowing of the bone marrow cavity and congestion. Osteocytes, osteoblasts and osteoclasts within the osteosclerotic area were inactive. The arterioles within bone marrow cavities occasionally showed edematous fibrotic thickening of the walls. The fracture line ran in conjunction with the lesions

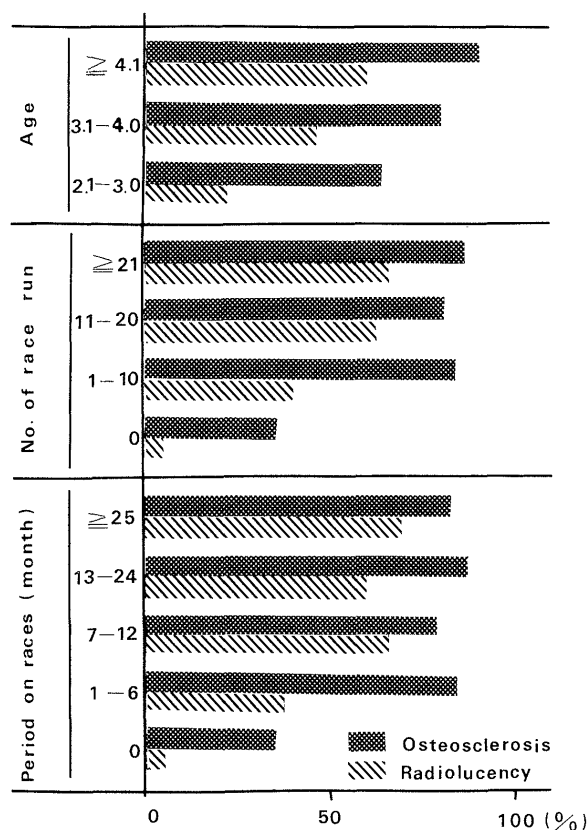


Fig. 2. The incidence of focal osteochondral lesions at the palmar aspects of the distal end of McIII and MtIII in both fractured and non-fractured bone.

described above (Fig. 3).

In the younger horses, the cartilage cells of the superficial tangential and radiate zones were arranged irregularly and were variable in size, and exhibited hydropic swelling. In the radiate and calcification zones, there was a thickening of articular cartilage accompanied by multinuclear chondrones, fissure formation and chondronecrosis with fibrosis (Fig. 4). However, the severity of subchondral osteosclerosis and osteonecrosis was not marked. In older horses, the articular cartilage showed fibrous scars in the superficial tangential and transitional zones. The chondronecrosis with fibrosis was infrequently observed in the radiate and calcification zone. In the immediate vicinity of the chondral lesions, the subchondral bone tissue showed marked osteonecrosis with surrounding fibrosis, chondrometaplasia and osteosclerosis.

The osteochondral lesions consisting of chondral lesions, osteosclerosis and osteonecrosis were similar to those in osteochondrosis reported by Hornof and O'Brien [3]. However, chondral lesions due to disturbance of an endochondral ossification appeared more obvious in younger horses with a short racing career rather than in older horses with a longer racing career. The microscopic differences between younger and older horses suggests that the osteonecrosis and osteosclerosis of the osteochondral lesions may be induced and exaggerated by progres-



Fig. 3. Area of osteosclerosis with osteonecrosis (arrow) from a 3 year-9-month-old horse with McIII longitudinal fracture during race (7 races). Border of the tissues on the right is fracture line. McIII, HE stain. $\times 26$.

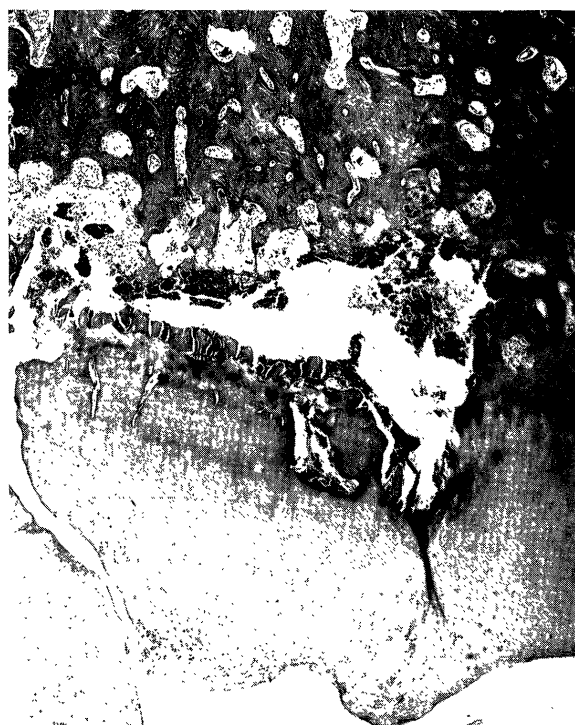

Fig. 4. The thickened articular cartilage shows a fissure, which has resulted in tissue separation. The subchondral bone tissues show destruction (necrosis), and the bone marrow cavities show narrowing and fibrosis (2 year-7-month-old, male, short racing history). McIII, HE stain. $\times 105$.

sive exercise [9, 10]. Additional factors may include localized hypoxia and/or ischemia caused by vascular alterations, under the existence of antecedent osteochondrosis. The fibrous scar of the articular cartilage and the surrounding fibrosis of the subchondral necrosis in older horses with longer racing careers indicate reparative changes as compensation for superficial erosions of articular cartilage and osteochondronecrosis. Because the increase in the severity of osteosclerosis appeared related to the number of races run, we suggest that osteosclerosis may be a reactive change for the osteonecrosis and load-bearing stress during progressive exercise. We speculate that the existence of chondrometaplasia and osteonecrosis may have been affected by hypoxia and ischemia due to circular disturbance in long-term.

Biomechanically, an osteosclerotic area has diminished resistance to torsion and shearing forces [8]. In addition, osteonecrosis in the subchondral area indicates that the structure of the osseous collagen fibers is altered, reducing bone tissue strength [8]. The lamellar orientation of the collagen fibers of the bone is suited for resisting mechanical load [1, 2].

Focal osteochondral lesions occurring in the immediate vicinity of a fractured area, may have induced the localized biomechanical disorders that resulted in the fracture reported by Krook and Maylin [7].

ACKNOWLEDGEMENT. We wish to thank Dr. Kipp Erickson, Department of Medicine, University of California, San Diego, for critical reading of this manuscript.

REFERENCES

1. Barbos, M. P. 1983. *Metab. Bone Dis. Rel.* 5: 309-315.
2. Boyde, A. 1983. *Metab. Bone Dis. Rel.* 5: 299-307.
3. Hornof, W. J. and O'Brien, T. R. 1980. *Vet. Radiology* 21: 161-167.
4. Jeffcott, L. B., Rossdale, P. D., Freestone, J., Frank, C. T., and Towers-Clark, P. F. 1982. *Equine Vet. J.* 14: 185-198.
5. Jones, D. G. C. 1975. *Vet. Rec.* 97: 193-197.
6. Kaneko, M., Kiryu, K., Oikawa, M., Kanemaru, T., Yamamoto, T., and Satoh, H. 1980. *Bull. Equine Res. Inst.* 17: 1-7.
7. Krook, L. and Maylin, G. A. 1988. *Cornell Vet. (Suppl. II)* 78: 1-133.
8. Rooney, J. R. 1969. pp. 140-143. In: *Biomechanics of Lameness in Horses*, 1st ed. Williams & Willkins Co., Baltimore.
9. Tomioka, Y., Kaneko, M., Oikawa, M., Kanemaru, T., Yoshihara, T., and Wada, R. 1985. *Bull. Equine Res. Inst.* 22: 22-29.
10. Yoshihara, T., Kaneko, M., Oikawa, M., Wada, R., and Tomioka, Y. 1989. *Jpn. J. Vet. Sci.* 51: 184-186.