

## The Dynamic Expression of Extracellular Matrix in the Bovine Endometrium at Implantation

Osamu YAMADA<sup>1,2</sup>, Jun-ichi TODOROKI<sup>3</sup>, Toru TAKAHASHI<sup>1</sup> and Kazuyoshi HASHIZUME<sup>1)\*</sup>

<sup>1</sup>Laboratory of Reproductive Biology and Technology, National Institute of Agrobiological Sciences, Ikenodai 2, Kukizaki, Inashiki-gun Ibaraki 305–8602, <sup>2</sup>Bio-oriented Technology Research Advancement Institution, Saitama, Saitama 331–8537 and <sup>3</sup>Kagoshima Prefectural Cattle Breeding and Development Institute, Oosumi, Kagoshima 899–8212, Japan

(Received 2 May 2001/Accepted 13 December 2001)

**ABSTRACT.** Remodeling of uterine endometrial extracellular matrix (ECM) is pivotal to successful implantation and placentation, and has been well described in the rodents and humans. However, bovine endometrial ECM remodeling is still vaguely defined, especially at the time of implantation. Therefore, this study investigated the distribution of four ECMs namely, types I and IV collagen, laminin and fibronectin, from days 0 to 30 of gestation in bovine endometrium by immunofluorescence microscopy. A change in the distribution pattern of ECMs was evident by day 14 of gestation as features at this stage were clearly different from those of day 14 of the estrous cycle. The immunoreactivity of type I collagen, fibronectin and laminin decreased from day 14 of gestation and was obscured by day 24 of gestation. The type I collagen fibers formed were of thinner consistency than those of the estrous cycle and showed a coarser meshwork within the epithelium sites during the implantation period. In addition, the type IV collagen and laminin immunoreactivities of epithelial basement membrane also remarkably declined at exactly the same time. By day 30 of gestation, the four ECMs had regenerated with the formation of the placentalome. In conclusion, this study reveals that remodeling of ECM is essential for the successful establishment of pregnancy in the bovine.

**KEY WORDS:** bovine, endometrium, extracellular matrix (ECM), implantation, remodeling.

*J. Vet. Med. Sci.* 64(3): 207–214, 2002

Gestation is achieved through an array of events that include fertilization, attachment, implantation and placentation. Implantation and consequent placentation are important processes for the success of gestation as remarkable changes occur between the conceptus and uterine endometrium [13, 15, 28, 30]. In the cow, the elongation of the conceptus starts around two weeks after fertilization and it first attaches to the endometrium at about three weeks of gestation [30]. Consequently, the cotyledons first appear over the caruncular area around day 30 of gestation [16, 18]. Endometrial remodeling may start simultaneously with elongation of the conceptus. Although bovine placenta is defined as synepitheliochorial placenta, extracellular matrix (ECM) remodeling is indispensable for successful implantation as in humans and rodents [28, 29]. The four major macromolecules of ECM are collagen, proteoglycan, glycoprotein and elastin [5, 14]. Apart from the basic function of providing support to the cells, their additional roles include regulation of cell function, shape, growth, differentiation, proliferation, etc [14]. Some growth factors and cytokines, like basic fibroblast growth factor are trapped within them and are mobilized at the appropriate times for remodeling of the tissue [19, 27, 30]. Collagens, which are composed of three different subunits, depending on the family, are the major components of ECM as well as the most abundant protein in the tissue. There are about twenty different types of ECM with disparate functions. For example,

type I collagen is distributed in all connective tissues except for the basement membrane, hyaline cartilage and support fibers [5], whereas, type IV comprises the basement membrane and plays a role in scaffolding by forming a network similar to that of a mesh sheet [5]. In ruminants, the binucleate cells from the fetal trophoblast cells come into contact with the epithelial cells on the surface of the endometrium and fuse with them to form a syncytium. The only source of support at this particular time for both types of cells is the basement membrane. Notwithstanding this, the fusion leads to formation of trinucleate cells that finally develop to new binucleate cells [30]. During these remarkable changes, ECMs also need to modify their composition in response to implantation signal(s). Indeed endometrial ECM remodeling has been well documented in other species but has only been vaguely described in cattle [10, 27]. Therefore, in the present study, we examined the expression of type I and IV collagens, laminin and fibronectin in the bovine endometrium during early gestation using immunofluorescence microscopy.

### MATERIALS AND METHODS

**Animals:** A total of 20 Japanese black beef cows were used in this study on days 0, 6, 7, 13 (n=2), 14 (n=2), 20 of the estrous cycle (Day 0=estrus), and days 5, 6, 7, 13 (n=2), 14 (n=2), 19, 20, 24 and 30 (n=2) of pregnancy (Day 0=artificial insemination). The data are summarized in Table 1 following classification of each stage according to previous reports [13, 30]: estrus and developmental stage of corpus luteum (CL) (day 0 to 6 of estrous cycle), luteal phase (days

\* CORRESPONDENCE TO: HASHIZUME, K., Laboratory of Reproductive Biology and Technology, National Institute of Agrobiological Sciences, Ikenodai 2, Kukizaki, Inashiki-gun Ibaraki 305–8602, Japan.

7 to 13) and regressive stage of CL (days 14 to 20), early preimplantation (days 0 to 6, and days 7 to 13), preimplantation (days 14 to 19), implantation (days 20 to 24), and early placental development (days 25 to 30).

**Tissue Preparation:** Following slaughter of animals, the uteri were perfused with 4% paraformaldehyde (PA) in phosphate-buffer saline (PBS, pH7.4) via ovarian and uterine arteries immediately on collection. After perfusion, uterine horns were cut in cross-section of 10 mm thickness and fixed in 4% PA overnight at 4°C. These specimens were dehydrated in alcohol and xylene sequentially, and embedded in paraffin wax. Serial 5  $\mu$ m sections were made using a rotary microtome (MICROM Laborgeräte GmbH, Heidelberg, Germany) and put on either poly-L-lysine coated or non-coated slides (Matsunami, Tokyo, Japan), respectively.

**Histological Detection:** The sections were stained with Hematoxylin-eosin and Heidenhain's azan for histological examination. For azan staining, deparaffinized sections were stained in 1% Azocarmine G (Wako, Osaka, Japan) solution containing 1% glacial acetic acid for 60 min at 60°C, then washed in distilled water (DW). Sections were later differentiated in 90% alcohol containing 0.1% aniline (Wako, Osaka, Japan) until the nuclei stood out. They were further rinsed in 96% alcohol following by fixing 1% acetic acid. Sections were then stood in 5% phosphotungstic acid solution (Wako, Osaka, Japan) for 3 hr, rinsed in DW, and stained in 2% glacial acetic acid containing 0.5% aniline blue (Wako, Osaka, Japan) and 0.5% Orange G (Wako, Osaka, Japan). After washing in DW, sections were finally differentiated in 96% alcohol. Collagen fibers and colloidal material were stained blue, while the nuclei either appeared orange or red.

**Antibodies:** Primary antibodies for ECM detection used in this study were as follows: rabbit anti-bovine type I collagen (LB-1197, LSL, Tokyo, Japan), rabbit anti-bovine type IV collagen (LB-1407, LSL, Tokyo, Japan), rabbit anti-mouse laminin (LB-1013, LSL, Tokyo, Japan) and rabbit anti-bovine-fibronectin (YU-B004, Yagai, Yamagata, Japan). Primary antibodies were diluted 1:500 (anti-type I and IV collagens) or 1:200 (anti-laminin and fibronectin) with PBS containing 10% normal goat serum. The secondary antibody used was fluorescein isothiocyanate (FITC) - conjugated goat anti-rabbit IgG (R102, Leinco Technologies Inc, St. Louis, U.S.A.) which was diluted 1:200 with PBS containing 10% normal goat serum.

**Immunofluorescence Detection:** For the detection of the four ECMs, the deparaffinized sections were treated for 30 min in PBS containing 0.05% protease (P-6911, Sigma, St. Louis, U.S.A.) at 37°C and then rinsed in PBS. Non-specific antibody binding was minimized by treatment with 10% normal goat serum for 20 min, followed by incubation with each specific antibody overnight at 4°C. After rinsing, the sections were incubated with the secondary antibody for 60 min at room temperature. Subsequent to rinsing in PBS, the sections were mounted in Vectashield mounting medium (Vector Laboratories, Burlingame, U.S.A.). Tis-

suess were assessed using a photomicroscope (ECLIPSE E800, Nikon, Tokyo, Japan) equipped with an epifluorescence illuminating system (HB-10103AF, Nikon, Tokyo, Japan). Photomicrographs were shot on Fuji Provia (Fuji, Tokyo, Japan) ISO 1600 color reversal film, using the same exposure times.

## RESULTS

**Histological Examination:** There was no change in the size and shape of the epithelial cells of either the caruncular or intercaruncular regions on days 0, 7 and 14 of the estrous cycle. The typical epithelial cells had uniform columnar shape and a size of 20 to 30  $\mu$ m in diameter. Well-developed and dense ECMs were found just beneath the epithelium of the linear layer. Thick fibers widely occupied the space between cells in the stromal area (Figs. 1a and b). During the initial stage (day 0 to 13) of gestation, the structural image of ECMs was similar to that of the estrous cycle (data not shown). On day 14 of gestation, the endometrial stroma appeared swollen on the epithelial side and the size of endometrial epithelium had decreased to about 15  $\mu$ m in diameter (Figs. 1c and d). The ECM fibers of the stromal region became thinner and their distribution was more dispersed by day 14 of gestation compared to day 14 of the estrous cycle (Figs. 1b and d). On day 24 of gestation, the conceptus was found in the expanded uterine lumen. During the same period remarkable changes were found. Endometrial epithelial cells lost their uniformity and degraded with pyknotic nuclei, their size was reduced and became flatter, and fetal membrane attached to the endometrial epithelial cells. Some trophoblast cells fused with uterine epithelial cells and some larger cells made binucleate and trinucleate cells (Figs. 1e and f). In the caruncular areas, the endometrial epithelial cells completely disappeared and the trophoblast cells directly attached to the endometrial stroma (Fig. 1e). These changes were found only in the caruncular area but not in the intercaruncular region. The ECM fibers of the endometrial stroma swelled and dispersed, especially, the fiber layer under the epithelium that was obscured by the degradation of the epithelial cells (Fig. 1e). On day 30 of gestation, although the fetal chorion was in close contact with the epithelium on the caruncle and intercaruncle, placental formation was only found in the caruncular region (Figs. 1g and h). Within the placental, the trophoblast cell layer pushed into the endometrium and formed a fret structure (crypt) in the caruncle (Fig. 1h). The surface of the crypt was lined with epithelium-like cells that appeared uniform (Fig. 1h). The crypt consisted of well-developed ECMs, capillaries and fibroblast-like cells. The intercotyledonary trophoblastic region and intercaruncular endometrium were smooth, and the intercaruncular endometrium had openings of the uterine glands and continuous epithelium from these glands covered the stroma that was enriched by ECMs, blood vessels and fibroblastic cells.

**Immunofluorescence Detection:** Results are summarized in Table 1. Type I collagen that is depicted as compact

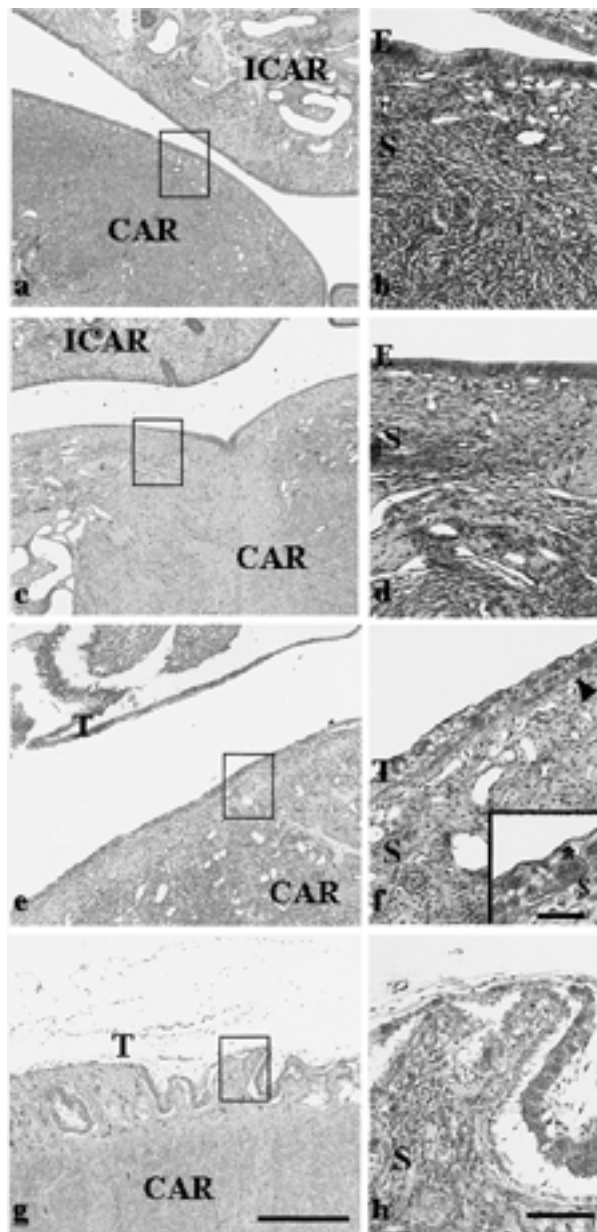


Fig. 1. Histological examination of bovine endometrium during the estrous cycle and early gestation. Uterine endometrium was stained by either HE (a, c, e and g) or AZAN (b, d, f and h). High-magnification photos (b, d, f, h) show the enlargement of the box in the low magnification photos (a, c, e and g). a and b: Uterine epithelium showed uniform columnar shape and size of 20 to 30  $\mu\text{m}$  in diameter on day 14 of estrous cycle. Thick fibers widely occupied the space between cells in the stromal area. c and d: On day 14 of gestation, uterine epithelium was about 15  $\mu\text{m}$  in diameter. Stromal fibers became thinner and dispersed. e and f: On day 24 of gestation, uterine epithelium lost uniformity and became flatter with pyknosis. Some trophoblast cells were directly attached to the stroma. Stromal fibers lost uniformity and dispersed with swelling. Photo f shows a fetal binucleate cell (asterisk) directly in contact with the stroma. g and h: On day 30 of gestation, fetal chorion adhered to the epithelium.

fibers with dense staining, occupied all areas of the endometrial stroma and its expression was quite stable during the estrous cycle (Fig. 2a) as well as during the early preimplantation period (day 0 to 13). Its fibers were well developed and formed a uniform dense structure underneath the epithelium. By day 14 of gestation, this layer became loose and showed a rough appearance associated with a mesh network. Its fibers were thin and staining intensity declined (Fig. 2b). On day 24 of gestation, immunofluorescence reactivity of type I collagen markedly decreased in the stroma beneath the epithelium (Fig. 2c). In some caruncular areas, it was difficult to detect any immunoreactivity of type I collagen (Fig. 2d). On day 30 of gestation, the type I collagen fibers had distinctly regenerated in the caruncular stroma. Within the placentome, much more development of type I collagen fibers was detected in the maternal crypts and stable immunofluorescence reactivity was found in the cotyledon (Fig. 2e). Type I collagen richly occupied the intercaruncular stroma (Fig. 2f).

Type IV collagen was located beneath the epithelial cells and detected as a scaffold in the basement membrane during the estrous cycle and day 14 of gestation (Figs. 3a and b). On day 24 of gestation, the immunofluorescence reactivity of type IV collagen declined with the implantation process (Figs. 3c and d). On day 30 of gestation, the type IV collagen present in the basement membrane was distinguished by its thickness and dense staining in the caruncular and intercaruncular endometrium. Strong immunofluorescence reactivity was found in the chorionic basement membrane and that of uterine glands in the intercaruncular endometrium (Figs. 3e and f).

Laminin was found in the basement membrane of epithelial cells and also in the vascular basement membrane during the estrous cycle and early preimplantation (day 0 to 13) (Fig. 4a). On day 14 of gestation, the immunofluorescence reactivity of laminin decreased in the vascular basement membrane. However, its reactivity in the epithelium and basement membrane was stable during the preimplantation period (day 14 to 19 of gestation) (Figs. 4a and b). On day 24 of gestation, laminin immunoreaction decreased in the endometrial epithelial cells, as well as, the vascular basement membrane of the caruncle. Specifically, very faint staining was found in caruncular area (Figs. 4c and d). On day 30 of gestation, laminin reappeared in both maternal and fetal tissues. In the caruncular area, laminin expression was found in the basement membrane of epithelial-like cells in the maternal crypts. In the chorion, the trophoblastic basement membrane also had strong staining (Fig. 4e). In the intercaruncular area, laminin was also localized in the basement membrane of the endometrial epithelial cells, blood vessels and uterine glands (Fig. 4f).

Fibronectin was found in the endometrial stroma during

Crypt of endometrium included well-developed fibers. E; uterine epithelium. S; stroma. T; trophoblast. CAR; caruncle. ICAR; intercaruncle. Bar=500  $\mu\text{m}$  (low magnification photos), 100  $\mu\text{m}$  (high magnification photos) and 50  $\mu\text{m}$  (insert photo in f).

Table 1. Changes of endometrial ECMs expression during implantation window

		estrous			gestation				
		0–6*	7–13*	14–0*	0–6†	7–13†	14–19†	20–24†	25–30†
caruncle	type I collagen	+++	+++	+++	+++	+++	+	–	+++
	type IV collagen	+++	+++	+++	+++	+++	++	–	+++
	laminin	++	++	++	++	++	+	–	++
	fibronectin	+	+	+	+	+	+	–	+
intercaruncle	type I collagen	+++	+++	+++	+++	+++	++	+	+++
	type IV collagen	+++	+++	+++	+++	+++	++	+	+++
	laminin	++	++	++	++	++	++	+	++
	fibronectin	+	+	+	+	+	+	+	+

+++; Strong, ++; Moderate, +; Weak; –; Negative

\*; Estrous cycle was classified into days 0 to 6 (estrus and developmental stage of corpus luteum (CL)), days 7 to 13 (luteal phase) and days 14 to 20 (regressive stage of CL) according to Hafez [13]. †; Gestation stage was classified into days 0 to 6, and days 7 to 13 (early preimplantation), days 14 to 19 (preimplantation), days 20 to 24 (implantation), and days 25 to 30 (early placental development) according to Wooding [30].

the estrous cycle and preimplantation (day 0 to 19) (Fig. 5a). On day 24 of gestation, the fibronectin immunoreactivity decreased in the epithelium and stroma of the caruncular area, but immunoreactivity was found in the intercaruncular area, especially in the epithelial and trophoblast cells (Figs. 5b, c and d). On day 30 of gestation, fibronectin expression reappeared in epithelial-like cells of the caruncular and intercaruncular area and fetal trophoblast cells. Rather strong expression was found in fetal trophoblasts (Figs. 5e and f).

## DISCUSSION

We examined the expression of type I and type IV collagens, laminin and fibronectin in bovine endometrium during the implantation period because ECM remodeling is essential for successful implantation and placentation. Asynchrony between embryo development and uterine receptivity either results in implantation failure or early embryo loss. Our results indicate that the immunofluorescence reactivity of collagens was stable and localized within the stroma during the estrous cycle, however, their immunoreactivities remarkably declined around implantation. Interestingly, the reconstitution of collagens and other ECM occurred following completion of implantation.

In ruminants, the morphological changes in the endometrium at implantation have been demonstrated by several authors [10, 18, 26]. They showed that the thin uterine epithelium comes directly into contact with the trophoblast at day 22 of gestation in sheep [10, 18]. King *et al.* [18] described that the contact between the epithelium and trophoblast appeared at day 21 of gestation and that cuboidal maternal epithelial cells with lipid droplets appeared at day 29 of gestation in the cow. The uterine epithelium

adhered to the embryonic trophectoderm and subsequently established an interdigitation of microvilli between the epithelium and trophectoderm [30]. These previous results are confirmed in the present study. The endometrial epithelium became either flat or disappeared during implantation, and a reformed epithelial-like cell layer covered the maternal crypts during placentation. Neither the origins nor inference of the epithelial-like cells of the maternal crypts were sufficiently investigated in the present study. However, our results indicate that the regeneration of uterine epithelium is essential for feto-maternal interactions, such as respiration, nutrition, hormonal regulation, immunologic relationship and other things, during pregnancy in cows.

Type I collagen, which is the major component of ECM, commonly has a heterotrimeric form comprising of two  $\alpha 1$  (I) chains and one  $\alpha 2$  (I) chain [5, 14]. Functionally, type I collagen is a large fibrillar protein with structural supportive properties [5, 14] shown in *in vitro* studies to be capable of rapidly stimulating vascular tube formation [15]. Previous reports have described the dynamic changes of type I collagen during implantation and placentation [3, 9]. During implantation and placentation, type I collagen fibers, which are lost on the formation of primary decidual tissue, are regenerated during the development of the secondary decidual zone in rats [3]. In the goat, though, type I collagen was distributed diffusely throughout the uterine stroma during pre-implantation; a dynamic loss of stromal type I collagen was found in the epithelium and stromal capillaries during implantation, and the integrin  $\beta 1$  subunit was also reduced simultaneously [9]. In this study, type I collagen was found sparsely in all areas of the endometrium, and its expression was rather intensive below the epithelium on day 14 of the estrous cycle. The expression pattern of type I collagen was confirmed as identical to that of previous reports [2].

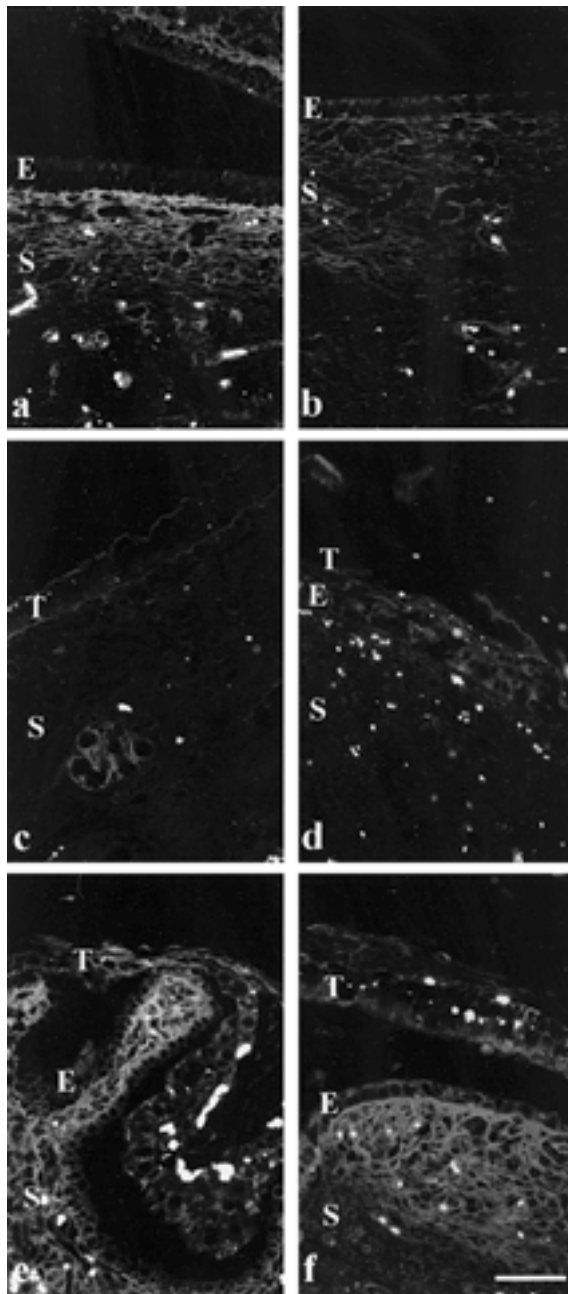


Fig. 2. Immunofluorescence detection of type I collagen in endometrium. a: On day 14 of estrus, type I collagen fibers showed a thick and dense structure underneath the epithelium. b: Type I collagen fibers became loose and formed a rough appearance on day 14 of gestation. c and d: In caruncular (c) and intercaruncular (d) endometrium, immunoreactivity of type I collagen decreased in the stroma on day 24 of gestation. e and f: In caruncular (e) and intercaruncular (f) endometrium, type I collagen fibers had distinctly regenerated in the stroma by day 30 of gestation. E; uterine epithelium, T; fetal trophoblast. Bar = 50  $\mu$ m.

Fibronectin binds to a number of biological macromolecules including heparin, types I, II, III and V collagens, the fibrin and integrin family, and regulates many functions of the cell such as growth, differentiation, shape, migration, etc. [12, 14]. In the bovine estrous cycle, fibronectin was distributed diffusely throughout the endometrial tissue, and integrin  $\beta$ 1 subunit was present in the endometrial stroma [17]. The bovine placentome is composed of an interdigitation of cotyledonary and caruncular villi, and the rich vascular system and the majority of types I and III collagens are localized within the maternal villi [25]. The present study demonstrated that there was a parallel decrease in the expression of type I collagen and fibronectin during the early implantation period and that the feature of collagen fibers remarkably changed from thick and dense to thin and rough. The abrupt fluctuation of type I collagen and fibronectin indicates a principal role in endometrial remodeling during the peri-implantation period, since their changes coincide with the progress of implantation. These results suggest that initiating regeneration of type I collagen and fibronectin sustain the formation of maternal crypts for fetal-maternal interaction during placental development.

The type IV collagen and laminin constitute customarily the basement membrane of epithelium, blood vascular vessels and various kinds of gland [5, 25]. The structure of type IV collagen is expressed as a network of mesh sheets and serves as multiple cell-binding sites. The laminin molecule is composed of a disulfide-bonded heterotrimer containing three non-identical chains designated  $\alpha$ ,  $\beta$  and  $\gamma$ , which interact with type IV collagen. Laminin also interacts with entactin and heparan sulfate proteoglycan which assist cells to bind to ECMs and play a role in cell proliferation and differentiation [6]. The role of laminin in implantation may depend on the placental structure. In the pig, no modification of the basement membrane composition was noticed during implantation [21]. In the goat, lack of type IV collagen and laminin was noted in the basement membrane of the luminal uterine epithelium adhering to the trophoblast and around the blood capillaries. The failure of ECM expression in the subepithelial stroma was also found [9]. These results could be interpreted as a modification of the composition of basal lamina rather than its destruction during implantation [9]. In the rat, expression of laminin was associated with the differentiation of cells during primary decidual formation [3]. In the mouse, the expression of laminin B2, type IV collagen  $\alpha$ 1 and  $\alpha$ 2 mRNA increased remarkably during placentation [6]. In the present study, the expression of type IV collagen and laminin decreased during the implantation period, and they were reconstructed in the maternal crypts soon after this period. This result agrees with that of Boss [2]. These dramatic events commonly occur in ruminants [9]. These findings reveal that the degradation and reconstruction of type IV collagen and laminin are a necessary process for the regeneration of uterine epithelial cells, increase of blood vessels and differentiation of trophoblast cells with the development of maternal crypts and fetal cotyledons in cows.



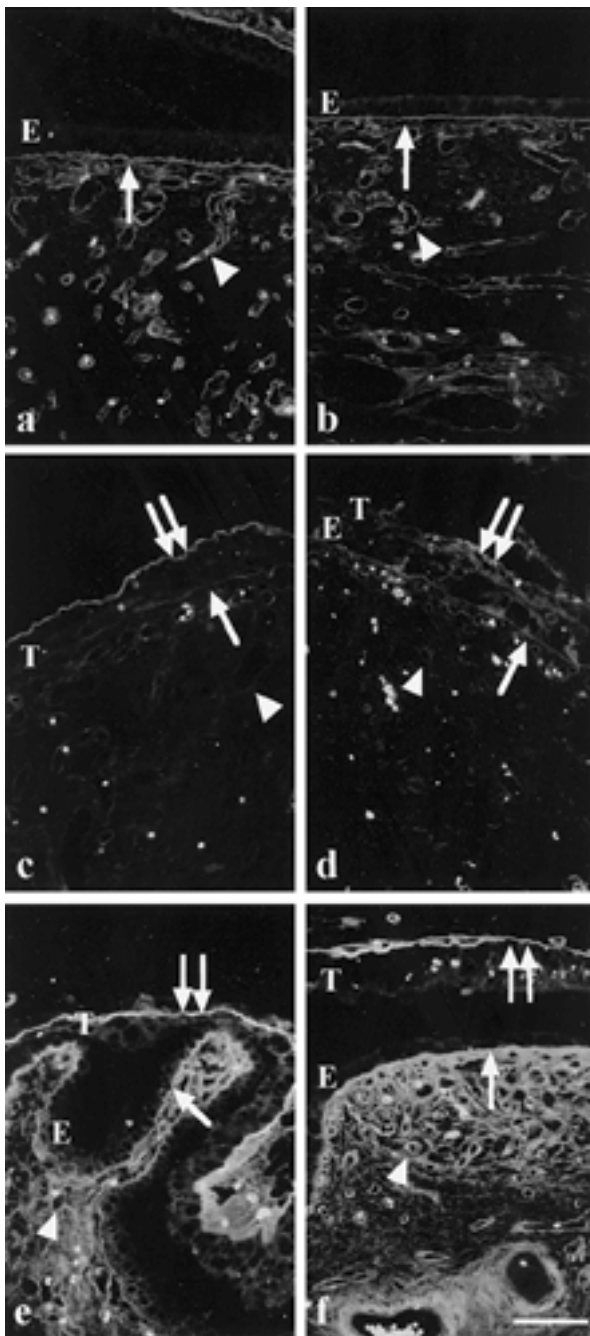


Fig. 3. Immunofluorescence detection of type IV collagen in endometrium. a: On day 14 of estrous, type IV collagen showed a uniform, thin and dense structure in basement membrane of epithelium and capillaries. b: Type IV collagen expression on day 14 of gestation was very similar to that of estrous (photo a). c: In caruncular endometrium, immunoreactivity of type IV collagen decreased in the basement membrane of epithelium and capillaries, but trophoblastic layer expressed distinct immunoreactivity of type IV collagen on day 24 of gestation. d: In intercaruncle, immunoreactivity was found in basement membrane of epithelium, capillaries and trophoblastic layer on day 24 of gestation. e and f: In caruncular (e) and intercaruncular (f)

Proteinases like matrix-metalloproteinases (MMPs) and cytokines are likely required for these rapid and distinct ECM remodeling events [4, 7, 8, 11, 20, 22, 23, 27], however, further studies are needed to verify the mechanism of remodeling in bovine implantation and placentation, because there are a few reports of MMP activity during implantation in ruminants [24]. In the mouse, MMP-2 participated in the early phase of decidualization which is a prerequisite for placentation, and MMP-9 and TIMP-3 regulated trophoblast invasion of the uterine wall [4]. In humans, it was reported that MMP-2 and -9, and their inhibitors are expressed by specific cells in the early and late placental bed and villi [23]. The coincidental expression of the proteolytic MMP-9 and inhibitors, TIMP-1, -2 and -3 generally in the same cells suggest that the activity of MMP-9, that is regulated by TIMPs, plays an important role in placental tissue organization, as well as in the invasion of trophoblast cells into the uterine wall [27]. ECM remodeling may be essential for ruminants including cows, not only in the structural changes observed in the endometrium but also in the release and/or activation of cytokines as ECMs aid several types of growth factors with glycoprotein configuration [1, 4, 7, 8, 11, 20, 22–24]. Notwithstanding this, ECMs expression as determined by immunofluorescence detection, revealed that their reactivity initially declined on implantation but increased in early placental development. However, no alteration was witnessed during the estrous cycle. These results suggest that endometrial remodeling is essential for implantation and placentation in bovine, and this remodeling process depends on mechanical and/or chemical signals from the embryo. Further study may give us a more accurate answer for the remodeling mechanism, including the relationship among MMPs, cytokines and ECMs.

## CONCLUSION

This study investigated the distribution of four ECMs namely, types I and IV collagen, laminin and fibronectin, during early gestation in the bovine endometrium by immunofluorescence microscopy. The remodeling of endometrial ECMs, especially fluctuation of type I collagen and fibronectin during implantation might have a role stimulating fetal membrane and epithelial cell contact, and it may be an essential process for the establishment of pregnancy in cows.

**ACKNOWLEDGEMENTS.** We are grateful to Dr. O. V. Patel for his helpful suggestions and observations and a critical reading of the manuscript. This study was supported by

endometrium, type IV collagen had richly occupied in the basement membrane of epithelial-like cells, capillaries and trophoblastic layers on day 30 of gestation. Arrow; epithelial basement membrane, Arrowhead; capillary basement membrane, Double arrows; trophoblastic basement membrane, E; uterine epithelium, T; fetal trophoblast. Bar = 50  $\mu$ m.

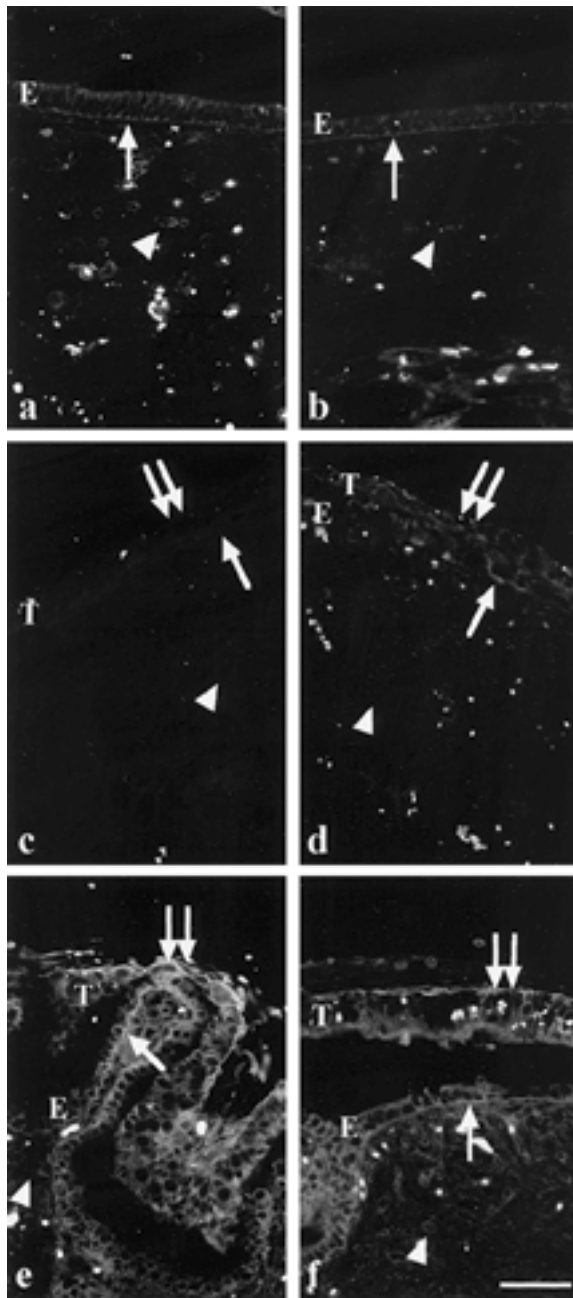


Fig. 4. Immunofluorescence detection of laminin in endometrium. a and b: Laminin was expressed stably in basement membrane of epithelium and capillaries with uniformity and thin structure on day 14 of estrous (a) and day 14 of gestation (b). c: In caruncular endometrium, immunoreactivity of laminin decreased in the basement membrane of epithelium and capillaries on day 24 of gestation. d: In intercaruncle, very feeble immunoreactivity was found in basement membrane of epithelium, capillaries and trophoblastic layer on day 24 of gestation. e and f: In caruncular (e) and intercaruncular (f) endometrium, laminin had richly occupied the basement membrane of epithelium-like cells, capillaries and trophoblastic layers on day 30 of gestation. Arrow; epithelial basement

the Bio-oriented Technology Research Advancement Institution, the National Institute of Animal Industry and the Organized Research Combination System from the Science and Technology Agency in Japan.

#### REFERENCES

1. Bischof, P., Haenggeli, L. and Campana, A. 1995. Gelatinase and oncofetal fibronectin secretion is dependent on integrin expression on human cytotrophoblast. *Mol. Hum. Reprod.* **10**: 734–742.
2. Boss, A. 2000. Immunohistochemical assessment of collagen type I, III, IV and VI in biopsy samples of the bovine uterine wall collected during the oestrous cycle. *Cells Tissues Organs.* **167**: 225–238.
3. Clark, D. E., Hurst, P. R., McLennan, I. S. and Myers, D. B. 1993. Immunolocalization of collagen type I and laminin in the uterus on days 5 to 8 of embryo implantation in the rat. *Anat. Rec.* **237**: 8–20.
4. Das, S. K., Yano, S., Wang, J., Edwards, D. R., Nagase, H. and Dey, S. K. 1997. Expression of matrix metalloproteinases and tissue inhibitors of metalloproteinases in the mouse uterus during the peri-implantation period. *Dev. Genet.* **21**: 44–54.
5. DerRest, M. V. and Garrone, R. 1991. Collagen family of proteins. *FASEB J.* **5**: 2814–2823.
6. Farrar, J. D. and Carson, D. D. 1992. Differential temporal and spatial expression of mRNA encoding extracellular matrix component in decidua during the peri-implantation period. *Biol. Reprod.* **46**: 1095–1108.
7. Fernandez, P. L., Meria, M. J., Nogales, F. F., Charonis, A. S., Stetler-Stevenson, W. and Liotta, L. 1992. Immunohistochemical profile of basement membrane proteins and 72 kilodalton type IV collagenase in the implantation placental site. *An Integrated View. Lab. Invest.* **66**: 572–579.
8. Goldberg, G. J., Strongin, A., Collier, I. E., Genrich, L. T. and Marmer, B. L. 1992. Interaction of 92 kDa type IV collagenase with the tissue inhibitor of metalloproteinases prevents dimerization, complex formation with interstitial collagenase, and activation of the proenzyme with stromelysin. *J. Biol. Chem.* **267**: 4583–4591.
9. Guillomot, M. 1999. Changes in extracellular matrix components and cytokeratins in the endometrium during goat implantation. *Placenta* **20**: 339–345.
10. Guillomot, M., Flechon, J. E. and Wintenberger-Torres, S., 1981. Conceptus attachment in the ewe: an ultrastructural study. *Placenta* **2**: 169–182.
11. Hurskainen, T., Höyatyä, M., Tuuttila, A., Oikarinen, A. and Autio-Harmainen, H. 1996. mRNA expression of TIMP-1, -2, and -3 and 92-KD type IV collagenase in early human placenta and decidua membrane as studies by in situ hybridization. *J. Histochem. Cytochem.* **44**: 1379–1388.
12. Hynes, R. O. 1992. Integrin; versatility, modulation, and signaling in cell adhesion. *Cell* **69**: 11–25.
13. Hafez, E. S. E. 1987. Reproduction in farm animals. 5th ed., Lea & Febiger, Philadelphia.
14. Haralson, M. A. and Hassell, J. R. 1995. The extracellular matrix—an overview. pp. 1–30. In: Extracellular Matrix-A Practical Approach (Haralson, M. A. and Hassell, J. R. eds.),

membrane, Arrowhead; capillary basement membrane, Double arrows; trophoblastic basement membrane, E; uterine epithelium, T; fetal trophoblast. Bar = 50  $\mu$ m.

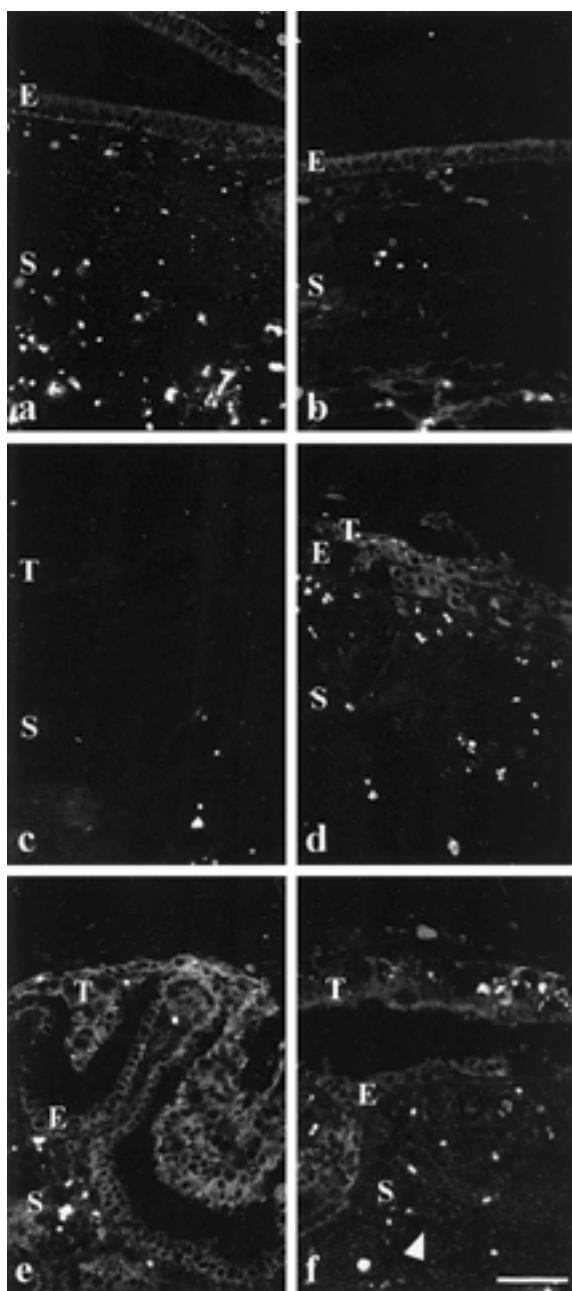


Fig. 5. Immunofluorescence detection of fibronectin in endometrium. a: Fibronectin were found on the surface of epithelium and stroma on day 14 of estrous. b: The expression of fibronectin was maintained on day 14 of gestation. c: In the caruncular area, the immunoreactivity decreased and it was difficult to detect. d: The immunoreactivity was found in the epithelium and trophoblast in the intercaruncle area on day 24 of gestation. e and f: In caruncular (e) and intercaruncular (f) endometrium, fibronectin expression was distinctly regenerated in the epithelium and trophoblastic layer on day 30 of gestation. E; uterine epithelium. S; stroma. T; fetal trophoblast. Bar=50  $\mu$ m.

- Oxford University Press, Oxford, U.K.
15. Jackson, C. J. and Jenkins, K. L. 1991. Type I collagen fibrils promote rapid vascular tube formation upon contact with the apical side of cultured endometrium. *Exp. Cell Res.* **192**: 319–323.
16. Jainudeen, M. R. and Hafez, E. S. E. 1987. Gestation, prenatal physiology and parturition. pp. 239–259. *In: Reproduction Farm Animal* (Hafez, E. S. E. ed.), Lea & Febiger, Philadelphia, U.S.A.
17. Kimmius, S. and MacLaren, L. A. 1999. Cyclic modulation of integrin expression in bovine endometrium. *Biol. Reprod.* **61**: 1267–1274.
18. King, G. J., Atkinson, A. and Robertson, H. A. 1980. Development of the bovine placentome from day 20 to 29 of gestation. *J. Reprod. Fertil.* **59**: 95–100.
19. Koks, C. A., Groothuis, P. G., Dunselman, G. A., de Goeji, A. F. and Evers, J. L. 2000. Adhesion of menstrual endometrium to extracellular matrix: the possible role of integrin alpha(6)beta(1) and laminin interaction. *Mol. Hum. Reprod.* **15**: 170–177.
20. Maj, J. G. and Kankofer, M. 1997. Activity of 72-kDa and 92-kDa matrix metalloproteinases in placental tissues of cows with and without retained fetal membranes. *Placenta* **18**: 683–687.
21. Menino, Jr., A. R., Hogan, A., Schultz, G. A., Novak, S., Dixon, W. and Foxcroft, G. H. 1997. Expression of proteinases and proteinase inhibitors during embryo-uterine contact in the pig. *Dev. Genet.* **21**: 68–74.
22. Murphy, G., Cockett, M. I., Ward, R. V. and Docherty, A. J. P. 1991. Matrix metalloproteinase degradation of elastin, type IV collagen and proteoglycan. A quantitative comparison of the activities of 95 kDa and 72 kDa gelatinases, stromelysins-1 and -2 and punctuated metalloproteinase (PUMP). *Biochem. J.* **277**: 277–279.
23. Polette, M., Nawrocki, B., Pintiaux, A., Massenat, C., Maquoi, E., Volders, L., Schaaps, J. P., Birembaut, P. and Foidart, J. M. 1994. Expression of gelatinases A and B and their tissue inhibitors by cells of early and term human placenta and gestational endometrium. *Lab. Invest.* **71**: 838–846.
24. Salamansen, L. A., Nagase, H. and Woolley, D. E. 1995. Matrix metalloproteinases and their tissue inhibitors at the ovine trophoblast-uterine interface. *J. Reprod. Fertil. (Suppl.)* **49**: 29–37.
25. Sharpe, K. L., Eiler, H. and Hopkins, F. M. 1990. Changes in the proportion type I and III collagen in the developing and retained bovine placentome. *Biol. Reprod.* **43**: 229–235.
26. Smith, S. E., Cullen, W. C. and Godkin, J. D. 1990. Ultrastructural morphometric analysis of the uterine epithelium during early pregnancy in the sheep. *J. Reprod. Fertil.* **89**: 517–525.
27. Vagnoni, K. E., Zheng, J. and Magness, R. R. 1998. Matrix metalloproteinase-2 and -9, and tissue inhibitor of metalloproteinases-1 of the sheep placenta during the last third of gestation. *Placenta* **19**: 447–455.
28. Weitlauf, H. M. 1994. Biology of implantation. pp. 391–440. *In: The Physiology of Reproduction*, 2nd ed. (Knobil, E., Neill, J. D. eds.), Raven Press, New York, U.S.A.
29. Woessner, Jr., J. 1991. Matrix metalloproteinases and their inhibitors in connective tissue remodeling. *FASEB J.* **5**: 2145–2154.
30. Wooding, F. B. P. 1992. Current topic: The synepitheliochorial placenta of ruminants: Binucleate cell fusions and hormone production. *Placenta* **13**: 101–113.