

Full Paper

Oral Mucosal Adhesive Films Containing Royal Jelly Accelerate Recovery From 5-Fluorouracil-Induced Oral Mucositis

Shinichi Watanabe^{1,*}, Katsuya Suemaru², Kenshi Takechi¹, Hiroaki Kaji³, Kimie Imai⁴, and Hiroaki Araki¹¹Division of Pharmacy, Ehime University Hospital, 454 Shitsukawa, Toon, Ehime 791-0295, Japan²School of Pharmacy, Shujitsu University, 1-6-1 Nishigawara, Okayama 703-8516, Japan³Division of Biochemistry, Faculty of Pharmaceutical Sciences, Himeji Dokkyo University, 7-2-1 Kami-Ohno, Himeji, Hyogo 670-8524, Japan⁴Division of Clinical Pharmaceutics, Faculty of Pharmaceutical Sciences, Setsunan University, 45-1 Nagaotoge-cho, Hirakata, Osaka 573-0101, Japan

Received August 16, 2012; Accepted December 2, 2012

Abstract. Oral mucositis induced by chemotherapy or radiotherapy has an impact upon quality-of-life, is dose-limiting for chemotherapy, and causes considerable morbidity. We evaluated the effect of royal jelly (RJ) on 5-fluorouracil (5-FU)-induced oral mucositis in hamsters. Oral mucositis was induced in hamsters through a combination of 5-FU treatment and mild abrasion of the cheek pouch. RJ was contained in chitosan–sodium alginate film (RJ film). Films were attached to the oral mucosa and the healing process examined by measuring the area of mucositis, myeloperoxidase (MPO) activity, microscopic aspects, and RT-PCR for detection of pro-inflammatory cytokines (tumor necrosis factor- α , interleukin-1 β). Furthermore, we evaluated the radical-scavenging activity of RJ and generation of keratinocyte growth factor from human periodontal ligament fibroblasts. RJ films (10%, 30%) significantly improved recovery from 5-FU-induced damage, reduced MPO activity and the production of pro-inflammatory cytokines. Additionally, RJ showed radical-scavenging activity. These data suggest that topical application of films that contain RJ had a healing effect on the severe oral mucositis induced by 5-FU and that the effect was caused by the anti-inflammatory or anti-oxidative activities of RJ.

Keywords: antioxidant, cancer, 5-fluorouracil, oral mucositis, royal jelly

Introduction

Oral mucositis induced by chemotherapy or radiotherapy is a common and painful side effect. Chemotherapy-induced mucositis has become a common dose-limiting toxicity for several regimens. Local anesthetics (1), agents that coat the oral mucosa with sodium alginate (2), anti-ulcer agents (e.g., polaprezinc, rebamipide), and anti-inflammatory agents (e.g., azulene, corticosteroids) are used for the treatment of oral mucositis (3–6). However, there are no established effective treatments for oral mucositis.

It has been speculated that mucositis results from a process that includes changes in the endothelium and

connective tissue, as well as the epithelium, which is stimulated by several cytokines. The oral microflora, saliva, and functional trauma provide an indigenous environment that modulates the frequency, course, and severity of mucositis. Thus, the healing of oral mucositis is a complex process that involves inflammatory aspects (e.g., monocyte migration and cytokine production), growth factors, and angiogenesis during re-epithelialization (7).

Recently, biologically active factors have been considered for their potential efficacy in preventing and/or treating mucositis. The efficacy of interleukin (IL)-11 and transforming growth factor- β 3 has been reported in animals and in vitro (8, 9). In clinical studies, granulocyte-colony stimulating factor (10) and keratinocyte growth factor (KGF) (11, 12) have been reported to reduce the severity of mucositis if applied before chemotherapy and/or in the repair phase.

*Corresponding author. kinnin@m.ehime-u.ac.jp

Published online in J-STAGE on January 25, 2013 (in advance)

doi: 10.1254/jphs.12181FP

Interestingly, a preliminary study has shown topical application of natural honey to be a simple and cost-effective treatment for radiation-induced mucositis (13). However, the precise efficacy of this treatment is unclear. Other bee products such as royal jelly (RJ) and propolis have been reported to have various biological activities. For instance, RJ (the principal food source of the queen honeybee) has pharmacological characteristics, including anti-bacterial (14), anti-allergic (15), antioxidant (16), and wound-healing properties (17).

Previously, we reported the effect of topical application of RJ ointment upon 5-fluorouracil (5-FU)-induced oral mucositis (18). However, the precise mechanism of the healing effect upon oral mucositis and RJ release from the base ointment were not clear. Topical treatment using films has been reported to be useful for oral mucositis because it can protect the oral mucosa and control the release of drugs from drug-delivery systems in the oral mucosa (19, 20).

In the present study, we constructed sodium alginate–chitosan films that contained RJ (RJ film) and examined their effect upon 5-FU–induced oral mucositis in hamsters.

Materials and Methods

The experimental protocol was conducted according to the Guidelines of the Ethics Review Committee for Animal Experimentation of Ehime University Medical School (Ehime).

Animals

Seven-week-old Golden Syrian hamsters (Japan SLC, Inc., Shizuoka) weighing 90–120 g were used in all experiments. All animals were housed in a room maintained at $22^{\circ}\text{C} \pm 2^{\circ}\text{C}$ under a 12-h light–dark cycle with lights on at 07:00 h. They were fed with a standard rodent diet and had free access to water.

Drugs

RJ was supplied by the Yamada Apiculture Center, Inc. (Okayama). RJ was collected from *Apis mellifera* L. that fed primarily on nectar and pollen from *Brassica rapa* var. *nippo-oleifera* in Jiang Shan in the People's Republic of China. 5-FU injection (Kyowa Hakko Co., Ltd., Tokyo), chitosan, and glycerol were obtained from Wako Pure Chemical Industries (Osaka). Sodium alginate was from Nacalai Tesque Co., Ltd. (Kyoto). Human periodontal ligament fibroblasts (HPdLFs) were purchased from Cambrex Bio Science, Walkersville, MD, USA. Stromal cell basal medium (SCBM) was obtained from Takara Bio Co., Ltd., Otsu. Rabbit anti-human KGF antibody, rabbit biotinylated anti-human KGF antibody, and recombinant human KGF were purchased from

PeptoTech EC (London, UK). Horseradish peroxidase (HRP)-conjugated streptavidin was from Zymed Laboratories (San Francisco, CA, USA) and 3,3',5,5'-tetramethylbenzidine (TMB) was from Sigma-Aldrich Japan (Tokyo).

Preparation of sodium alginate–chitosan films

RJ was dissolved in 50 mL distilled water and mixed with 1.0 g sodium alginate and 0.1 g glycerol. It was poured into petri dishes and dried under vacuum at room temperature. Chitosan was dissolved in 10 mL 0.3% acetic acid and 0.1 g glycerol was added as a plasticizer. The gelatinous chitosan was poured onto dried sodium-alginate layers and dried under vacuum at room temperature. The final concentration of RJ was 10% or 30% weight of the dried film. Films were punched with 10-mm diameter holes. The weight of the film preparation was 15 mg.

In vitro drug release

In vitro release of RJ from sodium-alginate layers was carried out using a modification of the method of Arakawa et al. (21). The 10% or 30% RJ film was attached to the wall of a 30-mL glass beaker and stirred at 50 rpm in 20 mL distilled water maintained at 37°C . Aliquots of 100 μL were taken at 1, 5, 10, 15, 30, 60, 120, 180, and 240 min and replaced with the same volume of distilled water. The major components of RJ are proteins. Hence, by determining the protein concentration we also determined the RJ concentration. The protein content of RJ was determined following the method of Lowry et al. (22) using bovine serum albumin as the standard.

Creating a model of oral mucositis

The hamster model for chemotherapy-induced oral mucositis was based on a modification of the method of Sonis et al. (23). Hamsters ($n = 12$ per group) received two intraperitoneal injections of 5-FU (60 mg/kg) on days 0 and 2. To induce mucosal ulceration, hamsters were anesthetized with diethyl ether. The left-cheek pouches were everted and scratched lightly with a small wire brush on days 1 and 2. Epithelial ulceration was noted in all of the hamsters on day 3. Films were applied to the left-cheek pouch every day from day 3 under anesthesia with diethyl ether. A sodium-alginate layer was attached to the oral mucosal side (the chitosan layer was on the oral cavity side). Ulcers were assessed every other day immediately before drug application. Assessment of the cheek pouch involved measurement of the length and width of the ulcer with calipers, which were determined in a single-blind manner.

Macroscopic analyses of cheek pouches

After 8 days of treatment with RJ films (10% and 30%), animals were anesthetized with diethyl ether. The cheek pouches were everted and photographed before the hamsters were killed. The photographs were used for scoring lesions. Scoring methods in hamsters followed the methods of Lima et al. (24) and Leitão et al. (25). For macroscopic analyses, inflammatory aspects (erythema, hyperemia, hemorrhagic areas, epithelial ulceration, and abscess) were evaluated in a single-blind manner and graded on a score of 0–3, as follows: 0 = normal cheek pouch with erythema and hyperemia absent or discreet and no hemorrhagic areas, ulcerations, or abscesses; 1 = moderate erythema and hyperemia, with no hemorrhagic areas, ulcerations, or abscesses; 2 = severe erythema and hyperemia, with hemorrhagic areas, small ulcerations, or scarred tissue, but no abscesses; and 3 = severe erythema and hyperemia, with hemorrhagic areas, extensive ulcerations, and abscesses.

Histopathological analyses

Samples of cheek pouches were removed from 6 hamsters per group for histopathological analyses on day 8. Specimens were fixed in 10% neutral-buffered formalin, dehydrated, and embedded in paraffin. Sections were obtained for staining with hematoxylin & eosin (H&E) and examined under light microscopy ($\times 400$). Scoring methods in hamsters followed the methods of Lima et al. (24) and Leitão et al. (25). The parameters of infiltration of inflammatory cells, vascular dilatation, ingurgitation, hemorrhagic areas, edema, ulceration, and abscesses were determined in a single-blind manner and graded on a score of 0–3: 0 = normal epithelium and connective tissue without vasodilatation; absence of, or discreet, cellular infiltration; absence of hemorrhagic areas, ulceration or abscesses; 1 = discreet vascular ingurgitation, areas of re-epithelization; discreet inflammatory infiltration with mononuclear prevalence; absence of hemorrhagic areas, edema, ulceration or abscesses; 2 = moderate vascular ingurgitation, areas of hydropic epithelial degeneration, inflammatory infiltration with neutrophil prevalence, presence of hemorrhagic areas, edema, subepithelial microblister, and eventual ulceration, absence of abscesses; and 3 = severe vascular ingurgitation and dilatation, inflammatory infiltration with neutrophil prevalence, hemorrhagic areas, edema, subepithelial microblister, and extensive ulceration and abscesses.

Determination of myeloperoxidase (MPO) activity

MPO activity, a marker for neutrophils in inflamed tissue, was also measured in hamster cheek pouches using a modification of the method of Chen et al. (26).

Cheek-pouch samples ($n = 6$ per group) were removed under anesthesia on day 8 and stored at -70°C until required for assay. Samples were weighed and homogenized in 10 volumes of 50 mM potassium phosphate buffer (pH 6) containing 0.5% hexadecyltrimethyl ammonium bromide for 1 min. After freezing and thawing the homogenates thrice, they were centrifuged at $12,500 \times g$ at 4°C for 15 min. Supernatants were collected and reacted with 0.167 mg/mL *o*-dianisidine dihydrochloride and 0.0005% hydrogen peroxide in 50 mM phosphate buffer (pH 6). The activity of MPO was measured by spectrophotometric means (U-3210; Shimadzu, Tokyo) at 450 nm. MPO activity was calculated by the slope of absorbance calibrated by standard MPO (Wako) and expressed as units MPO/g cheek pouch.

Semi-quantitative reverse transcription–polymerase chain reaction (RT-PCR) for pro-inflammatory cytokines

Mucosal tissues were harvested on day 8 and ribonucleic acid (RNA) extracted using a QuickGene RNA Tissue kit S2 (Fujifilm Co., Ltd., Tokyo). Syntheses of complementary deoxyribonucleic acid (cDNA) were undertaken using a PrimeScript One Step RT-PCR kit ver. 2 (Takara Bio). The thermal cycles consisted of denaturation at 94°C for 1 min, annealing at 54°C for 1 min, and extension at 72°C for 1 min, followed by a final extension at 72°C for 5 min. Amplification was carried out for 35 cycles in a 2720 Thermal Cycler (Applied Biosystems, Foster City, CA, USA). The PCR amplified products were fractionated on 2.0% agarose gel and analyzed using a Dual Ultraviolet Transilluminator (Astec Co., Ltd., Fukuoka) and Image J software. After the scanned images were digitized and quantified, the values for each cytokine were normalized to those of β -actin. Each sample was analyzed in duplicate in all experiments. The primer sequences used are listed in Table 1 (27, 28).

Determination of KGF level

HPdLFs (1×10^4 cells) were added to 96-well flat-bottom tissue culture plates (Nunc, Roskilde, Denmark) and incubated at 37°C in a 5% CO_2 incubator for 3 days to allow cells to be in a semi-confluent condition. Cells

Table 1. Primer sequences used in this study

Name	Sequence	bp
TNF- α	Forward: 5'-CGTGTCTCTCACCACACT-3'	71
	Reverse: 5'-TGGCGGACAGGAGGTTGA-3'	
IL-1 β	Forward: 5'-GGCTGATGCTCCCATTCG-3'	156
	Reverse: 5'-CACGAGGCATTCTGTTGTTCA-3'	
β -actin	Forward: 5'-TCATGAAGTGTGACGTCGA-3'	106
	Reverse: 5'-GATCTCCTTCTGCATCCGGTC-3'	

were washed and then cultured with various concentrations of RJ in SCBM containing 5% fetal bovine serum (FBS), 1 ng/mL fibroblast growth factor (FGF), 50 μ g/mL gentamicin, and 50 ng/mL amphotericin-B. After incubation for the indicated times, supernatants were collected and the KGF level quantified by an enzyme-linked immunoassay (ELISA). Briefly, ELISA plates (Maxisoap, Nunc) were coated with 100 μ L anti-human KGF (0.5 μ g/mL) overnight at 4°C. After washing and blocking [1% bovine serum albumin (BSA) in phosphate-buffered saline (PBS)], the wells were seeded with 50 μ L of supernatant and incubated for 2 h at room temperature. After washing, 50 μ L of biotinylated anti-human KGF (0.2 μ g/mL) was added. After 2 h, the KGF level was determined using HRP-conjugated streptavidin, a substrate solution [0.1 mg/mL TMB in 0.1 M acetate buffer (pH 5.5)], and 0.004% H₂O₂. After the addition of stop solution (2 N H₂SO₄), the plates were read at 450 nm with an ELISA Reader (Model 680 Microplate Reader; Bio-Rad, Hercules, CA, USA).

Scavenging activity upon 1,1-diphenyl-2-picrylhydrazyl (DPPH) radicals

The DPPH assay was based on the method of Nagai et al. (29). The RJ sample solution (0.3 mL) was mixed with 0.3 mL of DPPH radical solution (1.0 mM) and 2.4 mL of ethanol (99%). The mixture was shaken vigorously and left to stand for 30 min in the dark. The absorbance was measured at 517 nm. The capability of the test material to scavenge DPPH radicals was calculated as (%) = $[1 - (\text{absorbance of the sample at 517 nm}) / (\text{absorbance of the control at 517 nm})] \times 100$.

Electron spin resonance (ESR) studies

ESR spectra were obtained on a JES-TE300 Spectrometer equipped with a ESPRIT-425 computer system (JEOL, Tokyo) at room temperature with a quartz flat cell. The field setting was at 336 mT for 5,5-dimethyl-1-pyrroline-*N*-oxide and 3,3,5,5-tetramethyl-1-pyrroline-*N*-oxide spin trapping in the presence of an Mn²⁺ marker. The scan range was 10 mT; the modulation frequency was 9.423 GHz; the modulation width was 0.1 mT; the microwave power was 8 mW; the sweep time was 2 min; and the time constant was 0.1 s.

Detection of superoxide and hydroxyl radicals by ESR spectrometry

To detect superoxide radicals, a solution of each chemical was mixed with 3,3,5,5-tetramethyl-1-pyrroline-*N*-oxide (12.5 mg/mL), hypoxanthine (0.5 mM), dimethyl sulfoxide (DMSO, 15%), and xanthine oxidase (0.05 U/mL) in 0.1 M phosphate buffer (pH 7.4) and kept at room temperature for 1 min for ESR spectrometry. To detect

hydroxyl radicals, a solution of each chemical at the indicated final concentration, 5,5-dimethyl-1-pyrroline-*N*-oxide (0.1 M), hydrogen peroxide (0.1 mM) and iron (II) sulfate (0.1 mM) were mixed in this final concentration in 0.1 M phosphate buffer and kept at room temperature for 5 min for ESR spectrometry. The scavenging activity of each chemical upon superoxide radicals and hydroxyl radicals was indicated as a percentage of the control and calculated as follows: Percentage of control = $(h_i/h_c) \times 100$, where h_i and h_c are the respective ESR signal intensities of the sample with and without RJ.

Statistical analyses

All results are represented as the group mean and standard errors of the mean, or the median. The data for oral mucositis were analyzed using two-way analysis of variance (ANOVA) with drug treatment as the between-subjects factor and time as the within-subject factor. Whenever the drug-treatment factor or the drug treatment factor \times time interaction was significant, a *post hoc* comparison was carried out. The *post hoc* individual comparisons were done using Dunnett's test or Student's *t*-test. The area under the curve (AUC) of oral mucositis, MPO activity, RT-PCR, and radical-scavenging activity were analyzed using one-way ANOVA followed by Dunnett's test. Kruskal–Wallis and Mann–Whitney tests were used to compare median values. $P < 0.05$ was considered significant.

Results

Figure 1 shows the release profile of RJ from the RJ film. The release of RJ from the film was maintained for 4 h, and approximately 50% of RJ was released within 1 h.

Figure 2 shows the effect of RJ films (10%, 30%) on oral mucositis induced by 5-FU in hamsters. The

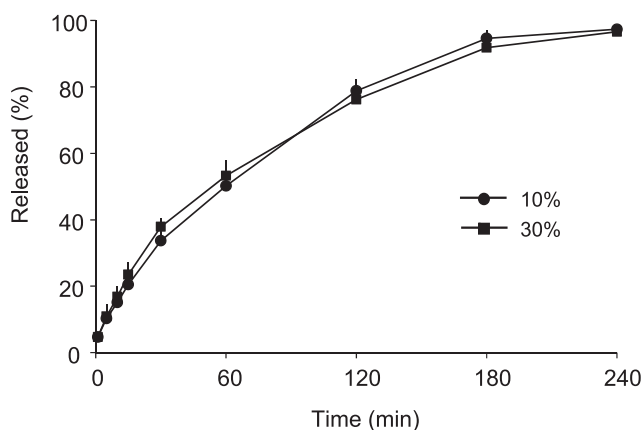


Fig. 1. Release profile of RJ from oral mucosal adhesive films. Each point represents the mean \pm S.D. ($n = 3$).

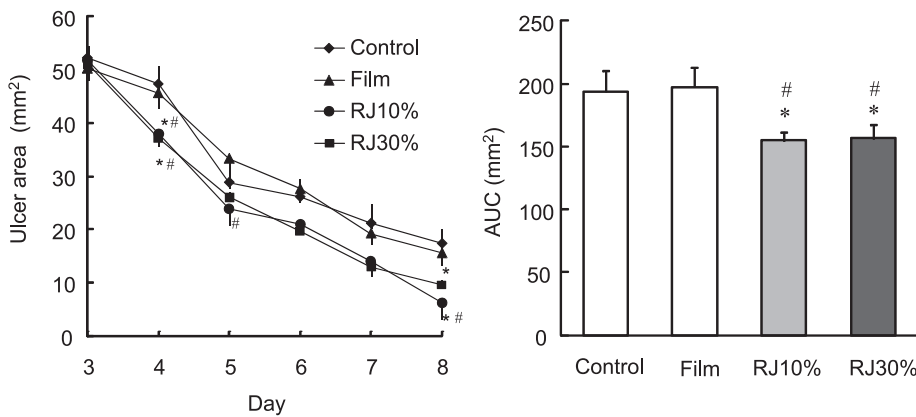


Fig. 2. Effect of topical application of RJ films on 5-FU-induced oral mucositis in hamsters. Each point represents the mean \pm S.E.M. of 12 hamsters per group. The bar chart represents the AUC between days 3 and 8 for each group. AUC was calculated from the summation of the ulcer area between days 3 and 8 for each group. * $P < 0.05$, significantly different from the control value, # $P < 0.05$, significantly different from the non-RJ film value (two-way or one-way ANOVA, followed by Dunnett's test).

Table 2. Macroscopic and microscopic analysis of hamster cheek pouch submitted to experimental OM and treated with RJ film on day 8

Experimental groups	Intact	5-FU		
		Control	RJ	
			10%	30%
Macroscopic analysis	0 (0–0)	2 (1–3)	1 (0–2) ^a	1 (0–2) ^a
Microscopic analysis	0 (0–0)	2 (2–3)	1 (1–2) ^a	1 (0–2) ^a

Data represents the median value (and range) of macroscopic scores in 12 or 6 animals per group. ^a $P < 0.05$, significantly different from the control value (Kruskal–Wallis and Mann–Whitney tests).

combination of intraperitoneal injection of 5-FU and mild abrasion of the cheek pouch caused oral mucositis on day 3. Thereafter, observation of mucositis showed that the lesions decreased in size with time. The film (which did not contain RJ) had no significant effect on the recovery from 5-FU-induced damage. However, RJ films that contained 10% and 30% RJ significantly reduced the area of mucositis in comparison with the control group ($P < 0.05$, two-way ANOVA). The AUC of oral mucositis between days 3 and 8 was decreased by RJ films ($P < 0.05$, one-way ANOVA).

Treatment with RJ films significantly improved recovery from 5-FU-induced damage, which presented as reduced erythema and absence of ulceration and abscesses on day 8 (Table 2).

MPO activity was increased significantly in the cheek-pouch tissue of hamsters subjected to 8 days of 5-FU-induced experimental oral mucositis ($P < 0.01$) in comparison with animals with intact cheeks. RJ films significantly reduced the 5-FU-induced increase in MPO activity ($P < 0.05$) (Fig. 3).

The histopathological analysis and grading system of hamster cheek pouches are shown in Fig. 4. The histopathology of the cheek pouches of hamsters subjected to 5-FU-induced oral mucositis revealed intense cellular infiltration with neutrophil prevalence and extensive

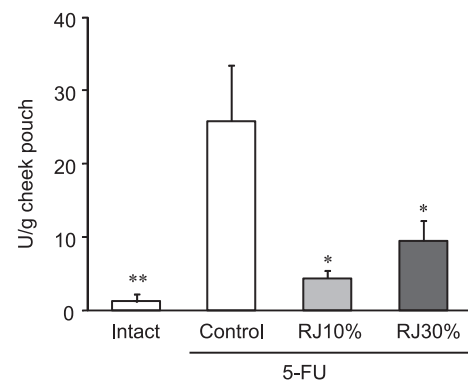


Fig. 3. Effect of topical application of RJ films on MPO activity in the cheek pouches of hamsters subjected to oral mucositis. Cheek pouches were removed on day 8. Data represent the mean \pm S.E.M. of 6 hamsters per group. * $P < 0.05$, ** $P < 0.01$, significantly different from the control value, (Student's *t*-test, one-way ANOVA, followed by Dunnett's test).

ulcers (Fig. 5B, Table 2) when compared with the normal cheek pouches of hamsters not subjected to oral mucositis (Fig. 5A, Table 2). Treatment with RJ films (10%, 30%) reduced the 5-FU-induced infiltration of inflammatory cells, ulceration, and formation of abscesses. Furthermore, areas of re-epithelization were observed (indicated by arrows in Fig. 5: C and D, Table 2).

At day 8, the mRNA levels of pro-inflammatory cytokines [tumor necrosis factor (TNF)- α and IL-1 β] increased in comparison with animals with intact cheeks. The mRNA levels of pro-inflammatory cytokines in RJ film-treated groups were significantly lower than those of the control group (Fig. 6: A and B).

Figure 7 shows the KGF generation from HPdLFs. Several concentrations of RJ had no effect on the KGF level in HPdLFs.

RJ showed scavenging activity upon DPPH radicals, superoxide radicals, and hydroxyl radicals. Each concentration of RJ sample displayed radical-scavenging

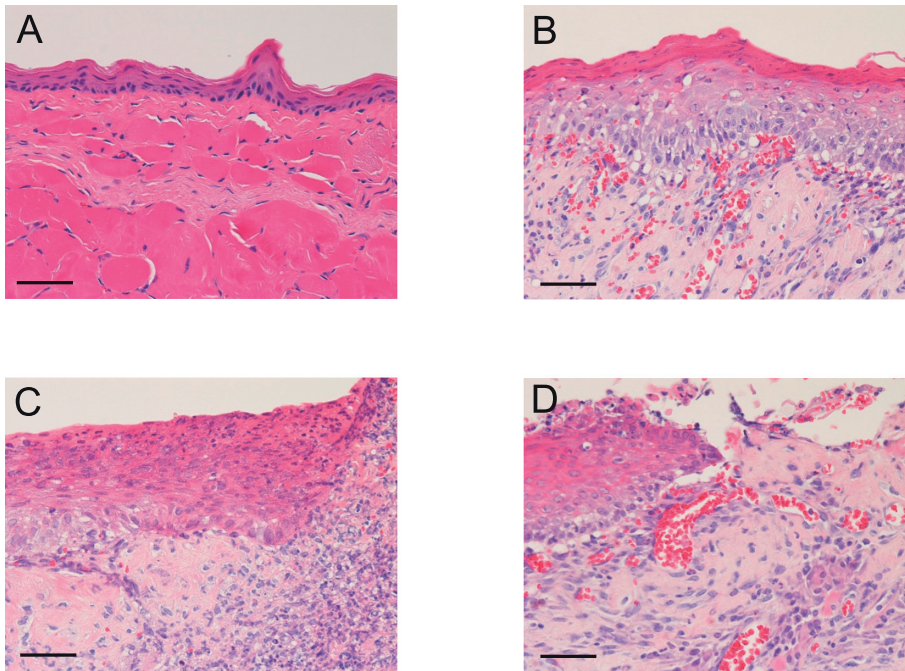


Fig. 4. Representative histopathological analysis of hamster cheek pouches and scoring system. score 0 (A), score 1 (B), score 2 (C), score 3 (D). Samples were removed and processed for H&E staining ($\times 400$ magnification) after the hamster was euthanized. Scale bar: 50 μm .

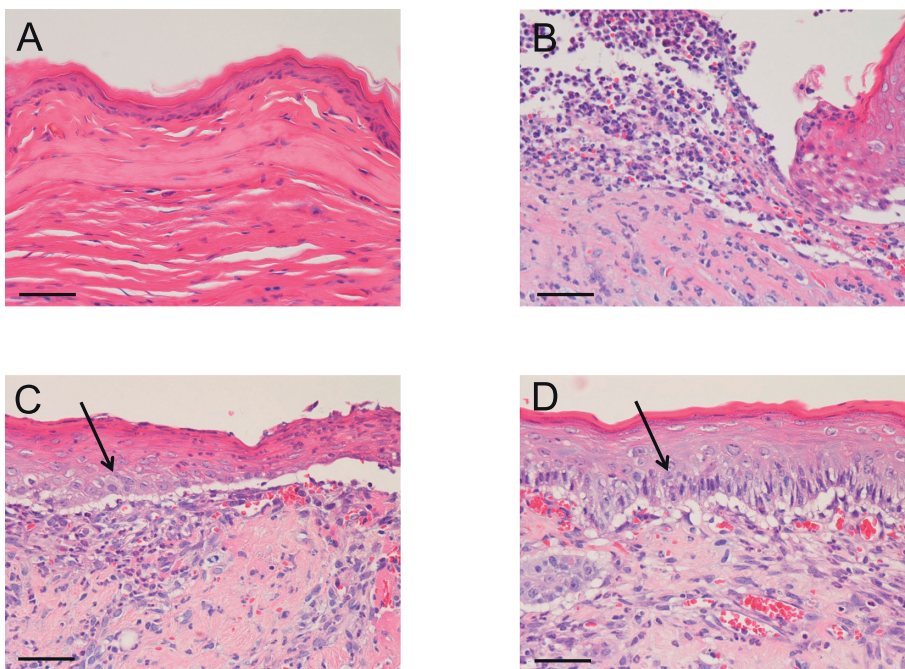


Fig. 5. Histopathological aspects of hamster cheek pouches: A) intact healthy mucosa; B) oral mucositis induced by 5-FU injection; C) oral mucositis induced by 5-FU, treatment with 10% RJ films; D) oral mucositis induced by 5-FU, treatment with 30% RJ films. Samples were removed and processed for H&E staining ($\times 400$ magnification) after the hamster was euthanized. Scale bar: 50 μm .

activity. RJ (1%, 10%) could significantly scavenge each free radical species compared with 0.1% RJ ($P < 0.01$) (Fig. 8).

Discussion

Oral mucositis is a complex process initiated by injury to cells in the basal epithelium and underlying tissue.

The probable mechanisms of oral mucositis induced by chemotherapy involve complex biological events mediated by several inflammatory cytokines such as $\text{TNF-}\alpha$, IL-1, and IL-6; the direct effect of chemotherapeutic drugs upon the basal epithelium and connective tissue; and the oral microbial environment (30). Additionally, it is thought that the development of oxidative stress and generation of reactive oxygen species (ROS)

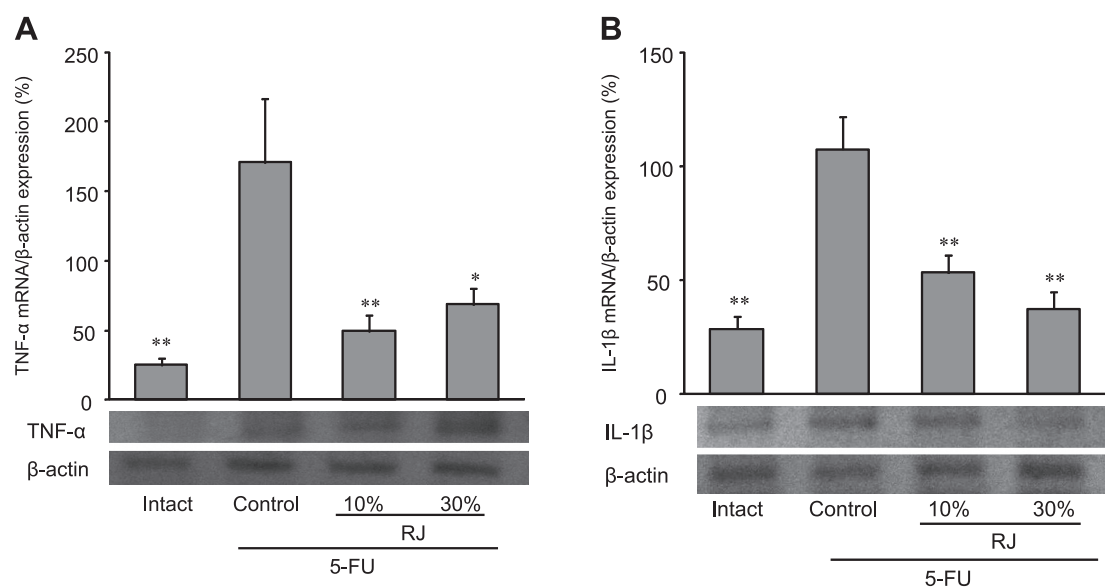


Fig. 6. Effect of RJ films on pro-inflammatory cytokine (A: TNF- α , B: IL-1 β) mRNA expression in hamster cheek pouches. Cheek pouches were removed on day 8. Data represent the mean \pm S.E.M. of 6 hamsters per group. * P < 0.05, ** P < 0.01, significantly different from the control value (Student's t -test, one-way ANOVA, followed by Dunnett's test).

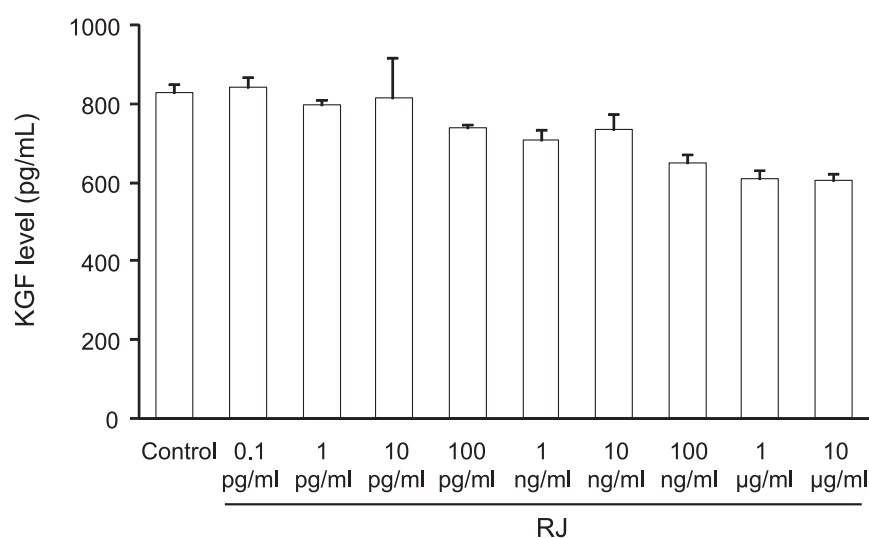


Fig. 7. KGF secreted from HPdLFs 120 h after stimulation with RJ. Data represent the mean \pm S.E.M. of three samples per group.

by chemotherapeutic agents or radiation are primary events in most pathways leading to mucositis. Moreover, ulcerative mucositis results in the destruction of the oral mucosa as an anatomical barrier. The mouth thus becomes a portal of entry for enteric bacteria, viruses, and fungi. Hence, ulceration of the oral mucosa results in an increased risk of infection, particularly during immunosuppression (31).

We previously found that topical application of RJ ointment decreased the ulcer area of oral mucositis induced by 5-FU in hamsters (18). The present study demonstrated clearly that treatment with RJ films signifi-

cantly reduced the lesions found in 5-FU-induced oral mucositis. On days 6 and 7, a significant difference in the ulcer area between the controls and RJ film-treated group was not observed. Thus, the use of RJ films may be more effective in the early stages of oral mucositis than in the late stages. The treatment significantly decreased ulcer area, infiltration of inflammatory cells, ulceration, and formation of abscesses. Furthermore, expression levels of pro-inflammatory cytokines were significantly decreased by RJ films.

It is well known that sodium alginate fiber dressing material is effective for treating wounds of the buccal

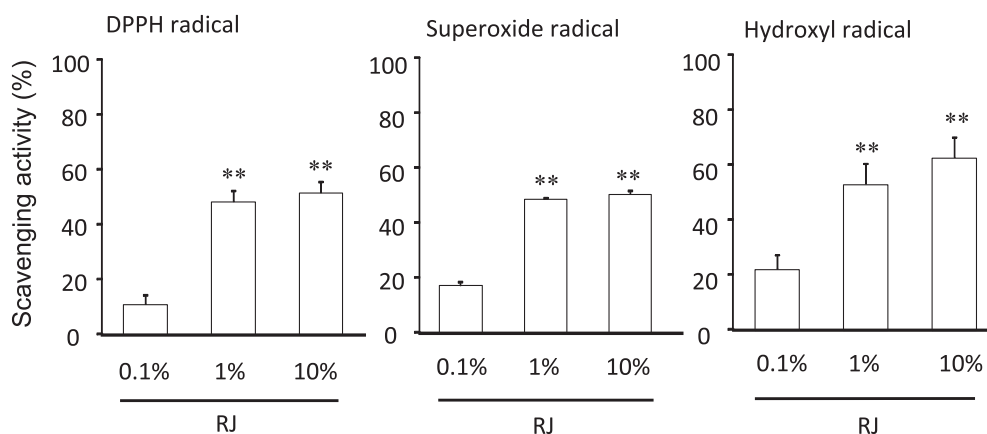


Fig. 8. Scavenging activity of RJ upon several species of free radicals. The capability of RJ to scavenge free radicals was represented as a percentage of the control value. Data represents the mean \pm S.E.M. of four samples per group. Data represent the mean \pm S.E.M. of four samples per group. ** $P < 0.01$, significantly different from the control value (one-way ANOVA, followed by Dunnett's test).

mucosa, and clinical studies have reported the reparative effect of sodium alginate solution on radiation-induced oral mucositis (2). However, films without RJ had no effect on 5-FU-induced oral mucositis in hamsters. Additionally, our previous study showed that films without drugs had no effects (32). Sodium alginate is a water-soluble and swellable polymer and is an excellent candidate for delivering drugs (33, 34). In fact, the sustained release of RJ from films was shown in the present study. These results suggested that the film formulation was effective for RJ release. Therefore, films that use sodium alginate-chitosan improve the healing effect of RJ on oral mucositis as a result of their drug-eluting properties.

It was not possible to mix $> 30\%$ of RJ with film, so the present study examined the effects of 10% and 30% of RJ film. The results showed a significant ameliorating effect of RJ films on the oral mucositis induced by 5-FU in hamsters. RJ contains a considerable amount of various proteins, free amino acids, lipids, vitamins, and sugars; and it is known to have diverse nutritional and pharmacological functions such as anti-bacterial (14), anti-allergic (15), and wound-healing actions (17). Recent studies have suggested that RJ efficiently inhibits the production of pro-inflammatory cytokines such as TNF- α , IL-1, and IL-6 by lipopolysaccharide- and interferon gamma-stimulated macrophages (35). Therefore, a mucosal-protective effect and a tissue repair-promoting action might be involved in the mechanism of the healing effect of RJ.

In the *in vitro* study, KGF generation from HPdLFs was not observed. RJ showed scavenging activity upon DPPH radicals, superoxide radicals, and hydroxyl radicals. Therefore, in the healing effect of RJ on oral mucositis,

radical-scavenging activity is more important than KGF generation. ROS such as hydroxyl radicals directory damage cells, tissues, and blood vessels. ROS activation and their subsequent ability to stimulate several transcription factors seem to characterize the tissue response to stomatotoxic damage. Transcription factors such as nuclear factor- κ B lead to the up-regulation of many genes, including those that result in the production of pro-inflammatory cytokines. Therefore, for agents to protect cells from free-radical damage is very important for the healing of oral mucositis.

In conclusion, the results of the present study suggest that treatment with RJ films has a healing effect on the oral mucositis induced by 5-FU through anti-inflammatory and antioxidative actions.

Acknowledgments

This work was supported by the Japanese Health Science Foundation and a Grant-in-Aid for Scientific Research (grant number 19590537) from the Japanese Ministry of Education, Culture, Sports, Science and Technology in Japan.

References

- 1 Yamamura K, Ohta S, Yano K, Yotsuyanagi T, Okamura T, Nabeshima T. Oral mucosal adhesive film containing local anesthetics: *in vitro* and clinical evaluation. *J Biomed Mater Res.* 1998;43:313–317.
- 2 Oshitani T, Okada K, Kushima T, Suematsu T, Obayashi K, Hirata Y, et al. [Clinical evaluation of sodium alginate on oral mucositis associated with radiotherapy]. *Nippon Gan Chiryo Gakkai Shi.* 1990;25:1129–1137. (text in Japanese with English abstract)
- 3 Fujiwara M, Kamikonya N, Tuboi K, Irie M, Izumi M, Irie T, et al. [Efficacy and safety of polaprezinc as a preventive drug for radiation-induced stomatitis]. *Nihon Igaku Hoshasen Gakkai*

- Zasshi. 2002;62:144–150. (text in Japanese with English abstract)
- 4 Matsukura T, Tanaka H. Applicability of zinc complex of L-carnosine for medical use. *Biochemistry (Mosc.)*. 2000;65: 817–823.
- 5 Matsuda T, Ohno S, Hirohata S, Miyanaga Y, Ujihara H, Inaba G, et al. Efficacy of rebamipide as adjunctive therapy in the treatment of recurrent oral aphthous ulcers in patients with Behcet's disease: a randomised, double-blind, placebo-controlled study. *Drugs R&D*. 2003;4:19–28.
- 6 Rubenstein EB, Peterson DE, Schubert M, Keefe D, McGuire D, Epstein J, et al. Mucositis study section of the multinational association for supportive care in cancer; International Society for Oral Oncology. Clinical practice guidelines for the prevention and treatment of cancer therapy-induced oral and gastrointestinal mucositis. *Cancer*. 2004;100:2026–2046.
- 7 Sonis ST. Mucositis as a biological process: a new hypothesis for the development of chemotherapy-induced stomatotoxicity. *Oral Oncol*. 1998;34:39–43.
- 8 Sonis ST, Van Vugt AG, McDonald J, Dotoli E, Schwertschlag U, Szklut P, et al. Mitigating effects of interleukin 11 on consecutive courses of 5-fluorouracil-induced ulcerative mucositis in hamsters. *Cytokine*. 1997;9:605–612.
- 9 McCormack ES, Borzillo GV, Ambrosino C, Mak G, Hamablet L, Qu GY, et al. Transforming growth factor-beta 3 protection of epithelial cells from cycle-selective chemotherapy in vitro. *Biochem Pharmacol*. 1997;53:1149–1159.
- 10 Saarialhti K, Kajanti M, Joensuu T, Kouri M, Joensuu H. Comparison of granulocyte-macrophage colony-stimulating factor and sucralfate mouthwashes in the prevention of radiation-induced mucositis: a double-blind prospective randomized phase III study. *Int J Radiat Oncol Biol Phys*. 2002;54:479–485.
- 11 Spielberger R, Stiff P, Bensinger W, Gentile T, Weisdorf D, Kewalramani T, et al. Palifermin for oral mucositis after intensive therapy for hematologic cancers. *N Engl J Med*. 2004; 351:2590–2598.
- 12 Freytes CO, Ratanatharathorn V, Taylor C, Abboud C, Chesser N, Restrepo A, et al. Phase I/II randomized trial evaluating the safety and clinical effects of repifermin administered to reduce mucositis in patients undergoing autologous hematopoietic stem cell transplantation. *Clin Cancer Res*. 2004;10:8318–8324.
- 13 Biswal BM, Zakaria A, Ahmad NM. Topical application of honey in the management of radiation mucositis: a preliminary study. *Support Care Cancer*. 2003;11:242–248.
- 14 Fujiwara S, Imai J, Fujiwara M, Yaeshima T, Kawashima T, Kobayashi K. A potent antibacterial protein in royal jelly. Purification and determination of the primary structure of royalisin. *J Biol Chem*. 1990;265:11333–11337.
- 15 Okamoto I, Taniguchi Y, Kunikata T, Kohno K, Iwaki K, Ikeda M, et al. Major royal jelly protein 3 modulates immune responses in vitro and in vivo. *Life Sci*. 2003;73:2029–2045.
- 16 Liu JR, Yang YC, Shi LS, Peng CC. Antioxidant properties of royal jelly associated with larval age and time of harvest. *J Agric Food Chem*. 2008;56:11447–11452.
- 17 Fujii A, Kobayashi S, Kuboyama N, Furukawa Y, Kaneko Y, Ishihama S, et al. Augmentation of wound healing by royal jelly (RJ) in streptozotocin-diabetic rats. *Jpn J Pharmacol*. 1990;53: 331–337.
- 18 Suemaru K, Cui R, Li B, Watanabe S, Okihara K, Hashimoto K, et al. Topical application of royal jelly has a healing effect for 5-fluorouracil-induced experimental oral mucositis in hamsters. *Methods Find Exp Clin Pharmacol*. 2008;30:103–106.
- 19 Aksungur P, Sungur A, Unal S, Iskit AB, Squier CA, Senel S. Chitosan delivery systems for the treatment of oral mucositis: in vitro and in vivo studies. *J Control Release*. 2004;98:269–279.
- 20 Oguchi M, Shikama N, Sasaki S, Gomi K, Katsuyama Y, Ohta S, et al. Mucosa-adhesive water-soluble polymer film for treatment of acute radiation-induced oral mucositis. *Int J Radiat Oncol Biol Phys*. 1998;40:1033–1037.
- 21 Arakawa Y, Kawakami S, Yamashita F, Hashida M. Effect of low-molecular-weight beta-cyclodextrin polymer on release of drugs from mucoadhesive buccal film dosage forms. *Biol Pharm Bull*. 2005;28:1679–1683.
- 22 Lowry OH, Rosebrough NJ, Farr AL, Randall RJ. Protein measurement with the Folin phenol reagent. *J Biol Chem*. 1951; 193:265–275.
- 23 Sonis ST, Tracey C, Shklar G, Jensen J, Florine D. An animal model for mucositis induced by cancer chemotherapy. *Oral Surg Oral Med Oral Pathol*. 1990;69:437–443.
- 24 Lima V, Brito GA, Cunha FQ, Rebouças CG, Falcão BA, Augusto RF, et al. Effects of the tumour necrosis factor-alpha inhibitors pentoxifylline and thalidomide in short-term experimental oral mucositis in hamsters. *Eur J Oral Sci*. 2005;113: 210–217.
- 25 Leitão RF, Ribeiro RA, Bellaguarda EA, Macedo FD, Silva LR, Oriá RB, et al. Role of nitric oxide on pathogenesis of 5-fluorouracil induced experimental oral mucositis in hamster. *Cancer Chemother Pharmacol*. 2007;59:603–612.
- 26 Chen J, Shen H, Nagasawa Y, Mitsui K, Tsurugi K, Hashimoto K. Pravastatin inhibits arrhythmias induced by coronary artery ischemia in anesthetized rats. *J Pharmacol Sci*. 2007;103:317–322.
- 27 Cho SA, Park JH, Seok SH, Juhn JH, Kim SJ, Ji HJ, et al. Effect of granulocyte macrophage-colony stimulating factor (GM-CSF) on 5-FU-induced ulcerative mucositis in hamster buccal pouches. *Exp Toxicol Pathol*. 2006;57:321–328.
- 28 Matsui M, Rouleau V, Bruyère-Ostells L, Goarant C. Gene expression profiles of immune mediators and histopathological findings in animal models of leptospirosis: comparison between susceptible hamsters and resistant mice. *Infect Immun*. 2011; 79:4480–4492.
- 29 Nagai T, Inoue R, Suzuki N, Nagashima T. Antioxidant properties of enzymatic hydrolysates from royal jelly. *J Med Food*. 2006; 9:363–367.
- 30 Scully C, Sonis S, Diz PD. Oral mucositis. *Oral Dis*. 2006;12: 229–241.
- 31 Zegarelli DJ. Fungal infections of the oral cavity. *Otolaryngologic clinics of North Am*. 1993;26:1069–1089.
- 32 Watanabe S, Suemaru K, Yamaguchi T, Hidaka N, Sakanaka M, Araki H. Effect of oral mucosal adhesive films containing ginsenoside Rb1 on 5-fluorouracil-induced oral mucositis in hamsters. *Eur J Pharmacol*. 2009;616:281–286.
- 33 Miyazaki S, Nakayama A, Oda M, Takada M, Attwood D. Chitosan and sodium alginate based bioadhesive tablets for intraoral drug delivery. *Biol Pharm Bull*. 1994;17:745–747.
- 34 Qurrat-ul-Ain, Sharma S, Khuller GK, Garg SK. Alginate-based oral drug delivery system for tuberculosis: pharmacokinetics and therapeutic effects. *J Antimicrob Chemother*. 2003;51:931–938.
- 35 Kohno K, Okamoto I, Sano O, Arai N, Iwaki K, Ikeda M, et al. Royal jelly inhibits the production of proinflammatory cytokines by activated macrophages. *Biosci Biotechnol Biochem*. 2004;68: 138–145.