

# Gonadotropin-Releasing Hormone Analog Therapy Failed to Improve Predicted Final Height in Two Children with Central Precocious Puberty and Microcephalus

KOJI OKUHARA, TOSHIHIRO TAJIMA, SHUJI ABE, KOHEI SATOH, JUN NAKAE, NOZOMI SHINOHARA AND KENJI FUJIEDA\*

*Department of Pediatrics, Hokkaido University School of Medicine, Sapporo 060–7898, Japan*

**Abstract.** Long-acting gonadotropin-releasing hormone (GnRH) analog treatment for central precocious puberty (CPP) suppresses excessive bone maturation by inhibiting the pituitary-gonadal axis, and usually assures favorable results for growth potential. Recently, we encountered two children with CPP and microcephalus in whom GnRH analog therapy arrested pubertal development, but could not suppress bone age maturation effectively. Eventually, their final height deteriorated rather than improved. The reason why these two cases did not respond to GnRH analog therapy remains unknown. However, microcephalus and minor cerebral anomalies may have some links to deterioration of final height. Our cases suggest that careful evaluation will be required especially for CPP with microcephalus throughout treatment with GnRH analog.

**Key words:** GnRH analog, Central precocious puberty, Microcephalus

(*Endocrine Journal* 47: S129–S132, 2000)

**CENTRAL** precocious puberty (CPP) is accompanied by a discordant increase in the rate of skeletal maturation resulting in premature epiphyseal closure and ultimately in short adult height. The objectives of therapy for CPP are to normalize final adult height and to avoid psychosocial problems caused by early pubertal development. A long-acting gonadotropin-releasing hormone (GnRH) analog acts as an agonist in gonadotropin secretion inhibiting the pituitary-gonadal axis, thereby resulting in suppression of pubertal development and bone maturation [1]. Therefore, GnRH analog has been currently used for the treatment of CPP to decelerate bone age maturation and improve final adult height [1–5]. Several preliminary reports have demonstrated that final height can be improved by this treatment [1–5]. Nevertheless, we encountered two children with CPP and microcephalus in whom unfavorable

outcomes on final height were observed by GnRH analog treatment.

## Case reports

### *Patient 1*

The patient was a 17 years old boy. The patient was delivered after 39 weeks of gestation by normal vaginal delivery. His birth height was 42.5 cm, weight 2600 g, and head circumference 31 cm (–4SD below the mean; microcephalus). Development delay was evident from infancy. He was referred to our clinic because of development of secondary sex characteristics at age 4.6 years. When examined, his height was 94 cm (–2.2SD for chronological age), weight 12 kg (–14.3% of BMI), and head circumference was (–4.9SD). His bone age was advanced (7 years old by the G-P atlas) for chronological age. He had stage 2 pubic hair, the testes were 2×3 cm and his penis was enlarged. Erection was noticed,

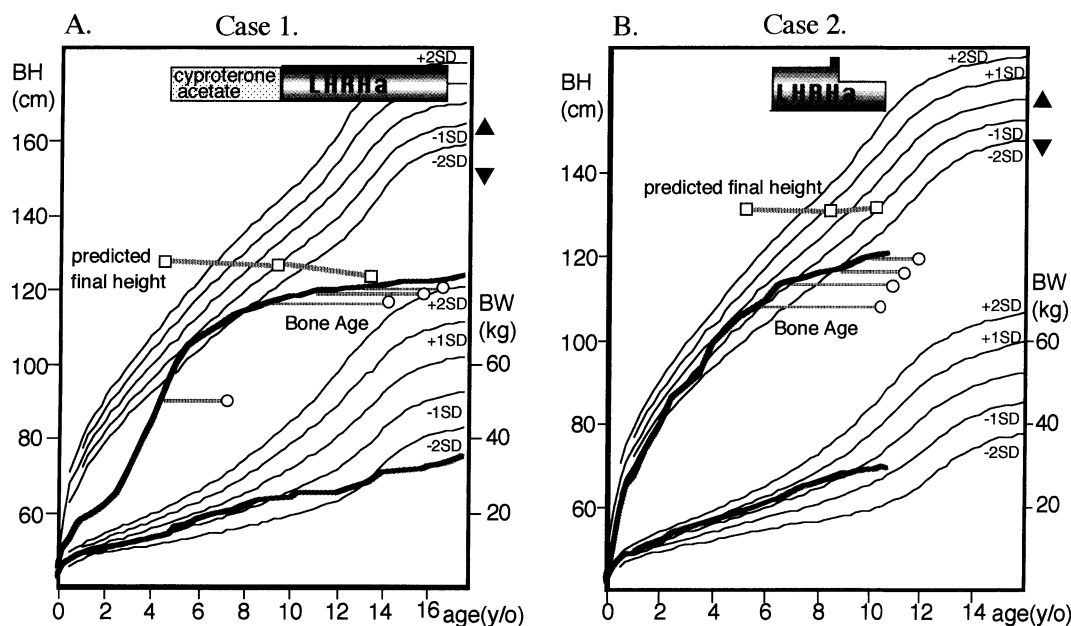
\* Correspondence to: Kenji FUJIEDA, M.D., PhD, Department of Pediatrics, Hokkaido University School of Medicine, Sapporo 060–7898, Japan

and he showed increased behavior activity levels and aggressiveness. Endocrine findings revealed that basal serum luteinizing hormone (LH) was 14.9 mIU/ml (RIA; normal prepubertal male 0.7–7.9 mIU/ml), follicle-stimulating hormone (FSH) was 4.5 mIU/ml (RIA; normal prepubertal male 0.3–7.0 mIU/ml), and that testosterone was 43.0 ng/ml. After 100 mg of intravenous LH-releasing hormone (LH-RH) injection, LH level increased from 7.2 to 148.8 mIU/ml, and FSH level increased from 6.1 to 13.9 mIU/ml. Other anterior pituitary hormone values were normal. Brain computed tomography (CT) scanning and magnetic resonance imaging (MRI) revealed bilateral ectopic gray matter. Based on these findings, he was diagnosed as having CPP. To control his emotional and behavioral disturbance, he was treated with cyproterone acetate, which did not affect his sexual development, bone age advancement and emotional disturbance. Serum testosterone levels were not suppressed completely, and at the age of 9.2 years, GnRH analog subcutaneous injection (30 mg/kg) once a month was

commenced instead of cyproterone acetate. At that time his bone age was 14 years. This therapy resulted in the arrest of his aggressiveness and the decrease in serum concentrations of testosterone and LH. Responses of LH and FSH to exogenous LH-RH also decreased. His height was 123.7 cm ( $-8.3SD$ ), and bone age was 16.6 years at the time of cessation of this treatment when he was 12.9 years. Growth was not improved after GnRH analog treatment (Fig. 1-A).

### Patient 2

The proband was a girl born as a small for date infant after a normal pregnancy by spontaneous delivery at 37 weeks of gestation. Her birth weight was 1970 g and height 42.5 cm. She revealed microcephalus (head circumference was 27.5 cm,  $-4SD$  below the mean) by unknown origin. Her psychomotor developmental milestones delayed. Breast development was recognized from 3 years of age, and menstrual flow commenced at the age of



**Fig. 1.** Growth charts of two cases are shown (A; case 1, B; case 2). Open circles and open squares indicate bone age estimated by the G-P atlas for height and predicted final height at each chronological age respectively. On the upper right axis, the triangle indicates height of the father, and the inverted triangle indicates that of the mother. **A;** At the start of GnRH analog therapy, the predicted final height was 127.7 cm and height-SDS for bone age  $-5.1SD$ . With this therapy the predicted final height decreased resulting in 123.7 cm of final height ( $-8.3SD$ ). **B;** When GnRH analog therapy started, the predicted final height was 132 cm and height-SDS for bone age  $-4.3SD$ . Her target height calculated from the parents' height was 147.5 cm. At the time of cessation of this therapy, the predicted final height remained 132.5 cm and height-SDS for bone age  $-4.4SD$ .

6.3 years. Therefore she was admitted to our hospital for the endocrine evaluation. At this time, her height was 110.9 cm ( $-0.8SD$ ), weight was 21.7 kg ( $+13.6\%$  of BMI), and head circumference was 41.5 cm ( $-6.5SD$ ). The breasts were Tanner III and pubic hair was stage II. Bone age was estimated to be 10.5 years by the G-P atlas. Endocrine examinations showed that the basal serum LH was 2.69 mIU/ml and the LHRH stimulated LH level was 22.54 mIU/ml (TR-FIA). The basal FSH level was 6.35 mIU/ml and the LHRH stimulated FSH level was 12.83 mIU/ml (TR-FIA). GH, TSH, Prolactin and ACTH did not show abnormal responses. Serum estradiol was 14.0 pg/ml. Plasma insulin-like growth factor (IGF-1) level was 224.0 ng/ml. Abdominal ultrasonography demonstrated mature uterus and ovaries. Brain MRI showed Rathke's cleft cyst in the pituitary. She was diagnosed as CPP, and GnRH analog therapy (from 70 to 40 mg/kg/month, subcutaneous injection) started to improve her predicted height. Subsequently, there was a fall in serum concentrations of LH, FSH and estradiol to prepubertal levels, and menstruation ceased by GnRH analog. In spite of these clinical and endocrine changes, her growth potential was distorted after GnRH analog therapy (Fig. 1-B). Her bone age reached 12 years at the age of 10.5 years when this treatment was stopped.

## Discussion

These two cases revealed unfavorable responses on bone maturation and growth potential by GnRH analog therapy. Their bone ages had been slowly advancing during GnRH therapy (bone age for

chronological age was 9.2 for 14 years at the initiation and 12.9 for 16.6 years at the cessation in patient 1, 10.5 for 6.4 years and 12 for 10.5 years in patient 2) in spite of decreasing of growth velocity. In patient 1, his final height (123.7 cm,  $-8.3SD$ ) was 4 cm lower than predicted final height calculated by the method of Ito and Yokoya for Japanese children based on Bayley-Pinneau's hypothesis [6] at the time of initiation of GnRH analog treatment. Growth velocity was also strikingly deteriorated after initiation of therapy in patient 2. Further, height-SDS for bone age of both cases was not improved throughout the GnRH analog therapy (in patient 1, from  $-6.3SD$  to  $-8.4SD$  and in patient 2, from  $-4.3SD$  to  $-4.4SD$ ). Oyama *et al.* reported that the clinical usefulness of this treatment was not different in patients with idiopathic and organic CPP, however, cases of microcephalus were not mentioned [2]. To our knowledge, there is no report of patients with CPP and microcephalus treated by GnRH analog. The reason why our cases revealed unfavorable results remains unknown. It is well recognized that the prognosis for final height is better in young CPP patients who are detected and treated at a much earlier age [2-5]. Therefore, there is a possibility that the initiation of therapy in these two cases with far advanced bone age was too late. In addition, microcephalus and minor cerebral anomalies may be somehow related to failure of treatment, considering the remarkable impairment of growth velocity compared with other CPP patients treated by GnRH analog [1-5].

In conclusion, our results suggest that patients with CPP and microcephalus should be evaluated very carefully during GnRH analog treatment.

## References

1. Comite F, Cutlar GB, Rivir J (1981) Short-term treatment of idiopathic precocious puberty with a long-acting analog of luteinizing hormone-releasing hormone. *New Engl J Med* 305: 1546-1550.
2. Oyama K, Tanaka T, Tachibana K, Niimi H, Fujieda K, Matsuo N, Satoh M, Hibi I and members of the TAP-144SR CPP Study Group (1998) Timing for discontinuation of treatment with a long-acting gonadotropin-releasing hormone analog in girls with central precocious puberty. *Endocr J* 45: 351-356.
3. Paul D, Conte FA, Grumbach MM, Kaplan SL (1995) Long term effect of gonadotropin releasing hormone agonist therapy on final and near final height in 26 children with true precocious puberty treated at a median age of less than 5 years. *J Clin Endocrinol Metab* 80: 546-551.
4. Tanaka T, Niimi H, Matsuo N, Fujieda K, Tachibana K, Oyama K, Satoh M, Hibi I and the TAP-144-SR CPP Study Group (1997) Dose of LHRH analog and growth velocity influence predicted final height in girls

- with central precocious puberty. *Clin Pediatr Endocrinol* 6: 77–84.
5. Brauner R, Adan L, Malandry F, Zantleifer D (1994) Adult height in girls with idiopathic true precocious puberty. *J Clin Endocrinol Metab* 79: 415–420.
  6. Ito R, Yokoya S (1995) Prediction of final height in Japanese children using Bayley-Pinneau's hypothesis. *J Jpn Pediatr Soc* 99: 1788–1795.