

## Zygomatic Sialolithiasis Diagnosed with Computed Tomography in a Dog

Namsoon LEE<sup>1)</sup>, Mihyun CHOI<sup>1)</sup>, Seoyeon KEH<sup>1)</sup>, Taehyun KIM<sup>1)</sup>, Hyunwook KIM<sup>1)</sup> and Junghee YOON<sup>2)\*</sup>

<sup>1)</sup>Haemaru Referral Animal Hospital, Seongnam-Si, Gyeonggi-do 463-050, Republic of Korea

<sup>2)</sup>College of Veterinary Medicine and the Research Institute for Veterinary Science, Seoul National University, Seoul 151-742, Republic of Korea

(Received 20 March 2014/Accepted 30 May 2014/Published online in J-STAGE 19 June 2014)

**ABSTRACT.** A 10-year-old castrated Shih-Tzu male dog was referred for examination of acute right exophthalmos, protrusion of the third eyelid and soft tissue swelling ventral to the globe. Ultrasonography revealed echogenic fluid around the right globe. Computed tomography (CT) showed an enlarged right zygomatic salivary gland compared with the left zygomatic gland and an amorphous cystic mass ventral to the right globe. Hyperdense material, which we suspected to be a sialolith, was identified in the right zygomatic gland. The zygomatic gland and the cystic lesion were removed, and a zygomatic sialocele with sialolith and ductal obstruction were found by histopathological examination. CT was a useful diagnostic tool for zygomatic sialolithiasis.

**KEY WORDS:** canine, computed tomography, sialocele, sialolithiasis, zygomatic gland

doi: 10.1292/jvms.14-0151; *J. Vet. Med. Sci.* 76(10): 1389–1391, 2014

Sialolithiasis is defined as the formation of calcified secretions in a salivary gland or duct, and canine sialolithiasis is a rare condition [8, 9, 21]. In a histopathological study of salivary gland disease in dogs and cats, the incidence of sialolithiasis was found to be 0.4% [9].

Canine sialolithiasis has been reported to affect the parotid salivary gland and duct, as well as the sublingual and mandibular salivary glands [4, 5, 7, 9, 16, 19, 24, 25]. To our knowledge, this is the first report describing zygomatic sialolithiasis as a cause of sialocele in a dog.

A 10-year-old castrated Shih-Tzu male dog was referred for examination of acute right exophthalmos. There was no known history of trauma. Ophthalmologic examination of the right eye found protrusion of the third eyelid and gland. On physical examination, a fluctuant and non-painful soft tissue mass was palpable around the right zygomatic bone. The dog had no pain upon opening of the mouth and intra-oral swelling and did not have remarkable periodontitis. Aspiration of the soft tissue mass produced a viscous material, suggestive of saliva. Cytology analysis revealed the presence of numerous degenerative neutrophils. A zygomatic salivary mucocele was suspected, and the dog was admitted for further investigation.

Plain skull radiographs showed no remarkable findings, except for protrusion of the right eye (Fig. 1). On ocular ultrasonography (Prosound Alpha 6; Hitachi Aloka Medical, Tokyo, Japan), intraocular structure was normal, but cyst-like structures with amorphous hyperechoic material appeared around the right retrobulbar region (Fig. 2). A ret-

robulbar mass was suspected, and computed tomography (CT) examination (Asteion Super 4; Toshiba, Tokyo, Japan) of the skull was performed for accurate evaluation of the retrobulbar lesion. CT was performed with 150 mA, 120 kV, beam pitch 1 and 1 mm slice thickness. A contrast study was performed 2–3 min after intravenous injection of 850 mgI/kg iohexol (Omnipaque; GE Healthcare Co., Ltd., Shanghai, China). CT images showed cystic materials around the right globe and zygomatic salivary gland, which induced dorso-cranial displacement of the right globe. The right zygomatic gland was enlarged with irregular margin, but had similar contrast enhancement when compared to the left side. And, the affected zygomatic gland had small cystic lesions, and a focal hyperdense object, suspected to be a sialolith, was located in the right zygomatic salivary gland, caudal to the last molar tooth (Fig. 3).

The zygomatic gland and the cystic lesions were removed. Histopathological examination of the zygomatic gland showed extrusion of mucus from the salivary gland into the adjacent connective tissue. In addition, there was a large mineralized structure occluding one of the ducts of the

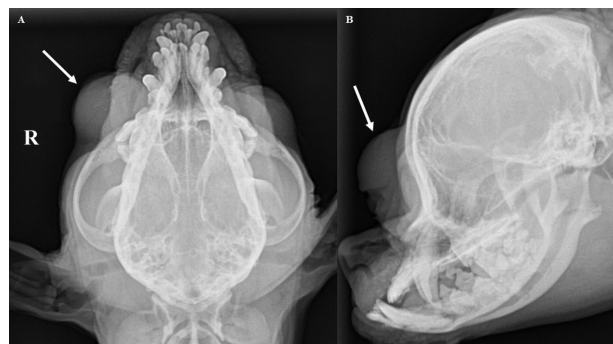


Fig. 1. Dorsoventral view (A) and right lateral view (B) of skull radiographs show protrusion of right eye (arrows). There are not severe bony changes by skull neoplasia and remarkable periodontitis.

\*CORRESPONDENCE TO: YOON, J., College of Veterinary Medicine and the Research Institute for Veterinary Science, Seoul National University, Seoul 151-742, Republic of Korea.  
e-mail: heeyoon@snu.ac.kr

©2014 The Japanese Society of Veterinary Science

This is an open-access article distributed under the terms of the Creative Commons Attribution Non-Commercial No Derivatives (by-nc-nd) License <<http://creativecommons.org/licenses/by-nc-nd/3.0/>>.

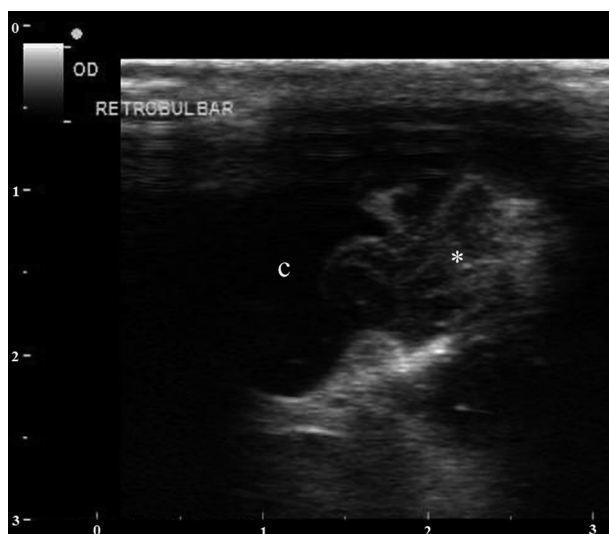

Fig. 2. Ocular ultrasonography. Cyst-like structure (c) with amorphous hyperechoic material (asterisk) appears around the right retrobulbar region.

gland (Fig. 4). These findings were consistent with a salivary mucocele associated with ductal obstruction by a sialolith. After the surgical procedure, ocular signs were resolved, and the dog was discharged.

The zygomatic salivary gland, in comparison with other salivary glands, is the least frequently involved in pathological conditions in dogs [1]. Because the zygomatic gland is located ventral to the zygomatic arch, mild changes cannot be detected in the early stages of pathology. Also, the clinical signs may be similar to the signs of other retrobulbar disease [11]. Therefore, diagnostic imaging can be useful to differentiate zygomatic gland disease from other retrobulbar disease.

Plain skull radiographs may help to screening examination whether there are severe bony changes by skull neoplasia and remarkable periodontitis. And, diagnosis of canine sialolithiasis was based on results of plain radiography in previous reports [5, 25]. But, sialolith was not shown due to bony structure of orbit around zygomatic gland in this case. Ultrasonography provided useful information about normal intraocular status and cystic retrobulbar lesion. These findings suggested a retrobulbar mass. But, ultrasonography may not detect the abnormalities in dogs with zygomatic gland disease, and the echotextural features of retrobulbar disease are not closely correlated with the histopathological diagnosis [2, 11–13]. And, in this case, the sialolith was not identified on ultrasonography.

In this case, CT was a useful diagnostic tool for visualization of the anatomic structures around the orbit due to their cross-sectional nature. Using CT, we were able to visualize an accurate distribution of the cystic lesions and their association with the zygomatic gland. We were also able to visualize the location of the sialolith in the right zygomatic gland caudal to the last molar tooth, at the location of the major duct of zygomatic gland [3, 22]. This information suggested that these were true ductal obstruction of sialolith. Although

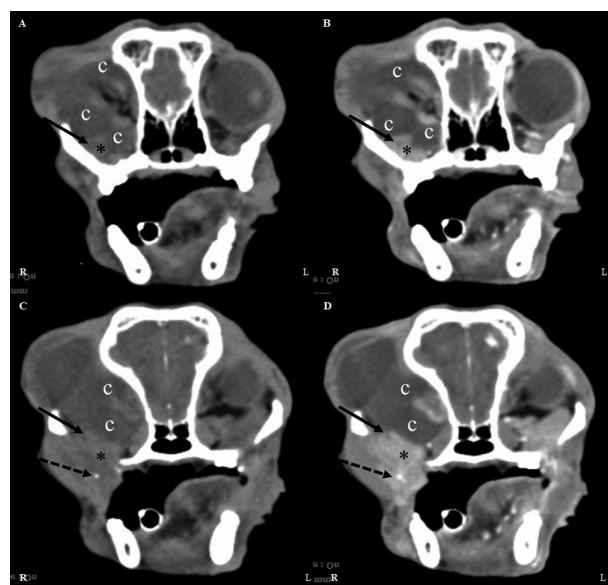


Fig. 3. Computed tomography (CT) of skull. Transverse CT images before (A, C) and after (B, D) contrast medium administration show cystic materials (c) around right globe and zygomatic gland (asterisks). The right zygomatic gland (arrow) has small cystic lesions (arrow) and a focal hyperdense object (dashed arrow).

sialography is recommended imaging modality for localizing of obstruction, to the authors' experience, catheterization to salivary duct was very difficult in small breed dogs [6, 20]. Magnetic resonance imaging (MRI) has been used to diagnose zygomatic gland disease [1, 2, 15]. Although MRI offers superior soft-tissue resolution and contrast in comparison with CT, the disadvantages of MRI include longer data acquisition time, increased thickness of tissue slices and less precise detection of soft tissue mineralization [10, 14, 15, 26, 27]. Therefore, MRI may be less sensitive than CT for identification of sialoliths, and CT was considered to be highly appropriate for this disorder in this case.

Although the etiology of sialolith formation is not clearly understood, several hypotheses have been proposed [17, 19, 21]. Sialoliths may both be a cause and a result of salivary retention [8, 18, 24, 25]. In addition, if obstruction occurs secondary to sialolith formation, chronic obstruction may result and contribute to a repetitive cycle of sialolith formation and inflammation [23, 24]. In this case, although the cause of the formation of the sialolith was unknown, the definitive diagnosis of mucocele associated with ductal obstruction by a sialolith was obtained by histopathologic examination.

Zygomatic sialocele is a condition rarely observed in veterinary medicine, but it should be considered as a possible diagnosis in any dog presenting with exophthalmos, protrusion of the third eyelid and palpation of a fluctuant soft tissue mass around the zygomatic bone. Ductal obstruction by a sialolith may result in zygomatic mucocele. CT was a useful diagnostic tool for accurate visualization of distribution of the cystic lesion, association with the zygomatic salivary gland and localization of the sialolith. This information was useful in choosing the option of surgical treatment.

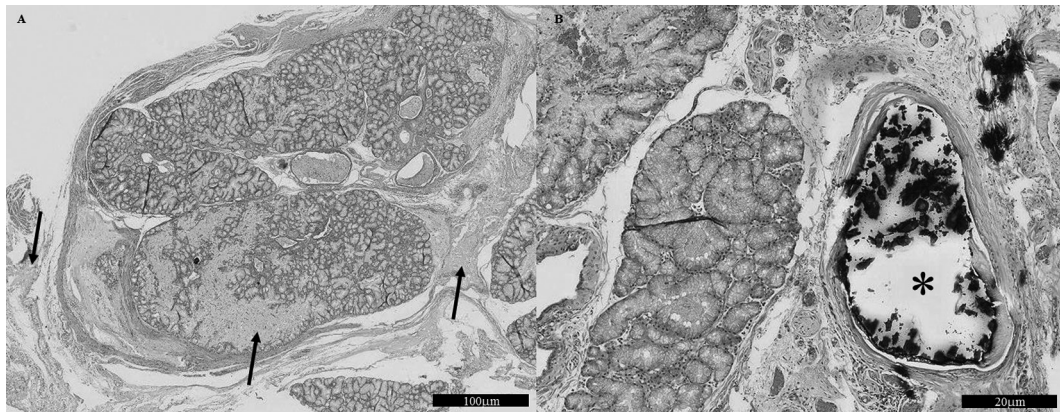


Fig. 4. Histopathological (HE stain) results of the right zygomatic gland. (A) Extrusion of the mucinous (arrows) from the salivary gland into the adjacent connective tissue. (B) A large mineralized structure (asterisk) occluding one of ductal cavity.

## REFERENCES

- Boland, L., Gomes, E., Payen, G., Bouvy, B. and Poncet, C. 2013. Zygomatic salivary gland disease in the dog: three cases diagnosed by MRI. *J. Am. Anim. Hosp. Assoc.* **49**: 333–337. [Medline] [CrossRef]
- Cannon, M. S., Paglia, D., Zwingenberger, A. L., Boroffka, S. A., Hollingsworth, S. R. and Wisner, E. R. 2011. Clinical and diagnostic imaging findings in dogs with zygomatic sialadenitis: 11 cases (1990–2009). *J. Am. Vet. Med. Assoc.* **239**: 1211–1218. [Medline] [CrossRef]
- Evans, H. E. and de Lahunta, A. 2013. The digestive apparatus and abdomen. pp. 385–642. In: Miller's Anatomy of the Dog, 4th ed. (Evans, H. E. and de Lahunta, A. eds.), WB Saunders, Philadelphia.
- Hunt, G. B., Youmans, K. R., Simpson, D. J. and Steel, R. J. 1997. Retropharyngeal pain and swelling in a dog. *Aust. Vet. J.* **75**: 476–491. [Medline] [CrossRef]
- Jeffreys, D. A., Stasiw, A. and Dennis, R. 1996. Parotid sialolithiasis in a dog. *J. Small Anim. Pract.* **37**: 296–297. [Medline] [CrossRef]
- Kneissl, S., Weidner, S. and Probst, A. 2011. CT sialography in the dog – a cadaver study. *Anat. Histol. Embryol.* **40**: 397–401. [Medline] [CrossRef]
- Kwon, Y. H., Lim, S. J., Chang, J. H., An, J. Y., Ahn, S. J., Jeong, S. M., Park, S. J., Cho, S. W., Choi, H. J. and Lee, Y. W. 2009. Sialoceles with sialolithiasis in a beagle dog. *J. Vet. Clin.* **26**: 371–375.
- Grases, F., Santiago, C., Simonet, B. M. and Costa-Bauzá, A. 2003. Sialolithiasis: mechanism of calculi formation and etiologic factors. *Clin. Chim. Acta* **334**: 131–136. [Medline] [CrossRef]
- Termote, S. 2003. Parotid salivary duct mucocele and sialolithiasis following parotid duct transposition. *J. Small Anim. Pract.* **44**: 21–23. [Medline] [CrossRef]
- Mafee, M. F., Putterman, A., Valvassori, G. E., Campos, M. and Capek, V. 1987. Orbital spaceoccupying lesions: role of computed tomography and magnetic resonance imaging. An analysis of 145 cases. *Radiol. Clin. North Am.* **25**: 529–559. [Medline]
- Mason, D. R., Lamb, C. R. and McLellan, G. J. 2001. Ultrasonographic findings in 50 dogs with retrobulbar disease. *J. Am. Anim. Hosp. Assoc.* **37**: 557–562. [Medline]
- Mattoon, J. S. and Nyland, T. G. 1995. Ocular ultrasonography. pp. 178–197. In: Veterinary Diagnostic Ultrasound. (Nyland, T.G. and Mattoon, J. S. eds.), W.B. Saunders, Philadelphia.
- Morgan, R. V. 1989. Ultrasonography of retrobulbar diseases of the dog and cat. *J. Am. Anim. Hosp. Assoc.* **25**: 393–399.
- Morgan, R. V., Daniel, G. B. and Donnel, R. L. 1994. Magnetic resonance imaging of the normal eye and orbit of the dog and cat. *Vet. Radiol. Ultrasound* **35**: 102–108. [CrossRef]
- Morgan, R. V., Ring, R. D., Ward, D. A. and Adams, W. H. 1996. Magnetic resonance imaging of ocular and orbital disease in 5 dogs and a cat. *Vet. Radiol. Ultrasound* **37**: 185–192. [CrossRef]
- Mulkey, O. C. and Knecht, C. D. 1971. Parotid salivary gland cyst and calculus in a dog. *J. Am. Vet. Med. Assoc.* **159**: 1774. [Medline]
- Prassinis, N. N., Tontis, D. K., Adamama-Moraitou, Kk., Galatos, A. D. and Siochu, A. 2005. Metaplastic ossification of a cervical sialoceles in a dog. *Aust. Vet. J.* **83**: 421–423. [Medline] [CrossRef]
- Rauch, S. and Gorlin, R. J. 1970. Diseases of the salivary glands. pp. 962–1003. In: Thoma's Oral Pathology. (Gorlin, R. J. and Goldman, H. M. eds.), CV Mosby, St. Louis.
- Ryan, T., Welsh, E., McGorum, I. and Yool, D. 2008. Sublingual salivary gland sialolithiasis in a dog. *J. Small Anim. Pract.* **49**: 254–256. [Medline] [CrossRef]
- Smith, M. M. 2005. Oral and salivary gland disorders. pp. 1295–1297. In: Textbook of Veterinary Internal Medicine Disease of the Dog and Cat. (Ettinger, S. J. and Feldman, E. C. eds.), Elsevier Saunders, St. Louis.
- Spangler, W. L. and Culbertson, M. R. 1991. Salivary gland disease in dogs and cats: 245 cases (1985–1988). *J. Am. Vet. Med. Assoc.* **198**: 465–469. [Medline]
- Tadjalli, M., Dehghani, S. N. and Basiri, M. 2004. Sialography in dog: normal appearance. *Veterinarski Arhiv.* **74**: 225–233.
- Teymoortash, A., Wollstein, A. C., Lippert, B. M., Peldszus, R. and Werner, J. A. 2002. Bacteria and the pathogenesis of human salivary calculus. *Acta Otolaryngol.* **122**: 210–214. [Medline] [CrossRef]
- Tivers, M. S. and Moore, A. H. 2007. Surgical treatment of a parotid duct sialolith in a bulldog. *Vet. Rec.* **161**: 271–272. [Medline] [CrossRef]
- Trumpatori, B. J., Geissler, K. and Mathews, K. G. 2007. Parotid duct sialolithiasis in a dog. *J. Am. Anim. Hosp. Assoc.* **43**: 45–51. [Medline]
- Weidner, S., Probst, A. and Kneissl, S. 2012. MR anatomy of salivary glands in the dog. *Anat. Histol. Embryol.* **41**: 149–153. [Medline] [CrossRef]
- Zimmerman, R. A. and Bilaniuk, L. T. 1988. Ocular MR imaging. *Radiology* **168**: 875–876. [Medline]