

Mast Cell Tumor in the Nasal Cavity of a Dog

Kiyokazu NAGANOBU, Hiroyuki OGAWA*, Kazuyuki UCHIDA, Ryoji YAMAGUCHI, Fumihito OHASHI¹⁾, Kihei KUBO¹⁾, Mika AOKI¹⁾, Mitsuru KUWAMURA¹⁾, Yasuko OGAWA²⁾ and Kimihiko MATSUYAMA²⁾

Department of Veterinary Science, Faculty of Agriculture, Miyazaki University, Miyazaki 889-2192, ¹⁾Department of Veterinary Medicine, Faculty of Agriculture, Osaka Prefecture University, Sakai, Osaka 599-8531, and ²⁾Matsuyama Animal Hospital, Miyazaki 889-0951, Japan

(Received 21 December 1999/Accepted 17 May 2000)

ABSTRACT. An 11-year-old male Shetland sheepdog displayed epistaxis and nasal discharge from the left nasal foramen. Cytological examination of a smear sample obtained by rhinotomy revealed neoplastic mast cells in the nasal cavity, a definitive diagnostic sign of mast cell tumor. The case was treated by surgery combined with radiotherapy and chemotherapy. Eighteen days after the last treatment, marked enlargement of the mandibular lymph nodes and facial edema developed, and the dog was euthanized at the owner's request. At necropsy, metastatic proliferation of mast cells was confirmed in the lymph nodes and liver, but no neoplastic mast cells were observed in the nasal cavity.

KEY WORDS: canine, mast cell tumor, nasal cavity.

J. Vet. Med. Sci. 62(9): 1009–1011, 2000

Cutaneous mast cell tumors are common and account for 7–21% of all canine skin tumors [5]. Extracutaneous mast cell tumors, although rare, have been described in the ocular system [6], oral cavity, nasopharynx, hepatopancreatic lymph nodes [14], larynx [3], intestine [15, 16], and spleen or liver [16]. On the other hand, the prevalence of canine sinonasal tumors has been reported to be 81 among 100,000 tumors [11]. Among them, adenocarcinoma, squamous cell carcinoma, and chondrosarcoma are relatively common [10–12]. There appear to be few reports describing canine mast cell tumors in the nasal cavity. Here we describe a case of canine mast cell tumor that originated in the nasal cavity.

A 15.4-kg, 11-year-old male Shetland sheepdog was presented to a referring veterinarian on the day after an initial episode of epistaxis and nasal discharge from the left nasal foramen. The dog was treated with antibiotics, and on the following day was referred to the Veterinary Hospital of Miyazaki University. Physical examination revealed enlargement of the left mandibular lymph node. Other superficial lymph nodes were normal in size on palpation. Mast cells, eosinophils and epithelial cells were found in a smear of the nasal discharge. Radiography of the head showed increased density of the soft tissue in the left nasal cavity (Fig. 1). Blood tests revealed no abnormalities, and mast cells were not found in the buffy coat smear. Rhinotomy was performed to obtain a specimen from the left nasal cavity. Various-sized mast cells with round or irregularly shaped nuclei were found in a smear sample from the nasal cavity (Fig. 2). Toluidine blue staining confirmed metachromatic granules in the cytoplasm of the neoplastic cells. Based on these findings, the present case was diagnosed as mast cell tumor of the nasal cavity. Surgical debulking of the nasal cavity was not carried out at this time.

Three days after the rhinotomy, the dog was sent to the Veterinary Hospital of Osaka Prefectural University and was treated with surgery, radiotherapy, and chemotherapy for 24 days. After surgical debulking of the nasal cavity and resection of the left mandibular lymph node, radiation therapy and chemotherapy were carried out. As much of the tumor as possible was removed. The diameter of the left mandibular lymph node was 4 cm. Histopathological examination showed that the nasal tissues consisted of a proliferation of

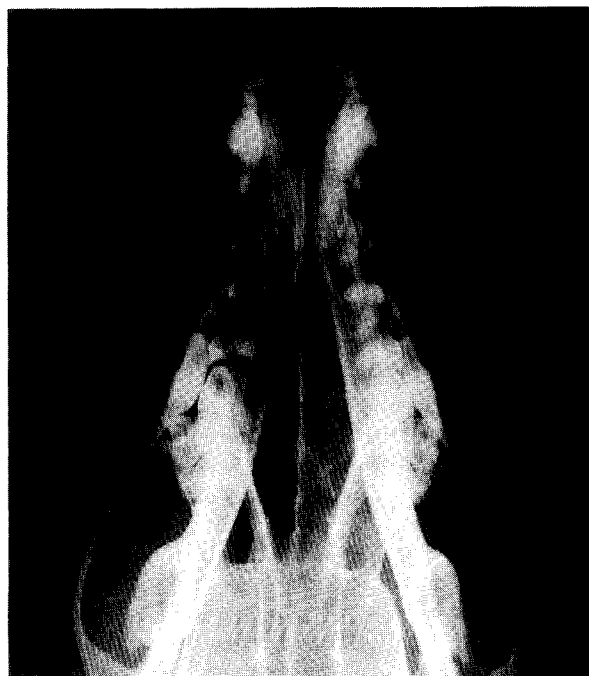


Fig. 1. Ventrodorsal radiography of the skull showing increased density of the soft tissue in the left nasal cavity.

*PRESENT ADDRESS: OGAWA, H., Laboratory of Veterinary Emergency Medicine, Graduate School of Agriculture and Life Sciences, The University of Tokyo, Tokyo 113-8657, Japan.

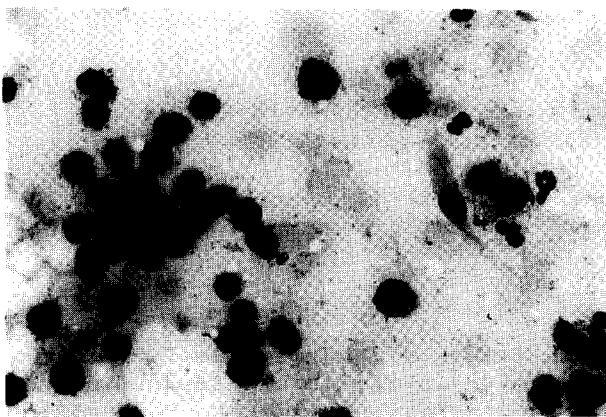


Fig. 2. Photomicrograph of a smear sample from the nasal cavity showing mast cells of various sizes with round or irregularly shaped nuclei (Giemsa stain, magnification $\times 150$).

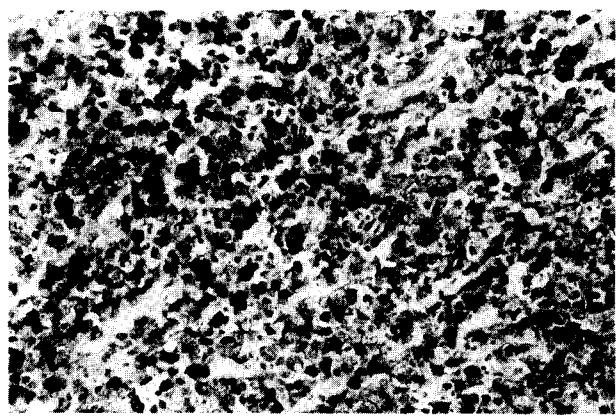


Fig. 3. Photomicrograph of nasal tissues showing proliferation of neoplastic mast cells (Toluidine blue stain, magnification $\times 100$).

neoplastic mast cells in which metachromatic granules were demonstrated by toluidine blue staining (Fig. 3). In addition, there were multiple foci of solidly proliferating tumor cells in the left mandibular lymph nodes (Fig. 4). These results indicated that the nasal mast cell tumor had already metastasized to the adjacent lymph nodes.

Each session of irradiation (5.4 Gy) was performed under anesthesia with medetomidine (0.05 mg/kg) and ketamine (10 mg/kg) after premedication with atropine (0.05 mg/kg).

The dog was treated in this way every two or three days, for a total of 7 times. Prednisolone, vincristine, and cyclophosphamide were used for chemotherapy. Prednisolone was given on days 1, 3, 6, and 9 (40 mg/m² sc) and days 11, 12, 16, and 18 (20 mg/m² sc). Vincristine was given on days 1 and 8 (0.75 mg/m² iv). Cyclophosphamide was given on days 1, 3, 6, and 9 (50 mg/m² iv), days 13 and 14 (42 mg/m² po), and days 11, 16, and 18 (83 mg/m² po). During this period, blood tests revealed leukopenia (3,000 / μ l) and elevated levels of alkaline phosphatase (3,008 U/l) and alanine aminotransferase (312 U/l). Doses and intervals of drug administration were varied in accordance with both the dog's condition and the results of blood tests. Famotidine, enrofloxacin, recombinant human granulocyte colony-stimulating factor and tranexamic acid were also given as required.

After treatment, the dog was sent back to Miyazaki University in good physical condition, and no further treatment was provided. However, 18 days later, the dog's general status deteriorated, and marked enlargement of both of the left and right mandibular lymph nodes and generalized facial edema were observed. The dog was therefore euthanized at the owner's request.

At necropsy, yellow pus-like material was found in the left nasal cavity. Histological examination revealed that this consisted of neutrophils and degenerated cells, but not neoplastic mast cells. The nasal mucous membrane showed edematous change and diffuse infiltration of lymphocytes, neutrophils, and macrophages, but neoplastic mast cells were not detected. However, marked proliferation of neoplastic mast cells was found in the mandibular and adjacent lymph

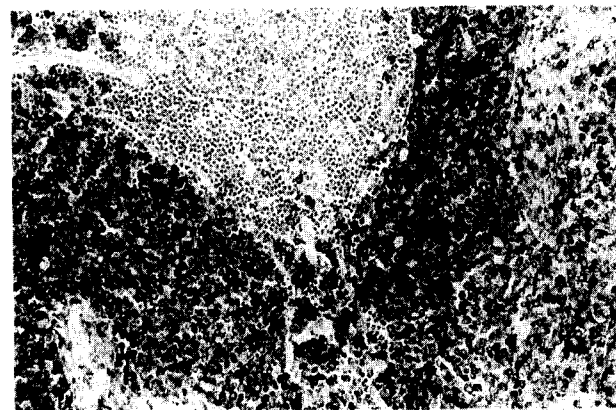


Fig. 4. Photomicrograph of a left mandibular lymph node showing proliferation of neoplastic mast cells (Toluidine blue stain, magnification $\times 50$).

nodes and liver. Two of the enlarged lymph nodes measured 6 \times 3 cm and 4 \times 2 cm, respectively. Their normal architecture had been replaced by diffusely proliferated neoplastic mast cells. The liver showed severe passive congestion, and neoplastic mast cells had infiltrated the sinusoids. No metastases were confirmed at other sites, and no ulceration of the gastrointestinal tract was observed.

The unilateral epistaxis and nasal discharge observed in the present case are signs often associated with intranasal tumors. Radiological examination may be helpful in determining the extent and location of the lesions. Definitive diagnosis of nasal tumors is made by cytological or histopathological examination. Nasal flushing, transnostril core-sampling, or rhinotomy is sometimes performed to obtain specimens. In the present case, the presence of mast cells and eosinophils in the nasal discharge and increased soft tissue density in the nasal cavity indicated a mast cell tumor in this location. However, such findings can also be associated with non-neoplastic inflammatory diseases [1]. The diagnosis of mast cell tumor was made by cytological exam-

ination of a smear sample obtained by rhinotomy.

Histological grade and clinical stage are known to influence the prognosis of canine cutaneous mast cell tumors. Well differentiated canine tumors have a better prognosis than poorly differentiated tumors [2, 13]. Multiple dermal tumors, regional lymph node involvement, and distant metastasis are also factors associated with poor prognosis [19]. In the present case, a lymph node involvement was evident at the time of diagnosis. Metastasis of the liver was not confirmed before the autopsy as no hepatomegaly had been found on physical examination and radiography.

Treatment of mast cell tumors involves surgery, radiation therapy, and chemotherapy. Surgical excision is indicated for solitary mast cell tumors when there is no evidence of lymph node involvement or metastasis. However, complete resection of nasal tumors is sometimes difficult because of invasion to surrounding tissues. Radiation therapy has been considered an effective treatment for some types of nasal tumors [17, 18] and mast cell tumors [7, 19]. In the present case, we carried out surgical debulking before radiation therapy. This procedure may decrease the degree of nasal cavity obstruction and nasal discharge, improving the patients' clinical status and allowing homogeneous irradiation of the nasal cavity [18]. In the dog we treated, radiation therapy after surgical debulking seemed to be effective for eradicating the neoplastic cells in the nasal cavity.

Many drugs, such as prednisone, vincristine, vinblastine, cyclophosphamide, and L-asparaginase, have been used for the treatment of canine mast cell tumors [4, 8, 9]. In general, however, chemotherapy does not seem to be very effective for the treatment of mast cell tumors [4]. Although glucocorticoid therapy is particularly recommended for canine mast cell tumors, reduction of the tumor size with oral prednisone was considered in 5 of 25 dogs with cutaneous mast cell tumors [9]. In addition, it was reported that chemotherapy including glucocorticoid had little or no effect on visceral mast cell tumors [16].

In the present case, management of metastasis to the lymph nodes and liver was difficult. However, our findings suggest that the therapeutic combination of surgery, radiotherapy and chemotherapy may be useful for the local control of canine mast cell tumors in the nasal cavity. Therefore, early detection of this tumor would play an important role in its management. Although nasal discharge or epistaxis can have a number of causes, mast cell tumor in the nasal cavity

should be included in the differential diagnosis of dogs with these symptoms.

REFERENCES

1. Andreasen, C. B., Rakich, P. M. and Latimer, K. S. 1989. pp. 47–53. *In: Diagnostic Cytology of the Dog and Cat* (Cowell, R. L. and Tyler, R. D. eds.), American Veterinary Publications, Goleta.
2. Bostock, D. E. 1973. *J. Small Anim. Pract.* 14: 27–40.
3. Crow, D. T., Goodwin, M. A. and Greene, C. E. 1986. *J. Am. Anim. Hosp. Assoc.* 22: 809–816.
4. Fox, L. E. 1998. pp. 477–486. *In: Cancer in Dogs and Cats: Medical and Surgical Management* (Morrison, W. B. ed.), Williams & Wilkins, Baltimore.
5. Henderson, R. A. and Brewer, W. G. Jr. 1993. pp. 2075–2088. *In: Textbook of Small Animal Surgery*, 2nd ed. (Slatter, D. ed.), W.B. Saunders, Philadelphia.
6. Jhonson, B. W., Brightman, A. H. and Whiteley, H. E. 1988. *J. Am. Anim. Hosp. Assoc.* 24: 439–442.
7. LaDue, T., Price, G. S., Dodge, R., Page, R. L. and Thrall, D. E. 1998. *Vet. Radiol. Ultra.* 39: 57–62.
8. McCaw, D. L., Miller, M. A., Bergman, P. J., Withrow, S. J., Moore, A. S., Knapp, D. W., Fowler, D. and Johnson, J. C. 1997. *J. Vet. Intern. Med.* 11: 375–378.
9. McCaw, D. L., Miller, M. A., Ogilvie, G. K., Withrow, S. J., Brewer, W. G. Jr., Klein, M. K., Bell, F. W. and Anderson, S. K. 1994. *J. Vet. Intern. Med.* 8: 406–408.
10. MacEwen, E. G., Withrow, S. J. and Patnaik, A. K. 1977. *J. Am. Vet. Med. Assoc.* 174: 45–48.
11. Madewell, B. R., Priester, W. A., Gillette, E. L. and Snyder, S. P. 1976. *Am. J. Vet. Res.* 37: 851–856.
12. Patnaik, A. K. 1989. *J. Am. Anim. Hosp. Assoc.* 25: 103–114.
13. Patnaik, A. K., Ehler, W. J. and MacEwen, E. G. 1984. *Vet. Pathol.* 21: 469–474.
14. Patnaik, A. K., MacEwen, E. G., Black, A. P. and Luckow, S. 1982. *Vet. Pathol.* 19: 608–615.
15. Patnaik, A. K., Twedt, D. C. and Marretta, S. M. 1980. *J. Small Anim. Pract.* 21: 207–212.
16. Takahashi, T., Kadosawa, T., Nagase, M., Matsunaga, S., Mochizuki, M., Nishimura, R. and Sasaki, N. 2000. *J. Am. Vet. Med. Assoc.* 216: 222–226.
17. Theon, A. P., Madwell, B. R., Harb, M. F. and Dungworth, D. L. 1993. *J. Am. Vet. Med. Assoc.* 202: 1469–1475.
18. Thrall, D. E. and Harvey, C. E. 1983. *J. Am. Vet. Med. Assoc.* 183: 663–666.
19. Turrel, J. M., Kitchell, B. E., Miller, L. M. and Theon, A. 1988. *J. Am. Vet. Med. Assoc.* 193: 936–940.