

Forum Minireview

Roles of Oral Bacteria in Cardiovascular Diseases — From Molecular Mechanisms to Clinical Cases:**Involvement of *Porphyromonas gingivalis* in the Development of Human Aortic Aneurysm**Koichiro Wada^{1,*} and Yoshinori Kamisaki¹¹Department of Pharmacology, Graduate School of Dentistry, Osaka University,
1-8 Yamadaoka, Suita, Osaka 565-0871, Japan

Received November 16, 2009; Accepted December 21, 2009

Abstract. Accumulating evidence suggests the involvement of *Porphyromonas gingivalis* (*P. gingivalis*), a periodontal pathogen, in cardiovascular diseases. Clinical specimens of aneurysmal tissue and dental plaque collected from patients infected with or without *P. gingivalis* were analyzed. The number of aneurysms in the distal aorta in the *P. gingivalis*-infected group was significantly higher than that in the non-infected group. Cellular accumulation of adipocytes in aneurysms was less frequently identified in the infected group. The expression of embryonic myosin heavy chain isoform, a phenotypic marker for proliferative smooth muscle cells, was higher in the *P. gingivalis*-infected group than the non-infected group. Clinical and histopathological features of aortic aneurysms associated with *P. gingivalis* infection are different from those present in non-infected patients. The major characteristic of *P. gingivalis* infection associated with aneurysms is smooth muscle cell proliferation in the distal aorta.

Keywords: *Porphyromonas gingivalis* (*P. gingivalis*), aortic aneurysm, smooth muscle cell, embryonic myosin heavy chain isoform, atherosclerosis, oral bacteria

1. Introduction

Chronic marginal periodontitis occurs worldwide and is among the most prevalent microbial diseases in humans (1). This inflammatory disorder is caused by the complex action of a small subset of periodontal pathogens that are harbored in dental plaque, a complex microbial biofilm. Periodontal inflammation often leads to superficial ulcers on the gingival sulcus, where blood capillaries are exposed to microbial biofilms (2). It is well known that periodontal pathogens are translocated and released from the sulcus into the bloodstream, and such transient bacteremia has been demonstrated in clinical trials to occur after preventive dental procedures and periodontal therapy, including tooth brushing (3), chewing (4), subgingival irrigation (5), periodontal treatment (6), and dental extractions (7), with frequencies ranging

from 17% – 100% in infected individuals.

Porphyromonas gingivalis (*P. gingivalis*) is a Gram-negative anaerobic bacterium considered to be a periodontal pathogen that causes severe periodontitis. Several epidemiologic studies have indicated the involvement of *P. gingivalis* in the development of systemic diseases such as cardiovascular disease, diabetes mellitus, preterm low birth weight, and rheumatoid arthritis (1, 8, 9). Among them, in particular, cardiovascular diseases are considered to be strongly related to the infection of periodontal pathological bacteria (10, 11). In addition, Editors' consensus about the "Periodontitis and Atherosclerotic Cardiovascular Disease" in the *American Journal of Cardiology* and *Journal of Periodontology* indicated the relationship between atherosclerotic cardiovascular disease and periodontitis (12, 13). In fact, it was reported that the periodontal pathological bacteria including *P. gingivalis* were detected in specimens of many cardiovascular diseases such as atherosclerosis (14, 15), arteriosclerotic aneurysms (15, 16), coronary heart disease (14, 17), heart valves of endocarditis (15), and

*Corresponding author. kwada@dent.osaka-u.ac.jp
Published online in J-STAGE on May 24, 2010 (in advance)
doi: 10.1254/jphs.09R22FM

Buerger’s disease (18).

In this review, we summarize the involvement of *P. gingivalis* in the development of human aortic aneurysm. For the purpose, we describe the clinical and histopathological features of aortic aneurysms in patients infected with periodontal pathogen, *P. gingivalis*.

2. Detection of *P. gingivalis* infection and classification of fimbriae genotypes

We investigated aortic aneurismal specimens and dental plaques collected from patients who underwent surgery for aortic aneurysms. Among them, 64.1% of the patients were infected with *P. gingivalis*.

P. gingivalis fimbriae, filamentous appendages on the bacterial surface, are classified into 6 genotypes based on the diversity of the *fimA* genes encoding each fimbria subunit. It was demonstrated that bacterial clones with types II, IV, and Ib *fimA* are invasive, whereas types I, III, and V are non-invasive (19). However, it is unknown whether these genotypes are related to the pathogenesis of atherosclerosis and aneurysms. It should be noted that the detection frequency of invasive clones (types II, IV, and Ib *fimA*) in *P. gingivalis*-positive specimens was significantly higher (88.0%) than that of non-invasive clones (types I, III, and V *fimA*).

3. Clinical differences of aortic aneurysms in patients infected with or without *P. gingivalis*

Classification into complications, such as hyperlipidemia, hypertension (HT), hyperurathemia, and diabetes mellitus (DM), were made according to the diagnostic criteria of the referring physicians. As for complications, HT was the most frequent complication in the patients analyzed in this study (Fig. 1). Notably, 48% of the patients in the infected group were hypertensive as com-

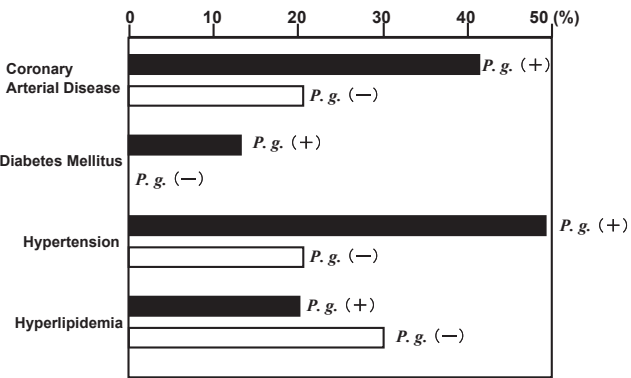


Fig. 1. Complications of aortic aneurysmal patients infected with or not infected with *P. gingivalis*.

pared to 21.4% in the non-infected group. Also, the percentage of patients that exhibited coronary artery disease (CAD) in the infected group (40.0%) was greater than that observed in non-infected group (21.4%). As for DM, 3 patients in the infected group exhibited this complication, whereas there were none in the non-infected group. The detection rates of HT, CAD, and DM in the infected group were shown to be higher than those in non-infected group.

The subjects were diagnosed as having a thoracic aortic aneurysm (TAA), thoracoabdominal aortic aneurysm (TAAA), or abdominal aortic aneurysm (AAA); then they were further classified into two categories based on the location of the involved aorta. Aneurysms formed between the ascending aorta and the aortic arch were defined as “aneurysms of the proximal aorta”, whereas those located between the descending aorta and abdominal aorta were defined as “aneurysms of the distal aorta”. Figure 2 shows the total number of patients in each group based on the results of bacterial detection in dental plaque and aneurysm tissues. A significantly greater percentage of AAAs were identified in the infected group (60.0%) as compared to the non-infected group (21.4%) (Fig. 2, $P < 0.05$). In contrast, TAAs were more frequently found in the non-infected group (78.6%) than the infected group (32.0%). When they were analyzed according to the location in the involved aorta, the infected group had aneurysms in the distal aorta significantly more frequently than the non-infected group (72.0% vs. 28.6%; $P < 0.05$). As for the size of the lesions, those in non-infected (57.3 ± 12.0 mm) group were slightly larger than those in the infected group (51.7 ± 9.8

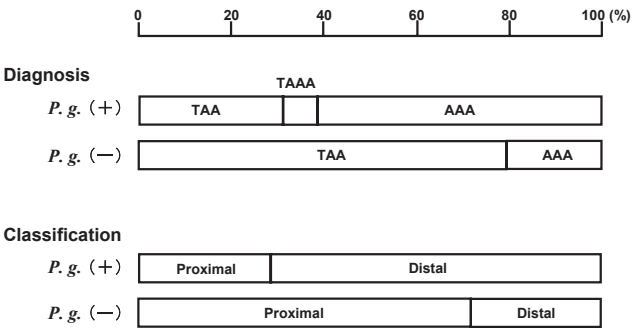


Fig. 2. Clinical diagnosis and classifications of aneurysmal patients infected with or not infected with *P. gingivalis*. The subjects were diagnosed as having a thoracic aortic aneurysm (TAA), thoracoabdominal aortic aneurysm (TAAA), or abdominal aortic aneurysm (AAA); then they were further classified into two categories based on the location of the involved aorta. Aneurysms formed between the ascending aorta and the aortic arch were defined as “aneurysms of the proximal aorta”, whereas those located between the descending aorta and abdominal aorta were defined as “aneurysms of the distal aorta”.

mm), although the difference was not significant.

4. Histopathological evaluations: increase in proliferative smooth muscle cells

We have recently reported that human aortic smooth muscle cells were drastically transformed by infection with *P. gingivalis* from a contractile to a proliferative phenotype, resulting in an increase in cell proliferation in vitro (20). The transformation of aortic smooth muscle cells from the contractile to the hyperproliferative phenotype was accompanied with upregulation of the embryonic isoform of myosin heavy chain (SMemb) expression (20). Figure 3 shows a typical microscopic photograph of SMemb expression in aneurysmal lesions isolated from a *P. gingivalis*-infected patient. The SMemb expression in infected patients was greater than those in non-infected patients. This result suggests that there is a direct relationship between *P. gingivalis* infection and proliferation of smooth muscle cells.

In contrast, accumulation of adipose cells was observed more frequently in aneurysmal lesions in non-infected patients than those in infected patients (Fig. 4B, $P < 0.05$). In addition, there is no significant difference of averaged total cholesterol levels between *P. gingivalis*-infected and non-infected patients (Fig. 4A), indicating the possibility of cholesterol-independent etiology of aneurysms.

5. Concluding remarks

Recent in vitro studies have demonstrated that *P. gingivalis* possesses properties that are consistent with an involvement in the pathogenesis of atherosclerosis. These

include the ability to cause low density lipoprotein oxidation, foam cell formation, and platelet aggregation (11). In addition, systemic challenge by *P. gingivalis* has been reported to accelerate atherogenic plaque formation in mice fed a high-cholesterol diet (21). These results strengthened the hypothesis that *P. gingivalis* infection may be a risk factor in the development of atherosclerosis. Atherosclerosis is also associated with AAA. However, only 9% – 16% of patients with atherosclerosis of the abdominal aorta have been reported to develop AAAs (22). This indicates that there must be risk factors other than elevated blood cholesterol.

In the present review, we show that aortic aneurysms associated with *P. gingivalis* infection are obviously different from those of non-infected patients. The aneurysms associated with *P. gingivalis* infection are correlated with less adipocellular accumulation than non-infected patients, supporting the notion of a cholesterol-independent etiology for *P. gingivalis*-related aneurysm formation. In fact, no positive correlation between total cholesterol level and adipocellular accumulation was observed (data not shown). We have previously observed that the expression of SMemb by *P. gingivalis* in cultured human aortic smooth muscle cells is associated with a change of these cells into a proliferative phenotype (20, 23). Given the increased SMemb expression in the absence of an adipocellular accumulation in *P. gingivalis*-infected aneurysm, we propose that a novel cholesterol-independent etiology exists in the formation of aortic aneurysmal lesions associated with *P. gingivalis* (Fig. 5). Recently, it has been reported that the average total

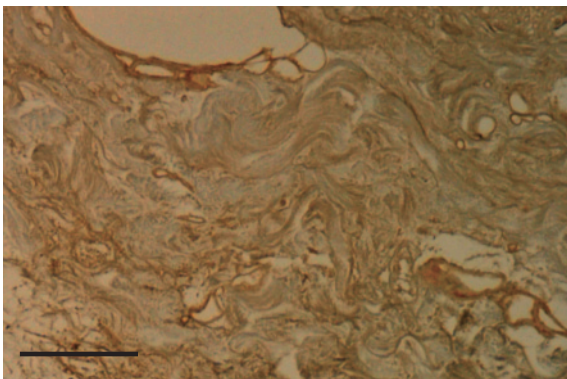


Fig. 3. Typical photograph of SMemb expression in aneurysm. Typical photograph of embryonic isoform of the myosin heavy chain (SMemb) expression in an aneurysm section isolated from a *P. gingivalis*-infected patient by immunochemical staining. Brown color represents the SMemb expression. Scale bar = 100 μ m.

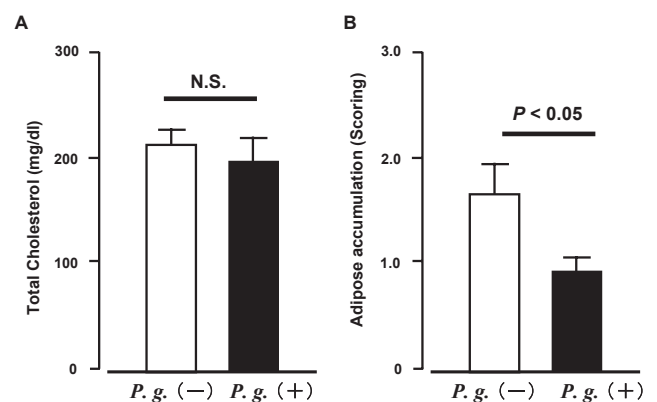


Fig. 4. Comparison of blood cholesterol level and adipose accumulation in aneurysmal patients infected with or not infected with *P. gingivalis*. A: Total blood cholesterol in aneurysmal patients infected with or not infected with *P. gingivalis*. Each column represents the mean \pm S.E.M. from 14 – 25 patients. B: Adipose accumulation in aneurysmal patients infected with or not infected with *P. gingivalis*. Averaged score of adipose accumulation is shown. Each column represents the mean \pm S.E.M. from 14 – 25 patients.

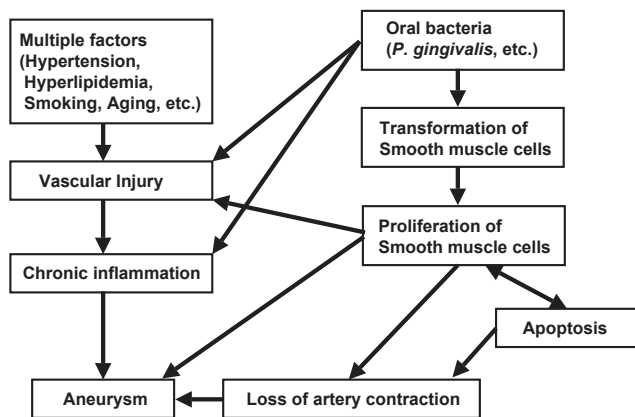


Fig. 5. Schematic illustration of possible mechanisms of aneurysm mediated by *P. gingivalis* infection.

cholesterol levels in Asians is lower than that in Westerns (24), indicating the potential new risk factor for cardiovascular diseases in Asia.

CAD, DM, and periodontitis are well-known common chronic diseases that have been shown to be closely related to each other (8). Most of the patients with CAD (10/13) were infected with *P. gingivalis*. As for DM, only 3 patients were identified as having this complication in this study, all of whom were in the *P. gingivalis*-infected group. Interestingly, there was a greater percentage of patients with HT in the *P. gingivalis*-infected group than in the non-infected group. In addition, *P. gingivalis*-infected specimens showed a significantly higher percentage of the proliferative type of smooth muscle cells, a causative factor in hypertension, compared to the specimens from non-infected patients. Thus, it is possible to speculate that hypertension is an additional, not previously appreciated, complication of infection with *P. gingivalis* (Fig. 5).

In our present observations, approximately 88% of the *P. gingivalis*-infected specimens contained invasive clones (types II, IV, and Ib). Since transient bacteremia can be induced by periodontal bacteria, it is possible to speculate that the clones with high virulence in periodontal disease are also highly virulent in cardiovascular diseases. Our observations and those reported in the literature clearly show that *P. gingivalis* infection is related to aortic aneurysm formation. Since *P. gingivalis* is a major pathogen of periodontitis and is detected with high frequency in adults with periodontitis, routine dental checkups and oral hygiene procedures should be regarded as important for the detection of subjects at high risk for developing aortic aneurysms in addition to other systemic diseases.

In conclusion, our review described the clinical and histopathological features of aortic aneurysms associated

with *P. gingivalis* infection. The latter were shown to be different from those detected in non-infected subjects. The major characteristic of aortic tissue associated with *P. gingivalis* infection was smooth muscle cell proliferation. Moreover, *P. gingivalis* infection was especially associated with aneurysms of the distal aorta. The present review supports a scenario in which *P. gingivalis* induces the smooth muscle cell-dependent hyperplasia.

Acknowledgments

We thank Drs. Kazuhiko Nakano (Osaka University) and Hideo Yoshioka and Kazuhiro Taniguchi (Osaka Rosai Hospital) for collection of samples and evaluation of analyzed data.

References

- 1 Tonetti MS, D'Aiuto F, Nibali L, Donald A, Storry C, Parkar M, et al. Treatment of periodontitis and endothelial function. *New Engl J Med*. 2007;356:911–920.
- 2 D'Aiuto F, Parkar M, Andreou G, Brett PM, Ready D, Tonetti MS. Periodontitis and atherogenesis: causal association or simple coincidence? *J Clin Periodontol*. 2004;31:402–411.
- 3 Sconyer JR, Crawford JJ, Moriarty JD. Relationship of bacteremia to tooth brushing in patients with periodontitis. *J Am Dent Assoc*. 1973;87:616–622.
- 4 Everett ED, Hirschmann JV. Transient bacteremia and endocarditis prophylaxis. A Review. *Medicine*. 1977;56:61–77.
- 5 Waki MY, Jolkovsky DL, Otomo-Corgel J, Lofthus JE, Nachnani S, Newman MG, et al. Effects of subgingival irrigation on bacteremia following scaling and root planing. *J Periodontol*. 1990; 61:405–411.
- 6 Kinane DF, Riggio MP, Walker KF, MacKenzie D, Shearer B. Bacteremia following periodontal procedures. *J Clin Periodontol*. 2005;32:708–713.
- 7 Vergis EN, Demas PN, Vaccarello SJ, Yu VL. Topical antibiotic prophylaxis for bacteremia after dental extractions. *Oral Surg Oral Med Oral Pathol Oral Radiol Endod*. 2001;91:162–165.
- 8 Southerland JH, Taylor GW, Moss K, Beck JD, Offenbacher S. Commonality in chronic inflammatory diseases: periodontitis, diabetes, and coronary artery disease. *Periodontol*. 2006; 40:130–143.
- 9 Moreillon P, Que YA. Infective endocarditis. *Lancet*. 2004;363: 139–149.
- 10 Offenbacher S, Madianos PN, Champagne CM, Southerland JH, Paquette DW, Williams RC, et al. Periodontitis-atherosclerosis syndrome: an expanded model of pathogenesis. *J Periodontol Res*. 1999;34:346–352.
- 11 Kuramitsu HK, Qi M, Kang IC, Chen W. Role for periodontal bacteria in cardiovascular diseases. *Ann Periodontol*. 2001;6: 41–47.
- 12 Friedewald VE, Kornman KS, Beck JD, Genco R, Goldfine A, Libby P, et al. The American Journal of Cardiology and Journal of Periodontology Editors' consensus: Periodontitis and atherosclerotic cardiovascular disease. *Am J Cardiol*. 2009;104:59–68.
- 13 Friedewald VE, Kornman KS, Beck JD, Genco R, Goldfine A, Libby P, et al. The American Journal of Cardiology and Journal of Periodontology Editors' consensus: Periodontitis and athero-

- sclerotic cardiovascular disease. *J Periodontol.* 2009;80:1021–1032.
- 14 Zaremba M, Gorska R, Suwalski P, Kowalski J. Evaluation of the incidence of periodontitis-associated bacteria in the atherosclerotic plaque of coronary blood vessels. *J Periodontol.* 2007;78:322–327.
- 15 Nakano K, Inaba H, Nomura R, Nemoto H, Takeuchi H, Yoshioka H, et al. Distribution of *Porphyromonas gingivalis* fimA genotypes in cardiovascular specimens from Japanese patients. *Oral Microbiol Immunol.* 2008;23:170–172.
- 16 Kurihara N, Inoue Y, Iwai T, Umeda M, Huang Y, Ishikawa I. Detection and localization of periodontopathic bacteria in abdominal aortic aneurysms. *Eur J Vasc Endovasc Surg.* 2004;28:553–558.
- 17 Pussinen PJ, Jousilahti P, Alfthan G, Palosuo T, Asikainen S, Salomaa V. Antibodies to periodontal pathogens are associated with coronary heart disease. *Arterioscler Thromb Vasc Biol.* 2003;23:1250–1254.
- 18 Iwai T, Inoue Y, Umeda M, Huang Y, Kurihara N, Koike M, et al. Oral bacteria in the occluded arteries of patients with Buerger disease. *J Vasc Surg.* 2005;42:107–115.
- 19 Nakagawa I, Amano A, Ohara-Nemoto Y, Endoh N, Morisaki I, Kimura S, et al. Identification of a new variant of *fimA* gene of *Porphyromonas gingivalis* and its distribution in adults and disabled populations with periodontitis. *J Periodontol Res.* 2002;37:425–432.
- 20 Inaba H, Hokamura K, Nakano K, Nomura R, Katayama K, Nakajima A, et al. Upregulation of S100 calcium-binding protein A9 is required for induction of smooth muscle cell proliferation by a periodontal pathogen. *FEBS Lett.* 2009;583:128–134.
- 21 Li L, Messas E, Batista EL Jr, Levine RA, Amar S. *Porphyromonas gingivalis* infection accelerates the progression of atherosclerosis in a heterozygous apolipoprotein E-deficient murine model. *Circulation.* 2002;105:861–867.
- 22 Jaffer FA, O'Donnell CJ, Larson MG, Chan SK, Kissinger KV, Kupka MJ, et al. Age and sex distribution of subclinical aortic atherosclerosis: a magnetic resonance imaging examination of the Framingham Heart Study. *Arterioscler Thromb Vasc Biol.* 2002;22:849–854.
- 23 Hokamura K, Inaba H, Nakano K, Nomura R, Yoshioka H, Taniguchi K, et al. Molecular analysis of aortic intimal hyperplasia caused by *Porphyromonas gingivalis* infection in mice with endothelial damage. *J Periodontol Res.* 2010;45:337–344.
- 24 Ueshima H, Sekikawa A, Miura K, Turin TC, Takashima N, Kita Y, et al. Cardiovascular disease and risk factors in Asia. *Circulation.* 2008;118:2702–2709.