

Radiographical Evaluation of Bone Maturation in Japanese Black Beef Cattle

Akihiro OISHI, Satoko HAMADA, Hiroshi SAKAMOTO, Shigeru KAMIYA¹⁾, Koichi YANAGIDA¹⁾, Chikara KUBOTA²⁾, Youichiro WATANABE²⁾, and Ryousuke SHIMIZU

Department of Veterinary Surgery, Faculty of Agriculture, Kagoshima University, 1-21-24 Korimoto, Kagoshima 890, ¹⁾Iriki Farm, Faculty of Agriculture, Kagoshima University, Uranomyoji Oya 4018-3, Iriki-cho, Satsuma-gun, Kagoshima 895-14, and ²⁾Division of Beef Cattle Management, Kagoshima Prefectural Livestock Experiment Station, 2440 Uenodan, Kokubu, Kagoshima 899-44, Japan

(Received 12 October 1995/Accepted 31 January 1996)

ABSTRACT. Epiphyseal ossification in the radius, ulna, metacarpus, proximal phalanx and tuber calcaneus was examined radiographically in Japanese Black beef cattle. The grade of standard ossification was assessed monthly for each epiphysis. Bone maturations could be divided into 8 grades for the distal radius and distal ulna, 7 grades for the distal metacarpus, 5 grades for the proximal phalanx, and 8 grades for the tuber calcaneus, respectively. The closure of the epiphyseal line completed at the earliest (12–14 months of age) on the proximal phalanx, and at the latest (35–37 months of age) on the distal ulna. Changes in gradings were steep at 0 to 5 months of age but became almost constant after 10 months of age in all the epiphyses. There were no significant differences in bone maturation between the cattle with different sex and breeding conditions. — **KEY WORDS:** bone maturation, cattle (Japanese Black), epiphyseal line (closure of), ossification, radiography.

J. Vet. Med. Sci. 58(6): 529–535, 1996

Normal morphological development of bones and joints is extremely important to diagnose the skeletal diseases in growing animals. In human beings [4, 9], dogs [1, 2, 5–7, 12], cats [13, 14] and horses [3, 8, 15, 16], normal epiphyseal developments of various bones has been standardized. However, there have been no reports on precise epiphyseal development and ossification in calves.

In this study, epiphyseal maturation of distal radius, distal ulna, distal metacarpus, proximal phalanx and tuber calcaneus in Japanese Black beef cattle was radiographically investigated.

MATERIALS AND METHODS

Animals: Totally one thousand and six hundred forty-three healthy Japanese Black cattle (0 to 37 months of age), reared in Iriki Farm of Kagoshima University and Kagoshima Prefectural Livestock Experiment Station, were used. Animals were divided into 6 types according to the sex and breeding conditions (exercise) as shown in Table 1. Radiographs were obtained from 10 cattle with the different type in each month of age.

Radiographical examination: Radiography was performed on the distal end of the radius and ulna, distal end of the metacarpus and proximal end of the proximal phalanx by left lateral and antero-posterior projection. Radiography of the tuber calcaneus was taken left laterally. The radiography was conducted outdoors using a portable X-ray machine (TANKA model TP-20; 70 kV, 10 mA) under the conditions with the focus film distance at 100 cm and the exposure time from 0.1 to 0.5 seconds.

Estimation of ossification grade: The grade of bone development was divided into 11 grades (grade 0–10) according to the method described by Owada and Sutow [9], as shown in Table 2. Changes in epiphyseal gradings

obtained from the mean grade value in each month of age were used for estimating epiphyseal development and ossification. Statistical analysis in the comparison of means between cattle types was carried out by Student's *t*-test and *P* value less than 0.05 was defined as significant.

RESULTS

Changes in epiphyseal gradings: Changes in gradings at all epiphyseal sites are shown in Fig. 1. Epiphyseal gradings increased steeply at 0 to 5 months of age but revealed little changes after 10 months of age in all the epiphyses. Bone development was basically the same for all cattle type and breeding conditions, indicating no affections by sex or exercise.

Epiphyseal maturation of the distal radius: The epiphyseal growth of the distal radius consisted of 8 grades as shown in Fig. 2. Epiphyseal status in newborn calves was classified into grade 3 or 4. The wavy shape of the epiphyseal line was very small (like the teeth of a saw) in grade 4, slightly small in grade 5–6, large in grade 7–8 and flat in grade 9–10. Fusion of the epiphyseal line (grade 8) completed at 10 months of age. Closure of the epiphyseal line (grade 10) completed at 28–30 months of age.

Epiphyseal maturation of the distal ulna: The epiphyseal growth of the distal ulna consisted of 8 grades as shown in Fig. 3. Epiphyseal status in newborn calves was classified into grade 2. The wavy shape of the epiphyseal line was not demonstrated in all the grades. The epiphyseal line fused at 30 months of age and closed at 35–37 months of age. In this site, the ossification stage of grade 6 (with capping) was not observed.

Epiphyseal maturation of the distal metacarpus: The epiphyseal growth of the distal metacarpus consisted of 7 grades as shown in Fig. 4. Epiphyseal status in newborn

Table 1. Radiographical follow-up of epiphyseal changes in Japanese Black beef cattle

Cattle type	Breeding condition	Periods of follow-up (months of age ^{a)})	
		Starting	Ending
Fostering male calves ^{b)}	Shedding and pasturage	0	13
Fostering female calves	Shedding and pasturage	0	13
Growing beef cattle (steers)	Shedding	11	31
Growing beef cattle (heifers)	Shedding	11	33
Heifers for reproduction ^{c)}	Pasturage	10	37
Bulls for reproduction	Shedding	5	18

a) Ten cattle were selected randomly at each month of age during the course of this study.

b) All male calves were castrated at 4–6 months of age.

c) All heifers were pregnant from 14–17 to 24–27 months of age and normally parturient.

calves was classified into grade 4 or 5. The wavy shape of the epiphyseal line was comparatively large in all the grades, showing with low wave in grade 5–6 and 9–10 and high wave in grade 7–8. Fusion and closure of the epiphyseal line was observed at 4 and 19–20 months of age, respectively.

Epiphyseal maturation of the proximal phalanx: The epiphyseal growth of the proximal phalanx consisted of 5 grades as shown in Fig. 5. Epiphyseal status in newborn calves was classified into grade 6. The wavy shape of the epiphyseal line was large in grade 6–9 but became wide and low in grade 10. The epiphyseal line fused at 3 months of age and the closure completed at 12–14 months of age.

Epiphyseal maturation of the tuber calcaneus: The epiphyseal growth of the tuber calcaneus consisted of 8 grades as shown in Fig. 6. Epiphyseal status in newborn calves was classified into grade 3 or 4. The wavy shape of the epiphyseal line was very small in grade 5–6 and large in grade 7–10. Fusion and closure of the epiphyseal line was observed at 6 and 27 months of age, respectively.

DISCUSSION

In veterinary medicine, normal skeletal development has been studied radiographically in dogs [1, 2, 5–7, 12], cats [13, 14] and horses [3, 8, 15, 16], and the results have

Table 2. Eleven grades of morphological changes of the epiphysis in human*

Grade	Radiographical findings of epiphyseal portion
0	No appearance of an epiphysis.
1	Appearance of a small round epiphysis.
2	Differentiation and enlargement of an epiphysis compared with grade 1, but no characteristic shape of the epiphysis.
3	Beginning characteristic differentiation of an epiphysis.
4	Appearance of epiphyseal characteristic outline, but smaller width of an epiphysis than of a metaphysis.
5	Equalization of both width of an epiphysis and metaphysis.
6	Overlapping of epiphyseal edge onto metaphyseal edge, so-called 'capping', and cleared characteristic shape of an epiphysis, but leaving gap between an epiphysis and metaphysis.
7	Partially fusion of an epiphysis with a metaphysis.
8	Development of epiphyseal fusion (over half).
9	Completion of epiphyseal fusion, but leaving a line of epiphyseal cartilage.
10	Slightly leaving of minute line or disappearance, and completion of epiphyseal closure.

* Classification method by Owada and Sutow [9].

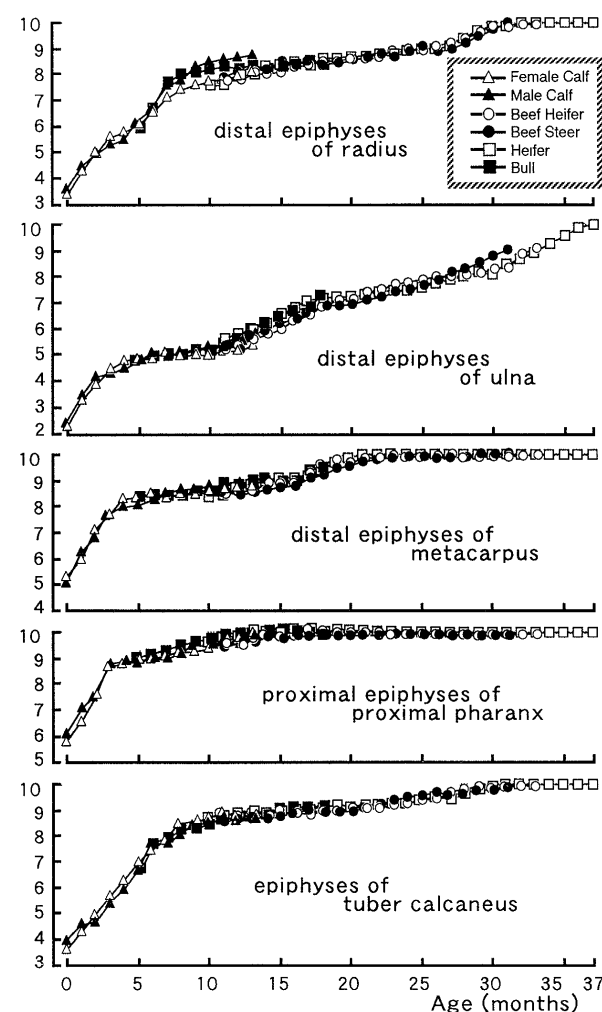


Fig. 1. Changes in mean gradings in the radius, ulna, metacarpus, proximal phalanx and tuber calcaneus.

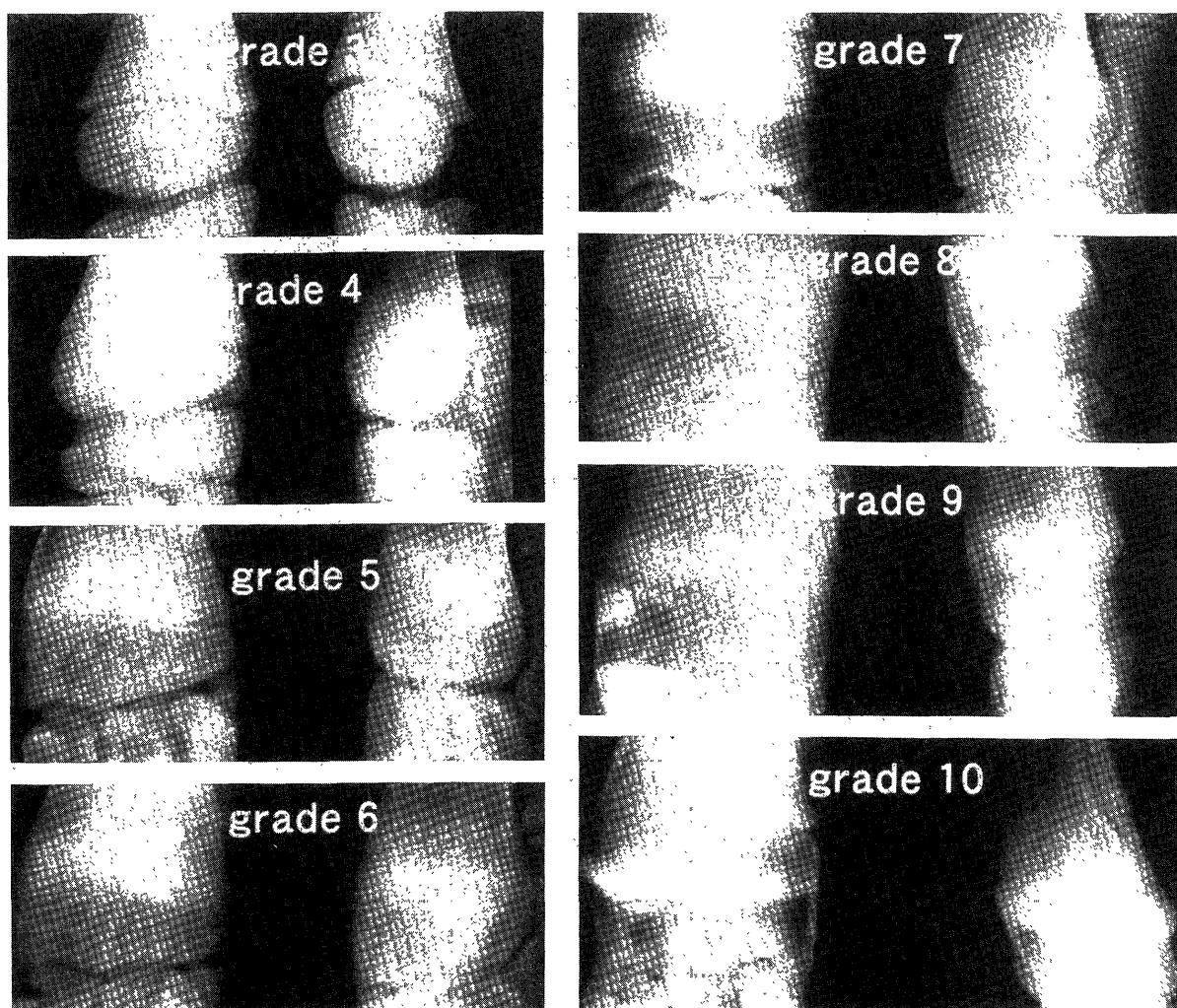


Fig. 2. Radiographs of standard ossification in the distal radius immediately after birth, the ossification stage was grade 3 or 4. Grades 5, 6, 7, 8, 9 and 10 were found at 2–3, 4–5, 6–7, 8–15, 16–27 and 28–30 months of age, respectively.

served as standards for clinical diagnosis. We have reported the radiographic epiphyseal growth for 10 months after birth in Japanese Black beef calves [10], however longer follow-up period and clarification of differences in cattle type and breeding conditions were thought to be required to standardize the skeletal growth.

From this study, ossification center of all the examined sites in newborn calves were similar to that in horses [15, 16]. Standard ossification progressed through 5 grades in the proximal phalanx, 7 grades in the distal metacarpus and 8 grades in the distal radius, distal ulna and tuber calcaneus. Morphological findings were similar to those in equine radius, metacarpus, proximal phalanx and tuber calcaneus [15, 16], but changes in ossification grades (so-called growth speed) differed from those in horses. In the distal radius, growth rate in cattle was slightly faster than in horses up to 10 months of age, but it slowed thereafter and closure of the epiphyseal line completed 5 to 6 months later than in horses. In the distal ulna and distal metacarpus, growth rates were clearly less than in horses but it was greater in the proximal

phalanx. In cattle, fusion of the epiphyseal line in the tuber calcaneus began 1 to 2 months later, advanced faster from 5 to 9 months of age, and final closure completed 3 to 5 months later than in horses.

The growth rate at each epiphyseal site in horses was faster in the more distal site [15]. However, in cattle, such a tendency was not demonstrated in the distal radius and distal metacarpus, showing similar ossification grade, from 10 to 15 months of age.

Maturation of the distal ulnar epiphysis was found quite different from other animal species. In human beings [9] and dogs [7], 'capping' showing the pre-stage of epiphyseal fusion was found to be the same as at other sites. In the horse, the ossification center of the distal ulna became apparent only in the early stage of epiphyseal growth and deteriorated in the final stage [15]. However in cattle, grade 6 ('capping') was not seen in the distal ulnar epiphysis, and closure of the epiphyseal line in this site completed 6 to 7 months later than in the distal radius. Such type of epiphyseal growth is not clearly seen in other ruminants. In




Fig. 3. Radiographs of standard ossification in the distal ulna. Immediately after birth, the ossification stage was grade 2. Grades 3, 4, 5, 7, 8, 9 and 10 were found at 0–1, 2–3, 4–12, 13–23, 24–29, 30–34 and 35–37 months of age, respectively.

sheep, fusion of the epiphyseal line in the distal ulna completed at 26 months of age, this being 2 to 3 months later than in the distal radius [11].

In this study, there was no significant difference in bone maturation between the type of cattle. This suggests that the effect of sex, nutrition and management on bone maturation is quite minimal.

In conclusion, radiographic maturation of the major epiphyseal lines were clarified. These results will be the standard for the diagnosis of the skeletal diseases in growing calves.

REFERENCES

1. Acheson, R. M. 1954. A method of assessing skeletal maturity from radiographs. *J. Anat.* 88: 498–508.
2. Andersen, A. and Floyd, M. 1963. Growth and development of the femur in the beagle. *Am. J. Vet. Res.* 24: 348–351.
3. Brown, M. P. and MacCallum, F. J. 1975. A system of grading ossification in limbs of foals to assist in radiologic interpretation. *Am. J. Vet. Res.* 36: 655–661.
4. Garn, S. M., Sandusky, S. T., Miller, R. L., and Nagy, J. M. 1972. Developmental implication of dichotomous ossification sequences in the wrist region. *Am. J. Phys. Anthropol.* 37: 111–116.

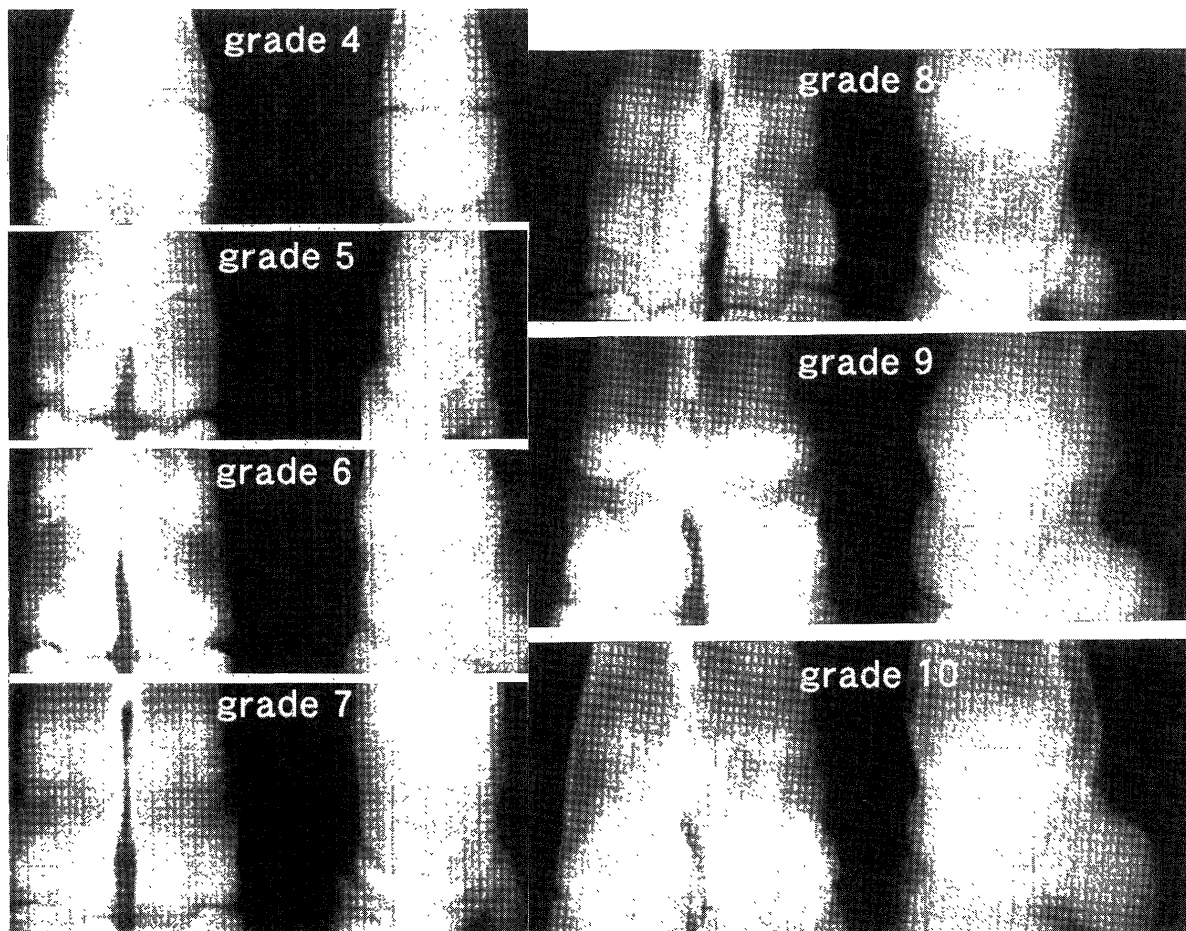


Fig. 4. Radiographs of standard ossification in the distal metacarpus. Immediately after birth, the ossification stage was grade 4 or 5. Grades 6, 7, 8, 9 and 10 were found at 1, 2–3, 4–10, 11–18 and 19–23 months of age, respectively.

5. Hare, W. C. D. 1961. Radiographic anatomy of the cervical region of the canine vertebral column. Part I. Fully developed vertebrae. *J. Am. Vet. Med. Assoc.* 139: 209–216.
6. Hare, W. C. D. 1961. Radiographic anatomy of the cervical region of the canine vertebral column. Part II. Developing vertebrae. *J. Am. Vet. Med. Assoc.* 139: 217–220.
7. Ichiki, H. 1976. Radiographic observation of normal skeletal growth. In: *Studies on Beagle for Research in Japan* (Hukui, M., Tomoda, I., and Ueda, Y. eds.), Soft Science, Tokyo (in Japanese).
8. MacCallum, F. J., Brown, M. P., and Goyal, H. O. 1978. An assessment of ossification and radiological interpretation in limbs of growing horses. *Br. Vet. J.* 134: 366–374.
9. Owada, K. and Sutow, W. W. 1953. The standard skeletal maturation (the standard skeletal age) from 6 to 19 years old in Japanese healthy children. *Clinical Pediatrics* 6: 738–746 (in Japanese).
10. Shimizu, R., Oishi, A., Hamada, S., and Sakamoto, H. 1995. Epiphyseal growth for 10 months after birth in Japanese Black beef cattle. *J. Jpn. Vet. Med. Assoc.* 48: 28–32 (in Japanese).
11. Smith, R. N. 1956. Fusion of the epiphyses of the limb bones of the sheep. *Vet. Rec.* 68: 257–259.
12. Smith, R. N. 1964. The pelvis of the young dog. *Vet. Rec.* 76: 975–979.
13. Smith, R. N. 1968. Appearance of ossification centers in the kitten. *J. Small Anim. Pract.* 9: 497–511.
14. Smith, R. N. 1969. Fusion of ossification centers in the cat. *J. Small Anim. Pract.* 10: 523–530.
15. Yoshida, K., Ueda, Y., and Masumitsu, H. 1982. Radiographical studies on ossification in the Thoroughbred 2. Closure process in the distal epiphyseal lines of the radius and the 3rd metacarpal bone and the proximal epiphyseal line of the proximal phalanx, and an assessment system of bone maturity. *Bull. Equine Res. Inst.* 19: 18–29 (in Japanese).
16. Yoshida, K., Ueda, Y., Nagasawa, Y., Masumitsu, H., and Fujii, Y. 1981. Radiographical studies on ossification in the Thoroughbred 1. Assessment of ossification changes in olecranon and calcaneus. *Bull. Equine Res. Inst.* 18: 8–18 (in Japanese).

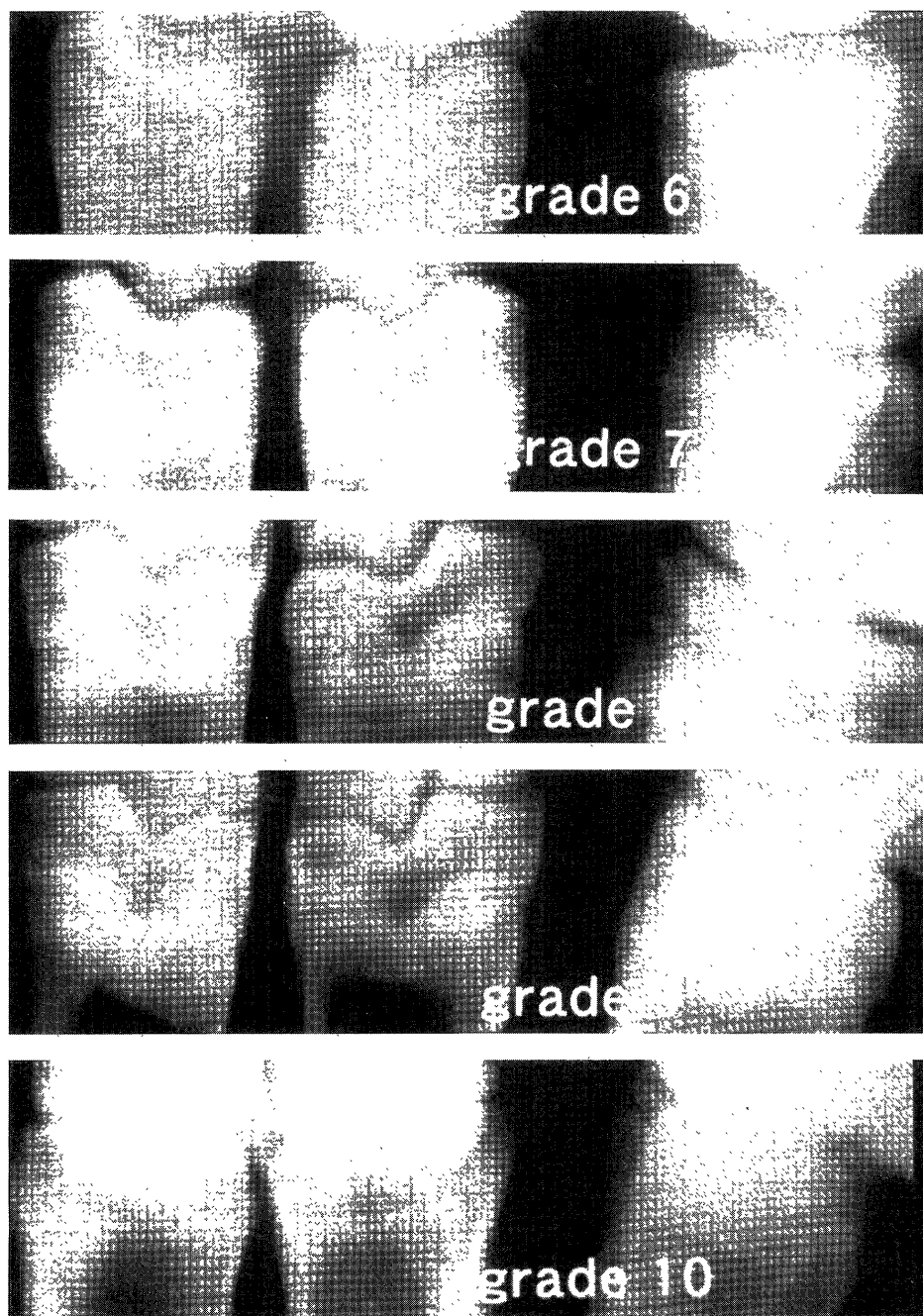


Fig. 5. Radiographs of standard ossification in the proximal pharynx. Immediately after birth, the ossification stage was grade 6. Grades 7, 8, 9 and 10 were found at 1–2, 3–4, 5–10 and 11–13 months of age, respectively.

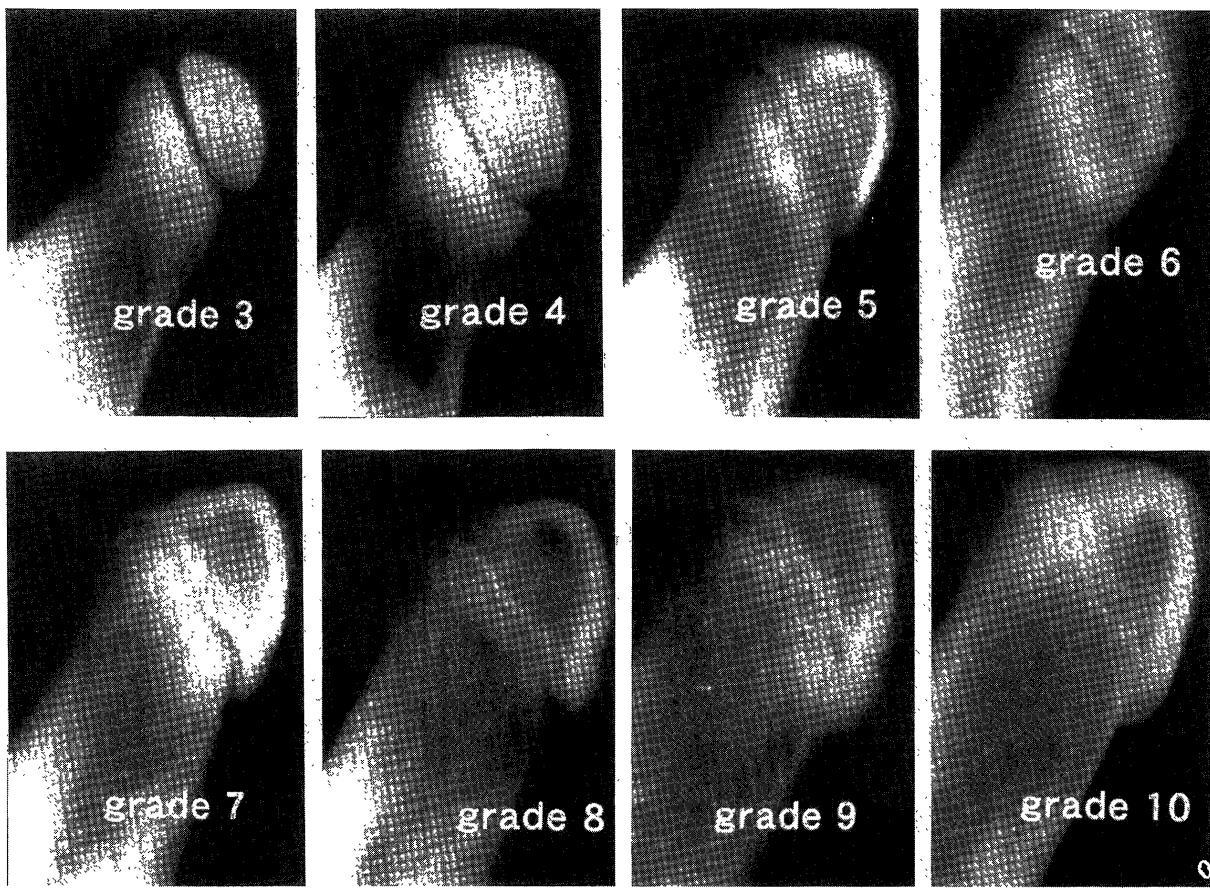


Fig. 6. Radiographs of standard ossification in the tuber calcaneus. Immediately after birth, the ossification stage was grade 3 or 4. Grades 5, 6, 7, 8, 9 and 10 were found at 1–2, 3–4, 5–6, 7–8, 9–25 and 26–29 months of age, respectively.