

Suppurative granulomatous sinorhinitis associated with *Nocardia* spp. infection in a cat

Ataru NAKANISHI^{1)*}, Tadahisa MASHITA^{1,2)}, Kyoko AKIYAMA¹⁾, Wakana NAKANISHI¹⁾, Takashi MORI^{3,4)}, Masaki YANO⁴⁾, Tetsuo ASAI²⁾, Rui KANO⁵⁾, Syunsuke SHIMAMURA²⁾ and Jun YASUDA²⁾

¹⁾Maizuru Animal Medical Center, 625–0037 Maizuru, Japan

²⁾The United Graduate School of Veterinary Science, Gifu University, 501–1193 Gifu, Japan

³⁾Laboratory of Veterinary Clinical Oncology, Department of Veterinary Medicine, Gifu University, 501–1193 Gifu, Japan

⁴⁾Animal Medical Center, Gifu University, 501–1193 Gifu, Japan

⁵⁾Department of Pathobiology, School of Veterinary Medicine, Nihon University, 1866 Kameino, 252–8510 Fujisawa, Japan

(Received 20 June 2014/Accepted 29 December 2014/Published online in J-STAGE 16 January 2015)

ABSTRACT. A 9-year-old spayed female cat was examined for cheek skin drainage. The skin lesion did not respond to medical therapy; thereafter, facial deformity developed. A computed tomography revealed an intranasal mass and maxillary osteolysis. The mass was histopathologically diagnosed as suppurative granulomatous inflammation caused by filamentous bacteria. The lesion responded well to radiation therapy. Although actinomycosis was suspected histopathologically, no actinomycetes were detected in the nasal lesion by a bacterial culture conducted at a commercial laboratory. The submandibular lymph node and subcutaneous tissue exhibited swelling. Microbiological examination and genetic analysis based on 16S rDNA gene sequence revealed that *Nocardia* spp. were isolated from both lesions.

KEY WORDS: intranasal mass, nocardiosis, radiation therapy, suppurative granulomatous inflammation

doi: 10.1292/jvms.14-0319; *J. Vet. Med. Sci.* 77(5): 597–599, 2015

Nocardiosis is an unusual infectious disease in animals that causes suppurative to pyo-granulomatous lesions on the skin and lungs [6]. There are also systemic or disseminated types of nocardiosis [5], but intranasal lesions caused by *Nocardia* spp. are not known to have been reported previously in dogs and cats. The definitive diagnosis of nocardiosis is generally based on microbiological culture and phenotypical characterization [4]. Recently, new molecular techniques have been introduced to identify different species of the genus *Nocardia* [4]. This case describes suppurative granulomatous sinorhinitis in a cat affected with nocardiosis.

A 9-year-old spayed female cat was examined for drainage of cheek skin. Tests for feline leukemia virus antigen and feline immunodeficiency virus antibody produced negative results with a commercially available kit (SNAP FIV/FelV Combo Test; IDEXX Laboratories, Tokyo, Japan). Upon physical examination, a slight fever (39.2°C) was recorded, and drainage from the right cheek was observed. Although the cat had been treated for these symptoms using 8 mg/kg of cefovecin sc, the cat was brought back six months after the symptomatic treatment due to the development of left-side facial deformity, intermittent drainage, epistaxis, lethargy and eye discharge. Complete blood cell count and serum chemistry revealed only mild hyperglycemia. A mass in the left nasal cavity and osteolysis of maxilla were found in a computed tomography (CT) scan of the cat's head. The

percutaneous fine needle aspiration and perinasal biopsy of the mass revealed suppurative granulomatous inflammation. Filamentous microorganisms were also found within the lesion (Fig. 1). Bacterial and mycological cultures showed no detectable filamentous bacteria or fungus. Although neoplastic lesions were not observed histopathologically, a single dose of orthovoltage x-ray radiation therapy (6.3 Gy) was administered to the intranasal mass; attempting to improve the mass and facial deformity. The cat was also treated by the subcutaneous injection and inhalation of oxytetracycline for 2 weeks. Although a discharge of pus from the cheek occurred intermittently, systemic condition and facial deformations improved. Two years (803 days) after it was first seen, the cat was examined again with a relapse of cheek drainage and facial deformity. In spite of antimicrobial therapy and the washing of the nasal cavity, the intranasal mass size increased and was exposed on the surface of the face on day 912 (Fig. 2). A subcutaneous injection of prednisolone was combined with antimicrobial therapy. However, the mass size still increased, and the cat exhibited fever (40.1°C), anorexia and progressive worsening of body condition.

The cat was referred to the Animal Medical Center at Gifu University for palliative radiation therapy on day 984. A CT scan and a biopsy revealed an intranasal mass and granulomatous inflammation (Fig. 3). Specimens from the lesion were cultured, but no microorganisms (except for *Staphyrococcus intermedius* group, which was not the cause of granuloma in this case) were obtained on the agar that contain both blood agar added NAD and MacConkey agar at 35°C with 5% CO₂ for 48 hr. Also, no anaerobes were obtained on the anaerobic rabbit blood agar and BBE agar at 35°C with anaerobical condition for 72 hr. Radiation therapy of 35 Gy in 5 fractions (7 Gy/fraction) with a linear accel-

*CORRESPONDENCE TO: NAKANISHI, A., Maizuru Animal Medical Center, 625–0037 Maizuru, Japan. e-mail: ataruatare@gmail.com

©2015 The Japanese Society of Veterinary Science

This is an open-access article distributed under the terms of the Creative Commons Attribution Non-Commercial No Derivatives (by-nc-nd) License <<http://creativecommons.org/licenses/by-nc-nd/3.0/>>.

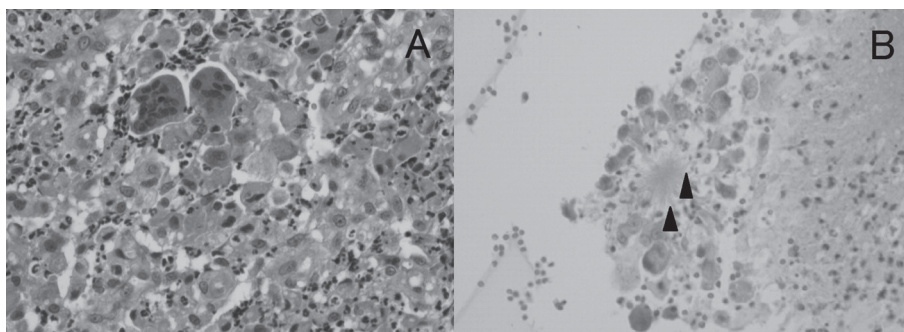


Fig. 1. Histopathological image of intranasal mass (Hematoxylin and eosin staining, $\times 400$). (A) Neutrophils, macrophages and multinucleated giant cells accumulated and formed granuloma. (B) Filamentous bacteria (arrowheads) are seen in the center of the granuloma.




Fig. 2. External appearance of the cat at the day of before (A) and after (B) radiation therapy. (A) A mass originated from nasal cavity exposed on the face. (B) The mass is not seen from the outside. A part of lower eyelid is dropped due to the mass.

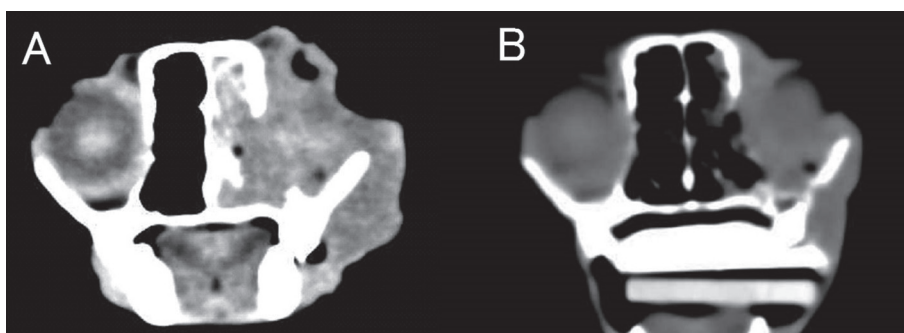


Fig. 3. Non contrast enhanced CT image of the cat taken in the transverse plane at the level of orbit before (A) and after (B) radiation therapy. (A) Note the attenuated soft tissue mass in the left nasal cavity. Erosion of the maxilla allowed the mass to extend into the orbit and subcutaneous tissue. (B) The mass is not seen in the nasal cavity, except for little soft tissue.

erator was conducted on the intranasal and exposed masses. The cat was treated with minocycline on the fifth radiation, because actinomycosis was suspected, and the previously cultured *S. intermedius* group was susceptible to it.

The mass reduced rapidly from the first radiation and was no longer externally visible by the day of the second radiation (Fig. 2). On the day of the fifth radiation, the intranasal mass had diminished in the CT scan image (Fig. 3), how-

ever, swelling of the subcutaneous tissue on the head and left submandibular lymph node remained. Histopathologic examination of both lesions revealed the same suppurative granulomatous inflammation.

Specimen from the lesion was cultured on Chocolate agar at 37°C with 5% CO₂ enriched atmosphere for 96 hr. Morphological examination of isolates revealed Gram-positive, rod-shaped and filamented microorganisms. Molecular anal-

Table 1. Antimicrobial susceptibility test of isolated *Nocardia flavorosea*

	48 hr (mg/l)	72 hr (mg/l)
ABPC	8	16
CEZ	16	16
CTX	≤0.5	≤0.5
SM	8	8
GM	≤0.5	≤0.5
KM	≤1	≤1
TC	2	4
NA	64	64
CPFX	2	2
CL	>16	>16
CP	32	32
TMP	>16	>16

In vitro antimicrobial susceptibility test performed using broth microdilution methods (35°C with 5% CO₂ enriched atmosphere, for 48 hr and 72 hr). Isolated bacteria are susceptible to kanamycin (≤1 mg/l) and tetracycline (2 mg/l). ABPC: Ampicillin, CEZ: Cefazolin, CTX: Cefotaxime, SM: Streptomycin, GM: Gentamycin, KM: Kanamycin, TC: Tetracycline, NA: Nalidixic Acid, CPFX: Ciprofloxacin, CL: Colistin, CP: Chloramphenicol, TMP: Trimethoprim.

ysis based on 16S rDNA gene was conducted for identification of the isolate [2, 3]. The 1,135 bases sequence of 1,135 bases obtained was compared with the GenBank database using BLAST and revealed a 99% homology with *Nocardia flavorosea* (Gene bank No. GQ259602). *In vitro* antimicrobial susceptibility test was performed using broth microdilution methods (35°C with 5% CO₂ atmosphere, for 48 hr) and showed high susceptibility to kanamycin (≤1 mg/l) and tetracycline (2 mg/l) as shown in Table 1. Five months after the fifth radiation, the cat was still on minocycline treatment and remained free of relapse.

Nocardiosis caused by *Nocardia spp.* is a rare infectious disease found in animals that have been inadvertently exposed by a skin puncture wound or by inhalation into the lungs [8]. Although nocardiosis has been classified into three clinical presentations (cutaneous, pulmonary and systemic [5]), intranasal lesion has not been previously reported in animals to our knowledge. In humans, immunosuppressive states, such as acquired immune deficiency syndrome or transplantation and corticosteroid administration, often cause nocardiosis [1]. The present case tested negative for the FeLV antigen and FIV antibody, and the cat had not been administered immunosuppressive agents.

Animals affected with nocardiosis are usually effectively treated with appropriate antibiotics based on an antimicrobial susceptibility test [4]. Successful treatment of cats with nocardiosis has been reported mostly for skin lesions [1, 4]. In contrast, fatal cases were reported for other forms of nocardiosis following standard antibiotic treatment [4, 10]. In this case, radiation therapy was performed, because the intranasal mass increased in spite of antibiotic treatment. Radiation is not a definitive therapy for suppurative granulomatous lesions; but, it was effective as a palliative therapy considering the reduction in mass size and improvement of

the cat's general condition after the first radiation treatment.

Many filamentous bacteria were detected in the lesion histopathologically, but bacterial cultures failed many times. Since the bacteria grew slowly, colonies were formed after 96 hr of incubation, and thus, colonies were not detected at the commercial laboratory after 48 hr of incubation in this case. There are some reports of animal nocardiosis that bacterial colonies were obtained after 72 hr to 2 weeks of incubation [4, 7]. If nocardiosis is suspected, specimens should be incubated aerobically 72 hr or more. Also, there is a case report that definite diagnosis was made by only polymerase chain reaction (PCR) to amplify the 16S ribosomal RNA gene using DNA extracted from the pus because no microbial colony was cultured from the lesion [6]. PCR analysis should be used for detection of 16S ribosome RNA of *Nocardia spp.* in the case that bacterial culture failed.

Nocardia spp. are gram-positive, aerobic and partially or variably acid-fast bacteria that form branching filamentous rods [9]. Molecular analysis based on 16S rRNA gene revealed that sequence obtained from the isolate showed 99% homology with *N. flavorosea*. Because sequence from 16S rRNA of *N. flavorosea* has 99.2% similarity with that of *N. carnea*, further analysis like genomic DNA-DNA hybridization is needed to differentiate these two species [3].

REFERENCES

1. Angeles, R. M., Lasala, R. P. and Fanning, C. V. 2008. Disseminated subcutaneous nocardiosis caused by *Nocardia farcinica* diagnosed by FNA biopsy and 16S ribosomal gene sequencing. *Diagn. Cytopathol.* **36**: 266–269. [Medline] [CrossRef]
2. Chun, J. and Goodfellow, M. 1995. A phylogenetic analysis of the genus *Nocardia* with 16S rRNA gene sequences. *Int. J. Syst. Bacteriol.* **45**: 240–245. [Medline] [CrossRef]
3. Chun, J., Seong, C. N., Bae, K. S., Lee, K. J., Kang, S. O., Goodfellow, M. and Hah, Y. C. 1998. *Nocardia flavorosea* sp. nov. *Int. J. Syst. Bacteriol.* **48**: 901–905. [Medline] [CrossRef]
4. de Farias, M. R., Werner, J., Ribeiro, M. G., Rpdigheri, S. M., Cavalcante, C. Z., Chi, K. D., Condas, L. A. Z., Gonoï, T., Matsuzama, T. and Yazama, K. 2012. Uncommon mandibular osteomyelitis in a cat caused by *Nocardia africana*. *BMC Vet. Res.* **8**: 239. [Medline] [CrossRef]
5. Edwards, D. F. 2006. Actinomycosis and nocardiosis. pp. 451–461. In: *Infectious Disease of the Dog and cat*, 3rd ed. (Greene, C. E. ed.) Saunders Elsevier, St. Louis.
6. Harada, H., Endo, Y., Sekiguchi, M., Setoguchi, A. and Momoi, Y. 2009. Cutaneous Nocardiosis in a Cat. *J. Vet. Med. Sci.* **71**: 785–787. [Medline] [CrossRef]
7. Hattori, Y., Kano, R., Kunitani, Y., Yanai, T. and Hasegawa, A. 2003. *Nocardia africana* Isolated from a Feline Mycetoma. *J. Clin. Microbiol.* **41**: 908–910. [Medline] [CrossRef]
8. Linda, M. and Keith, A. Hnilica Nocardiosis. pp. 52–53. In: *Small Animal Dermatology*, 2nd ed., Saunders, Philadelphia.
9. McNeil, M. M. and Brown, J. M. 1994. The medically important aerobic actinomycetes: epidemiology and microbiology. *Clin. Microbiol. Rev.* **7**: 357–417. [Medline]
10. Malik, R., Krockenberger, M. B., O'Brien, C. R., White, J. D., Foster, D., Tisdall, P. L. C. and Gilpin, C. 2006. *Nocardia* infections in cats: a retrospective multi-institutional study of 17 cases. *Aust. Vet. J.* **84**: 235–245. [Medline] [CrossRef]