

Hexachlorophene and Cuprizone Induce the Spongy Change of the Developing Rat Brain by Different Mechanisms: The Role of 2', 3'-Cyclic Nucleotide 3'-Phosphodiesterase (CNPase)

Takeshi KANNO^{1)*}, Satoshi SASAKI¹⁾, Naoaki YAMADA¹⁾, Kazufumi KAWASAKO¹⁾ and Minoru TSUCHITANI¹⁾

¹⁾Kashima Laboratory, Mitsubishi Chemical Medience Corp., 14 Sunayama, Kamisu, Ibaraki 314-0255, Japan

(Received 19 October 2011/Accepted 25 January 2012/Published online in J-STAGE 8 February 2012)

ABSTRACT. The goal of this research was to identify mechanisms responsible for the spongy change induced in rats after repeated hexachlorophene (HCP) or cuprizone (CPZ) dosing. Rats were dosed with 35 mg/kg HCP for 5 days followed by drug withdrawal for 7 days suffered spongy changes to the white matter of the cerebrum, cerebellum, medulla oblongata, and spinal cord that were accompanied by degeneration of oligodendroglia. The severity of both lesions increased prominently on day 5; however, the spongy change decreased and degeneration of oligodendroglia reversed on day 12 (7 days after dosing ceased). On day 12, cerebral cortex oligodendroglia were stained strongly by anti-CNPase. Other rats were fed for 8 days with powdered chow containing 1% (w/w) CPZ, which was then withdrawn for 16 days. The rats exhibited the spongy change in the white matter of the cerebrum and cerebellum as well as oligodendroglial cell death from day 3. The severity of both lesions increased prominently on day 8. Cerebral cortex oligodendroglia were stained strongly by anti-CNPase on days 3 to 8 and decreased to the control levels by day 24 (16 days after dosing ceased). Electron microscopy revealed that oligodendroglia frequently displayed apoptotic morphology. These findings suggest that CNPase expression was induced in the course of restoration following HCP-induced insults to oligodendroglia and the myelin sheath, and in the course of demyelination by CPZ-induced damage to oligodendroglia. However, the role of CNPase on both courses is unclear.

KEY WORDS: CNPase, cuprizone, hexachlorophene, neurotoxicity, rat.

doi: 10.1292/jvms.11-0469; *J. Vet. Med. Sci.* 74(7): 837–843, 2012

Hexachlorophene (HCP), used as an antimicrobial agent in soaps, liquid detergents, and cosmetics during the 1960's [12, 22], has also been widely used in agriculture as a plant fungicide and pesticide [12, 13, 22]. In 1969, however, Gump *et al.* [8] conducted experiments demonstrating that HCP was toxic chemical in a variety of animals, including mice, rats, guinea pig, dogs, and sheep. Moreover, Kimbrough and Gaines [13] described the HCP-induced spongy change in the cerebral white matter in rats. Considerable research has been subsequently devoted to studying the HCP-induced spongy change [4, 12, 13, 16, 22, 23], which corresponds to the splitting of the intraperiod line of the myelin sheath [16].

Cuprizone (CPZ), a potent copper chelator, causes the spongy change in the central nervous system of mice, guinea pigs, and rats [3, 6, 19]. CPZ treatment provides a model for toxic demyelination model characterized by this pathology [1, 7, 18]. The CPZ-induced spongy change is also accompanied by the same ultrastructural changes as those described above for HCP [3] and is believed to be caused by cytotoxic insults to oligodendroglia [3, 19].

Myelin basic protein (MBP) [2, 5, 10, 15], proteolipid protein (PLP) [2, 5, 10], and CNPase [2, 5, 10, 15, 24] are

specific markers expressed either in oligodendroglia or in the myelin. MBP and PLP are respectively associated with the formation of the major dense line and intraperiod lines of the myelin [5, 25]. Both proteins compose 60–80% of total protein content of the central nervous system [5]. Given that CNPase expression increases from postnatal days 15 to 30 in the developing rat brain, CNPase is thought to play an important role in myelinogenesis [10]. Furthermore, CNPase provides a marker of oligodendroglia differentiation because it localizes to the periaxonal region of the myelin sheath and oligodendroglial cell membranes [24]. We have been able to demonstrate a single dose of aniline induces the spongy change, which can be detected by light microscopy, and that CNPase activity peaks before its onset [11]. However, the role of CNPase during cytotoxic insults to oligodendroglia or the myelin sheath is still unknown.

To better understand the role of CNPase expression in neurotoxicity, we examined the temporal changes in immunostaining patterns of CNPase in the HCP- and CPZ-induced spongy change in rats.

MATERIALS AND METHODS

Chemicals: Hexachlorophene (C₁₃H₆Cl₆O₂, CAS No.70–30-4) and cuprizone (biscyclohexanone oxaldihydrazone, C₁₄H₂₂N₄O₂, CAS No.370–81-0) were obtained from Sigma-Aldrich Japan Co., Ltd. (Tokyo, Japan). A 3.5 mg/ml HCP stock solution in 1% carboxymethylcellulose-Na (CMC-Na) was used. CPZ was mixed with powdered chow

*CORRESPONDENCE TO: KANNO, T., Kashima Laboratory, Mitsubishi Chemical Medience Corp., 14 Sunayama, Kamisu, Ibaraki 314-0255, Japan.

e-mail: Kanno.Takeshi@me.medience.co.jp

©2012 The Japanese Society of Veterinary Science

(CF-1, Oriental Yeast Co., Ltd., Tokyo, Japan) to prepare a 1 w/w% homogeneous mixture.

Animals: Female, Crlj: WI (Wistar), 19-day-old and male, Crl: (CD) SD, 16-day-old rats, all with their dams, were obtained from Charles River Laboratories Japan Inc. (Tsukuba, Japan). The animals were housed in polycarbonate cages in a room maintained at 20°C to 25°C, 55 ± 15% relative humidity under 12-hr light/dark cycle. Rats were offered a commercial diet (MF or CF-1, Oriental Yeast Co., Ltd., Tokyo, Japan) and tap water *ad libitum*. Three-week-old healthy rats were used and acclimated for 6 (Crlj: WI (Wistar)) or 5 (Crl: (CD) SD) days. The animals were cared for according to the Japanese Association for Laboratory Animal Science's and our institution's guidelines for the care and use of laboratory animals. Mitsubishi Chemical Medience Corp.'s Institutional Animal Care and Use Committee approved these protocols.

Protocol design: Study 1: Twelve Crlj: WI (Wistar) rats were classified according to body weight and on this basis assigned to 4 experimental groups (3 rats per group) by the day of euthanasia. Two rats in each group were dosed by gavage with 35 mg/kg HCP, and 1 rat was dose with CMC-Na as a control. The dose level was determined based on the published reports [20, 21]. Dosing was continued for 5 days, after which 1 group (day 12) was withdrawn from treatment for 7 days. Ultimately 1 control rat and 2 HCP-treated rats were euthanized on each day point (days 1, 2, 5, and 12) sequentially. The first day of dosing was designated as day 1.

Study 2: Twelve Crl: (CD) SD rats were classified by body weight and accordingly assigned to 4 experimental groups (3 rats per group) by the day of euthanasia. Two rats in each group were fed powdered chow containing 1 w/w% CPZ, and 1 rat was fed a normal diet. The dose level was determined based on the published data [3, 6, 18]. Dosing was continued for 8 days, at which time one group (day 24) was withdrawn from treatment for 16 days. Ultimately 1 control rat and 2 CPZ-treated rats were euthanized on each day point (days 3, 6, 8, and 24) sequentially. The first day of dosing was designated as day 1.

Pathological examination: All rats were anesthetized via intraperitoneal injection of pentobarbital sodium (Nembutal Injection, Dainippon Sumitomo Pharma Co., Ltd., Osaka, Japan) and euthanized by exsanguination from the right atrium, and then perfused with 4% paraformaldehyde via the left ventricle. We prepared cross sections of the brain and spinal cord (cervical, thoracic, and lumbar) tissues. The samples were embedded in paraffin and stained with hematoxylin and eosin (HE). Brain sections were also stained using a labeled streptavidin-biotin system (DAKO LSAB2 System-HRP, DAKO Japan Ltd., Kyoto, Japan). Primary antibodies, their working dilutions and suppliers were as follows: mouse monoclonal antibodies against human CNPase (1:400 in dilution, Millipore, Billerica, MA, U.S.A.), human MBP (1:25 in dilution, Serotec Ltd., Oxford, England), PLP (1:200 in dilution, Millipore, Billerica, MA, U.S.A.), and a rabbit polyclonal antibody against activated caspase-3 (1:80 in dilution, Millipore, Billerica, MA, U.S.A.). For antigen retrieval using antibodies against CNPase, MBP, and PLP, the slides were transferred to 0.5% Immunosaver (Nisshin

EM Corp., Tokyo, Japan), and heated for 25 min at 95°C using a 400W-MW processor (MI-77, Azumaya Corp., Tokyo, Japan) and microwaved.

The severity of the spongy change and the degree of anti-CNPase immunostaining were designated at grades 4 and 3 [11], respectively, and temporally evaluated as follows: A. The spongy change: score=0, not detectable (-); score=1, small vacuoles scattered in the white matter (+); score=2, small or middle vacuoles diffusely present in the white matter (++); score=3, large vacuoles massively present in the white matter (+++). B. anti-CNPase antibody: score=1, slightly positive in the submembranous region of small oligodendroglia (+); score=2, moderately positive throughout the swollen cytoplasm of oligodendroglia (++); score=3, strongly positive throughout the swollen cytoplasm of oligodendroglia (+++).

For electron microscopy, cerebral cortex, corpus callosum, and corpus striatum tissue fragments were fixed in 4% paraformaldehyde and then fixed in 1% osmium tetroxide for 2 hr. Sections were embedded in an epoxy resin. Semi-thin sections were stained with toluidine blue. Ultrathin sections for electron microscopy (TEM, Hitachi H-7600, Hitachi High-Technologies Corp., Tokyo, Japan) were stained with uranyl acetate and lead citrate.

RESULTS

Mortality and clinical signs: Study 1: No deaths occurred due to HCP treatment. HCP-treated rats showed hindlimb paralysis during the administration period, but this symptom disappeared 3 days after dosing ceased.

Study 2: One CPZ-treated rat died on day 8. CPZ-treated rats showed locomotor activity loss or titubation on day 5, but these signs disappeared 1 day after dosing ceased.

Histopathological findings: Study 1: No abnormalities were observed in any region of the brain in HCP-treated rats on day 1. The spongy change was observed in the white matter of the cerebrum, cerebellum, medulla oblongata, and spinal cord from days 2 to 12 (7 days after dosing ceased). The lesions in the cerebrum and cerebellum were most severe, particularly in the corpus callosum and the white matter of the cerebellum. Degeneration of oligodendroglia with pyknotic nuclei was present in the affected white matter of the cerebrum, cerebellum, medulla oblongata, and spinal cord from days 2 to 5. On day 5, the severity of the spongy change and degeneration of oligodendroglia increased prominently. On day 12, however, the severity of the spongy change decreased and degenerated oligodendroglia reverted to their normal phenotype.

Study 2: The spongy change was observed in the white matter of the cerebrum and cerebellum, and cerebral cortex from days 3 to 8. On day 8, the severity of the lesion peaked. However, the spongy changes in CPZ-treated rats were slightly less severe than in HCP-treated rats. In addition, on day 24 (16 days after dosing ceased), the spongy change fully reversed. Degenerated oligodendroglia with pyknotic nuclei and condensed cytoplasm, and apoptotic morphology, such as fragmented nuclei and condensed eosinophilic cytoplasm

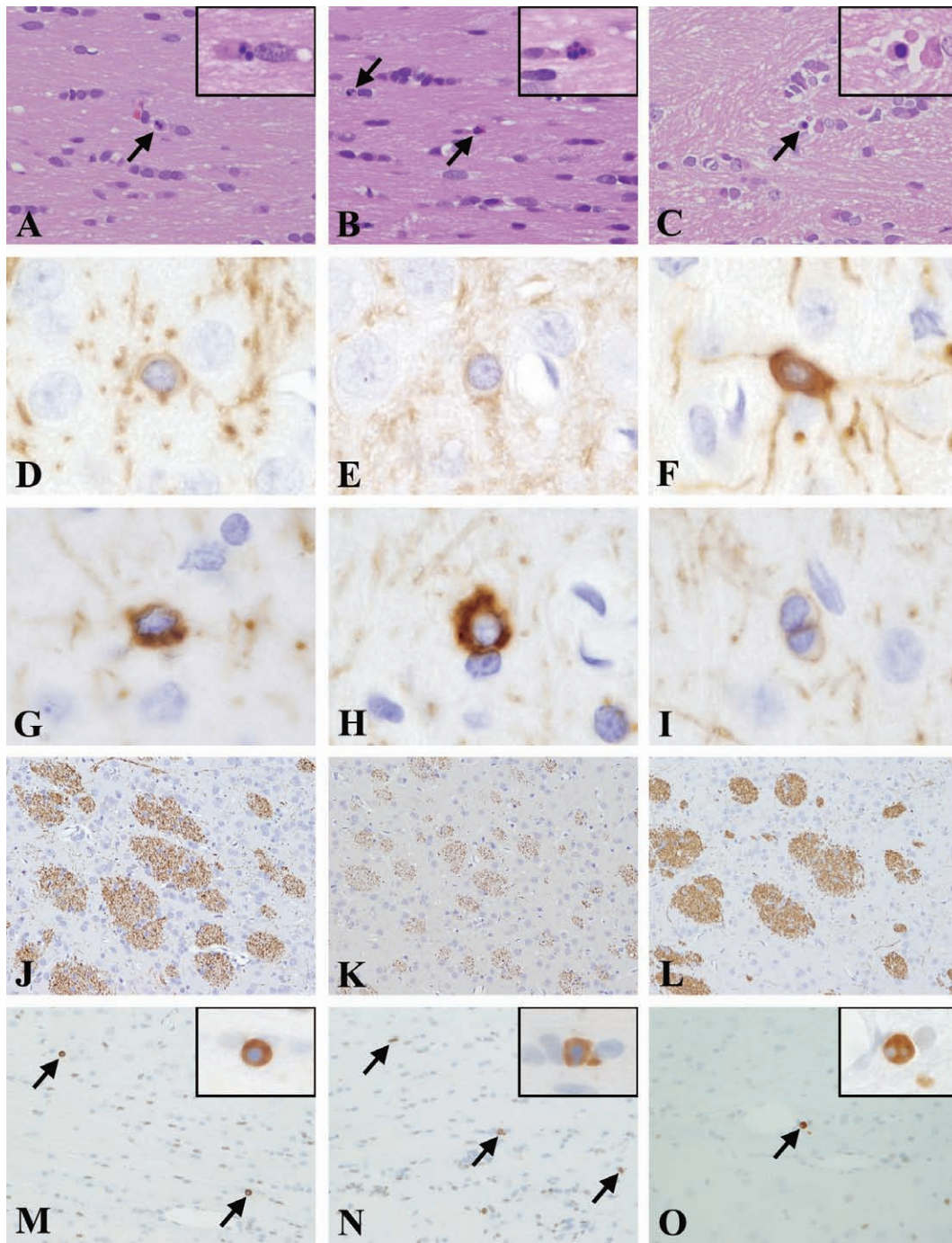


Fig. 1. Oligodendroglial apoptosis characterized by fragmented nuclei and condensed eosinophilic cytoplasm in the corpus callosum following CPZ dosing on days 6 (A, arrow), 8 (B, arrows), and 24 (C, arrow). Immunostaining of CNPase in the cerebral cortex in rats treated with HCP (D to F) or CPZ (G to I). Immunostaining of MBP (J to L) in the corpus striatum and caspase-3 (M to O) in the corpus callosum following CPZ treatment. CNPase reactivity is observed in the submembranous region of oligodendroglia in the controls (D), HCP-treated rats on day 5 (E), and CPZ-treated rats on day 24 (I). Strong CNPase immunostaining extends to the swollen cytoplasm of oligodendroglia in HCP-treated rats on day 12 (F) and CPZ-treated rats on days 6 (G) and 8 (H). Corpus striatum nerve fibers stain positively for MBP in the control (J) and recovered animals on day 24 (L). However, immunoreactivity in the corpus striatum decreased on day 8 (K). Caspase-3 expression by some oligodendroglia is observed on days 6 (M, arrows), 8 (N, arrows), and 24 (O, arrow). On day 8, numerous oligodendroglia are strongly positive for caspase-3 (N, arrows).

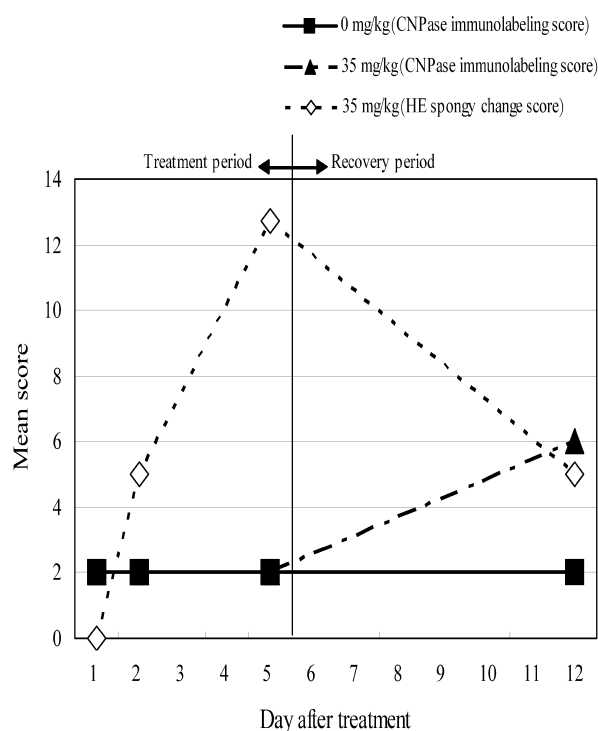


Fig. 2. Mean score of the severity of the spongy change and the degree of CNPase immunostaining in HCP-treated rats. CNPase expression peaked on day 12, while the spongy change is detected on day 2, and peaked on day 5. On day 12, the severity of the spongy change decreases.

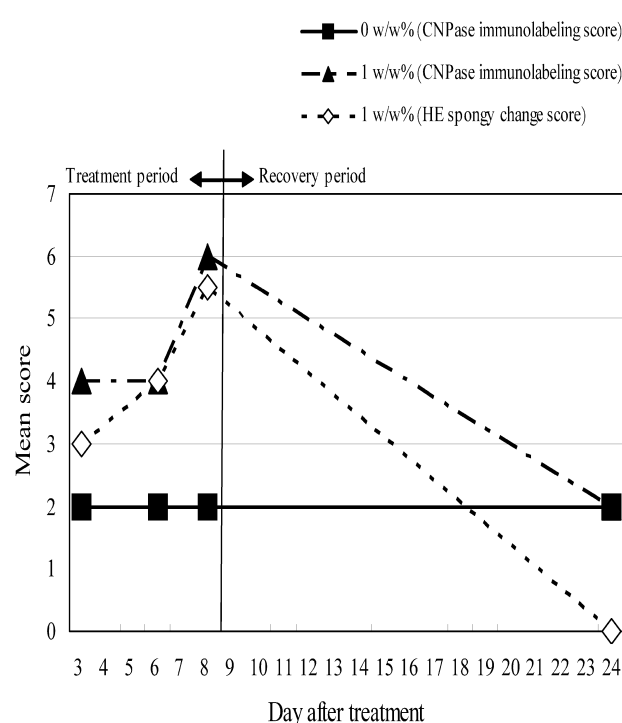


Fig. 3. Mean score of the severity of the spongy change and the degree of CNPase immunostaining in CPZ-treated rats. CNPase expression is detected from day 3, peaking on day 8, but reverse to control levels on day 24, while the spongy change is detected on day 3, peaking on day 8. On day 24, the spongy change reverses.

of oligodendroglia were detected in the cerebral cortex and white matter from days 3 to 24 (Fig. 1A, 1B and 1C). On day 8, oligodendroglial cell death was most frequent.

Immunohistochemical findings: Study 1: Temporal changes were identified by CNPase immunostaining, while no changes were observed when sections were immunostained for MBP, PLP, or caspase-3.

In controls, CNPase positive reaction was observed in the submembranous region of the normal oligodendroglia in the cerebral cortex (Fig. 1D). In HCP-treated rats, CNPase positive reaction was comparable to that of the controls from days 1 to 5 (Fig. 1E). On day 12, strong CNPase positive reaction extended to the swollen cytoplasm of oligodendroglia in the cerebral cortex (Fig. 1F). In contrast, no strong CNPase positive reaction was observed in the white matter as control. Figure 2 depicts the temporal spongy change in the white matter and the CNPase immunostaining pattern in the cerebral cortex. CNPase expression peaked on day 12, 7 days after dosing ceased, while the spongy change was detected on day 2 and peaked on day 5.

Study 2: Temporal changes were identified by CNPase, MBP, and caspase-3 immunostaining while no changes were detected by PLP immunostaining.

In CPZ-treated rats, from days 3 to 8 (Fig. 1G and 1H), moderate to strong CNPase immunostaining in the cerebral cortex extended to the swollen cytoplasm of oligodendroglia

and was strongest on day 8 (Fig. 1H). CNPase positive reaction was comparable to that of the controls on day 24 (Fig. 1I). No strong CNPase positive reaction was observed in the white matter as control. CNPase reaction in the white matter did not vary on each day point. Figure 3 depicts the temporal spongy change in the white matter as well as the CNPase immunostaining pattern in the cerebral cortex. CNPase expression was observed from day 3 and peaked on day 8. On day 24, CNPase expression reversed to control levels. Corpus callosum or corpus striatum nerve fibers in controls were positive for MBP immunostaining (Fig. 1J). In CPZ-treated rats, MBP immunoreactivity in the white matter, particularly in the corpus callosum and corpus striatum, decreased from days 3 to 8 (Fig. 1K). MBP immunoreactivity reappeared on day 24 (Fig. 1L). Caspase-3 immunostaining was undetectable in controls. Caspase-3 immunoreactivity in oligodendroglia was observed in the cerebral cortex and corpus callosum from days 3 to 8 (Fig. 1M and 1N). On day 8, numerous oligodendroglia were stained strongly by the caspase-3 antibody (Fig. 1N). A few oligodendroglia were caspase-3 positive on day 24 (Fig. 1O).

Electron microscopic findings: Study 1: Splitting of the myelin sheath and edema of the cytoplasm of oligodendroglia in the cerebral cortex, corpus callosum, and corpus striatum were observed on day 2 and thereafter. On day 5, the severity and incidence of splitting of the myelin sheath

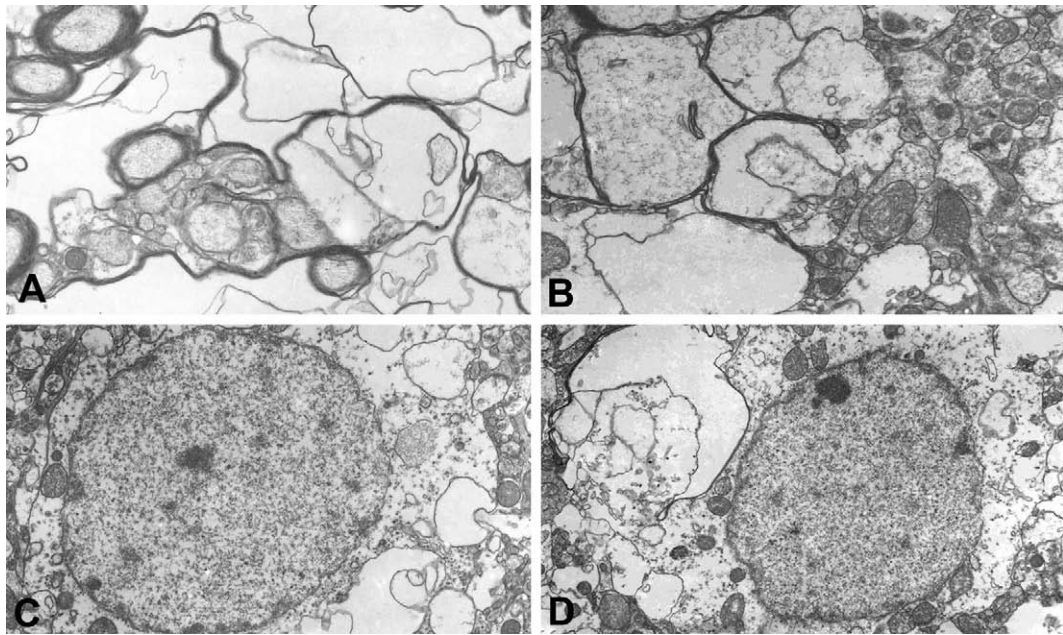


Fig. 4. Electron photomicrographs of the myelin sheath and oligodendroglia in the corpus callosum and cerebral cortex in HCP dosing, on day 5. The myelin sheath splitting in the corpus callosum (A) and cerebral cortex (B) are observed. In addition, the swollen dendritic processes or axons are also observed (B). The swollen cytoplasm of oligodendroglia in the corpus callosum (C) and cerebral cortex (D) is observed.

increased prominently in the corpus callosum (Fig. 4A) and cerebral cortex (Fig. 4B). Furthermore, the severity of the swollen dendritic processes and axons increased in the cerebral cortex (Fig. 4B). The swollen cytoplasm of oligodendroglia was most severe in the corpus callosum (Fig. 4C), cerebral cortex (Fig. 4D), and corpus striatum. On day 12, the severity and incidence of splitting of the myelin sheath and the swollen cytoplasm of oligodendroglia in the corpus callosum decreased. In the cerebral cortex, the swollen dendritic processes, axons, and cytoplasm of oligodendroglia reversed their normal features.

Study 2: Splitting of the myelin sheath in the cerebral cortex (Fig. 5A) and corpus callosum was observed from days 6 to 8. From days 3 to 24, oligodendroglia frequently displayed apoptotic morphologies characterized by condensed and fragmented nuclei with apoptotic bodies in the corpus callosum. On day 8, numerous apoptotic cells were present in the corpus callosum (Fig. 5B). Consistent with the decreased numbers and diameters of myelinated nerve fibers in the fascicles of the corpus striatum, many non-myelinated nerve fibers were present from days 6 to 8 (Fig. 5C). On day 24, the normal features of the myelin sheath in the cerebral cortex, corpus callosum, and corpus striatum were restored. However, a few oligodendroglia exhibited apoptotic features.

DISCUSSION

The physiological function of CNPase is unknown. However, it has been proposed to be closely involved with

process outgrowth in oligodendroglia [17]. Then we consider that CNPase expression may be related to restoration following HCP-induced insults to oligodendroglia and the myelin sheath. Meanwhile, CNPase expression increased with progression of splitting of the myelin sheath in CPZ-treated rats. That is to say, the stage of CNPase expression in CPZ-treated rats is different from that in HCP-treated rats. So it is considered that the role of CNPase is not single. It is well known that partial remyelination occurs during acute demyelination in CPZ exposure [14]. Although CNPase may play a role in partial remyelination during progression of splitting of the myelin sheath in CPZ-treated rats, the results in the present study are not sufficient to support this speculation.

In HCP-treated rats, the distribution of the lesion observed here corresponds that of described by other reports [12, 13, 16, 22, 23]. Because HCP increases the cerebral water content, it is suggested that the spongy change induced by HCP results from intramyelin accumulation of the fluid [16, 22], and this change is reversible [12, 13, 16, 22, 23]. In our present study, edema of the dendritic processes or axons, in addition to myelin sheath splitting, was observed from days 2 to 12. Therefore we consider that the spongy change in our study was induced by similar mechanism described in above literatures [16, 22]. In CPZ-treated rats, the spongy change with oligodendroglial apoptosis was present in our study, and this result is consistent with published data [3, 9, 19]. Hesse *et al.* [9] described that oligodendroglial apoptosis occur before demyelination in mice. Thus, oligodendroglia are considered to be the primary target of CPZ rather than the

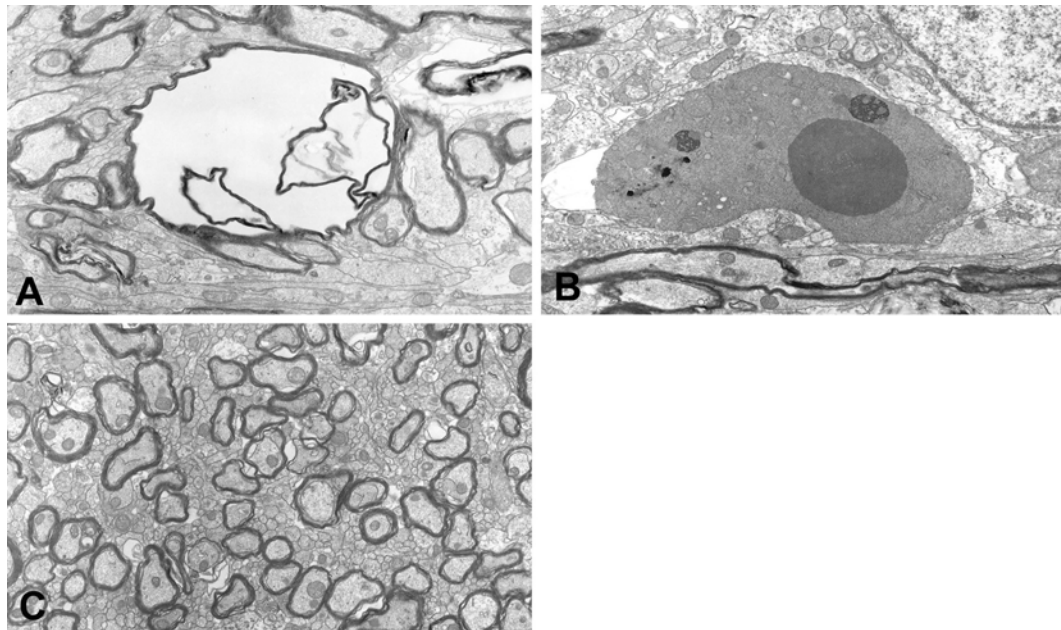


Fig. 5. Electron photomicrographs of the myelin sheath, oligodendroglia, and nerve fiber fascicles in the cerebral cortex, corpus callosum, and corpus striatum induced by CPZ. The myelin sheath splitting in the cerebral cortex is observed on day 8 (A). Oligodendroglia exhibiting morphological characteristics of apoptosis, such as condensed and fragmented nuclei with apoptotic bodies on day 8 in the corpus callosum (B). The numbers and diameters of myelinated nerve fiber in the corpus striatum prominently decreases, and numerous non-myelinated nerve fibers are observed on day 8 (C).

myelin sheath. Further, the mechanism involved in splitting of the myelin sheath by CPZ differs from that induced by HCP. Splitting of the myelin sheath may occur simultaneously in HCP-treated rats or sporadically in CPZ-treated rats. Then, in HCP-treated rats, restoration of the myelin sheath may occur after simultaneous splitting, and in CPZ-treated rats, remyelination may occur during demyelination which starts irregularly. So we consider that the difference in the mechanism of myelin sheath splitting can cause the difference of the stage of CNPase expression in HCP-treated rats and CPZ-treated rats.

Strong CNPase positive reaction was not observed in the white matter, where degeneration of oligodendroglia and the spongy change were present in both HCP- and CPZ-treated rats. We previously reported that aniline induces the spongy change in the white matter of the spinal cord, which is accompanied by strong CNPase immunoreaction in the gray matter but not the white matter [11]. The reason for this is unknown why CNPase immunoreaction of oligodendroglia only in the gray matter.

MBP immunoreactivity decreased in the white matter, particularly of the corpus callosum and corpus striatum in CPZ-treated rats. It is reported that decreased MBP immunoreactivity resulted from significant decrease in myelin yield and the dramatic changes in the chemical composition in rat model of CPZ-induced demyelination [1]. Therefore, we think that decreased MBP immunoreactivity results from similar phenomenon in present study.

In summary, our findings here suggest that increased

CNPase expression is induced in the course of restoration subsequent to cytotoxic insults to oligodendroglia and the myelin sheath resulting from HCP treatment and in the course of demyelination by damage to oligodendroglia resulting from CPZ treatment. This difference in the temporal pattern of CNPase expression may be attributed to differing splitting mechanisms between in HCP- and CPZ-treated rats. However, the role of CNPase on the healing is unclear under the HCP and CPZ intoxication in the brain.

ACKNOWLEDGMENTS. The authors thank Jun Sasaki and Saki Itou for assistance with this investigation, and Takayoshi Ito, Yukie Ishibashi, and Chie Shiroumaru for their excellent technical assistance. The authors also thank Steve Yamakami, Azumi Takahashi, and Kanae Tamatsukuri for editing the manuscript.

REFERENCES

1. Adamo, A. M., Paez, P. M., Escobar Cabrera, O. E., Wolfson, M., Franco, P. G., Pasquini, J. M. and Soto, E. F. 2006. Remyelination after cuprizone-induced demyelination in the rat is stimulated by apotransferrin. *Exp. Neurol.* **198**: 519–529. [[Medline](#)] [[CrossRef](#)]
2. Berry, M. and Butt, A. M. 1997. Macrogliosis. pp. 63–83. In: *Greenfield's Neuropathology*, 6th ed. (Graham, D. I. and Lantos, P. L. eds.), Arnold, London, Great Britain.
3. Blakemore, W. F. 1972. Observations on oligodendrocyte degeneration, the resolution of status spongiosus and remyelination in cuprizone intoxication in mice. *J. Neurocytol.* **1**: 413–426.

- [Medline] [CrossRef]
4. Cammer, W. and Moore, C. L. 1972. The effect of hexachlorophene on the respiration of brain and liver mitochondria. *Biochem. Biophys. Res. Commun.* **46**: 1887–1894. [Medline] [CrossRef]
 5. Campagnoni, A. T. 1988. Molecular biology of myelin proteins from the central nervous system. *J. Neurochem.* **51**: 1–14. [Medline] [CrossRef]
 6. Carlton, W. W. 1969. Spongy encephalopathy induced in rats and guinea pigs by cuprizone. *Exp. Mol. Pathol.* **10**: 274–287. [Medline] [CrossRef]
 7. Franco, P. G., Silvestroff, E. F., Soto, E. F. and Pasquini, J. M. 2008. Thyroid hormones promote differentiation of oligodendrocyte progenitor cells and improve remyelination after cuprizone-induced demyelination. *Exp. Neurol.* **198**: 458–467. [Medline]
 8. Gump, W. S. 1969. Toxicological properties of hexachlorophene. *J. Soc. Cosmet. Chem.* **20**: 173–184.
 9. Hesse, A., Wagner, M., Held, J., Bruck, W., Salinas-Riester, G., Hao, Z., WSaisman, A. and Kuhlmann, T. 2010. In toxic demyelination oligodendroglia cell death occurs early and is FAS independent. *Neurobiol. Dis.* **37**: 362–369. [Medline] [CrossRef]
 10. Kanfer, J., Parenty, M., Goujet-Zalc, C., Monge, M., Bernier, L., Campagnoni, A. T., Dautigny, A. and Zalc, B. 1989. Development expression of myelin proteolipid, basic protein, and 2', 3'-cyclic nucleotide 3'-phosphodiesterase transcripts in different rat brain regions. *J. Mol. Neurosci.* **1**: 39–46. [Medline]
 11. Kanno, T., Kurotaki, T., Yamada, N., Yamashita, K., Wako, Y. and Tsuchitani, M. 2010. Activity of 2', 3'-cyclic nucleotide 3'-phosphodiesterase (CNPase) in spinal cord with spongy change induced by a single oral dose of aniline in rats. *Toxicol. Pathol.* **38**: 359–365. [Medline] [CrossRef]
 12. Kennedy, G. L. Jr., Dressler, I. A., Richter, W. R., Keplinger, M. L. and Calandra, J. C. 1976. Effect of hexachlorophene in the rat and their reversibility. *Toxicol. Appl. Pharmacol.* **35**: 137–145. [Medline] [CrossRef]
 13. Kimbrough, R. D. and Gaines, T. B. 1971. Hexachlorophene effects on the rat brain: study of high doses by light and electron microscopy. *Arch. Environ. Health* **23**: 114–118. [Medline]
 14. Kipp, M., Clarner, T. and Dang, J. 2009. The cuprizone animal model: new insights into an old story. *Acta Neuropathol.* **118**: 723–736. [Medline] [CrossRef]
 15. Kursula, P. 2001. The current status of structural studies on proteins of the myelin sheath (review). *Int. J. Mol. Med.* **8**: 475–479. [Medline]
 16. Lampert, P., O'Brien, J. and Garrett, R. 1973. Hexachlorophene encephalopathy. *Acta Neuropathol.* **23**: 326–333. [Medline] [CrossRef]
 17. Lee, J., Gravel, M., Gravel, M., Zhang, R., Thibault, P. and Braun, P. E. 2005. Process outgrowth in oligodendrocytes is mediated by CNP, a novel microtubule assembly myelin protein. *J. Cell Biol.* **170**: 661–673. [Medline] [CrossRef]
 18. Lindner, M., Fokuhl, J., Linsmeier, F., Trebst, C. and Stangle, M. 2009. Chronic toxic demyelination in the central nervous system leads to axonal damage despite remyelination. *Neurosci. Lett.* **453**: 120–125. [Medline] [CrossRef]
 19. Love, S. 1988. Cuprizone neurotoxicity in the rat: morphologic observations. *J. Neurol. Sci.* **84**: 223–237. [Medline] [CrossRef]
 20. Nakae, H. S., Dost, F. N. and Buhler, D. R. 1973. Studies on the toxicity of hexachlorophene in the rat. *Toxicol. Appl. Pharmacol.* **24**: 239–249. [Medline] [CrossRef]
 21. Nieminen, L. and Bjondahl, K. 1973. Effect of hexachlorophene on the rat brain during ontogenesis. *Food Cosmet. Toxicol.* **11**: 635–639. [Medline] [CrossRef]
 22. Towfighi, J. 1980. Hexachlorophene. pp. 440–455. In: *Experimental and Clinical Neurotoxicology* (Spencer, P. S. and Schauburg, H. H. eds.), Williams & Wilkins, Baltimore.
 23. Towfighi, J., Gonatas, N. K. and McCree, L. 1974. Hexachlorophene-induced changes in central and peripheral myelinated axons of developing and adult rats. *Lab. Invest.* **31**: 712–721. [Medline]
 24. Trapp, B. D., Bernier, L., Andrews, S. B. and Colman, D. R. 1988. Cellular and subcellular distribution of 2',3'-cyclic nucleotide 3'-phosphodiesterase and its mRNA in the rat central nervous system. *J. Neurochem.* **51**: 859–868. [Medline] [CrossRef]
 25. Yin, X., Peterson, J., Gravel, M., Braun, P. E. and Trapp, B. D. 1997. CNP overexpression induces aberrant oligodendrocyte membranes and inhibits MBP accumulation and myelin compaction. *J. Neurosci. Res.* **50**: 238–247. [Medline] [CrossRef]