

A Novel Approach for Diagnosing Diabetic Retinopathy in Fundus Images

¹Dhiravidachelvi, E. and ²V. Rajamani

¹Department of ECE, Satyabama University, Chennai, India

²Department of ECE, Veltech-Multi Tech Engineering College, Chennai, India

Article history

Received: 30-11-2013

Revised: 09-12-2013

Accepted: 12-08-2014

Corresponding Author:

Dhiravidachelvi, E.,

Department of ECE,

Satyabama University,

Chennai, India

Email: selvi.sathi@gmail.com

Abstract: In recent years the medical profession has seen an ever increasing demand for diagnosis and a permanent cure for illnesses caused by climatic-changes, unwholesome food and environmental pollution. Also the appearances of hitherto unknown viral diseases have caused eye diseases, which have prompted surgeons to monitor the health of the eyes. Potential new therapies that may help in preserving sight in the growing population of diabetic patients into the 21st Century. Early detection of diseases affecting the eyes reduces the risk of permanent damage. Some of the serious conditions which warrant early diagnosis are: Glaucoma, floaters, macula degradation and diabetic retinopathy. In the early stages, a choice of treatment options exist, which dwindles as the disease spreads. A visual inspection of the optic disc, macula and the blood vessels of the eye requires to be done routinely. Diabetic patients run the risk of damage to retinal vessels, which are referred to as diabetic retinopathy. This may further be classified as: Non-proliferative diabetic retinopathy and proliferative diabetic retinopathy. In scientific literatures, feature extraction method has been reported for diagnosis and classification. In this study a systematic Decide, Detect, Determine and Do approach for analyzing diabetic retinopathy images has been taken up. The proposed approach gives a clearer picture of the abnormality, its type (NPDR or PDR), its status (viz., mild, moderate or severe) and finally the appropriate treatment.

Keywords: Diabetic Retinopathy, PDR, NPDR, Macula, Optic Disc, Blood Vessels

Introduction

The two common retinal disorders that cause blindness are Diabetic Retinopathy (DR) and glaucoma. Prolonged hyperglycemia cause retinal lesions that could lead to blindness. Diabetic Retinopathy (DR) is the leading cause for blindness and vision defects in most developed countries. Early diagnosis paves the way for effective treatment that will inhibit the progression of the disease (Sánchez and Hornero, 2004). In the beginning since the afflictment is asymptomatic the diabetic patients do not undergo any eye examination until it is already too late for an optimal treatment. Routine retinal examinations for diabetic patients guarantee the early discovery of DR which will in turn drastically lower the incidence of blindness. However the occurrence of diabetes is pretty common and mass screening is time consuming and requires many skilled graders to

inspect the fundus photographs to explore for retinal lesions. A reliable method for quantitative and automated evaluation of the occurrence of lesions in fundus images that is a more expensive tool is required to support the partial number of specialists, which may lead to reduction in examination time. The raw diagnostic information collected from patients is often enormous and a manual analysis of such a large data is hardly feasible. In the medical context, the problem arises when the vast raw diagnostic information collected from patients has to be manually diagnosed to decide as to what stage or class the patient has to be assigned, initially. In most of the cases, the boundaries between the different abnormal classes are not straightforward which further add to the complexity.

These classification problems are specific in the case of ophthalmologic applications. In ophthalmology, a detailed eye fundus examination is highly preferred for diagnosing the abnormalities with the normal images

(Yagmur *et al.*, 2008), the problem for the specialist's lies in processing the huge data; only then can a meaningful diagnosis be made to reveal the abnormalities. An automated system can overcome this problem by automatically identifying and classifying all the images.

Diabetic Retinopathy

The damage to retinal vessels is known as diabetic retinopathy. Common types of diabetic retinopathy are Non-Proliferative Diabetic Retinopathy (NPDR) and Proliferative Diabetic Retinopathy (PDR). NPDR is normally known as background retinopathy and in the early stage of diabetic retinopathy blood and fluid leak within the retina. The leakage of blood and fluid may cause swelling of the retina to form deposits called exudates.

Classification of Diabetic Retinopathy by Fundus Images:

- Mild NPDR shows one dot or micro aneurysms in the first quadrant
- Moderate non-proliferative diabetic retinopathy showing extensive intra-retinal micro-vascular abnormalities, cotton wool spots, venous dilatation and hemorrhages
- Severe non-proliferative (pre-proliferative) diabetic retinopathy showing marked venous beading and irregularity; in addition, intra-retinal micro-vascular abnormalities (arrows), multiple cotton wool spots and multiple hemorrhages may be seen
- Proliferative diabetic retinopathy showing new peripheral vessels with feeding vessels from retinal artery, which cause severe affliction such as retinal detachment and regular loss of vision
- Diabetic retinopathy with clinically significant macular edema viz., exudative maculopathy showing hard exudates and hemorrhages lateral to macula. The above four phases can take place with any of the following abnormalities/diseases/aberrations

Microaneurysms

This is the first clinical abnormality to be noticed in the eye. They are clearly visible in isolation and in clusters astiny, dimred spots looking like tiny hemorrhages within the retina light perceptible area. The size ranges from 10-100 microns and is circular in shape. At this phase the disease is not eye threatening.

Haemorrhages

Occur in the deeper layer of the retina and are called blot hemorrhages because of their shapes.

Hard Exudates

These are one of the major characteristics of DR. They can change their size from tiny specks to large

patches with distinct edges. They impair vision by preventing the light from reaching the retina.

Soft Exudates

These are pale yellow in color and are repeatedly called cotton wool spots. They are round or oval in shape due to in formation of capillary occlusions which may lead to permanent damage to the retina.

Neovascularisation

These can be described as unusual growth of blood vessels of the eye including the retina and tantamount to vision loss.

Diabetic retinopathy is a common diabetic eye disease which damages the blood vessels of an eye. Fundus images are used for diagnosis by qualified clinicians to verify for any abnormalities or changes in the retina. Sekhar *et al.* (2008) They capture the image by using special devices called ophthalmoscopes. In each pixel of the fundus image they have three colors namely blue green and red. Walter (1999), each value quantized into 256 levels.

Related Works

Progressive damage to blood which causes retinal conditions are classified as: Normal, Non-Proliferative DR (NPDR), Proliferative DR (PDR) and advanced retinopathy. A computer based system to identified this (Priya and Aruna, 2011; Selvathi *et al.*, 2012). The earliest clinical manifestation of NPDR is the occurrence of micro aneurysms which are confined to the region of the posterior pole. Other attribute lesions of the non-proliferative stage are 'dot and blot' hemorrhages, hard (intra-retinal) exudates, macular edema, cotton-wool spots (soft exudates), Intra-Retinal Micro vascular Abnormalities (IRMA), venous beading and loops. The presence of these lesions determines the various degrees of severity includes NPDR (mild, moderate or severe) and PDR. The retina has a light receptive tissue at the back of the eye, which is necessary for a good vision. The patients with hypertensive retinopathy, as expected, suffer from hypertension. Fundus images are used for diagnosis by qualified clinicians to verify for any abnormalities or aberrations in the retina.

The significant manifestation of diabetic retinopathy and retinopathy of prematurity and cardiovascular risk are the changes in retinal vasculature, such as hemorrhages, angiogenesis and rise in vessel tortuosity, blockages and arteriolar venular diameter ratios (Basha and Prasad, 2008). The main cause of DR is an abnormal blood glucose level increase where in the vessel endothelium gets damaged and vessel permeability increases. Even though DR is not a curable disease using laser photocoagulation we can prevent major vision loss if detected in the early stages. Though, DR patients

recognize no symptoms in the early stages, it shows in the later stages, until visual loss develops (Lee *et al.*, 2001). As the treatment is insufficient we need an eye-fundus examination (Martin *et al.*, 2010).

Images taken at usual conditions are often noisy, lack in contrast and illumination is not uniform. Techniques to improve contrast and sharpness and reduce noise are therefore required as an aid for human interpretation of the fundus images are called image enhancement as a first step towards automatic analysis of the fundus images. Standard contrast stretch techniques a functional by (Sinthanayothin *et al.*, 1999; Osareh *et al.*, 2001; Goldbaum *et al.*, 1990); methods allowed to enrich certain features (e.g., only micro aneurysms), are applied in restoration techniques for images with very poor feature (e.g., due to cataracts) have been applied in (Cree *et al.*, 1999; Venkatesan *et al.*, 2012). The annual retinal examination and early detection of DR can considerably reduce the risk of visual loss in diabetic individuals (Rema and Pradeepa, 2007).

Proposed Approach

This approach consists of 4 functional steps. The first step is to read an image I , where I is a Retinal image and register the image for correcting the alignment of the Image. Once the correct output is received, the input image is preprocessed, by removing the noise using salt and pepper noise removal method and enhancing the image by pixel level (Sinthanayothin *et al.*, 1999). The second step is to calculate the SIFT feature point by matching the input image and the template images and then the histogram value of input image and the template image and calculate number of connected components of the input image and the template image by using morphological operations. This comparison output score decides whether the input image is a normal image or an abnormal image. Then, the image is checked to see whether it is affected by NPDR or PDR and to also determine the stage of the NPDR or PDR whether it is mild, moderate or severe. Once the stage of the NPDR or PDR is determined then the treatment is suggested and the proposed system is shown in Fig. 1.

Preprocessing

The preprocessing steps for the proposed approach are depicted in Fig. 2. Here, the first column shows the original image, second column shows the converted gray scale image, the third column shows the salt and pepper noise applied image and the fourth column shows the noise removed and enhanced image.

Decide

This study tackles the problem, by reading the input image I , preprocessing the image by removing the noise and registering the image and comparing them with the

template images TI_1 , TI_2 (Trained Normal (TI_1), Trained abnormal (TI_2)), decide whether it is a normal image NI or abnormal image ANI . If, it is an Abnormal Image (ANI), then the next step is detecting and determining the stage of the abnormality viz. $ANIMI$, $ANIMO$, ANS (abnormal mild, abnormal moderate, abnormal severe) by counting and analyzing the number of tiny dots or exudates with their size. By seeing the image or by extracting the damages of the image, it can't be concluded whether the extracted portion is a tiny dot or exudates or hemorrhage. One way of finding the number of tiny dots and other damages in the image is by getting the number of connected components and calculating the size and the position of the dots. The damages or other irrelevant part of the images can be extracted by different threshold values. Just by comparing the histogram to justify whether the two images are equal or not is not very accurate. In order to produce more accuracy in the proposed system, the histogram value, the sift key points and connected components of the input image and the template image are compared to decide whether the input images is normal or abnormal.

Where, HI and HTI stand for the Histogram of I and TI respectively. For a given image I_i , the color histogram HI is a compact summary of the image. (A Template of images can be queried to and that image is already trained Normal Image or Abnormal Image similar kind of image to I and can return the image TI with the most similar color histogram HTI). Typically color histograms are compared using the sum of squared differences (L2-distance) or the sum of absolute value of differences (L1-distance). The most similar image to I would be the image TI Minimizing. If the $d(I, TI)$ gives very less value then both the input image I and the template image TI are the same. Are shown in Fig. 3.

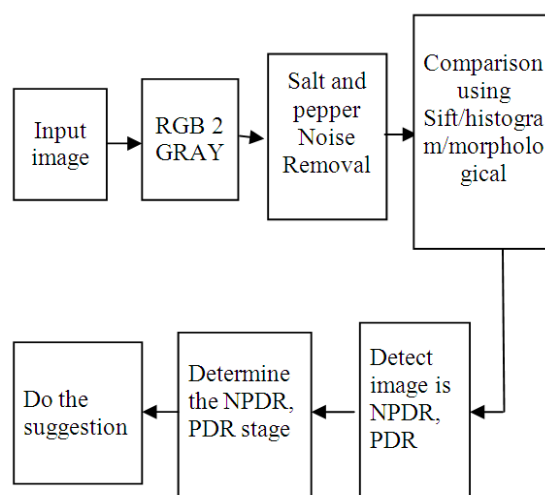


Fig. 1. Architecture of the proposed system

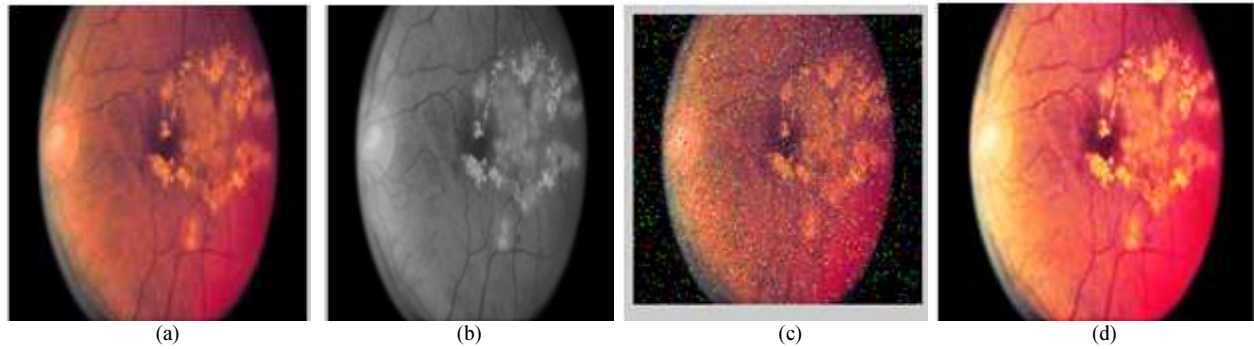


Fig. 2. Preprocessing for the proposed approach (a) Original image, (b) Gray scale image, (c) Noise applied image, (d) Noise removed image

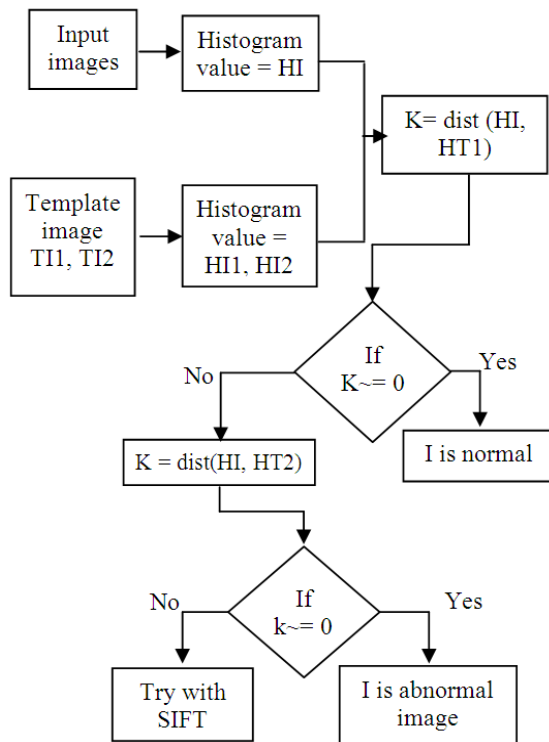


Fig. 3. Histogram method

Input image I and the template image T11, T12 histogram values are calculated. HI, is the compact summary of the input Image and HT1, HT2 are the histogram value of the Template images. If there is no difference between the histogram of the input image I and the template image T11 and the input image it is decided as normal image or else it is decided as abnormal image which is given in detail in Fig. 4. Incase both conditions are not satisfied between the input image and the template images then comparison can be made by another methodology like SIFT comparison.

According to the number of matched points it can be decided whether the input image is normal or abnormal.

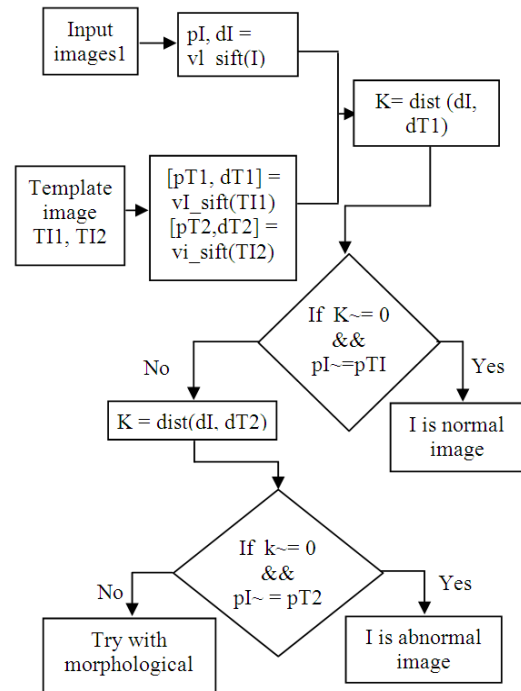


Fig. 4. SIFT method

The input image I and the template image T11, are compared and it gives two sets of values pI, dI for I and pT1, dT1, pT2, dT2 for the template images respectively. If, the difference between distances values dI and dT1 are merely equal to zero and the number matching points pI and pT1 are merely the same, the image is normal. Incase both condition are not satisfied between the input image and the template images then a comparison can be made by using another methodology like morphological comparison Fig. 5.

The input image I and the template images T11, T12 are converted into binary images for morphological operations and the number of objects (connected components) num, num1 and num2 are calculated respectively. The object labels are in L, L1, L2 and both nums, L is compared with the num1, L1 and num2 is compared with L2 to ascertain if

they are matching L2. If num is merely equal to num1 it means that the input image is a normal image or else it is decided as an abnormal image.

Detect and Determination

After deciding whether the input image I is an abnormal image ANI, then the detect and Determination step is employed to detect the abnormality as NPDR or PDR and the stages of the NPDR and PDR as mild, moderate or severe respectively. In the determination step, the number of connected components in the image is retrieved and the number is used to conform if it is NPDR or PDR. Even though the image is detected as NPDR or PDR, it is mandatory to determine the stage of NPDR/PDR. So that the 'DO' step can propose an effective treatment suggestion for diabetic retinopathies. For accurate determination, the input image is segmented using OTSU method with different threshold values and the tiny dots, the exudates and the hemorrhages are extracted. If the tiny dots the hemorrhages and the, exudates are visible very lightly on the surface of the retina images nearer to the macula they are considered as affected by Mild NPDR disease. If the number of hemorrhages are visible but little and the size of the exudates are small in appearance on the surface of the retinopathy images nearer to the macula images then the NPDR stage is Moderate, where the area and the circumference of the extracted portions is taken into account. If the number of tiny dots and its area are less they are classified as mild and if the number of tiny dots are more and the area bigger than the mild they are moderate and if number of dots are more and exudates are also more, then they are classified as severe.

The three Score values derived from (i) SIFT feature, (ii) Histogram value, (iii) connected components have been used with success for deciding whether the case is normal or abnormal. The abnormal images are further analyzed to assess the stages of the NPDR. Finally, the "do" part indicates the treatments and the recommended diets.

Do

These are some of the methods and treatments suggested, for using or preventing vision loss. The diabetic retinopathy stages are so disparate that, the treatment varies

for each stage. Table 1 shows a clear idea and provides suggestions for curing or preventing vision loss.

Results

The pseudo code is written in MATLAB and the output is compared with the existing system. In the experiments conducted 100 images were used as input image. According to the proposed approach (4D) the classified output is given and the test performance of the proposed approach is evaluated by comparing the true positive rate of detection as well as the false positive rate of detection by employing the 4D approach against the existing diagnostic systems.

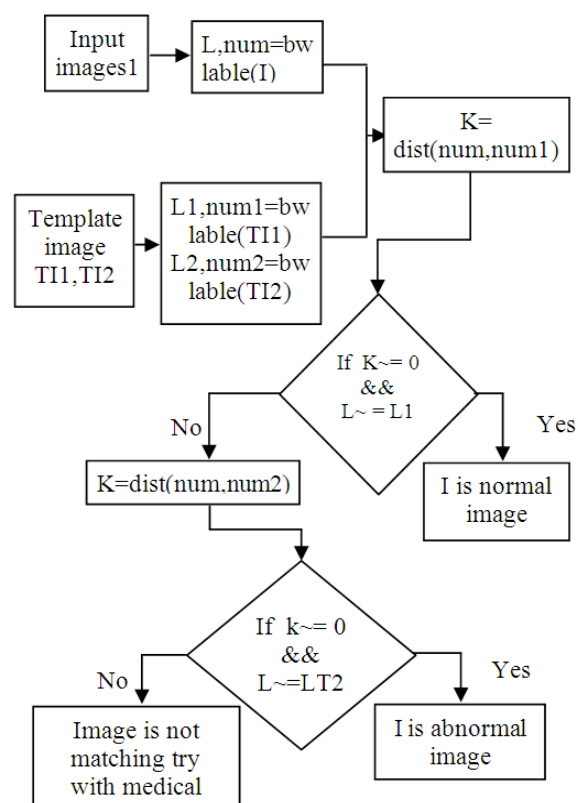


Fig. 5. Comparing input image with template images using morphological method

Table 1. Suggestions and treatment for diabetic retinopathy disease in a stage wise implementation

Normal: Treatment-1:	Take fruits like papaya often, also Fish, egg, nuts and peas, are good vegetables and greens could be consumed every day.
NPDR-Mild: Treatment-2:	Annual check-up needed. Control diabetes by taking more wheat products; reduce intake of rice. Sugar free food is recommended.
NPDR-Moderate Treatment-3:	Checking-up twice a month by an ophthalmologist is necessary. Serious diet control is recommended; take recommended medicine regularly.
NPDR-Severe Treatment-4:	They require frequent follow-ups as they are at high risk to progress to PDR. To keep the diabetes under control, Ragi with milk, sugar free food, wheat products and soul food are recommended.
PDR-Severe Treatment-5:	A test called Fluoresce in angiography should be taken. There is a chance for vision loss. However dieting and regular Treatment of diabetes may help.

A hundred (100) test images were taken as a data bank. Experimentation was done using the existing system and the proposed approach. The existing system shows 9 images as being in the normal stage, 36 in the mild stage, 20 in the moderate stage, 18 in the severe in NPDR and 17 in the PDR stages. However, the proposed approach classifies 13 images as normal, 24 images as mild and 30 images as moderate, 22 images as severe NPDR and 11 images in the PDR stage are shown in Table 2 and Fig. 6. The disparity may be due to the fact that mild and moderate images cannot be classified very easily by extracting color features. In the proposed approach, classification is done using four parameters viz., the color, histogram, number and the size of the abnormalities. The accuracy of the existing method vs. proposed approach is given by calculating the ratios: True Positive Rate, False Positive Rate (TPR, FPR) where:

$$\left. \begin{aligned} \text{TruePositiveRate} &= \frac{\text{CorrectlyDetectedimageDiseasestages}}{\text{TotalNumberofimage}} \\ \text{FalsePositiveRate} &= \frac{\text{Wrongdetectionofimagediseasestages}}{\text{Totalimagedetected}} \end{aligned} \right\} \quad (1)$$

The classification of the real database of images into various types and the computed ratios TPR and FPR for the existing and the proposed approaches are shown in Table 3 and Fig. 7. The data base images used were the ones that were 'truly' classified in hospitals by specialist doctors. In the database, there were 'true' 20 normal, 20 NPDR-mild, 12 NPDR-moderate, 20 NPDR-severe and 28 PDR images present. In the experiment, the existing system detected and classified, 17 out of 20 as normal, 15 out of 20, as the mild NPDR, 8 out of 12, as moderate NPDR, 18 out of 20 as severe NPDR and 20 out of 28, images as under PDR. The proposed 4D system however, classified 20 out of 20 in normal, 19 out of 20 in mild, 10 out of 12 in moderate, 19 out of 20 in severe and 25 out of 28 in PDR.

From Table 4 and Fig. 9, the proposed 4D system's performance is found to be better than that of the existing system as far as the true positive rate is concerned. Also, the False Detection Rate (FDR) for the proposed 4D system is substantially lower. The true positive detection for the 4D approach is 93% as against 78% of the existing procedures. Similarly, the false detection rate is lower at 7% rather than 22% for the existing schemes.

The percentage of the TPR and FPR is calculated by the Equation 1 given above. Table 3 gives the image category wise classified results and Table 4 gives the comparison of the overall percentage of the TRP and FPR of the trained data base by the proposed approach and the Existing approach.

The corresponding graphical representation gives the efficiency of the proposed system compared with that of the existing system. The proposed system 4D approach gives 93% accurate classification for the entire category of

DR images as well as combined. In this study the TPR and the FPR are accurate because of the compared template images collected in real time (Hospital Images from RR Eye Research Institute, Chennai and Benchmark Data base Images). Figure 8 gives detailed information about the number of TPR and FPR for normal, NPDR, NPDR, NPDR and PDR individually for the Existing system as well as for the proposed system.

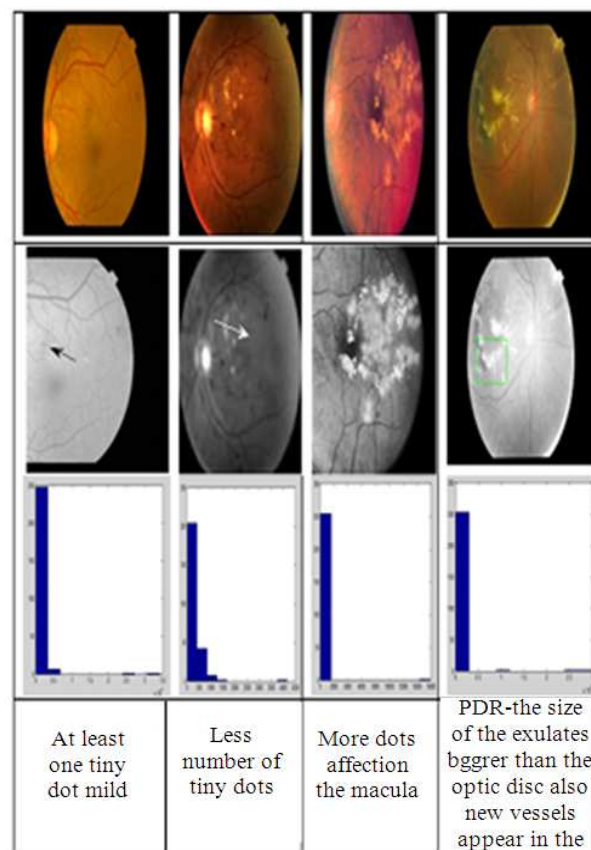


Fig. 6. NPDR, PDR detection results

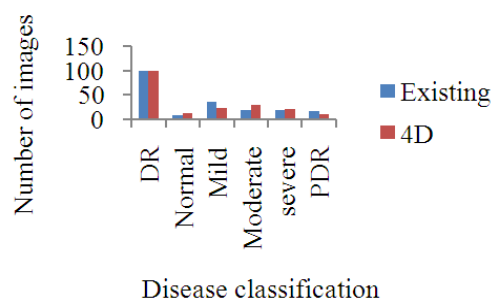


Fig. 7. Existing Vs. 4D-NPDR, PDR detection

Table 2. Performance of the proposed approach and the existing diagnostic system

Method	DR	Normal	Mild	Moderate	Severe	PDR
Existing	100	9	36	20	18	17
4D	100	13	24	30	22	11

Table 3. Existing Vs. 4 D-TPR, FPR comparison

Classification	Trained classified images	Existing TPR	Proposed TPR	Existing FPR	Proposed FPR
Normal	20	17	20	3	0
NPRD-Mild	20	15	19	5	1
NPDR-Moderate	12	8	10	4	2
NPDR-Severe	20	28	19	2	1
PDR	28	20	25	8	3

Table 4. Percentage of performance

Method	TPR (%)	FPR(%)
Existing system	78	22
Proposed system	93	7

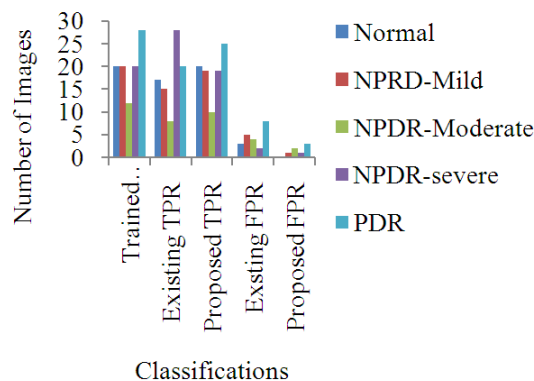


Fig. 8. Existing Vs. 4 D-TPR, FPR comparison

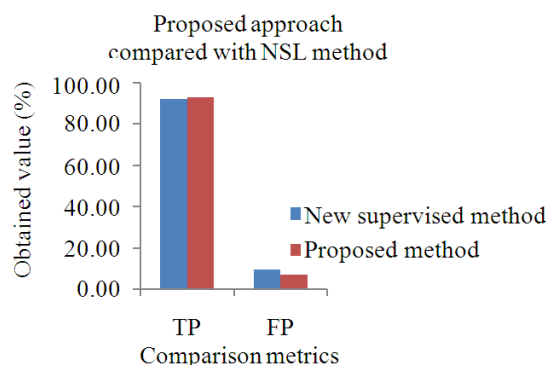


Fig. 9. 4D Vs. New supervisor learning-TPR, FPR comparison

From Fig. 8, it is concluded that from the total number of trained classified images of 100, the total number of images the proposed system classifies accurately are the number of normal images in trained folder is 20, the number of normal image classified is 20; the number of NPDR mild images in trained folder is 20, the number of NPDR-Mild images classified is 19; the number of NPDR Moderate images in trained folder is 12, the number of NPDR-Moderate images classified is 10, the number of NPDR Severe in trained folder is 20, the number of NPDR-Severe images classified is 19; and, finally, the number of PDR images in trained folder is 28, the number of NPDR-Mild images classified is 25. Whereas the

number of images the Existing system classifies are the number of normal images in trained folder is 20, the number of normal image classified is 17, the number of NPDR mild images in trained folder is 20, the number of NPDR-Mild images classified is 15, the number of NPDR Moderate images in trained folder is 12, the number of NPDR-Moderate images classified is 8, the number of NPDR severe in trained folder is 20, the number of NPDR-severe images classified is 18 and finally the number of PDR images in trained folder is 28, the number of NPDR-Mild images classified is 20. By comparing the accuracy between the approaches as depicted in Table 3, the proposed approach gives more accuracy than the existing approach.

Also the proposed approach is compared with the existing approach named new supervised method and proves its efficiency in Fig. 9.

From the Fig. 9, it is clear that the proposed approach is improved the efficiency of the classification accuracy in diabetic retinopathy images. The True positive rate of the proposed approach is increased than the new supervised approach. Since the proposed approach introduced in this study is more efficient than the existing approaches.

Conclusion

The proposed approach of this study gives more accuracy in analyzing and diagnosing the disease, showing the exact stage of the disease and suggesting good methods for treatment. The previous papers classify the number of retinopathy images as normal or abnormal and the stages of NPDR and PDR% in a database, without detecting the disease and specifying the direct classification. While the classification can be done by any kind of data mining methodology, detecting the disease from an image automatically and classifying them will provide better accuracy. In the proposed approach the performance accuracy is 93%, as suggested by the experiments performed using the data base received from RR Eye Research Institute, Chennai.

The size and color of micro aneurysm is very similar to the blood vessels. Its size is variable and often very small so it can be easily confused due to the noise present in the image. These changes can be accurately detected because of our perfect Template images. In human retina, there is a pigmentation variation and the texture, size and location of human features vary from person to person. More false positives occur when the blood vessels are

overlapping or adjacent with micro aneurysms. So there is a need for an effective automated micro aneurysm detection method so that diabetic retinopathy can be treated at an early stage and blindness due to diabetic retinopathy can be prevented.

In this study, some existing methods have been reviewed to give a comprehensive view of the field. The NPDR, PDR classification is proposed for accuracy and a comparison of the performance is made using bench mark databases. For upcoming research, the data can be augmented to give more confidence in the results. The proposed DR grading method validity can be further established by performing cross-validation based on the opinion of experts.

Acknowledgement

This study was supported by R.R.EYE Research Institute, Vadapalani, Chennai and Tamilnadu, India.

Author's Contributions

All authors equally contributed in this work.

Ethics

This article is original and contains unpublished material. The corresponding author confirms that all of the other authors have read and approved the manuscript and no ethical issues involved.

References

- Basha, S.S. and K.S. Prasad, 2008. Automatic detection of hard exudates in diabetic retinopathy using morphological segmentation and fuzzy logic. *Int. J. Comput. Sci. Netw. Security*, 8: 211-218.
- Cree, M.J., J.A. Olson, K.C. McHardy, P.F. Sharp and J.V. Forrester, 1999. The preprocessing of retinal images for the detection of fluorescein leakage. *Phys. Med. Biol.*, 44: 29-308.
 DOI: 10.1088/0031-9155/44/1/021
- Goldbaum, M.H., N.P. Katz, S. Chaudhuri, M. Nelson and P. Kube, 1990. Digital image processing for ocular fundus images. *Ophthalmol. Clin. North Am.*
- Lee, S.J., C.A. McCarty, H.R. Taylor and J.E. Keefe, 2001. Costs of mobile screening for diabetic retinopathy: A practical framework for rural populations. *Aus. J. Rural Health*, 8: 186-192.
 DOI: 10.1046/j.1038-5282.2001.00356.x
- Martin, D., A. Aquino, M.E. Gegundez-Arias and J.M. Bravo, 2010. A new supervised method for blood vessel segmentation in retinal images by using gray-level and moment invariants-based features. *IEEE Trans. Med. Imag.*, 30: 146-158.
 DOI: 10.1109/TMI.2010.2064333
- Osareh, A., M. Mirmehdi, B. Thomas and R. Markham, 2001. Automatic recognition of exudative maculopathy using fuzzy c-means clustering and neural networks. *Proceedings of the Medical Image Understanding Analysis Conference, (UAC' 01)*, pp: 49-52.
- Priya, R. and P. Aruna, 2011. Review of automated diagnosis of diabetic retinopathy using the support vector machine. *Int. J. Applied Eng. Res.*, 1: 844-863.
- Rema, M. and R. Pradeepa, 2007. Diabetic retinopathy: An Indian perspective. *Ind. J. Med. Res.*, 125: 297-310.
- Sánchez, C.I. and R. Hornero, 2004. Retinal image analysis to detect and quantify lesions associated with diabetic retinopathy. *Proceedings of the 26th Annual International Conference of the IEEE Engineering in Medicine and Biology Society*, Sept. 1-5, IEEE Xplore Press, San Francisco, CA, pp: 1624-1627. DOI: 10.1109/IEMBS.2004.1403492
- Sekhar, S., W. Al-Nuaimy and A.K. Nandi, 2008. Automated localisation of retinal optic disk using hough transform. *Proceedings of the 5th IEEE International Symposium on Biomedical Imaging: From Nano to Macro*, May 14-17, IEEE Xplore Press, Paris, pp: 1577-1580.
 DOI: 10.1109/ISBI.2008.4541312
- Selvathi, D., N.B. Prakash and N. Balagopal, 2012. Automated detection of diabetic retinopathy for early diagnosis using feature extraction and support vector machine.
- Sinthanayothin, C., J.F. Boyce, H.L. Cook and T.H. Williamson, 1999. Automated localisation of the optic disc, fovea and retinal blood vessels from digital colour fundus images. *Br. J. Ophthalmol.*, 83: 902-910. DOI: 10.1136/bjo.83.8.902
- Venkatesan, R., P. Chandakkar and B. Li, 2012. Classification of diabetic retinopathy images using multi-class multiple-instance learning based on color correlogram features. *Proceedings of the Annual International Conference of the IEEE Engineering in Medicine and Biology Society*, Aug. 28-Sept. 1, IEEE Xplore Press, San Diego, CA, pp: 1462-1465. DOI: 10.1109/EMBC.2012.6346216
- Walter, T., 1999. Détection de pathologies rétinienues à partir d'images couleur du fond d'oeil, rapport d'avancement de these. *Ecole Phys. Med. Biol.*, 44: 29-308.
- Yagmur, F.D., B. Karlık and A. Okatan, 2008. Automatic recognition of retinopathy diseases by using wavelet based neural network. *Proceedings of the 1st International Conference on the Applications of Digital Information and Web Technologies*, Aug. 4-6, IEEE Xplore Press, Ostrava, pp: 454-457.
 DOI: 10.1109/ICADIWT.2008.4664391