

REVIEW

Insights and clinical questions about the active surveillance of low-risk papillary thyroid microcarcinomas

Yasuhiro Ito, Hitomi Oda and Akira Miyauchi

Department of Surgery, Kuma Hospital, Kobe 650-0011, Japan

Abstract. Over 20 years ago, two Japanese institutions initiated an active surveillance policy for papillary microcarcinomas (PMCs) without high-risk features (such as clinical lymph node and distant metastases) and suspected trachea or recurrent laryngeal nerve invasion. Since the most recent American Thyroid Association (ATA) guidelines adopt active surveillance as a therapy option for low-risk PMCs, the number of institutions worldwide carrying out this policy can be expected to increase. However, before adopting an active surveillance strategy, some important clinical questions must be considered. In this review, conceivable clinical questions with our answers based on the present accumulation of low-risk PMC surveillance data are presented.

Key words: Papillary microcarcinoma, Thyroid, Low-risk, Active surveillance

Background of a Trial of Active Surveillance of Low-risk PMC

It is well known that a high incidence of papillary microcarcinomas (PMCs) is detected during autopsies as latent PMCs. Latent PMCs measuring 3–10 mm—the size detectable by ultrasound—were incidentally detected in 0.5–5.2% of autopsy studies [1]. On the other hand, Takebe *et al.* conducted a screening study for thyroid cancer using ultrasound examinations and ultrasound-guided fine needle aspiration biopsies (FNABs) on subjects who visited his center for breast cancer screening, and they reported in 1994 that a thyroid carcinoma was detected in 3.5% of otherwise healthy adult women [2]. They also reported that 85% of these measured ≤ 15 mm. The incidence presented by Takebe *et al.* was more than 1,000 times higher than that of clinical thyroid carcinomas in that era, and was not discrepant with the findings obtained in autopsy studies.

History of the Active Surveillance of PMCs

Based on the findings of PMCs by autopsies, ultra-

sound and FNABs, Akira Miyauchi (Kuma Hospital, Kobe, Japan) initiated an active surveillance policy, which means that PMCs are followed by ultrasound once or twice per year instead of an immediate surgery, for low-risk cases with the approval of other surgeons in 1993. He hypothesized that most PMCs do not grow or grow very slowly, and that active surveillance is the only method to predict their activity. He also suspected that a rescue surgery performed after the detection of signs of PMC progression (such as size enlargement and the novel appearance of node metastases) is not too late and would not influence patients' prognoses. In 1995, Cancer Institute Hospital (Tokyo, Japan) also initiated an active surveillance program for low-risk PMCs, and these two institutions have published promising data using large patient series [3-9].

Recent Increase in the Incidence of Thyroid Carcinoma but not in its Mortality

Studies conducted in the United States and Korea demonstrated that the incidence of thyroid carcinoma increased greatly (by 2.4-fold between 1973 and 2002 and by 2.9-fold between 1975 and 2009 in the United States and by 15-fold between 1993 and 2011 in Korea), mainly because of the increase of small papillary carcinomas, including PMCs, detectable by imaging modalities such as ultrasound [10-12]. Importantly, these

Submitted Nov. 8, 2015; Accepted Nov. 12, 2015 as EJ15-0637

Released online in J-STAGE as advance publication Dec. 2, 2015

Correspondence to: Yasuhiro Ito, Department of Surgery, Kuma Hospital, 8-2-35, Shimoyamate-dori, Chuo-ku, Kobe 650-0011, Japan. E-mail: ito01@kuma-h.or.jp

©The Japan Endocrine Society

reports also showed that the mortality rate for thyroid carcinoma did not change during the same periods, indicating the possibility that harmless small carcinomas were detected and treated more frequently.

Contraindications for the Active Surveillance of PMCs

At our institution, the contraindications for the active surveillance of PMCs were decided as follows when we started our active surveillance policy in 1993 [3]: (1) Clinical node-positive (N+), (2) Clinical distant metastasis-positive (M+) (very rare), (3) Clinical sign of extrathyroid invasion, that is, vocal cord paralysis (Ex2), (4) high-grade malignancy such as tall cell variant suspected on cytology, and (5) the presence of progression signs (*i.e.*, size enlargement and/or novel appearance of lymph node metastases) during active surveillance. We cautiously include tumors located on the course of the recurrent laryngeal nerve (RN) and/or attaching to the trachea (TR) (described later) as a contraindication. Multiplicity of the tumors and a family history of differentiated thyroid carcinoma were not included in the contraindications. These contraindications are also used at the present time at our institution.

How Should PMC Patients be Advised about Active Surveillance?

In the past, we proposed two therapy options to patients with low-risk PMCs: active surveillance, and immediate surgery with a full explanation of the background issues described above. We provided the choice of these options to the patients and asked them to select one. Giving the patients this choice was based on the lack of adequate evidence that active surveillance was superior to immediate surgery at that time. However, at present, we recommend active surveillance as the first line of therapy for low-risk PMCs (see the Clinical questions described later).

How Should Active Surveillance of Low-risk PMC Patients be Conducted without Surgery?

PMC patients with none of the exclusion criteria described above are followed-up by ultrasound for 6 months after the diagnosis and at least once per year

thereafter to determine whether novel lymph node metastases or size enlargement are present. If suspicious nodes are detected (especially in the lateral compartment), we perform an FNAB and thyroglobulin measurement of the washout of the needles used for the FNAB [13] to diagnose whether the nodes are metastatic or reactive. A rescue surgery is performed when the tumor size has enlarged by ≥ 3 mm or lymph node metastases are diagnosed. Otherwise, the active surveillance is continued. For tumors with size enlargement only, a rescue surgery might be delayed until the tumor size has exceeded 13 mm.

Successful Data of Active Surveillance of Low-risk PMC Patients

The first report of active surveillance of low-risk PMCs of 162 patients was published in 2003 from Kuma Hospital [3]. That study demonstrated that, in each year, the tumor size of more than 70% of the PMC cases did not change or even decreased compared to the size at the initiation of active surveillance. The second report from Kuma Hospital was published in 2010, increasing the number of enrolled patients to 340, and that study obtained similar results [5]. In the most recent study of 1,235 patients from our institution in 2014, only 8% of the PMC patients showed size enlargement by 3 mm compared to the initiation of active surveillance, and only 3.8% of the patients showed a novel appearance of lymph node metastases at 10 years of observation [6].

In 2010, a study conducted at the Cancer Institute Hospital demonstrated that of 300 lesions of low-risk PMCs, only 7% showed enlargement and of 230 patients, only 1% showed novel lymph node metastases during active surveillance [4]. This study also showed that 6% of 415 lesions increased in size [4]. Studies from the two institutions clearly showed that, during active surveillance, (1) the incidence of tumor-size increase and that of the novel appearance of nodal metastasis in low-risk PMCs are low, and (2) none of their patients enrolled in active surveillance showed distant metastasis or died of thyroid carcinoma. These studies also showed that a rescue surgery after the detection of progression signs was not too late and that no life-threatening recurrence was detected thereafter. These are important points for adopting an active surveillance policy as a therapy option for low-risk PMCs.

Clinical Questions for an Active Surveillance Policy for Low-risk PMCs

It is simple to perform active surveillance for low-risk PMCs, but in practice, several clinical questions arise and physicians might be unsure regarding the correct treatment options. Although not all of such questions have been solved, the present accumulation of data addresses some of them. Common clinical questions and their answers are described below.

(1) How should we judge whether tumors are at risk for TR and RN invasion?

Tumors without the contraindications described above can be strong candidates for active surveillance. However, in some cases it is difficult to determine whether the tumor is at risk of invading the TR or RN. We recently showed that, in PMCs ≥ 7 mm, the angle formed by the TR and the tumor surface is useful for this evaluation (Fig. 1, Table 1). If the angle between the TR and the tumor surface is acute, the tumor can be a candidate for active surveillance. Among PMCs < 7 mm, no significant TR invasion was observed in our series [9], and thus PMCs < 7 mm might be appropriate

for active surveillance.

Regarding RN invasion, none of the PMCs < 7 mm in our series showed significant RN invasion. In the PMCs ≥ 7 mm, it is important to determine whether a normal rim is present between the tumor and the course of RN before the patient is enrolled in active surveillance (Table 2) [9]. If a normal rim is present between the tumor and the course of RN, it could be a candidate for active surveillance. However, we should be careful to observe a PMC with a risk of RN invasion because if it invades the RN during the surveillance, the quality of life of the patient could be significantly damaged.

For these evaluations, a computed tomography (CT) scan is easier than ultrasound. It is thus better to use not only ultrasound but also a CT scan to decide whether such PMCs can be under active surveillance and to follow them if the ultrasound image is unclear because of the shadowing by calcification.

(2) Is the diagnosis on cytology necessary for low-risk PMC?

The most recent ATA guidelines state that thyroid nodules ≤ 1 cm do not need to be diagnosed based on cytology unless other evidence of aggressive features

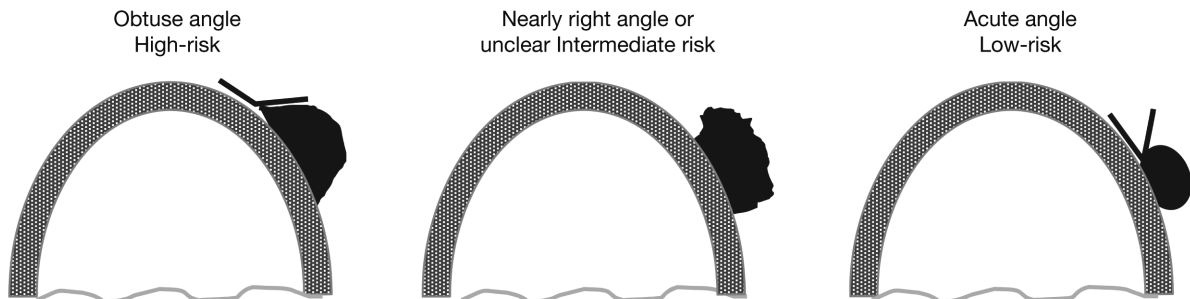


Fig. 1 Schema of typical examples of PMCs presenting a high, intermediate, and low risk for TR invasion

Table 1 Relationship between preoperative and postoperative findings of TR invasion in the subset of PMCs ≥ 7 mm

Surgical and pathological TR invasion			
Risk grade/TR invasion	No or minimal	Significant	Total
High-risk	39 (76%)	12 (24%)	51
Intermediate risk	78 (100%)	0	78
Low-risk	208 (100%)	0	208
No risk	537 (100%)	0	537
Total	862	12	874

No or minimal, no invasion or invasion to adventitia dissection only; Significant, laminate dissection or dissection of tracheal cartilage and mucosa. $P = 0.0000$ (high vs. intermediate). $P = 0.0001$ (intermediate vs. low).

Table 2 Relationship between preoperative and postoperative findings of RN invasion in the subset of PMCs ≥ 7 mm

Surgical and pathological RN invasion			
Risk grade/RN invasion	No or minimal	Significant	Total
High-risk	89 (91%)	9 (9%)	98
Low-risk	28 (100%)	0	28
No risk	748 (100%)	0	748
Total	865	9	874

No or minimal, No invasion or minimal invasion requiring RN shaving; Significant, Invasion requiring partial layer dissection or complete dissection of RN with reconstruction. $P = 0.0625$ (high vs. low).

such as lymph node metastases, distant metastases and apparent extrathyroid extension is obtained [14]. This indicates that a cytological diagnosis of low-risk PMC is not required. This may be similar to the active surveillance policy for low-risk PMCs, but whether this strategy is the best may vary from country to country. In Japan, favorable data and clear evidence of the success of active surveillance of low-risk PMCs have accumulated, indicating that it is better to disclose a cytological diagnosis of PMC to patients and their prognoses by active surveillance. Moreover, this disclosure gives patients the incentive to regularly visit the assigned clinic for active surveillance and prevents the loss of patients to follow-up.

(3) Are there any predictors of the growth of low-risk PMC?

There are some molecular markers that predict the prognosis of papillary thyroid carcinomas, including *BRAF* mutation and *TERT* mutation [15, 16]. Although *BRAF* mutation is well known as a prognostic factor of clinical papillary carcinoma, this has not been demonstrated in Japan except for high-risk patients [17, 18]. Therefore, although *BRAF* mutation can be technically investigated using FNAB specimens, it is not useful to predict PMC growth activity or for the decision regarding whether immediate surgery is necessary.

It was recently reported that PMCs with a rich blood supply or a lack of strong calcification on ultrasound have stronger growth activity [8]. However, in that study's series, no patients showed life-threatening tumor progression during the active surveillance or after the rescue surgery. These findings indicate that immediate surgical treatment was not necessary even for the patients in their series classified as having stronger growth activity. Moreover, the blood supply findings on ultrasound might depend on the examiners, and observer variation may occur, especially when the ultrasound is not performed by the same technician.

In our most recent report, young age (≤ 40 years) was an independent predictor of PMC progression [6]. It is quite interesting that, in clinical thyroid carcinoma, old age is a very strong prognostic factor of carcinoma recurrence and carcinoma death. In the low-risk PMC group, we obtained the controversial finding that old patients are very appropriate candidates for active surveillance. In the low-risk young patients too, no life-threatening rapid growth during active surveillance and no significant recurrence after the rescue

surgery were detected.

Therefore, no useful predictors of rapid and life-threatening growth requiring immediate surgery have been found to date, and at this time, all low-risk PMCs can be candidates for active surveillance as the first-line treatment option.

(4) Is thyroid-stimulating hormone (TSH) suppression useful for active surveillance of low-risk PMCs?

Thyroid stimulation hormone (TSH) suppression is a common strategy to avoid the recurrence or progression of a recurred lesion of differentiated thyroid carcinoma, including papillary carcinoma. In Japan, however, no studies of large numbers of patients have been conducted to examine the efficacy of TSH suppression for thyroid carcinomas. Sugitani *et al.* performed a randomized study and obtained negative results regarding the efficacy of TSH suppression for carcinoma recurrence and death [19]. They also showed that the TSH level during the active surveillance of low-risk PMCs was not related its progression of the PMCs [7]. However, we performed TSH suppression (or set the TSH level at low normal) during active surveillance especially for young patients, and we found that although the number of enrolled patients was small, none of the PMCs under TSH suppression progressed [6]. Therefore, active surveillance under TSH suppression may be effective to some extent, especially for PMCs in young patients, but further studies are needed to draw any conclusions.

(5) How should we manage low-risk PMCs in young females who may want to become pregnant in the future?

The desire to have children is a very important issue for young females with low-risk PMCs. If a high incidence of PMC growth during pregnancy requiring surgery after delivery is likely, prophylactic surgery could be better than active surveillance for young females. Shindo *et al.* reported that 49.4% of PMCs showed size enlargement during pregnancy [20]. Their study was from our institution, but we thereafter found that there was a strong selection bias in their series. We therefore re-checked all the cases of all of the low-risk PMC patients under active surveillance aged ≤ 40 years, and we found that the PMCs only of 8% (four of 51 patients) showed size enlargement by ≥ 3 mm between before the pregnancy and after the delivery. Only two of those four patients underwent

surgery after delivery (the remaining two continued under active surveillance) because of the PMC's enlargement during the pregnancy [21]. We can thus conclude that the possibility of a pregnancy is not a reason for declining the active surveillance of a low-risk PMC. Even though a PMC may increase in size during a pregnancy, a rescue surgery after the delivery can solve the problem.

(6) Which should be the first-line therapy for low-risk PMC, active surveillance or surgical treatment?

This is the fundamental question; *i.e.*, which of the two therapy options, active surveillance and immediate surgery, is better. Some endocrinologists and surgeons may think that surgery is still the first-line choice of therapy, because the surgical procedure is easy and also cost-effective for hospitals. However, Oda *et al.* demonstrated that, although surgery for low-risk PMC is easy, permanent vocal cord paralysis and permanent hypoparathyroidism occurred in 0.2% and 1.6% of patients, respectively [22]. These data are from our hospitals, where surgery is performed by skilled thyroid surgeons. If non-experts perform the surgery for these patients, the incidence of severe adverse events could be much higher. If active surveillance is chosen as the first-line option, such adverse events could be avoided except among the patients who later undergo rescue surgery; however, the incidence of rescue surgery is low according to previous studies.

We can therefore conclude that active surveillance should be the first line of therapy for low-risk PMCs and that rescue surgery can be performed after the detection of progression signs.

(7) Are other therapeutic approaches beneficial for patients with PMCs?

Other than active surveillance and surgery, there are some therapy options: percutaneous ethanol injection therapy (PEIT) [23] and radiofrequency ablation (RFA) [24]. However, both of these options are useful only for local control, and node metastases and small carcinoma lesions cannot be treated with PEIT or RFA. Since most PMCs are indolent and do not grow, it would be meaningless to perform unnecessary therapy. If the biological characteristics of PMC could be accurately predicted (*e.g.*, extremely rapid growth and anaplastic transformation in the future), these options may be useful to some extent to ablate the problematic lesions. However, to date, it is impossible to accurately predict the growth activity of PMCs. At least at present, active surveillance as the first line and surgical treatment as the second line of therapy for progressive PMC cases should thus be considered more appropriate than other local control therapies.

Summary

Although the strategy of active surveillance is simple, various clinical questions about active surveillance arise at its initiation and along the way. Fortunately, the progression of studies has provided answers for some, although not all, of these questions. At present, no data have been reported suggesting that the active surveillance of low-risk PMCs as the first line of therapy is not appropriate. If novel clinical issues arise concerning active surveillance, further studies will be necessary to address the issues by accumulating evidence.

References

1. Ito Y, Miyauchi A (2007) A therapeutic strategy for incidentally detected papillary microcarcinoma of the thyroid. *Nat Clin Pract Endocrin Metab* 3: 240-248.
2. Takebe K, Date M, Yamamoto Y (1994) Mass screening for thyroid cancer with ultrasonography (in Japanese). *KARKINOS* 7: 309-317.
3. Ito Y, Uruno R, Nakano K, Takamura Y, Miya A, et al. (2003) An observation trial without surgical treatment in patients with papillary microcarcinoma of the thyroid. *Thyroid* 13: 381-388.
4. Sugitani I, Koda K, Yamada K, Yamamoto N, Ikenaga M, et al. (2010) Three distinctly different kinds of papillary thyroid microcarcinoma should be recognized: our treatment strategies and outcomes. *World J Surg* 34: 1222-1231.
5. Ito Y, Miyauchi A, Inoue H, Fukushima M, Kihara M, et al. (2010) An observation trial for papillary thyroid microcarcinoma in Japanese patients. *World J Surg* 34: 28-35.
6. Ito Y, Miyauchi A, Kihara M, Higashiyama T, Kobayashi K, et al. (2014) Patient age is significantly related to the progression of papillary microcarcinoma of the thyroid under observation. *Thyroid* 24: 27-34.
7. Sugitani I, Fujimoto Y, Yamada K (2014) Association between serum thyrotropin concentration and growth of asymptomatic papillary thyroid microcarcinoma. *World*

- J Surg* 38: 673-378.
8. Fukuoka O, Sugitani I, Ebina A, Toda K, Kawabata K, et al. (2016) Natural history of asymptomatic papillary thyroid microcarcinoma: Time-Dependent changes in calcification and vascularity during active surveillance. *World J Surg* 40: 529-537.
 9. Ito Y, Miyauchi A, Oda H, Kobayashi K, Kihara M, et al. (2016) Revisiting low-risk thyroid papillary microcarcinomas resected without observation: was immediate surgery necessary? *World J Surg* 40: 523-528.
 10. Davies L, Welch HG (2006) Increasing incidence of thyroid cancer in the United States, 1973–2002. *JAMA* 295: 2164-2167.
 11. Davies L, Welch HG (2014) Current thyroid cancer trends in the United States. *JAMA Otolaryngol Head Neck Surg* 140: 317-322.
 12. Ahn HS, Kim HJ, Welch HG (2014) Korea's thyroid-cancer "epidemic" — screening and overdiagnosis. *N Engl J Med* 371: 1765-1767.
 13. Urano T, Miyauchi A, Shimizu K, Tomoda C, Takamura Y, et al. (2005) Usefulness of thyroglobulin measurement in fine-needle aspiration biopsy specimens for diagnosing cervical lymph node metastasis in patients with papillary thyroid cancer. *World J Surg* 29: 483-485.
 14. Haugen BR, Alexander EK, Bible KC, Doherty GM, Mandel SJ, et al. (2016) 2015 American Thyroid Association management guidelines for adult patients with thyroid nodules and differentiated thyroid cancer. *Thyroid* 26: 1-133.
 15. Liu X, Bishop J, Shan Y, Pai S, Liu D, et al. (2013) Highly prevalent *TERT* promoter mutations in aggressive thyroid cancers. *Endocr Relat Cancer* 20: 603-610.
 16. Xing M, Liu B, Liu X, Murgan AK, Zhu G, et al. (2014) *BRAFV600E* and *TERT* promoter mutations cooperatively identify the most aggressive papillary thyroid cancer with highest recurrence. *J Clin Oncol* 32: 2716-2726.
 17. Ito Y, Yoshida H, Maruo R, Morita S, Takano T, et al. (2009) *BRAF* mutation in papillary thyroid carcinoma in a Japanese population: its lack of correlation with high-risk clinicopathological features and disease-free survival of patients. *Endocr J* 56: 89-97.
 18. Ito Y, Yoshida H, Kihara M, Kobayashi K, Miya A, et al. (2014) *BRAF(V600E)* mutation analysis in papillary thyroid carcinoma: is it useful for all patients? *World J Surg* 38: 679-687.
 19. Sugitani I, Fujimoto Y (2010) Does postoperative thyrotropin suppression therapy truly decrease recurrence in papillary thyroid carcinoma? A randomized controlled trial. *J Clin Endocrinol Metab* 95: 4576-4583.
 20. Shindo H, Amino N, Ito Y, Kihara M, Kobayashi K, et al. (2014) Papillary thyroid microcarcinoma might progress during pregnancy. *Thyroid* 24: 840-844.
 21. Ito Y, Miyauchi A, Kudo T, Ota H, Yoshioka K, et al. (2016) Effects of pregnancy on papillary microcarcinomas of the thyroid re-evaluated in the entire patient series at Kuma Hospital. *Thyroid* 26: 156-160.
 22. Oda H, Miyauchi A, Ito Y, Yoshioka K, Nakayama A, et al. (2016) Incidences of unfavorable events in the management of low-risk papillary microcarcinoma of the thyroid by active surveillance versus immediate surgery. *Thyroid* 26: 150-155.
 23. Lim CY, Yun JS, Lee J, Nam KH, Chung WY, et al. (2007) Percutaneous ethanol injection therapy for locally recurrent papillary thyroid carcinoma. *Thyroid* 17: 347-350.
 24. Dupuy DE, Monchik JM, Decrea C, Pisharodi L (2001) Radiofrequency ablation of regional recurrence from well-differentiated thyroid malignancy. *Surgery* 130: 971-977.