

## ***In Vitro* and *In Vivo* Comparison of Applanation Tonometry and Rebound Tonometry in Dogs**

Noriyuki NAGATA<sup>1,2)</sup>, Masashi YUKI<sup>1)</sup> and Takashi HASEGAWA<sup>2)\*</sup>

<sup>1)</sup>Yuki Animal Hospital, 2-99 Kiba-cho, Minato-ku, Nagoya 467-0021 and <sup>2)</sup>Department of Advanced Clinical Medicine, Division of Veterinary Science, Graduate School of Life and Environmental Sciences, Osaka Prefecture University, Izumisano, Osaka 598-8531, Japan

(Received 30 May 2011/Accepted 18 July 2011/Published online in J-STAGE 1 August 2011)

**ABSTRACT.** Intraocular pressure (IOP) evaluated by applanation tonometry via TONO-PEN XL (TP), and rebound tonometry via TonoVet (TV) were compared in enucleated canine eyes with varied pressure of the anterior chamber (AC) and in clinical cases. TV measured IOP values were lower than IOP measurements of TP in the enucleated eyes with 5–10 mmHg of AC ( $P<0.0001$ ), though there was no significant difference in IOP values obtained with TP and TV on the pressure ranges of 15–20 mmHg. However, TP detected IOP values were lower than IOP measurements of TV in the eyes with over 25 mmHg of AC ( $P<0.0001$ ). The results of clinical cases were similar to the enucleated eye model. There was no significant difference in IOP values obtained from TP and TV in dogs with normotensive eyes. IOP measurements of TP were lower than those of TV in glaucomatous eyes ( $P<0.0001$ ). TV was a reliable tonometer for measurement of IOP in hypertensive eyes, whereas it was less accurate than TP in hypotensive eyes. The characteristics of TP and TV should be considered in the evaluation of IOP in practice.

**KEY WORDS:** canine, intraocular pressure, TONO-PEN applanation tonometry, TonoVet rebound tonometry.

*J. Vet. Med. Sci.* 73(12): 1585–1589, 2011

Evaluation of intraocular pressure (IOP) is important for the diagnosis and management of ophthalmic disease in animals [14]. Several tonometries, including indentation, applanation, or rebound tonometry are used to measure IOP in veterinary field [14]. Applanation tonometry, such as TONO-PEN XL (TP), is widely used in the field of veterinary ophthalmology, though it includes potential problems with inaccuracies caused by manual measurement and requires application of a topical anesthetic before IOP measurement [18]. On the other hand, rebound tonometry, such as TonoVet (TV), which has recently become available, is expected to be more reliable than TP, because a constant pressure can be given to the cornea by a mechanically launched probe, thereby providing increased accuracy of IOP measurements [7, 10, 12]. An added benefit is that topical anesthetics are not needed for detection of the animal's IOP [7, 10, 12]. There are reports dealing with the usefulness and/or accuracy of TV in animals and birds [1, 6, 7, 9–12]. In dogs, TP displayed lower IOP values than TV in *in vitro* enucleated eyes, although the relation between the two tonometries in glaucomatous eyes was not the same as *in vitro* [7]. Information about the relationship of IOP evaluated by TP and TV is essential for veterinary practitioners, since the number of veterinary ophthalmologists using both TP and TV has increased recently to assure accurate diagnoses of animals with ophthalmic diseases. The aim of this study is to re-evaluate IOP values measured with TP and TV in the enucleated canine eye model and clinical cases, and to

clarify the relationship and characteristics of both tonometries in veterinary practice.

### **MATERIALS AND METHODS**

**Eye samples and clinical cases:** Thirty eyes without ophthalmic disorders were immediately enucleated transconjunctivally from healthy beagle dogs euthanized for reasons unrelated to this study. The eyes were stored in saline (0.9% NaCl) solution (Otsuka, Tokyo, Japan) at 4°C for up to twelve hours after enucleation.

A total of 247 eyes, including 70 cases consisting of 18 male and 52 female dogs with 1.6 to 37.8 kg of body weight and 3 months to 17 years of age were evaluated by IOP for ophthalmic examination and/or treatment of ophthalmic diseases at the Osaka Prefecture University Veterinary Medical Center. The examined samples included 174 normotensive eyes (94 right and 80 left eyes) without glaucoma, uveitis, and corneal disorders, and 73 glaucomatous hypertensive eyes (33 right and 40 left eyes).

**Measurement of IOP:** IOP was measured with two tonometers in this study; TONO-PEN XL (TP, Medtronic Solan, FL, U.S.A.) as applanation tonometry, and TonoVet (TV, Tiolat, Helsinki, Finland) as rebound tonometry. IOP was evaluated on the center of the cornea in accordance with the instruction manual of each tonometer. Three final IOP readings with variances of less than 5% on each tonometer were obtained and averaged for determination of IOP values for each examined eye. Topical anesthesia of 0.4% oxybutyprocaine hydrochloride (Santen, Osaka, Japan), was applied when IOP was measured by TP in clinical cases.

**Experimental procedures:** For *in vitro* study, the pressure of the anterior chamber (AC) of an enucleated eye was

\* CORRESPONDENCE TO: HASEGAWA, T., Department of Advanced Clinical Medicine, Division of Veterinary Science, Graduate School of Life and Environmental Sciences, Osaka Prefecture University, Izumisano, Osaka 598-8531, Japan.  
e-mail: hsst56@vet.osakafu-u.ac.jp

adjusted by the method of Dziezyc *et al.* [2]. In brief, the enucleated eye was securely positioned on a plastic cup and cannulated transclerally with two 24 G indwelling needles (Terumo, Tokyo, Japan) at 3 and 9 o'clock positions from 2 mm behind the limbus. A cyanoacrylate glue was applied on the sclera with the needle to prevent leakage of aqueous humor. One needle at the 3 o'clock position was connected to lactate ringer's solution (LRS, Terumo, Tokyo, Japan) via a silicone tube, and the other needle at 9 o'clock position was connected to a bedside monitor containing a pressure recorder (BSM-5192, Nihon Kohden, Tokyo, Japan) via a silicone tube and transducer (DX-300, Nihon Kohden, Tokyo, Japan) for monitoring and recording the pressure of AC. The pressure of AC was set in 5 mmHg steps from 5 to 50 mmHg and 10 mmHg steps from 50 to 100 mmHg under pressure control by adjusting the 10 to 140 cm height of the LRS from the eye. IOP was measured with TP and TV at each step. A saline solution was frequently applied to the eye to maintain the cornea in moist condition.

In clinical cases, dogs were handled gently and minimally restrained so as not to artificially raise IOP values via direct pressure on the jugular veins. Also, care was taken not to place pressure on the globe with gentle retraction of the examined eyelid. IOP was measured by TV in sternal recumbency or sitting position, and then IOP was sequentially evaluated with TP in the same position.

**Statistical analysis:** IOP values evaluated by TP and TV and differences between the pressure of AC and IOP measurements are shown as mean  $\pm$  standard deviation (SD). In clinical cases, IOPs of right and left eyes were analyzed separately to prevent a bias effect by pooling of both eyes [22]. The correlation coefficient was calculated with Pearson's correlation coefficient by the rank test. Comparison of IOP values obtained by TP and TV was evaluated by paired Student *t*-test. A *p*-value of less than 0.05 was considered to be statistically significant.

## RESULTS

**In vitro enucleated eye model:** Correlations between the pressures of AC and IOP values evaluated by TP or TV were assessed for the enucleated eyes. A significant linear correlation was detected between the pressure of AC and TP detected IOP ( $r=0.99$ ,  $P<0.0001$ ), and the regression equation between these 2 variables was  $y=0.71x + 1.88$  (Fig. 1). There was also a significant linear correlation between the pressures of AC and TV measured IOP ( $r=0.99$ ,  $P<0.0001$ ; Fig. 1). The regression equation of TV was  $y=0.95x - 0.93$ , and underestimation of IOP values obtained by TV was lower than those by TP (Fig. 1). The differences between the pressure of AC and IOP evaluated by each tonometer are shown in Fig. 2. Although IOP values measured with TV were significantly lower than TP evaluated values in the eyes with 5–10 mmHg of AC ( $P<0.0001$ ), there was no significant difference in IOP values obtained with TP and TV on the pressure of AC at 15–20 mmHg. However, IOP measurements of TP were significantly lower than those of TV

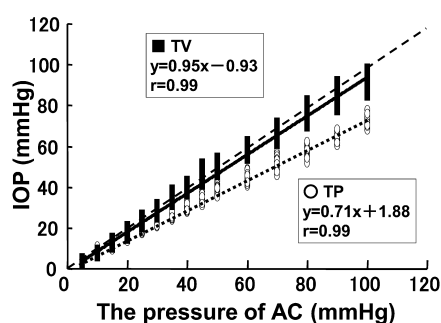


Fig. 1. Relationship between the pressure of anterior chamber (AC) and intraocular pressure (IOP) evaluated with applanation tonometry via Tono-Pen XL (TP), and rebound tonometry via TonoVet (TV) in freshly enucleated canine eyes. The open circle and solid square represent TP and TV, respectively. The solid and dotted lines are calculated regression lines. The dashed line shows an ideal 1:1 relationship.

in the eyes with over 25 mmHg of AC ( $P<0.0001$ ), and TP increasingly underestimated IOP as the pressures of AC increased.

**In vivo clinical cases:** In normotensive eyes, the regression equation and the correlation coefficient between TP and TV were  $y=0.75x + 3.84$  and  $r=0.70$  in right eyes, and  $y=0.71x + 4.29$  and  $r=0.76$  in left eyes, respectively (Fig. 3). There were significant correlations between TP and TV in both normotensive eyes ( $P<0.0001$ ). In glaucomatous eyes, the regression equation and the correlation coefficient between TP and TV were  $y=1.07x + 3.15$  and  $r=0.82$  in right eyes, and  $y=1.05x + 4.59$  and  $r=0.86$  in left eyes, respectively (Fig. 4). Significant correlations were also found between TP and TV in both eyes with glaucoma ( $P<0.0001$ ).

IOP values obtained by TP and TV are shown in Table 1. In normotensive eyes, IOP values obtained by TP and TV were  $13.7 \pm 4.1$  and  $14.2 \pm 4.4$  mmHg in right eyes, and  $13.8 \pm 4.8$  and  $14.2 \pm 4.5$  mmHg in left eyes, respectively. There was no significant difference in IOP values obtained with TP and TV in dogs with normotensive eyes. In glaucomatous eyes, IOP values measured with TP and TV were  $44.5 \pm 10.8$  and  $50.7 \pm 14.1$  mmHg in right eyes, and  $41.4 \pm 12.7$  and  $47.8 \pm 15.5$  mmHg in left eyes, respectively. IOP values evaluated by TP were significantly lower than TV in hypertensive both eyes, similar to the result with the enucleated eye model ( $P<0.0001$ ).

## DISCUSSION

Since assessment of IOP is crucial for making accurate diagnosis on animals with ophthalmic diseases, such as glaucoma and uveitis [14], veterinary ophthalmologists who use both TP and TV have been increasing year by year in Japan. According to previous reports, TP displays lower

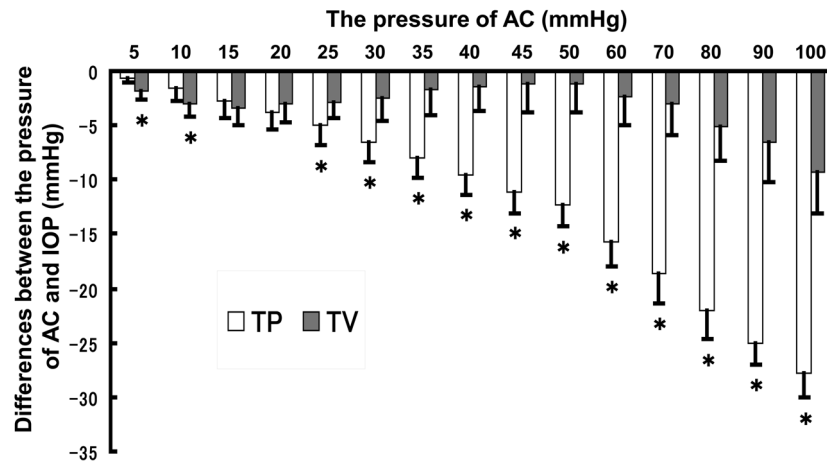


Fig. 2. Differences between the pressure of anterior chamber (AC) and intraocular pressure (IOP) detected by applanation tonometry via Tono-Pen XL (TP), and rebound tonometry via TonoVet (TV) in freshly enucleated canine eyes. The open and gray bars represent TP and TV, respectively. Asterisk indicates statistically significant differences ( $P<0.0001$ ) between TP and TV.

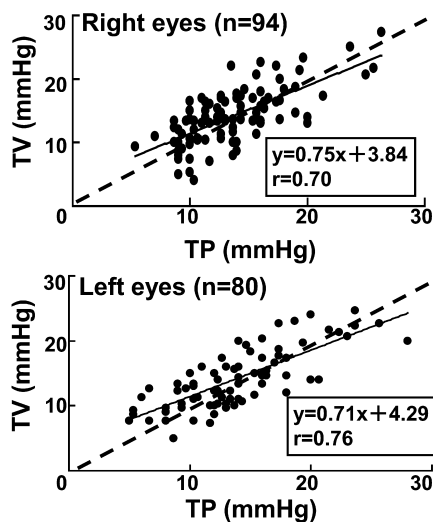


Fig. 3. Relationship between intraocular pressure (IOP) measurements by applanation tonometry via Tono-Pen (TP), and rebound tonometry via TonoVet (TV) in normotensive eyes of clinical cases. The solid and dashed lines are calculated regression lines and an ideal 1:1 relationship, respectively.

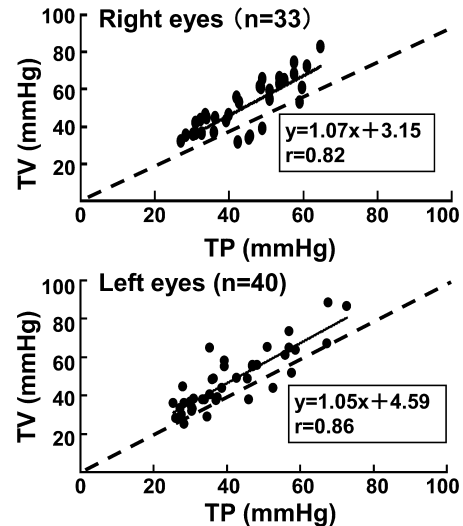


Fig. 4. Relationship between intraocular pressure (IOP) measurements by applanation tonometry via Tono-Pen (TP), and rebound tonometry via TonoVet (TV) in glaucomatous hypertensive eyes of clinical cases. The solid and dashed lines are calculated regression lines and an ideal 1:1 relationship, respectively.

IOP values than TV in dogs [7, 10]. However, the characteristics of the tonometers described above were not necessarily observed in our clinical cases. This phenomenon may indicate that there is unclarified information about the relationship of IOP values detected by TP and TV in dogs. Therefore, IOP measurements of TP and TV were re-evaluated to clarify the detailed relationship and/or characteristics of both tonometers in dogs in this study.

Although both TP and TV displayed lower pressure values than the manometer in all pressure ranges in the enucleated eye model, TV and a manometer almost represented the ideal line (Fig. 1). IOP measurements of TP were clearly lower than those of TV for hypertensive ranges of over 25 mmHg of AC, and TP increasingly underestimated the pressure values at the higher pressure ranges (Fig. 2). These results are similar to those of the previous study [7]. TP was

Table 1. Comparison of intraocular pressure (IOP) obtained by applanation tonometer via Tono-Pen XL (TP), and rebound tonometer via TonoVet (TV) in normotensive and hypertensive eyes of clinical cases

	IOP(mmHg)		Significance
	TP	TV	
Normotensive eyes			
Right eyes (n=94)	13.7 ± 4.1	14.2 ± 4.4	N.S.
Left eyes (n=80)	13.8 ± 4.8	14.2 ± 4.5	N.S.
Hypertensive eyes			
Right eyes (n=33)	44.5 ± 10.8	50.7 ± 14.1	$P < 0.0001$
Left eyes (n=40)	41.4 ± 12.7	47.8 ± 15.5	$P < 0.0001$

N.S. : not significance.

originally designed for humans, and correlation factors were needed for evaluating IOP in other species [20], whereas TV had calibration factors for measuring IOP of animals, such as the dog, cat, and horse [10]. Hence, TV might be able to provide more accurate IOP than TP.

The characteristic of both tonometers in *in vivo* clinical cases should be the same as in *in vitro*. The corresponding linear regression describing the relationship of TP measurements to TV in glaucomatous eyes in this study was  $y = 1.07x + 3.15$  in right eyes and  $y = 1.05x + 4.59$  in left eyes ( $x = \text{TP measurement}$  and  $y = \text{TV measurement}$ , Fig. 4), indicating that the relationship of TP and TV in hypertensive glaucomatous eyes was consistent with the results observed in the *in vitro* model. On the other hand, one report showed a different relationship between the two tonometers in glaucomatous eyes compared to our results. The corresponding linear regression describing the relationship of TP measurements with TV in glaucoma cases was  $y = 0.7996x + 2.459$  ( $x = \text{TP measurement}$  and  $y = \text{TV measurement}$ ) [7]. The stage of glaucoma and evaluation procedure might have caused the differences in results between the two studies. Eyes affected by chronic glaucoma were examined in the present study, while acute glaucoma was selected for analysis of the relationship of TP and TV in the study of Gorig [7]. Since corneal edema is generally observed in the acute early stage of glaucoma [3, 21, 23], corneal thickness may be influenced by the edematous condition of the eye. One report showed that TP and TV detected IOP values were affected by variations in the central corneal thickness in clinically normal dogs [19]. Hence, the difference of IOP readings between the two tonometers might be influenced by different corneal surface conditions related with acute or chronic glaucoma, thereby inducing a different result in the relationship between the two tonometers [19, 24]. In addition, we evaluated only hypertensive glaucomatous eyes for analysis of the regression equation and the correlation coefficient between TP and TV, whereas normotensive eyes were included in the same analysis in the previous study [7]. This different sampling might also have contributed to the differences in the results between the two studies.

Underestimation of IOP measurements by TV was signif-

icantly higher than TP detected IOP values in the pressure ranges up to 10 mmHg of AC, suggesting that TP might be reliable for evaluation of IOP on hypotensive eyes. TP is based on the principle of applanation tonometry applying the Imbert-Fick law, according to which the pressure required to flatten 1 mm<sup>2</sup> of the cornea is equal to the pressure in the eye [14]. In some cases of hypotensive eyes, such as uveitis, it is sometimes difficult to detect the flat cornea at the center of the eye by TP due to a corneal cavity induced by pressure applied manually. Compared with TP, IOP was easily detected by TV in hypotensive eyes because a corneal cavity was not induced by the TV probe. This was not surprising since the TV probe was small and mechanically launched to provide a constant pressure on the cornea without high pressure. Although TV was less accurate than TP in the lower pressure ranges up to 10 mmHg, TV could provide convenient handling for measurement of IOP in hypotensive eyes.

There was no significant difference in the accuracy of IOP evaluated by both tonometers in the normotensive pressure range of 10 to 25 mmHg (Fig. 2 and Table 1). These findings indicate that the accuracy of IOP values given by TP and TV depend on the pressure range of the AC in animals. TP was less accurate than TV in the hypertensive pressure range for over 25 mmHg, whereas it provided more accurate IOP values than TV in the hypotensive pressure range up to 10 mmHg.

There are several reports showing reference ranges of canine normal IOP [4, 8, 10, 12, 13, 15–17, 25]. In the present study, IOP values obtained by TP were similar to those of previous studies in healthy dogs [4, 10, 12, 16, 17]. However, IOP measurements of TV were higher than those of other studies [10, 12]. The difference of IOP measurements observed here may be attributed to the examined cases, IOP measurement time, and examiners. IOP generally differs depending on the time of the day, breed, sex, age of the animal, animal behavior, and the expertise of the examiner [5, 8, 17]. In addition, TV might underestimate the IOP when the cases examined had IOP values in the pressure range of 10 to 15 mmHg, judging from the results presented here (Fig. 2). The reference range of normal IOP might be established by each tonometer at each hospital.

In summary, TV was a reliable tonometer for measurement of IOP for hypertensive eyes, while TP could provide accurate IOP for hypotensive eyes. The accuracy of both tonometers was similar for normotensive eyes. The characteristics of both the TP and TV tonometers should be considered for the evaluation of IOP in practice.

## REFERENCES

1. Danias, J., Kontiola, A. I., Filippopoulos, T. and Mittag, T. 2003. Method for the noninvasive measurement of intraocular pressure in mice. *Invest. Ophthalmol. Vis. Sci.* **44**: 1138–1141.
2. Dziezyc, J., Millichamp, N. J. and Smith, W. B. 1992. Comparison of applanation tonometers in dogs and horses. *J. Am. Vet. Med. Assoc.* **201**: 430–433.
3. Gelatt, K. N., Brooks, D. E. and Kallberg, M. E. 2007. The

- canine glaucomas. pp. 753–811. *In: Veterinary Ophthalmology*, 4th ed. (Gelatt, K. N. ed.), Blackwell Publishing, Iowa.
4. Gelatt, K. N., Gum, G. G. and Barrie, K. P. 1981. Diurnal variation in intraocular pressure in normotensive and glaucomatous Beagles. *Glaucoma* **3**: 21–24.
  5. Gelatt, K. N. and MacKay, E. O. 1998. Distribution of intraocular pressure in dogs. *Vet. Ophthalmol.* **1**: 109–114.
  6. Goldblum, D., Kontiola, A. I., Mittag, T., Chen, B. and Danias, J. 2002. Non-invasive determination of intraocular pressure in the rat eye. Comparison of an electronic tonometer (TonoPen), and a rebound (impact probe) tonometer. *Graefes Arch. Clin. Exp. Ophthalmol.* **240**: 942–946.
  7. Görig, C., Coenen, R. T., Stades, F. C., Djajadiningrat-Laanen, S. C. and Boevé, M. H. 2006. Comparison of the use of new handheld tonometers and established applanation tonometers in dogs. *Am. J. Vet. Res.* **67**: 134–144.
  8. Heywood, R. 1971. Intraocular pressures in the Beagle dog. *J. Small Anim. Pract.* **12**: 119–121.
  9. Jeong, M. B., Kim, Y. J., Yi, N. Y., Park, S. A., Kim, W. T., Kim, S. E., Chae, J. M., Kim, J. T., Lee, H. and Seo, K. M. 2007. Comparison of the rebound tonometer (TonoVet) with the applanation tonometer (TonoPen XL) in normal Eurasian eagle owls (*Bubo bubo*). *Vet. Ophthalmol.* **10**: 376–379.
  10. Knollinger, A. M., La Croix, N. C., Barrett, P. M. and Miller, P. E. 2005. Evaluation of a rebound tonometer for measuring intraocular pressure in dogs and horses. *J. Am. Vet. Med. Assoc.* **227**: 244–248.
  11. Kontiola, A. I., Goldblum, D., Mittag, T. and Danias, J. 2001. The induction/impact tonometer: a new instrument to measure intraocular pressure in the rat. *Exp. Eye Res.* **73**: 781–785.
  12. Leiva, M., Naranjo, C. and Peña, M. T. 2006. Comparison of the rebound tonometer (ICare) to the applanation tonometer (Tonopen XL) in normotensive dogs. *Vet. Ophthalmol.* **9**: 17–21.
  13. Lovekin, L. G. 1964. Primary glaucoma in dogs. *J. Am. Vet. Med. Assoc.* **1**: 1081–1091.
  14. Maggs, D. J. 2008. Basic diagnostic techniques. pp. 95–97. *In: Slatter's Fundamentals of Veterinary Ophthalmology*, 4th ed. (Maggs, D. J., Miller, P. E. and Ofri, R. eds.), Saunders Elsevier, Missouri.
  15. Magrane, W. G. 1951. Tonometry in ophthalmology. *North Am. Vet.* **32**: 413–414.
  16. Miller, P. E., Pickett, J. P., Majors, L. J. and Kurzman, I. D. 1991. Clinical comparison of the Mackay-Marg and Tono-Pen applanation tonometers in the dog. *Prog. Vet. Comp. Ophthalmol.* **1**: 171–176.
  17. Miller, P. E. and Pickett, J. P. 1992. Comparison of the human and canine Schiotz tonometry conversion tables in clinically normal dogs. *J. Am. Vet. Med. Assoc.* **201**: 1021–1025.
  18. Moore, C. G., Milne, S. T. and Morrison, J. C. 1993. Noninvasive measurement of rat intraocular pressure with the TonoPen. *Invest. Ophthalmol. Vis. Sci.* **34**: 363–369.
  19. Park, Y. W., Jeong, M. B., Kim, T. H., Ahn, J. S., Ahn, J. T., Park, S. A., Kim, S. E. and Seo, K. 2011. Effect of central corneal thickness on intraocular pressure with the rebound tonometer and the applanation tonometer in normal dogs. *Vet. Ophthalmol.* **14**: 169–173.
  20. Passaglia, C. L., Guo, X., Chen, J. and Troy, J. B. 2004. TonoPen XL calibration curves for cats, cows and sheep. *Vet. Ophthalmol.* **7**: 261–264.
  21. Pickett, J. P. 2004. Glaucoma. pp. 516–517. *In: The 5-Minute Veterinary Consult Canine and Feline*, 3rd ed. (Tilley, L. P. and Smith, Jr. F. W. K. eds.), Lippincott Williams & Wilkins, Philadelphia.
  22. Ray, W. A. and O'Day, D. M. 1985. Statistical analysis of multi-eye data in ophthalmic research. *Invest. Ophthalmol. Vis. Sci.* **26**: 1186–1188.
  23. Severin, A. G. 1996. Canine glaucoma. pp. 458–470. *In: Severin's Veterinary Ophthalmology Note*, 3rd ed., Veterinary Ophthalmology Notes, Colorado.
  24. Simon, G., Small, R. H., Ren, Q. and Parel, J. M. 1993. Effect of corneal hydration on Goldmann applanation tonometry and corneal topography. *Refract. Corneal Surg.* **9**: 110–117.
  25. Vainisi, S. J. 1970. Tonometry and gonioscopy in the dog. *J. Small Anim. Pract.* **11**: 231–240.