

# Histopathology and Distribution of Cells Harboring Bovine Leukemia Virus (BLV) Proviral Sequences in Ovine Lymphosarcoma Induced by BLV Inoculation

Kan-ichi OHSHIMA, Yoko AIDA<sup>1)</sup>, Jong-Chan KIM<sup>1)</sup>, Kōsuke OKADA, Tatsunari CHIBA, Kenji MURAKAMI, and Yoji IKAWA<sup>2)</sup>

*Department of Veterinary Pathology, Faculty of Agriculture, Iwate University, Morioka-shi 020, <sup>1)</sup>Laboratory of Gene Technology and Safety, <sup>2)</sup>Laboratory of Molecular Oncology, Tsukuba Life Science Center, Institute of Physical and Chemical Research (RIKEN), Koyadai, Tsukuba, Ibaraki 305, Japan*

(Received 10 May 1990/Accepted 2 November 1990)

**ABSTRACT.** Six sheep with lymphosarcoma induced by hypodermic inoculation of bovine leukemia virus (BLV) materials were examined to elucidate the relation between pathologic lesions and integration of BLV provirus in cellular DNAs. Antibodies to BLV gp-antigens had been detected since the 3rd week after the inoculation, and BLV was positive when checked 3 months later. Lymphosarcomas followed the leukemic phase in 4 sheep. The other 2 sheep showed initial lesions of lymphosarcoma and were aleukemic clinically. Five animals were killed by euthanasia and autopsied at 2.5 to 3.5 years postinoculation (pi) because of their diseased condition. One animal died 10 years pi following the 4th leukemic episode. Sarcomatous lesions were confirmed grossly and histologically, and the proliferating neoplastic cells were classified into lymphocytic, polymphocytic, lymphoblastic and histiocytic types. Integration of BLV provirus in cellular DNAs of the peripheral blood lymphocytes (PBL) and neoplastic cells of sarcomatous lesions was examined by Southern blotting technique. BLV provirus was demonstrated in the PBL of all infected animals and in most of the sarcomatous lesions of the spleen, kidney and lymph nodes except 4 lymph nodes showing slight neoplastic infiltration. The results indicated that ovine lymphosarcoma could be caused by BLV and the cells carrying proviral information seemed to be disseminated and proliferate in the lesions.—**KEY WORDS:** BLV provirus, bovine leukemia virus, integration, lymphosarcoma, sheep.

*J. Vet. Med. Sci.* 53(2): 191–199, 1991

Bovine leukemia virus (BLV) is an exogenous retrovirus associated with enzootic bovine leukosis (EBL). Spontaneously occurring ovine lymphosarcoma (OLS) was reported in Europe [2, 5, 6] and New Zealand [10]. Enke [4] pointed out that OLS occurred in animals inoculated with bovine blood as a vaccine against piroplasmiasis. C-type virus isolated from spontaneous OLS was identical to BLV in their antigenicity [25–27]. Many attempts were made to induce OLS by the inoculation of BLV materials. Sheep were susceptible to the virus and OLS was easily produced within several years [3, 7, 8, 11, 14, 15, 18, 19, 21, 22, 28–30, 34–38]. At present, sheep is considered to be a useful model for EBL.

There were many similarities between EBL and OLS, and the target cells of BLV were B-cells in both animals [1]. The DNAs of BLV provirus were usually integrated with the DNAs of infected lymphocytes [12, 13, 23, 31].

The purpose of the present study is to elucidate the pathological characteristics of BLV-induced disorders in sheep and to know the distribution of cells harboring BLV proviral sequences.

## MATERIALS AND METHODS

Five Suffolk and one Corridale sheep aged 4 to 6 months were subcutaneously inoculated with blood of BLV-infected sheep or cattle. One Corridale sheep was reserved as a BLV-negative control. When examined clinically and hematologically one week before the experiment, all sheep showed no abnormalities.

For the blood examination, blood samples were collected from the jugular vein weekly after inoculation and monthly from the 2nd month.

An electric microcellcounter was used for counting blood cells and differential leukocyte count was made in blood smears stained with May-Giemsa solution. Mononuclear cells (MNCs) and atypical mononuclear cells called lymphoid, unusual or leukemic lymphocytes were calculated.

For detection of antibodies to BLV, immunodiffusion was done by using BLV glycoprotein 51 and internal protein 24 antigens. BLV was detected by syncytium assay as described previously [24].

Six sheep were used for histological observations and their outlines with virological and hematological

data are shown in Table 1. Animals were killed by euthanasia and autopsied for pathological examinations. After gross observation, tissues were fixed in 10% neutral formalin solution and embedded in paraffin. Paraffin sections were stained with hematoxylin and eosin (HE).

Electron microscopy was performed on selected tissues using a Hitachi H-600 electron microscope as described elsewhere [20].

Selected tissues (Table 3) with or without tumor were frozen at  $-80^{\circ}\text{C}$  and stored for Southern blot analysis. Extraction of cellular DNAs from the frozen tissue blocks was performed with the sodium dodecyl sulfate (SDS) plus phenol-chloroform method [16]. Peripheral blood lymphocytes (PBLs; MNCs) were separated from blood cells with Percoll (Pharmacia, USA) according to the method of Miyasaka and Trnka [17] and total DNAs were extracted from the PLBs as described by Hughes *et al.* [9].

High molecular weight DNAs (10  $\mu\text{g}$ ) were completely digested with an excess of *Hind*III restriction enzyme. The digested chromosomal DNAs were electrophoresed on 0.8% agarose gels and *Hind*III-digested  $\lambda$  DNA was used as a size

marker. After electrophoresis, the DNAs were transferred from agarose gels to nitro-cellulose filters by the method of Southern [33]. The filters were hybridized with  $^{32}\text{P}$ -nick-translated probes in a buffer containing 50% formamide at  $42^{\circ}\text{C}$  for 12 hrs. The filters were washed 4 times for 30 min in  $2 \times$  SSPE containing 0.2% SDS at  $45^{\circ}\text{C}$  with agitation.

BLV proviral genome of hybridization probe used in the present experiment was prepared by double digestion with *Eco*RI and *Sa*I and gel electrophoresis of a BLV proviral clone ( $\lambda$  BLV-1) whose complete nucleotide sequence has already been determined [32]. These labeled probes were obtained by nick translation using [ $\alpha$ - $^{32}\text{P}$ ] dCTP (Amersham; 3000 Ci/mmol).

## RESULTS

**Blood examination:** The result of the blood examinations is shown in Table 1. Antibodies to BLV appeared from 3–4 weeks after the inoculation and the presence of BLV was confirmed by syncytium assay. Four animals were leukemic and white blood cell counts ranged from 41,400–188,900/cmm at their terminal stages.

Table 1. Experimental sheep and results of blood examinations

Sheep No.	Breed and sex <sup>a)</sup>	Age when inoculated <sup>b)</sup> (months)	Method of inoculation <sup>c)</sup>	BLV <sup>d)</sup>	Antibodies to BLV <sup>e)</sup>		Age at slaughtered (years)	Terminal blood cell count/cmm <sup>f)</sup>			
					gp51	p24		rbc	wbc	MNC	AtMC
1	Su, F	6	sc, 1.0 ml bovine blood infected with BLV	+	+(3)	—	3	874	7,300	3,358	146
2	Su, F	6	sc, 1.0 ml ovine blood infected with BLV	+	+(3)	+(6)	3	1,012	10,400	5,148	468
3	Su, M	6	sc, 1.0 ml bovine blood infected with BLV	+	+(3)	—	3	503	188,900	187,956	178,511
4	Su, M	6	sc, 1.0 ml ovine blood infected with BLV	+	+(3)	+(4)	3	1,073	41,400	35,811	14,490
5	Co, M	4	sc, 10 ml bovine blood infected with BLV	+	+(3)	+(3y)	10	616	176,400	175,518	164,934
6	Su, F	4	Irradiated 100R, sc, 1.0 ml bovine blood infected with BLV	ND	+(4)	+(1.5y)	4	675	111,300	107,961	101,700
7	Co, F	ND	ND	—	—	—	3	739	8,100	4,334	41

Notes. a) Su: Suffolk, Co: Corridale, F: female, M: male, b-d) ND: not done, c) sc: subcutis, d,e) +: positive, —: negative, e) ( ): conversion time in weeks or years (y) after inoculation, f) rbc: red blood cell, wbc: white blood cell, MNC: mononuclear cell, AtMC: atypical mononuclear cell.

Table 2. Results of pathological examination

Sheep No.	Autopsy	Histology
1	Infected with BLV, without lesions, wasting	Initial lesions of lymphosarcoma, Scrapie-like encephalopathy
2	Initial lesions of lymphosarcoma	Prolymphocytic cell proliferation in the left lateral iliac lymph node
3	Lymphosarcoma with cutaneous and cerebral lesions	Lymphosarcoma, lymphocytic
4	Lymphosarcoma	Lymphosarcoma, lymphoblastic
5	Lymphosarcoma with cutaneous and cerebral lesions	Lymphosarcoma, prolymphocytic, poorly differentiated, intravascular proliferation
6	lymphosarcoma	Lymphosarcoma, histiocytic
7	Without infection of BLV, wasting	Nodular worm and Fasciola infection

*Pathologic lesions:* Pathologic findings are summarized in Table 2.

No. 1: Although the blood cell counts were within the normal range, she was slaughtered due to undernutrition.

Grossly, there was no obvious lesion except moderate numbers of intestinal lesions of nodular worm. Microscopically, initial lesions characterized by hyperplastic follicles were found in the mandibular, superficial cervical and mesenteric lymph nodes. There were slight infiltration of large, basophilic, blastic cells in the medullary sinuses and focal accumulation of the cells in the cortical regions of the mandibular (Fig. 1) and lateral iliac lymph nodes. Vacuolar degeneration of neurons was evident especially in the medulla oblongata and slight perivascular glia cuffing was found in the cerebrum.

No. 2: Macroscopically, no obvious lesions were observed. Histologically, there were follicular hyperplasia and proliferation of prolymphocytic cells in the medulla of the left lateral iliac lymph node (Fig. 2).

No. 3: Moderate to marked neoplastic involvement with necrotic changes was seen in the liver, gall bladder, spleen, kidneys, myocardium, aorta, lungs, pancreas, submandibular and parotid glands, alimentary organs from the tongue to the rectum, bladder, skeletal muscles, skin, lymph nodes of the whole body, bone marrow, meninges, and others.

Although the architecture of most lymph nodes was completely effaced by the proliferating neoplastic cells, the medullary sinuses remained in the mesenteric lymph nodes. The neoplastic cells were degenerative in some nodes. Pericapsular neoplastic infiltrates were common. Lymph follicles were atrophic or obscured. The neoplastic cells prolifer-

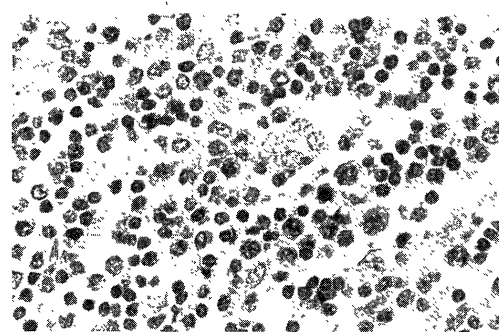


Fig. 1. Scattered large blastic cells in sinus (initial lesion) of the mandibular lymph node of sheep No. 1. HE-stain,  $\times 400$ .

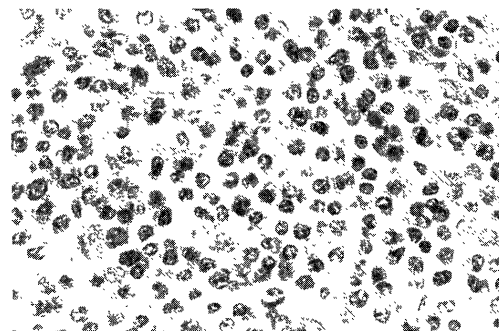


Fig. 2. Prolymphocytic neoplastic cell proliferation in the left lateral iliac lymph node of sheep No. 2. HE-stain,  $\times 400$ .

ated diffusely and markedly in the splenic red pulp, while the white pulp was atrophic.

Cutaneous lesions composed of prominent neoplastic proliferation in the dermis and subcutis (Fig. 3) were similar to those of bovine skin leukosis [20].

The neoplastic cells were medium-sized lymphocytic and characterized by a spherical nucleus with a small amount of heterochromatin and a narrow rim

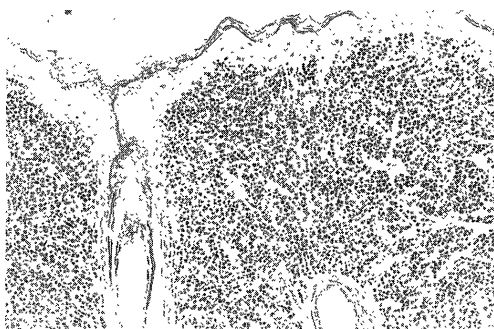


Fig. 3. Neoplastic lesion in the dermis of sheep No. 3. HE-stain,  $\times 100$ .




Fig. 4. Medium-sized lymphocytic neoplastic cells in the mesenteric lymph node of sheep No. 3. HE-stain,  $\times 400$ .

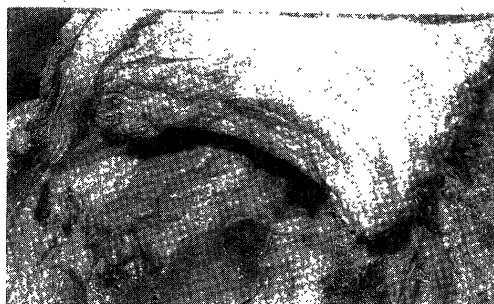

Fig. 5. Tumorous thickening of the thoracic wall of sheep No. 4.

of cytoplasm (Fig. 4).

No. 4: Multiple tumors were palpable through the skin on the thoracic, femoral and other regions. The animal became difficult to stand and died.

Necropsy revealed tumor masses in the muscles of the chest wall (Fig. 5), femoral, axillar, shoulder and other portions, and the largest one was as large as a man's head. Conspicuous additional lesions were observed on the wall of the gastrointestinal tract.

Microscopically, the neoplastic cells proliferated in the periportal areas of the liver, perivascular and parafollicular areas of the splenic pulp, myocar-

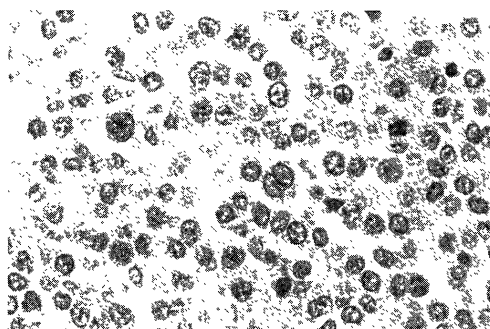


Fig. 6. Large lymphoblastic neoplastic cells with distinct nucleoli in tumor of the thoracic wall of sheep No. 4. HE-stain,  $\times 400$ .

dium, pericardium, alveolar wall of the lungs, abomasal and intestinal walls, peritoneal adipose tissues, and skeletal muscles (Fig. 6). The retropharyngeal, mediastinal and iliac lymph nodes were completely replaced by the proliferation of the neoplastic cells. In the other lymph nodes, the neoplastic cells proliferated mainly in the medulla and the residual cortical structure was recognizable.

The neoplastic cells were large in size and lymphoblastic in appearance. Many of the cells had pale-staining, lobulated or pleomorphic nuclei sometimes with obvious nucleoli (Fig. 6).

No. 5: During the 4th leukemic attack of about 2 months' duration, the animal died. Necropsy revealed splenomegaly and slightly swollen lymph nodes of the whole body. The neoplastic involvement was found in the liver, heart, bone marrow, colon, adipose tissues of the whole body, skeletal muscles of the left forelimb, and inguinal region of the skin.

Microscopically, neoplastic cells were predominant in the hepatic blood vessels and splenic red pulp. The white pulp was atrophic. There were marked to moderate neoplastic infiltrations in the epicardium and myocardium, pulmonary alveolar walls, mandibular and parotid glands, omentum, cutaneous and subcutaneous tissues, and so on. The neoplastic cells infiltrated moderately to slightly in the medulla and the blood capillaries were obviously dilated with many neoplastic cells in the lymph nodes (Fig. 7). Moderate to slight neoplastic infiltration was recognized in the cerebral perivascular regions (Fig. 8), adrenal glands, tongue, tonsils, gastrointestinal tract, bladder, diaphragm, and so on. The vascular lumina filled with neoplastic cells were seen throughout the examined tissues. The neoplastic cells were large and polymorphic and classified into

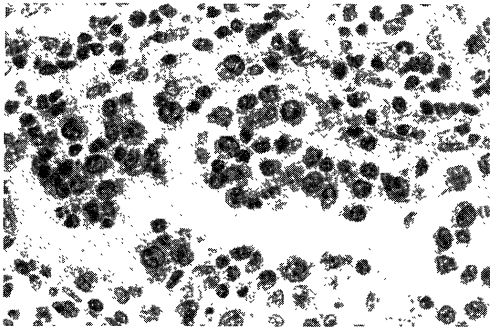


Fig. 7. Prolymphocytic neoplastic cells proliferated in the blood vessel in the right submaxillary lymph node of sheep No. 5. HE-stain,  $\times 400$ .




Fig. 8. Marked neoplastic cell infiltration and proliferation in the blood vessels, perivascular lymph spaces and the surrounding tissue in the diencephalon of sheep No. 5. HE-stain,  $\times 100$ .

prolymphocytic type.

No. 6: The luckmic condition continued for about one month, and then euthanasia was performed.

Grossly, the animal showed splenomegaly, markedly or moderately enlarged lymph nodes of the whole body. The hemal lymph nodes were also enlarged (Fig. 9). Neoplastic lesions were observed in the surrounding tissues of the right optic nerve and thoracic aorta, myocardium, and omentum.

Microscopically, the neoplastic cells proliferated markedly and diffusely in the splenic red pulp, and the white pulp was atrophic. Many lymph nodes revealed complete obliteration of architecture by neoplastic proliferation (Fig. 10). The neoplastic cells infiltrated slightly to moderately into the periportal area of the liver, renal pelvis, myocardium, capsules of the adrenal and thyroid glands, mandibular glands, tongue, gastrointestinal tract, bladder, ovaries, uterus, vagina, mammary glands, diaphragm, skeletal and orbital muscles and adipose tissues, and so on. Nodular neoplastic proliferation was detected in the pleural and peribronchial tissues.




Fig. 9. Neoplastic swelling of the mesenteric hemal lymph nodes of sheep No. 6.




Fig. 10. Large and polymorphic histiocytic neoplastic cells proliferate in the superficial cervical lymph node of sheep No. 6. HE-stain,  $\times 400$ .

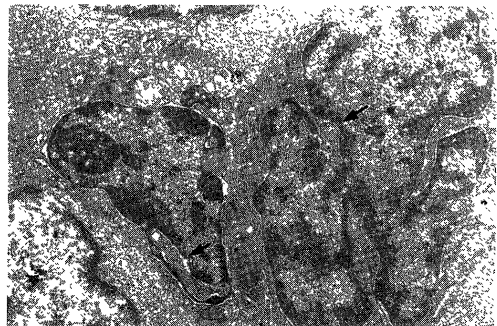


Fig. 11. Irregularly cleaved nucleus with distinct nucleolus and nuclear pockets (arrows) are shown in neoplastic cells from the superficial cervical lymph node of sheep No. 6. Several lysosomes, mitochondria, poorly developed rough surfaced endoplasmic reticulum and moderate amounts of ribosomes are seen in the cytoplasm with complicated border.  $\times 6,000$ .

The neoplastic cells were large and polymorphic with pale-staining lobulated nuclei, and showed indistinct cell boundaries. They were histiocytic (reticulum cell) type in morphology (Fig. 10).

Electron-microscopically, the neoplastic cells were characterized by irregularly contoured nuclei with distinct nucleoli and nuclear pockets. There

were several lysosomes and moderate amounts of ribosome in the cytoplasm showing complicated border (Fig. 11).

No. 7: The animal was recumbent owing to undernutrition and was killed by euthanasia as a BLV-negative control. Autopsy revealed numerous lesions of nodular worm in the intestinal wall and encapsulated fluke nodules in the liver. Microscopically, no obvious lesions were noted except the above-mentioned lesions.

*Localization of BLV proviral sequences in target cells:* The restriction endonuclease *Hind*III cuts once the insert DNA of BLV proviral DNA and generates two fragments containing viral information per BLV copy. Results obtained from hybridization of the BLV probe and *Hind*III-digested DNAs of the PBLs and tissues from 6 BLV-infected and a normal sheep are shown in Table 3.

In 4 (Nos. 3–6) of 6 BLV-infected sheep, two *Hind*III fragments (No. 3; 6.7 and 4.3 kilobases, No. 4; 20.0 and 4.3 kilobases, No. 5; 5.0 and 2.5 kilobases, and No. 6; 23.0 and 4.3 kilobases) were detected in DNAs of all PBLs tested, and of several sarcomatous cells out of the tissues tested. In the microscopically sarcomatous iliac lymph node of

No. 2, mesenteric and subiliac lymph nodes of No. 5, and macroscopically sarcomatous mesenteric lymph node of No. 6, we failed to show the positive hybridization bands. In the other 2 BLV-infected but aleukemic sheep (Nos. 1 and 2), proviral DNAs showing a smear ranging from 6 to 20 kilobases were integrated into DNAs of the PBLs but not of the tissue cells. Moreover, no proviral sequences were detected in not only cellular DNAs from normal sheep but those of non-neoplastic tissues from BLV-infected sheep.

#### DISCUSSION

Southern blot analysis and histopathological examination of OLS disclosed that the BLV provirus was integrated into genomic DNAs of most sarcomatous tissues except 4 lymph nodes with slight lesions. Such a study has never been reported and clearly demonstrated that the present neoplasms were caused by BLV infection.

It was suggested that OLS was a good model of EBL, and most of the experimentally inoculated animals were affected with lymphosarcoma. The fact that OLSs occurred 3 to 4 years after the

Table 3. Neoplastic lesions and integration of BLV provirus in the neoplastic cells

Organs	Sheep No.													
	1		2		3		4		5		6		7	
	Sar <sup>a)</sup>	Int <sup>b)</sup>	Sar <sup>a)</sup>	Int <sup>b)</sup>	Sar <sup>a)</sup>	Int <sup>b)</sup>	Sar <sup>a)</sup>	Int <sup>b)</sup>	Sar <sup>a)</sup>	Int <sup>b)</sup>	Sar <sup>a)</sup>	Int <sup>b)</sup>	Sar <sup>a)</sup>	Int <sup>b)</sup>
Peripheral blood														
Lymphocytes	–	+	–	+	+	+	+	+	+	+	+	+	–	–
Liver	–	·	–	·	++	·	+	+	+	+	·	+	–	·
Spleen	–	–	–	–	+++	+	·	+++	+	+++	+	+++	–	–
Kidney	–	–	–	–	++	·	–	–	++	+	–	–	–	–
Thymus	–	·	–	·	–	·	–	·	–	·	–	–	–	·
Neoplasm														
thoracic wall	–	·	–	·	–	·	+++	+	–	·	–	·	–	·
gluteal muscle	–	·	–	·	++	·	++	·	+	+	–	·	–	·
Lymph nodes														
superf. cervical	–	–	–	–	+++	+	++	+	+	+	+++	+	–	–
mandibular	+	·	–	·	+++	·	+	+	+	·	+++	·	–	·
retropharyngeal	–	·	–	·	+++	·	+++	·	+	+	++	·	–	·
mediastinal	–	·	–	·	+++	·	+++	·	+	+	++	·	–	·
mesenteric	–	–	–	–	++	+	++	+	+	–	++	–	–	–
reticular	–	·	–	·	+++	·	–	·	–	–	·	–	–	·
omasum	–	·	–	·	+++	+	–	·	+	·	–	·	–	·
iliac	+	·	+	–	+++	+	+++	+	+	·	+++	·	–	·
subiliac	–	·	–	·	+++	+	+	·	+	–	+++	·	–	·
popliteal	–	–	–	–	+++	+	–	·	+	·	–	·	–	·
Hemal lymph nodes														
mesenteric	–	·	–	·	++	·	++	·	–	·	++	+	–	·

Notes: a) Sar: leukemic or sarcomatous lesion, –: aleukemic or microscopically negative, +: leukemic or microscopically sarcomatous, ++: grossly moderate sarcomatous, +++: grossly marked sarcomatous.

b) Int: integration of bovine leukemia virus provirus, –: undetected, +: detected by Southern blotting, ·: not tested.

inoculation of BLV by various routes was observed not only in the present study but also in our previous study (unpublished data). In these studies, the neoplastic lesions were similar to those of EBL. Involvement of the spleen and lymph nodes was rather common in both species. Distinct cutaneous lesions were found in 2 sheep and were seldom observed in EBL, although common in the skin leukosis [20]. Cerebral lesions found in 2 sheep were possibly metastatic, because prominent sarcomatous lesions were observed in varied tissues of the whole body, and in one case, intravascular neoplastic invasion was evident.

A sheep (No. 5), 10 years old, died with the moderate neoplastic involvement. It is not clear whether such a phenomenon is observable only in aged animals with low ability of cellular growth or not. There might be other spontaneous mechanisms concerned than age factor.

As shown in Table 3, the present experiments employing Southern blot analysis and molecular cloned BLV DNA as a probe, revealed no BLV proviral sequences were detected in the 4 lymph nodes showing slight neoplastic infiltration from sheep Nos. 2, 5 and 6. This is possibly due to considerably lower population of BLV-infected cells in the examined tissues, and insufficient sensitivity of the assay. Actually, a small number of neoplastic cells were microscopically observed in 3 of the 4 lymph nodes and a small focal lesion in one of them. Therefore, in these instances, by using other techniques with higher sensitivity or improved preparation of DNAs from frozen tissues, positive hybridization bands might be detectable not only in cellular DNAs of sarcomas but also of initial lesions or even of non-neoplastic tissues from BLV-infected sheep.

In the present experiment, each of sheep Nos. 3–6 showed a definite hybridization pattern in varied neoplastic tissues and PBLs. The results then suggested that, as in cattle [12, 23], sheep tumors appeared to be monoclonal expansions of cells carrying proviral information. The BLV probe could be hybridized with two *Hind*III fragments, whose size varied from case to case. As *Hind*III makes one cleft of linear BLV proviral DNA [31], it appears that most of the sarcomatous cells tested contains one BLV proviral DNA copy of BLV per genome. In contrast, smear covering hybridization bands of proviral DNAs were observed in the PBLs from aleukemic sheep Nos. 1 and 2. In the subclinical

stage of the infection at 15 months after inoculation with BLV, *Hind*III-digested PBL DNAs from sheep Nos. 3–6 showed also smear covering bands of a wide range varying between 6 to 23 kilobases (unpublished data). These facts indicated that proviral DNA was integrated at a large number of genomic sites in the PBLs.

Additionally, it was difficult to find proviral sequences in the several lymph nodes from infected sheep Nos. 1 and 2 with partial initial lesions as well as in the histologically normal reticular lymph node but from affected sheep No. 5 as shown in Table 3. It was thought that the integration itself was comparatively rarely observed in the lymphocytes composing the original lymph nodes from infected or even affected sheep. Further studies are needed to elucidate the relationship between the initial lesion and location of integrated cells in the lymph nodes.

It might be concluded that BLV-infection occurred initially in the PBLs, and the lymphocytes in the lymph nodes seemed to have a tendency to escape the BLV-infection in spite of circulation of the infected cells from the blood to the organs. It is possible that a selection of BLV-positive PBLs took place during the progress of the disease, and then the selected cells began their monoclonal growth. The fact that the cells with proviral DNAs were disseminated and proliferated after the neoplastic transformation was demonstrated histologically and by DNA analysis.

**ACKNOWLEDGEMENTS.** This study was supported in part by grants from the Ministry of Health and Welfare of Japan for Comprehensive 10-Year Strategy for Cancer Control and by Special Coordination Funds from the Science and Technology Agency of the Japanese Government.

#### REFERENCES

1. Aida, Y., Miyasaka, M., Okada, K., Onuma, M., Kogure, S., Suzuki, M., Minoprio, P., Levy, D., and Ikawa, Y. 1989. Further phenotypic characterization of target cells for bovine leukemia virus experimental infection in sheep. *Am. J. Vet. Res.* 50: 1946–1951.
2. Anderson, L. J. and Jarrett, W. F. H. 1968. Lymphosarcoma (leukemia) in cattle, sheep and pigs in Great Britain. *Cancer* 22: 398–405.
3. Dimmock, C. K., Rogers, R. J., Chung, S. Y., McKenzie, A. R., and Waugh, P. D. 1986. Differences in the lymphoproliferative response of cattle and sheep to bovine leucosis virus infection. *Vet. Immunol. Immunopathol.* 11: 325–331.
4. Enke 1964. Vermutlicher Uebertragungsweg der Leukose vom Rind auf das Schaf. *Monatsh. Veterinaarmed.* 19: 45.
5. Enke, K.-H., Jungnitz, M., and Roessger, M. 1961. Ein

- kasuistischer Beitrag zur lymphatischen Leukose des Schafes. *Dtsch. Tierärztl. Wochenschr.* 69: 359–364.
6. Hilgenfeld, M. and Krieg, K. 1965. Beitrag zur leukose des Schafes. *Monatsh. Veterinaermed.* 20: 266–270.
7. Horvath, Z. 1976. Experimental transfer of enzootic bovine leucosis to sheep. *Acta Vet. Acad. Sci. Hung.* 26: 31–32.
8. Hoss, H. E. and Olson, C. 1974. Infectivity of bovine C-type (leukemia) virus for sheep and goats. *Am. J. Vet. Res.* 35: 633–637.
9. Hughes, S. H., Shank, P. R., Spector, D. H., Kung, H. -J., Bishop, J. M., Varmus, H. E., Vogt, P. K., and Breitman, M. L. 1978. Proviruses of avian sarcoma virus are terminally redundant, coextensive with unintegrated linear DNA and integrated at many sites. *Cell* 15: 1397–1410.
10. Johnstone, A. C. and Manktelow, B. W. 1978. The pathology of spontaneously occurring malignant lymphoma in sheep. *Vet. Pathol.* 15: 301–312.
11. Kenyon, S. J., Ferrer, J. F., McFeely, R. A., and Graves, D. C. 1981. Induction of lymphosarcoma in sheep by bovine leukemia virus. *J. Natl. Cancer Inst.* 67: 1157–1163.
12. Kettmann, R., Cleuter, Y., Mammerickx, M., Meunier-Rotival, M., Bernardi, G., Burny, A., and Chantrenne, H. 1980. Genomic integration of bovine leukemia provirus: Comparison of persistent lymphocytosis with lymph node tumor forms of enzootic bovine leukosis. *Proc. Natl. Acad. Sci. U.S.A.* 77: 2577–2581.
13. Kettmann, R., Mammerickx, M., Portetelle, D., Gregoire, D., and Burny, A. 1984. Experimental infection of sheep and goat with bovine leukemia virus: Localization of proviral information in the target cells. *Leukemia Res.* 8: 937–944.
14. Mammerickx, M., Dekegel, D., Burny, A., and Portetelle, D. 1976. Study on the oral transmission of bovine leukosis to sheep. *Vet. Microbiol.* 1: 347–350.
15. Mammerickx, M., Portetelle, D., and Burny, A. 1981. Experimental transmission of bovine leukemia virus (BLV) between several animal species. *Zentralbl. Veterinaermed., B* 28: 69–81.
16. McKnight, G. S. 1978. The induction of ovalbumin and conalbumin mRNA by estrogen and progesterone in chick oviduct explant culture. *Cell* 14: 403–413.
17. Miyasaka, M. and Trnka, Z. 1985. Sheep as an experimental model for immunology: Immunological techniques in vitro and in vivo. pp. 403–422. In: *Immunological Methods*, vol. 3 (Lefkovits, I. and Pernis, B. eds.), Academic Press Inc., New York.
18. Ohshima, K., Iigou, Y., Okada, K., and Numakunai, S. 1984. Ovine lymphosarcoma experimentally infected with bovine leukemia virus by tabanid flies. pp. 63–69. In: *Proceedings of the Fourth Congress of the Federation of Asian Veterinary Associations, The Chinese Society of Veterinary Science, Taipei.*
19. Ohshima, K., Okada, K., Numakunai, S., Yoneyama, Y., Sato, S., and Takahashi, K. 1981. Evidence on horizontal transmission of bovine leukemia virus due to blood-sucking tabanid flies. *Jpn. J. Vet. Sci.* 43: 79–81.
20. Okada, K., Yamaguchi, A., Ohshima, K., Numakunai, S., Itoh, H., Seimiya, Y., and Koyama, H. 1989. Spontaneous regression of bovine cutaneous leukosis. *Vet. Pathol.* 26: 136–143.
21. Olson, C. and Baumgartener, L. E. 1976. Pathology of lymphosarcoma in sheep induced with bovine leukemia virus. *Cancer Res.* 36: 2365–2373.
22. Olson, C., Miller, L. D., Miller, J. M., and Hoss, H. E. 1972. Transmission of lymphosarcoma from cattle to sheep. *J. Natl. Cancer Inst.* 49: 1463–1467.
23. Onuma, M., Sagata, N., Okada, K., Ogawa, Y., Ikawa, Y., and Ohshima, K. 1982. Integration of bovine leukemia virus DNA in the genomes of bovine lymphosarcoma cells. *Microbiol. Immunol.* 26: 813–820.
24. Onuma, M., Watarai, S., Sonoda, M., Mikami, T., and Izawa, H. 1980. Detection of bovine leukemia virus by syncytium assay. *Can. J. Comp. Med. Vet. Sci.* 44: 289–293.
25. Paulsen, J., Kuwilsky, S., and Schliesser, Th. 1973. Antikörper gegen bovines und ovines C-Typ-Virus-spezifisches Antigen in Seren von Rindern eines leukoseverseuchten Milchviehbestandes. *Zentralbl. Veterinaermed., B* 20: 696–700.
26. Paulsen, J., Rudolph, R., Hoffmann, R., Weiss, E., and Schliesser, Th. 1972. C-type virus particles in phytohemagglutinin-stimulated lymphocyte cultures with reference to enzootic lymphatic leukosis in sheep. *Med. Microbiol. Immunol.* 158: 105–112.
27. Paulsen, J., Rudolph, R., and Miller, J. M. 1974. Antibodies to common ovine and bovine C-type virus specific antigen in serum from sheep with spontaneous leukosis and from inoculated animals. *Med. Microbiol. Immunol.* 159: 105–114.
28. Paulsen, J., Rudolph, R., and Schliesser, Th. 1975. Experimentelle Uebertragung der lymphatischen Leukose des Schafes. *Zentralbl. Veterinaermed., B* 22: 737–748.
29. Rensang, A. A., Baars, J. C., Calafat, J., Mastenbrek, N., and Quak, J. 1976. Studies on bovine leukemia III. The hematological and serological response of sheep and goats to infection with whole blood from leukemic cattle. *Zentralbl. Veterinaermed., B* 23: 662–668.
30. Rogers, R. J., Chung, Y. S., and Dimmock, C. K. 1984. Development of lymphosarcoma in sheep after inoculation with bovine leukosis virus. *Aust. Vet. J.* 61: 196–197.
31. Sagata, N., Ogawa, J., Kawamura, J., Onuma, M., Izawa, H., and Ikawa, Y. 1983. Molecular cloning of bovine leukemia virus DNA integrated into the bovine tumor cell genome. *Gene* 26: 1–10.
32. Sagata, N., Yasunaga, T., Tsuzuku-Kawamura, J., Ohishi, K., Ogawa, Y., and Ikawa, Y. 1985. Complete nucleotide sequence of the genome of bovine leukemia virus: Its evolutionary relationship to other retroviruses. *Proc. Natl. Acad. Sci. U.S.A.* 82: 677–681.
33. Southern, E. M. 1975. Detection of specific sequences in prolymphocytic leukemia. *Br. J. Haematol.* 40: 587–596.
34. Urbaneck, D., Beyer, J., Wittmann, W., and Seils, H. 1973. Pathomorphologische Befunde bei Schafleukose aus Uebertragungsversuchen mit Material haematologisch leukose-positiver Rinder. *Arch. Exp. Veterinaermed.* 27: 75–87.
35. Van Der Maaten, M. J. and Miller, J. M. 1976. Induction of lymphoid tumors in sheep with cell free preparations of bovine leukemia virus. pp. 377–379. In: *Comparative Leukemia Research, Bibl. Haemat.*, vol. 43 (Clemmesen, J. and Yohn, D. S. eds.), Karger, Basel.
36. Wittmann, W. and Urbaneck, D. 1969. Untersuchungen zur Aetiologie der Rinderleukose 8. Uebertragungsversuche mit Blut leukosekranker Rinder auf Schafleukose. *Arch. Exp. Veterinaermed.* 23: 709–713.
37. Wittmann, W. and Urbaneck, D. 1970. Die Uebertragbarkeit der enzootischer Rinderleukose auf das Schaf.



- Monatsh. Veterinaarmed.* 25: 218–221.
38. Wittmann, W., Urbaneck, D., Seils, H., and Beyer, J.  
1971. Untersuchungen zur Aetiologie der Rinderleukose  
10. Gesamtauswertung erster Uebertragungsversuche mit  
Blut leukosekranker Rinder auf Schaflaemmer unter besonderer Beruecksichtigung klinischer und haematologischer Befunde. *Arch. Exp. Veterinaarmed.* 25: 587–595.