

CASE SERIES

REHABILITATION OF SUBACROMIAL PAIN SYNDROME
EMPHASIZING SCAPULAR DYSKINESIS IN AMATEUR
ATHLETES: A CASE SERIESKatherinne F. Moura, PT, MSc¹Renan L. Monteiro, PT, MSc¹Paulo R.G. Lucareli PT, PhD²Thiago Y. Fukuda, PT, PhD^{1,3}

ABSTRACT

Study design: Case series

Background and Purpose: Scapular dyskinesis has been associated with several shoulder injuries. Recent literature has suggested that a greater activation of the scapular muscles can play an important role in reducing subacromial impingement in patients with shoulder pain. Thus, the purpose of this case series was to describe a rehabilitation program that emphasizes scapular dyskinesis correction for those with clinical evidence of subacromial pain syndrome.

Case Descriptions: The four amateur athletes in this series showed clinical evidence of subacromial pain syndrome and scapular dyskinesis and each underwent a treatment protocol consisting of three phases. Phase 1 emphasized pain relief, scapular control, and recovery of normal range of motion (ROM), Phase 2 focused on muscular strengthening, and Phase 3 emphasized sensory motor training.

Outcomes: All subjects demonstrated decreased pain, improved sports performance and function, increased muscular strength for shoulder elevation and external rotation, and increased ROM for internal rotation. Improvement in serratus anterior (SA) activation was also noted.

Discussion: The results of this case series suggest that subjects with clinical tests positive for subacromial pain syndrome can show significant improvement with an intervention focused on scapular dyskinesis correction. SA activation can play an important role in this process given that all subjects presented with better recruitment after rehabilitation, as measured by electromyography.

Levels of Evidence: Level 4*Key Words:* Impingement, serratus anterior, trapezius

CORRESPONDING AUTHOR

Thiago Y. Fukuda

Instituto Trata, Rua Martinico Prado, 26 Cj
141, CEP 01224-010

Bairro Higienópolis, São Paulo – SP, Brazil

Phone: (55 + 11) 96400-4144

E-mail: fukuda@institutotrata.com.br

¹ Physical Therapy Sector, Santa Casa of São Paulo - ISCMSP, São Paulo-SP, Brazil² Nove de Julho University, São Paulo-SP, Brazil³ Trata Institute – Knee and Hip Rehabilitation, São Paulo-SP, Brazil

BACKGROUND AND PURPOSE

Subacromial pain syndrome is defined as any non-traumatic shoulder problem, usually unilateral, with localized pain around the acromion, which usually worsens during or after lifting of the arm.¹ The following terms are commonly linked to subacromial pain syndrome: bursitis, tendinosis calcarea, supraspinatus tendinopathy, partial tear of the rotator cuff, biceps tendinitis and rotator cuff tendon degeneration. Interest in the etiology, diagnosis, and treatment of subjects with shoulder pain continues to increase.¹ While there is available information for subacromial pain syndrome,²⁻⁶ there is limited research regarding appropriate rehabilitation programs for those subjects that present clinical evidence of scapular dyskinesis. As clinicians become more aware of scapular influence on shoulder injuries, information is needed to help guide rehabilitation focusing on scapular control.

The scapula is highly dependent on muscle activation for mobility and stability due to minimal stability offered by the bony structures.⁷⁻⁹ The combination of the actions of the upper and lower trapezius fibers with the serratus anterior (SA) and the rhomboid muscles provides dynamic scapular stability. The main function of the upper trapezius (UT) is to generate the clavicular retraction needed to avoid excessive internal rotation of the scapula.¹⁰ The main function of the lower trapezius (LT) is to rotate the scapula upward during arm elevation.^{8,9} The rhomboids assist the LT in stabilizing the scapula by controlling medial and lateral sliding. The SA is the muscle that contributes to all normal components of the three-dimensional movement of the scapula (upward rotation, posterior tilt, and external rotation) during arm elevation, while stabilizing its medial border and lower angle, and it is also responsible for scapula protraction.^{8,9}

Scapular dyskinesis refers to dysfunctional movement of the scapula and describes the loss of control of optimal scapular mechanics.⁸ Scapular dyskinesis is not considered an injury and is not always directly related to a specific injury.⁹ However, this change reduces the shoulder function, stressing the acromioclavicular joint, subacromial space, muscle activation, arm positioning and movement, which can lead to the onset of symptoms.⁹ The final result of

most of these etiological factors is a protracted scapula, which can lead to a decrease in the subacromial space, decreased rotator cuff strength due to poor stabilization of the scapula, and increased stress in the anterior glenohumeral ligaments.^{8,9}

Dyskinesis can be evaluated and classified as “yes” or “no” with an agreement of 79%, moderate interrater reliability (ICC of 0.41), and good sensitivity (76%).^{9,11} Scapular dyskinesis can also be classified as: Type 1 or inferior angle prominence, which is associated with excessive anterior tilt; Type 2 or medial border prominence, which is associated with excessive scapular internal rotation; and Type 3 or superior border prominence, which is associated with elevated scapula.¹¹ This method also has a moderate interrater reliability (ICC of 0.44), but with an interrater agreement of 61% and low sensitivity (between 10%-54%).¹¹ Therefore, the yes/no classification has been the most commonly recommended method for use in research.^{8,9,11-13}

Some authors describe scapular dyskinesis as the cause-effect of several disorders of the shoulder complex,^{9, 14} thus scapular rehabilitation should be included in the treatment of subjects with these disorders. Currently, the treatment described in the literature is based on exercises that increase soft tissue flexibility and range of motion (ROM). Others have also suggested strengthening exercises for the periscapular muscles without overload of the hyperactive muscles.^{9,10,15,16}

However, there is a need for further investigation and descriptions of rehabilitation programs focused on scapular dyskinesis correction during treatment of patients with subacromial pain syndrome. The program outlined in this case series emphasized scapular control and muscular performance. Thus, the purpose of this case series was to describe a rehabilitation program that emphasizes scapular dyskinesis correction for those with clinical evidence of subacromial pain syndrome.

CASE DESCRIPTION

This research received approval from The Institutional Review Board of Santa Casa of São Paulo – SP, Brazil, and all participants gave informed, written consent prior to participation. Four amateur athletes with report of unilateral subacromial pain syn-

drome and clinical evidence of scapular dyskinesis were evaluated at baseline and after six weeks of treatment. The demographic data, relevant history, and primary symptoms of each subject are shown in Table 1. Evaluation consisted of an assessment of glenohumeral internal rotation deficit – GIRD,^{6,12} pain and level of function as assessed with the visual analogue scale (VAS), the Constant score,^{17,18} and the Athletic Shoulder Outcome Rating Scale (ASORS).¹⁹ A visual assessment of the scapular dyskinesis was performed according to methods used in previous studies.¹¹⁻¹³ The Yes/No categorical classification for scapular dyskinesis was used due to better reliability. The following special tests for scapular dyskinesis were performed: the scapular assistance test⁹ (SAT) and the scapular retraction test (SRT).^{9, 20-22} Beside the visual test, at least one of these two tests had to be positive for the confirmation that subacromial pain syndrome was related to scapular dyskinesis.

In addition, the Yocum, Neer, Hawkins, and Jobe tests for subacromial pain syndrome;^{23,24} the apprehension test and Fukuda tests for glenohumeral instability were administered.²⁵ Based on the study conducted by Michener et al,²⁴ these tests were clustered aiming to increase diagnostic accuracy. An evaluator who was not part of the treatment sessions conducted all tests and questionnaires. It is

important to highlight that no patients presented radiological signs of decreased glenohumeral or acromioclavicular joint space or morphological changes in the acromion shape.

Isometric strength was measured using a handheld dynamometer (Lafayette Instruments, Lafayette, IL, USA) for shoulder elevator, internal and external rotator muscles. The strength tests were performed according to Donatelli et al²⁶ and Marcondes et al²⁷ methods. A reliability pilot study that was conducted with 10 healthy subjects (20 shoulders) demonstrated ICC values of 0.8 for elevation and 0.7 for internal and external rotation (over three repetitions), which are considered good reliability. To evaluate the internal and external rotator strength, patients were positioned in supine with the shoulder in the scapular plane (around 40 degrees of abduction and flexion), elbow flexed at 90 degrees and neutral rotation. The dynamometer was positioned 2 cm below the styloid process in the ventral face of the wrist (for internal rotation) and dorsal face (for external rotation).^{26, 28} To assess the strength of shoulder elevation, the patient was in a sitting position, shoulder in scapular plane and neutral rotation with the elbow extended. The dynamometer was positioned on the dorsal surface of the wrist.²⁷ The tests were performed twice, with an interval of one minute between each test. The

Table 1. *Subject Demographics*

Patient	Age, y	Gender	Relevant history	Complaints
1	22	Female	Student, amateur tennis player, unilateral anterior shoulder pain, and scapular dyskinesis on the right side (dominant arm)	Anterior and lateral shoulder pain with irradiation (occasional) to the hand, duration of symptoms: 4 years
2	21	Male	Amateur soccer player, bodybuilder, unilateral anterior shoulder pain, and scapular dyskinesis on the left side (non-dominant arm)	Anterior shoulder pain during sports-specific activity and daily-life activities, duration of symptoms: 2 months
3	20	Female	Student, bodybuilder, traumatic shoulder dislocation (6 years ago), general joint laxity, unilateral anterior shoulder pain and anterior instability, and scapular dyskinesis on the right side (dominant arm)	Anterior shoulder pain, apprehension for dislocation during overhead activities, duration of symptoms: 6 years
4	36	Male	Amateur archer, unilateral anterior shoulder pain, and scapular dyskinesis on the left side (non-dominant arm)	Anterior shoulder pain during elevation and arm support on left side during sports-specific activity, duration of symptoms: 4 months

average between these tests was used for statistical analysis. Strength data, measured in kilograms, were normalized to body mass, also measured in kilograms using the following formula: (kg strength/kg body weight) x 100.^{27, 28}

To assess the muscular activation during shoulder elevation in scapular plane, the electromyography (EMG) activity was recorded using an 8-channel EMG system (EMG System do Brasil® Ltda) and surface electrodes with 10-mm diameter Ag/AgCl discs set at an inter-electrode distance of 2 cm, following skin preparation (shaving and cleansing with 70% alcohol) to reduce electrode impedance (typically 10 kΩ or less).²⁹ The EMG signals were converted into a digital format using a 16-bit analog-to-digital converter (EMG System do Brasil®) and an input range of -12 to +12 volts. For signal processing, a high-pass filter with frequency of 500 Hz. Analysis was performed during arm elevation at 120 degrees, with a resistance of around 50% of 1-maximal repetition (1-MR). The root mean square (RMS) of the EMG signal was captured in the UT, LT, and SA of the involved limb for six seconds with the arm elevated and six seconds in the initial position (12 seconds total). A metronome was used to control duration of movement. The patients performed three trials, with a rest time of 30 seconds between each repetition. All data were normalized in relation to maximal isometric voluntary contraction (MVIC).^{10,28} The electrodes were positioned according to SENIAM criteria.^{16,29,30}

To assess the maximal voluntary isometric contraction (MVIC) of the UT, the subject was seated with the arm in 90 degrees abduction, neutral shoulder rotation and with the head rotated 45 degrees toward the non-test side. The patient was then asked to perform shoulder abduction against a fixed resistance imposed by straps on the distal humerus, while manual resistance was applied to the back of the head in the anterolateral direction.³¹ The LT was tested in the prone position, with the arm placed diagonally overhead in line with the fibers of the LT. Resistance was applied against further elevation.³² For the SA, the patient was seated with the arm flexed to 135 degrees and resistance was applied against the further flexion.^{29,33} The subjects performed three 10-second MVICs. There was a one minute pause between each MVIC.

Rehabilitation protocol

The treatment protocol (Table 2) was developed for those with report of subacromial pain syndrome and clinical evidence of scapular dyskinesis. It was asked that subjects not perform sports activities until discharged, returning gradually at Phase 3 of the protocol. Phase 1 consisted of pain control, ROM, and education in scapular control (Figure 1). Pain control was performed as needed according to therapist experience, using manual techniques as trigger point treatment or joint mobilization, or modalities, combined with therapy.^{1,34,35} In this phase, the subjects were instructed to keep shoulders down during the exercises to reduce UT activation. Once a patient noted diminished pain and decreased UT activation with improved control of the scapular movement, the patient could progress to Phase 2.

Phase 2 focused on periscapular muscular strengthening and initiation of sensory motor training (Figure 2). All exercises were dosed at 3 sets of 15 repetitions throughout the protocol, and this intermediate dosage was chosen in order to focus on muscular strength and endurance. Once muscle strength and scapular control were considered acceptable, i.e. performing the exercises without excessive anterior tilt of the scapula, the subject could progress to next phase.

Phase 3 emphasized advanced sensory motor training. Proper scapular alignment and stabilization were encouraged at all times during activity (Figure 3).^{5-7,16,32,36,37} All subjects attended two treatment sessions per week for six weeks and progressed through all protocol phases.

OUTCOMES

Special test results, pain level, and functional scores are included in Table 3. The results of the strength assessment, ROM, and muscular activation (EMG) are provided in Table 4. All subjects attended two treatment sessions per week and progressed through the three phases of the proposed protocol in accordance with the outlined criteria.

Each subject generally progressed well through the treatment program. The analysis of the EMG data showed a pattern of consistently increased SA activity among all subjects, however this pattern did not

Table 2. *Rehabilitation protocol for treatment of scapular dyskinesis*

Parameter	Phase 1	Phase 2	Phase 3
Progression criterion	<ul style="list-style-type: none"> • Anterior shoulder pain • Scapular dyskinesis 	<ul style="list-style-type: none"> • Significant decrease or absence of pain complaint • Scapular conscious 	<ul style="list-style-type: none"> • Good control and muscular strength
Pain	<ul style="list-style-type: none"> • Myofascial release • Physical agents (combined therapy or laser therapy) 	If necessary: <ul style="list-style-type: none"> • Myofascial release • Physical agents (combined therapy or laser therapy) 	
Scapular awareness (Scapular consciousness)	<ul style="list-style-type: none"> • Sitting, arms in neutral position, pull their shoulder blades back and down 		
ROM	<ul style="list-style-type: none"> • Sleeper stretch for posterior shoulder capsule 	If necessary: <ul style="list-style-type: none"> • Sleeper stretch for posterior shoulder capsule 	
Muscle strength	<ul style="list-style-type: none"> • Punch exercise (supine, with the arm flexed to 90° and the elbow extended, punch the ceiling -protracts and retracts the scapula) • Wall push-up plus exercise (standing with hands on wall, protraction and retraction of the scapula) and progress to knee push up plus exercise (support on hands and knees, elbow extended, protraction and retraction of the scapula) • Modified prone Cobra (arms in neutral position, arm extension with external rotation) • In all exercises (except Punch and Push-up plus) perform scapular retraction and depression <p>• 3 X 15 reps</p>	<ul style="list-style-type: none"> • Punch with dumbbells^a • One-handed knee push up plus exercise (support in one hand and knees, protraction and retraction of the scapula) and progress to standard push-up plus (support on hands and feet, elbow extended, protraction and retraction of the scapula) • Modified prone Cobra exercise (arms in neutral position, arm extension with external rotation with dumbbells) • Prone horizontal abduction exercise (arms abducted at 90°, horizontal abduction with external rotation in prone with dumbbells)^a • Prone V-raise exercise (arms abducted at 120°, horizontal abduction with external rotation in prone with dumbbells)^a • Prone row (arms in neutral position, arm extension with the elbows flexed to 90° in prone)^a • Rotator cuff exercise (arm internal / external rotation at 45° of abduction with roll under arm with elastic resistance) • In all exercises (except Punch and Push-up plus) perform scapular retraction and depression • 3 X 15 reps • Progression of the load as tolerated 	<ul style="list-style-type: none"> • Low row exercise (arm extension in shoulder neutral rotation and the elbows extended with elastic resistance)^b • Rotator Cuff exercise (arms internal / external rotation at 90° elevation in scapular plane with elastic resistance)^b • In all exercises (except Punch and Push-up plus) perform scapular retraction and depression • 3 X 15 reps
Sensory motor training			<ul style="list-style-type: none"> • Punch with oscillation flexibar • Standard push-up plus the Swiss ball or balancer (Hands on the unstable surface) • Modified prone Cobra exercise on the swiss ball with dumbbells^a • Prone horizontal abduction exercise on the swiss ball with dumbbells^a • Prone V-raise exercise on the swiss ball with dumbbells^a • In all exercises (except Punch and Push-up plus) perform scapular retraction and depression • 3 X 15 reps
Abbreviations: ROM - Range of motion a Load: 70% of the 1-repetition maximum b Maximum resistance that enabled 10 repetitions			

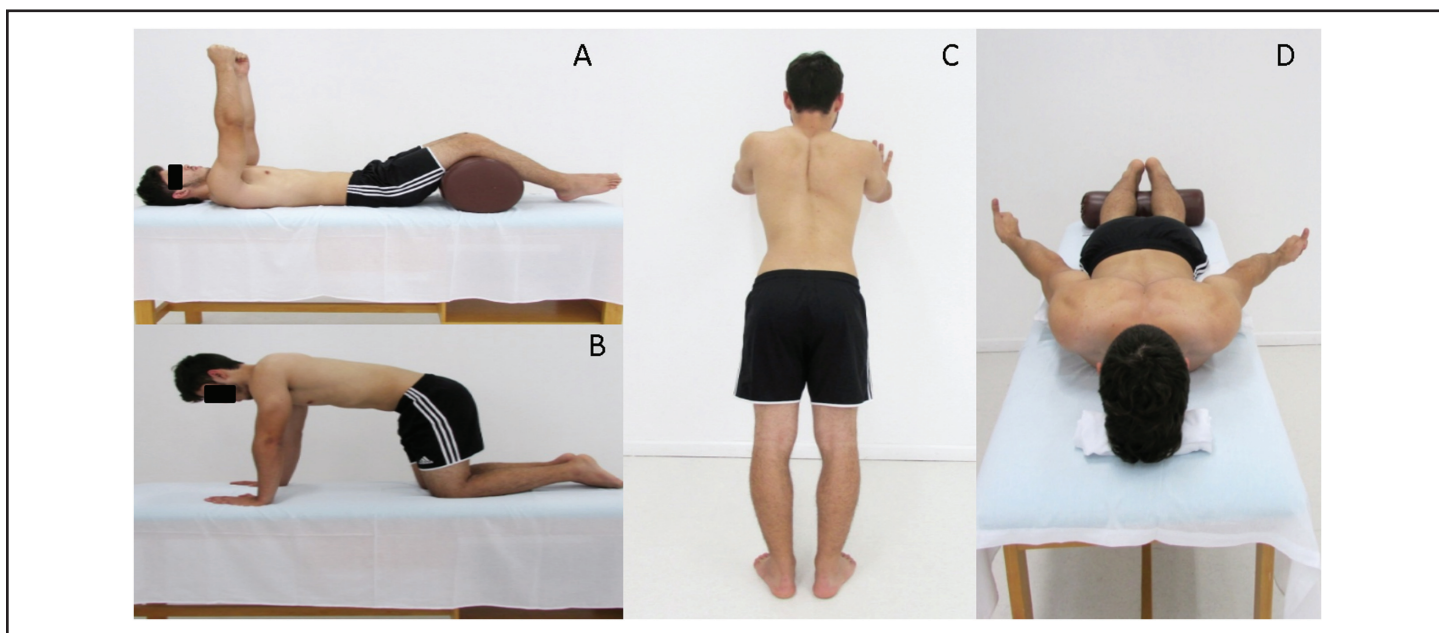


Figure 1. Phase 1. A) Punch exercise. B) Knee push-up plus exercise. C) Wall push-up plus exercise. D) Modified prone Cobra.

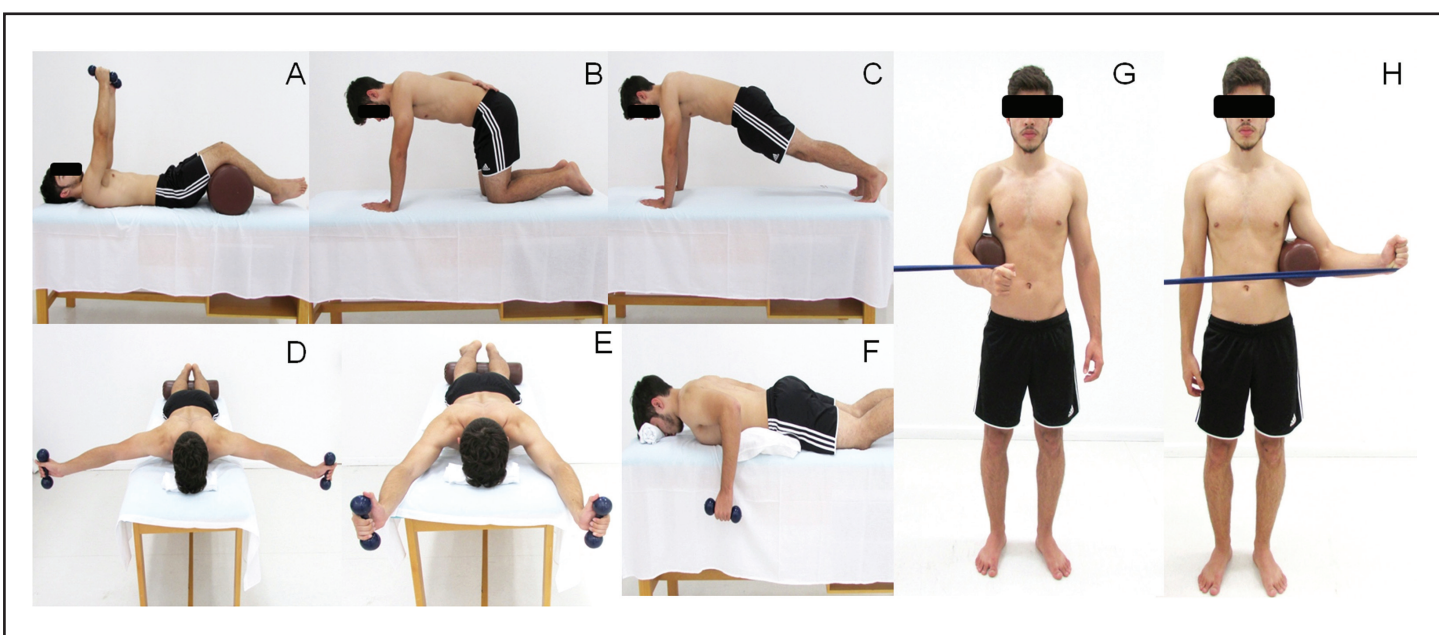


Figure 2. Phase 2. A) Punch with dumbbells. B) One-handed knee push up plus exercise. C) Standard push-up plus. D) Prone horizontal abduction exercise. E) Prone V-raise exercise. F) Prone row. G) Rotator cuff exercise (internal rotation). H) Rotator cuff exercise (external rotation).

exist with regard to the UT and LT because two subjects (1 and 2) decreased activation of the UT and LT, while the other two subjects (3 and 4) showed an increase in activation.

It should be noted that subject 1 reported a decrease in shoulder pain and improvement in scapular con-

trol in the first two weeks. However, in the third week, the subject presented with UT pain during daily activities followed by excessive muscle tension, which influenced progress in the protocol. After this period, the protocol was completed with 16 sessions (8 weeks), without pain complaints, and with return to normal functional and sporting activities.

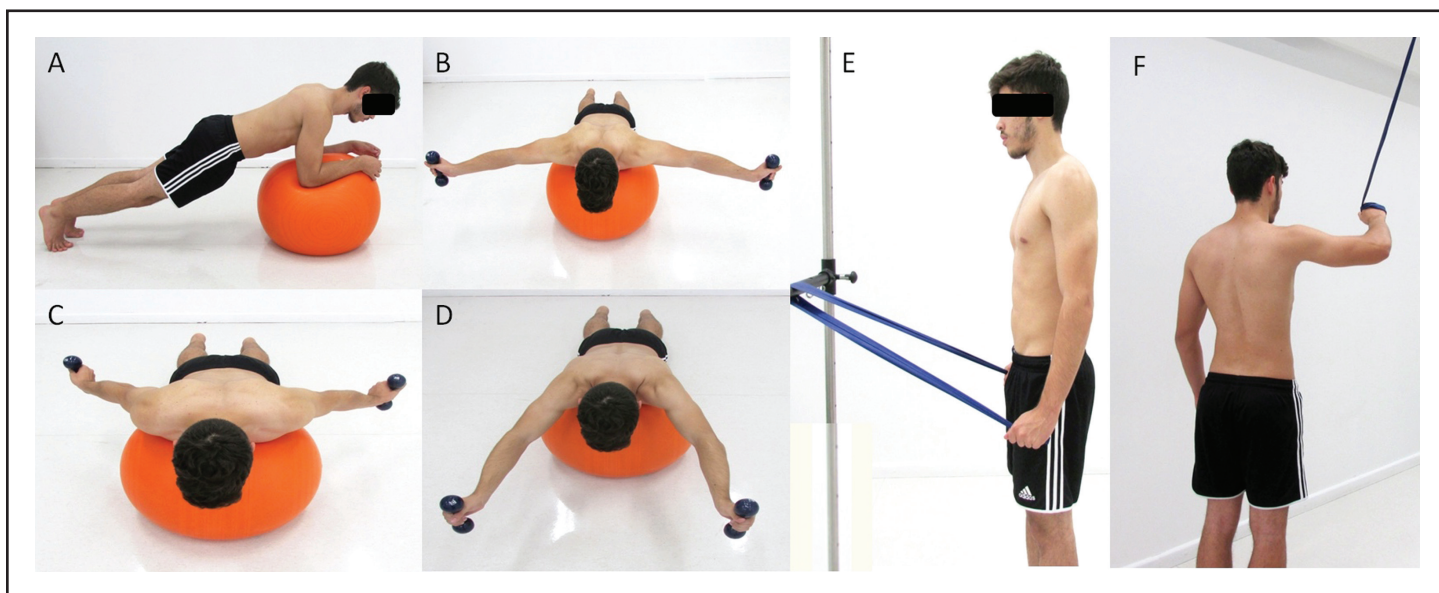


Figure 3. Phase 3 A) Standard push-up plus the Swiss ball. B) Prone horizontal abduction exercise on the Swiss ball with dumbbells. C) Modified prone Cobra exercise on the Swiss ball with dumbbells. D) Prone V-raise exercise on the Swiss ball with dumbbells. E) Low row exercise. F) Rotator cuff exercise (internal rotation at 90° elevation in Scapular plane).

Subject 2 progressed to Phase 2 in just one week and complied with all steps of the protocol. Table 1 shows that this subject had a short duration of symptoms, which may have favored a faster progression through the protocol. After 12 treatment sessions (6 weeks), the patient resumed normal functional and sports activities without complaints.

Subject 3 had bilateral anterior instability of the shoulder associated with a history of recurrent dislocation of the right shoulder and positive provocative tests for glenohumeral instability. The protocol was completed after 12 sessions (6 weeks), but the patient still presented with apprehension sign. However, functional and sporting activities were resumed without complaints.

Subject 4 was an amateur archer with subacromial impingement in the left shoulder (arm providing support to the bow), precluding him from participating in sport. After 12 sessions (6 weeks), the subject showed significant clinical improvement, returning to sports training.

DISCUSSION

This case series describes a rehabilitation program focusing on treatment of scapular dyskinesis used with amateur athletes who presented with clinical evidence of subacromial pain syndrome. Over a

six-week period, the four subjects who participated in this program noted decreased pain, increased strength and ROM, as well as improvement in function and sports performance. Moreover, all subjects showed increased SA muscle activation, as observed by surface EMG.

As noted in Table 3, after treatment, all subjects reached good and excellent scores in terms of function and sports performance, which allowed the return to sport-specific training. Sports performance was assessed by the ASORS questionnaire, which was chosen because it is valid for assessing active adults or athletes with shoulder injuries.¹⁹ Level of function was assessed by the Constant score, which was validated for several shoulder injuries.³⁸ It has an interrater error ranging from 0% to 8%.¹⁸ The minimal clinically important difference (MCID) is unknown for both questionnaires. However, the MCID for the VAS (0-10 cm) was estimated at 1.4cm, specifically for shoulder injuries.³⁹ All patients demonstrated total pain relief (down to zero in VAS), as well as improved muscle strength of the arm elevators (19%-43%)(Table 4). It is important to highlight that, in the first evaluation, the patients' shoulder internal rotators (IR) were stronger than the external rotators (ER) at a ratio of 1.2:1, which changed to 1:1 over the course of the treatment. These findings

Table 3. Results of clinical tests and functional and pain scales for the initial evaluation and re-evaluations (discharge from therapy)

Patient/Special Tests	Before		After	
	Involved	Uninvolved	Involved	Uninvolved
Patient 1				
Yocum	+	-	-	-
Hawkins - Kennedy	+	+	+	-
Neer	+	-	-	-
Jobe	+	+	-	-
Apprehension test	-	-	-	-
Fukuda test	-	-	-	-
SAT	+	-	-	-
SRT	+	-	-	-
VAS (0-10) ^a	5		0	
CONSTANT (0-100) ^b	73 (regular)		82 (good)	
ASORS (0-100) ^c	28 (poor)		80 (good)	
Patient 2				
Yocum	-	-	-	-
Hawkins - Kennedy	+	+	-	-
Neer	-	-	-	-
Jobe	+	-	-	-
Apprehension test	-	-	-	-
Fukuda test	-	-	-	-
SAT	-	-	-	-
SRT	+	-	-	-
VAS (0-10) ^a	6		0	
CONSTANT (0-100) ^b	90 (excellent)		100 (excellent)	
ASORS (0-100) ^c	96 (excellent)		100 (excellent)	
Patient 3				
Yocum	-	-	-	-
Hawkins - Kennedy	+	+	-	-
Neer	+	-	-	-
Jobe	+	-	-	-
Apprehension test	+	+	+	-
Fukuda test	-	-	-	-
SAT	+	+	-	-
SRT	-	-	-	-
VAS (0-10) ^a	6		0	
CONSTANT (0-100) ^b	77 (regular)		83 (good)	
ASORS (0-100) ^c	92 (excellent)		96 (excellent)	
Patient 4				
Yocum	+	-	+	-
Hawkins - Kennedy	+	-	+	-
Neer	+	-	-	-
Jobe	-	-	-	-
Apprehension test	-	-	-	-
Fukuda test	-	-	-	-
SAT	-	-	-	-
SRT	-	-	-	-
VAS (0-10) ^a	8		0	
CONSTANT (0-100) ^b	76 (regular)		91 (excellent)	
ASORS (0-100) ^c	70 (good)		86 (good)	
Abbreviations: SAT - Scapular Assistance Test; SRT - Scapular Retraction Test; VAS - Visual Analog Scale; ASORS - Athletic Shoulder Outcome Rating Scale				
^a 0- to 10-cm scale, where 0 means "no pain" and 10 means "worst imaginable pain"				
^b 0 to 100 points, where below 70 points is "poor", 70-79 is "regular", 80-89 is "good" and 90-100 is "excellent"				
^c 0 to 100 points, where below 50 points is "poor", 50-69 is "regular", 70-89 is "good" and 90-100 is "excellent"				

Table 4. Muscle strength using handheld dynamometer, range of motion using goniometer, and EMG data

	Patient 1			Patient 2			Patient 3			Patient 4		
	Before	After	Change, %	Before	After	Change, %	Before	After	Change, %	Before	After	Change, %
Muscle strength ^a , %												
Arm elevation	16.9	19.1	13.1	42.2	43.5	3.05	24.3	33.1	35.9	15.0	39.2	161.8
Internal rotation	32.7	37.8	15.6	68.5	70.9	3.5	43.8	39.7	(-) 9.4	41.8	56.9	35.6
External rotation	26.0	31.8	22.5	61.9	68.1	10.1	26.5	39.9	50.5	42.5	65.4	54.0
Range of motion, degrees												
Internal rotation	57.0	94.0	64.9	62.0	67.0	8.1	62.0	87.0	40.3	73.0	94.0	28.8
External rotation	93.0	104.0	11.8	99.0	92.0	(-) 7.1	95.0	94.0	(-) 1.0	94.0	91.0	(-) 3.2
Surface EMG ^b , %												
Upper trapezius	17.9	12.6	(-) 29.8	50.5	35.6	(-) 29.5	15.1	81.7	441.0	17.5	55.9	219.7
Lower trapezius	25.2	9.8	(-) 61.2	71.5	51.5	(-) 28.0	24.0	59.9	149.3	8.1	26.4	226.7
Serratus anterior	35.3	68.6	94.6	49.6	70.0	41.0	33.9	43.4	28.1	24.4	44.4	81.6
Abbreviation: EMG (electromyography)												
^a Normalized in relation to body mass index												
^b Normalized in relation to maximal isometric voluntary contraction												

appear to contradict previous theoretical ideas⁶ that the dynamic stabilization of the shoulder depends on a proper balance between ER and IR, where the ER should have at least 65% of the IR strength.

An increase in ROM for internal rotation was observed, which probably occurred due to stretching (sleeper stretch) of the posterior shoulder structures. This finding corroborates with those of other authors who reported that this deficit in internal rotation is closely related to posterior capsule tightness and to scapular dyskinesis, leading to labral lesions and subacromial impingement, among others.^{5,21}

There was increased SA activation in all subjects after treatment, which may also have contributed to improvement of symptoms and the diminished scapular dyskinesis. This finding corroborates the opinion of several authors who believe that the SA is a very important muscle because it is involved in the three scapular movements required for arm elevation and because it commonly demonstrates lower activation in subjects with shoulder injuries.^{5,8-10,37} The fact that most of the patients showed increased SA activity may have influenced the patient's progress with regard to symptoms, even though this increase was not accompanied by a reduction in UT activity or an increase in LT activity shows that all patients presented with dyskinesis in the affected limb. The fact that most of the patients showed increased SA activity may have influenced the patient's progress with regard to symptoms, even though this increase was not accompanied by a reduction in UT activity or an increase in LT activity.^{11,13} A possible explanation

for the lack of change in the UT / LT relationship is that subjects may have had more scapula anterior tilt than upward deficit. However, the clinical tests currently available are inconclusive in terms specificity of different types of scapular dyskinesis.

Various authors have suggested that neuromuscular control and strengthening of the periscapular muscles is important in the treatment of scapular dyskinesis in patients with shoulder injuries. A study by Baskurt et al¹⁵ on patients with subacromial impingement syndrome showed the efficacy of proprioceptive neuromuscular facilitation exercises for scapular muscles. These results agree with the findings of De Mey et al,³⁶ who associated this clinical improvement with the reduction in relative UT activation and the increase in SA activity, even if these exercises leave the UT/LT relationship unchanged.⁴⁰ Finally, the results of a systematic review suggest that a rehabilitation program for subjects with shoulder dysfunction should focus on strengthening the periscapular and rotator cuff muscles, joint mobilization techniques, and posterior capsule stretching.⁴

The treatment protocol described and utilized in the present study emphasized improvement in scapular movement and scapular dyskinesis with the use of exercises divided into three phases according to the level of difficulty based on previous studies.^{6,7,15,16,32,37} A number of authors agree that patterns of scapular dyskinesis can be caused by excess UT activation combined with reduced LT and SA activation and that the appropriate treatment would then be selective activation of the hypoactive muscles and reduc-

tion in the hyperactive muscles.^{3,5,10,16,30,36} However, the present study showed a pattern of SA activation accompanied by a directly proportional relationship between UT and LT activity. These results help to understand how the treatment focusing on scapular dyskinesis can lead to symptom relief, since the dyskinesis may be associated with several shoulder pathologies (such as subacromial impingement, rotator cuff tear, multidirectional instability, among others). The authors of this study strongly believe that the treatment of shoulder injuries should not be focused only on the lesion, but rather on the movement dysfunction. It is important to highlight that other authors already have shown that the presence of rotator cuff tear or degeneration as well as labral injury are not necessarily related to pain.⁴¹⁻⁴³

The limitations of the present case series include the small number of patients treated and the absence of a control group, which do not allow the generalization of the results. Another limitation is the use of surface EMG, because this technique may have allowed interference or cross-talk from other muscle groups. However, EMG is the most common technique used in the literature to evaluate muscle activity. It is important to highlight that the SENIAM criteria for electrode placement and procedures were adopted to minimize all potential interferences. Nevertheless, this study is relevant because it proposes and examines a treatment protocol for scapular dyskinesis to improve shoulder pain in active subjects. Future clinical trials with greater subject numbers and a control group are needed to confirm these results.

CONCLUSION

The results of this case series indicate that amateur athletes with clinical evidence of subacromial pain syndrome associated with scapular dyskinesis patients responded well to a rehabilitation program that emphasized scapular control, upper trapezius relaxation, correction of muscular imbalance, and sensory motor training. The results suggest that subjects with clinical evidence of subacromial pain syndrome can show significant improvement in terms of pain relief, function, and muscular performance after a rehabilitation program intended to address scapular dyskinesis. Further research is necessary to determine the short- and long-term effectiveness

of this approach in the management of shoulder injuries.

REFERENCES

1. Diercks R, Bron C, Dorrestijn O, et al. Guideline for diagnosis and treatment of subacromial pain syndrome: a multidisciplinary review by the Dutch Orthopaedic Association. *Acta Orthop*. 2014;85(3):314-322.
2. Bahu MJ, Trentacosta N, Vorys GC, Covey AS, Ahmad CS. Multidirectional instability: evaluation and treatment options. *Clin Sports Med*. 2008;27(4):671-689.
3. Ellenbecker TS, Cools A. Rehabilitation of shoulder impingement syndrome and rotator cuff injuries: an evidence-based review. *Br J Sports Med*. 2010;44(5):319-327.
4. Kuhn JE. Exercise in the treatment of rotator cuff impingement: a systematic review and a synthesized evidence-based rehabilitation protocol. *J Shoulder Elbow Surg*. 2009;18(1):138-160.
5. Ludewig PM, Reynolds JF. The association of scapular kinematics and glenohumeral joint pathologies. *J Orthop Sports Phys Ther*. 2009;39(2):90-104.
6. Wilk KE, Obma P, Simpson CD, Cain EL, Dugas JR, Andrews JR. Shoulder injuries in the overhead athlete. *J Orthop Sports Phys Ther*. 2009;39(2):38-54.
7. Escamilla RF, Yamashiro K, Paulos L, Andrews JR. Shoulder muscle activity and function in common shoulder rehabilitation exercises. *Sports Med*. 2009;39(8):663-685.
8. Kibler WB, Sciascia A. Current concepts: scapular dyskinesis. *Br J Sports Med*. 2010;44(5):300-305.
9. Kibler WB, Sciascia A, Wilkes T. Scapular dyskinesis and its relation to shoulder injury. *J Am Acad Orthop Surg*. 2012;20(6):364-372.
10. Ludewig PM, Braman JP. Shoulder impingement: biomechanical considerations in rehabilitation. *Man Ther*. 2011;16(1):33-39.
11. Uhl TL, Kibler WB, Gecewich B, Tripp BL. Evaluation of clinical assessment methods for scapular dyskinesis. *Arthroscopy*. 2009;25(11):1240-1248.
12. Burkhart SS, Morgan CD, Kibler WB. The disabled throwing shoulder: spectrum of pathology Part III: The SICK scapula, scapular dyskinesis, the kinetic chain, and rehabilitation. *Arthroscopy*. 2003;19(6):641-661.
13. Gumina S, Carbone S, Postacchini F. Scapular dyskinesis and SICK scapula syndrome in patients with chronic type III acromioclavicular dislocation. *Arthroscopy*. 2009;25(1):40-45.

-
14. Kibler WB, Ludewig PM, McClure PW, Michener LA, Bak K, Sciascia AD. Clinical implications of scapular dyskinesis in shoulder injury: the 2013 consensus statement from the 'Scapular Summit'. *Br J Sports Med.* 2013;47(14):877-885.
 15. Baskurt Z, Baskurt F, Gelecek N, Ozkan MH. The effectiveness of scapular stabilization exercise in the patients with subacromial impingement syndrome. *J Back Musculoskelet Rehabil.* 2011;24(3):173-179.
 16. Cools AM, Dewitte V, Lanszweert F, et al. Rehabilitation of scapular muscle balance: which exercises to prescribe? *Am J Sports Med.* 2007;35(10):1744-1751.
 17. Conboy VB, Morris RW, Kiss J, Carr AJ. An evaluation of the Constant-Murley shoulder assessment. *J Bone Joint Surg Br.* 1996;78(2):229-232.
 18. Constant CR. An evaluation of the Constant-Murley shoulder assessment. *J Bone Joint Surg Br.* 1997;79(4):695-696.
 19. Leme L, Saccol M, Barbosa G, Eijnisman B, Faloppa F, Cohen M. Validação, reprodutibilidade, tradução e adaptação cultural da escala Athletic Shoulder Outcome Rating Scale para a língua portuguesa. *Rev Bras Med.* 2010;67(suplemento 3):12.
 20. Kibler WB. The role of the scapula in athletic shoulder function. *Am J Sports Med.* 1998;26(2):325-337.
 21. Kibler WB, Ludewig PM, McClure P, Uhl TL, Sciascia A. Scapular Summit 2009: introduction. July 16, 2009, Lexington, Kentucky. *J Orthop Sports Phys Ther.* 2009;39(11):A1-A13.
 22. Seitz AL, McClure PW, Finucane S, et al. The scapular assistance test results in changes in scapular position and subacromial space but not rotator cuff strength in subacromial impingement. *J Orthop Sports Phys Ther.* 2012;42(5):400-412.
 23. Calis M, Akgun K, Birtane M, Karacan I, Calis H, Tuzun F. Diagnostic values of clinical diagnostic tests in subacromial impingement syndrome. *Ann Rheum Dis.* 2000;59(1):44-47.
 24. Michener LA, Walsworth MK, Doukas WC, Murphy KP. Reliability and diagnostic accuracy of 5 physical examination tests and combination of tests for subacromial impingement. *Arch Phys Med Rehabil.* 2009;90(11):1898-1903.
 25. Lo IK, Nonweiler B, Woolfrey M, Litchfield R, Kirkley A. An evaluation of the apprehension, relocation, and surprise tests for anterior shoulder instability. *Am J Sports Med.* 2004;32(2):301-307.
 26. Donatelli R, Ellenbecker TS, Ekedahl SR, Wilkes JS, Kocher K, Adam J. Assessment of shoulder strength in professional baseball pitchers. *J Orthop Sports Phys Ther.* 2000;30(9):544-551.
 27. Marcondes FB, Rosa SG, Vasconcelos RA, Basta A, Freitas DG, Fukuda TY. Força do manguito rotador em indivíduos com síndrome do impacto comparado ao lado assintomático. *Acta Ortop Bras.* 2011;19(6):5.
 28. Marcondes FB, de Jesus JF, Bryk FF, de Vasconcelos RA, Fukuda TY. Posterior shoulder tightness and rotator cuff strength assessments in painful shoulders of amateur tennis players. *Braz J Phys Ther.* 2013;17(2):185-194.
 29. Hermens HJ, Freriks B, Disselhorst-Klug C, Rau G. Development of recommendations for SEMG sensors and sensor placement procedures. *J Electromyogr Kinesiol.* 2000;10(5):361-374.
 30. Lin JJ, Hanten WP, Olson SL, et al. Functional activity characteristics of individuals with shoulder dysfunctions. *J Electromyogr Kinesiol.* 2005;15(6):576-586.
 31. McLean L, Chislett M, Keith M, Murphy M, Walton P. The effect of head position, electrode site, movement and smoothing window in the determination of a reliable maximum voluntary activation of the upper trapezius muscle. *J Electromyogr Kinesiol.* 2003;13(2):169-180.
 32. Arlotta M, Lovasco G, McLean L. Selective recruitment of the lower fibers of the trapezius muscle. *J Electromyogr Kinesiol.* 2011;21(3):403-410.
 33. Decker MJ, Hintermeister RA, Faber KJ, Hawkins RJ. Serratus anterior muscle activity during selected rehabilitation exercises. *Am J Sports Med.* 1999;27(6):784-791.
 34. Almeida TF, Roizenblatt S, Benedito-Silva AA, Tufik S. The effect of combined therapy (ultrasound and interferential current) on pain and sleep in fibromyalgia. *Pain.* 2003;104(3):665-672.
 35. Cummings TM, White AR. Needling therapies in the management of myofascial trigger point pain: a systematic review. *Arch Phys Med Rehabil.* 2001;82(7):986-992.
 36. De Mey K, Danneels L, Cagnie B, Cools AM. Scapular muscle rehabilitation exercises in overhead athletes with impingement symptoms: effect of a 6-week training program on muscle recruitment and functional outcome. *Am J Sports Med.* 2012;40(8):1906-1915.
 37. Reinold MM, Escamilla RF, Wilk KE. Current concepts in the scientific and clinical rationale behind exercises for glenohumeral and scapulothoracic musculature. *J Orthop Sports Phys Ther.* 2009;39(2):105-117.
 38. Smith MV, Calfee RP, Baumgarten KM, Brophy RH, Wright RW. Upper extremity-specific measures of disability and outcomes in orthopaedic surgery. *J Bone Joint Surg Am.* 2012;94(3):277-285.
-

-
39. Tashjian RZ, Deloach J, Porucznik CA, Powell AP. Minimal clinically important differences (MCID) and patient acceptable symptomatic state (PASS) for visual analog scales (VAS) measuring pain in patients treated for rotator cuff disease. *J Shoulder Elbow Surg.* 2009;18(6):927-932.
 40. De Mey K, Danneels LA, Cagnie B, Huyghe L, Seyns E, Cools AM. Conscious correction of scapular orientation in overhead athletes performing selected shoulder rehabilitation exercises: the effect on trapezius muscle activation measured by surface electromyography. *J Orthop Sports Phys Ther.* 2013;43(1):3-10.
 41. Miniaci A, Dowdy PA, Willits KR, Vellet AD. Magnetic resonance imaging evaluation of the rotator cuff tendons in the asymptomatic shoulder. *Am J Sports Med.* 1995;23(2):142-145.
 42. Miniaci A, Mascia AT, Salonen DC, Becker EJ. Magnetic resonance imaging of the shoulder in asymptomatic professional baseball pitchers. *Am J Sports Med.* 2002;30(1):66-73.
 43. Sher JS, Uribe JW, Posada A, Murphy BJ, Zlatkin MB. Abnormal findings on magnetic resonance images of asymptomatic shoulders. *J Bone Joint Surg Am.* 1995;77(1):10-15.