

Oral hirudiniasis in a stray dog, first report in Italy

Donato Antonio RAELE^{1)*}, Domenico GALANTE¹⁾ and Maria Assunta CAFIERO¹⁾

¹⁾Istituto Zooprofilattico Sperimentale della Puglia e della Basilicata, via Manfredonia, 20, 71121 Foggia, Italy

(Received 16 March 2015/Accepted 2 May 2015/Published online in J-STAGE 22 May 2015)

ABSTRACT. In June 2014, a male stray dog was recovered at Ente Nazionale di Protezione Animali (ENPA) kennel of Manfredonia, Apulia region, showing oral bleeding and physical prostration. The dog fell in a water canal and was trapped. During the clinical examination, a specimen of leech was revealed into its oral cavity. The parasite, probably entered by drinking unfiltered and contaminated water, has been identified as an adult of aquatic leech *Limnatis nilotica*. Leeches could overrun wide variety of animals, and few reports about blood sucking leech infestations in mammals are available in literature. This paper describes here the first oral hirudiniasis in a dog in Italy and highlights the possibility of human nasopharyngeal leech-related infection in Apulia region.

KEY WORDS: leech, *Limnatis nilotica*, stray dog

doi: 10.1292/jvms.15-0145; *J. Vet. Med. Sci.* 77(10): 1315–1317, 2015

Leeches (Annelida: Hirudinidae) are 34 segmented somite invertebrates predominantly present in freshwater. Leeches can be blood sucking parasites or predators. More than 600 species have been described worldwide, and they include aquatic, terrestrial and marine leeches [34]. Most of the documented leech infestation cases are recorded in tropical or sub-tropical areas and are closely related to habits with unsafe drinking water [11]. Symptoms with leech infestations include body pain, itching, swelling, severe anemia, short-term bleeding, hypersensitivity and anaphylactic reactions [13, 17].

Nile leech *Limnatis nilotica* (Savigny, 1820) has been classified as a member of the Hirudinidae [16]. This species lives in countries around the Mediterranean area and was reported in Spain [4], France [12], Yugoslavia [33], Oman [25], Romania and Bulgaria [18], Turkey [1, 3, 9], Egypt and Lebanon [26], Iran [7, 20, 32], Iraq [2], Tajikistan [30], Libya [31], Azores [29] and Tunisia [15]. *L. nilotica* is a blood feeder which populates in water holes, ponds and canals and attacks animals and humans while they drink. The Nile leech has 30 flat-topped, rough-surfaced teeth mounted on small, rounded and soft jaws unable to pierce external skin [26]. The bite is usually painless, but the wounds bleed for long time and unlikely to cicatrize. The invertebrate enters through the mouth or the nostrils and sucks blood from mucosal membranes of the pharynx, larynx or nostrils, often causing the death of their victims [10]. Nile leech is not host-specific, and it has been found in humans [1, 8], goats [7], cattle [6], donkeys [20], camels [14], deers [4] and hen [5] in different countries and recently in dogs in Iran [28]. In all these cases, respiratory disorders and anemia were dominant

signs [7].

In humans, *L. nilotica* causes many different clinical symptoms, such as epistaxis, hemolysis, hematemesis and vaginal bleeding [1]. Uncontrolled bleeding from neglected wounds may cause anemia and death [10].

In Italy, few reports of the species are confined in Tuscany, Campania, Puglia, Basilicata, Sicily and Sardinia [19, 21]. A rare case of human Nile leech infestation was also described in Naples [21]. The authors described that a specimen of *L. nilotica* was collected from the vomit of a soldier coming back from Libya in 1912, and the majority of old cases recorded refer especially to soldiers. Indeed, a lot of cases were already observed among those of the French troops in duty in Egypt in 1799 and then during campaigns in Spain and Portugal in 1889 [21].

The paucity of reports of Nile leech infestation in modern Europe may be related to the reclamation of wetlands, specialized farming which easily found a source of clean drinking water, the control of stray animals and the general good economic conditions of European citizens.

Of relevant interest, we report here the first case of *L. nilotica* infestation in a male stray dog in Italy. On the 23rd of June 2014, a sub-urban free ranging dog was captured by volunteers of Ente Nazionale di Protezione Animali (ENPA) in Manfredonia. The local police reported that a male stray dog had the habit to drink from a small river and it fell in a drainage ditch (41°35'30"N; 15°53'35"E) before it was trapped. The dog was saved from the roadside ditch. The canal is composed of embanked basins created during the reclamation of the Land Reform of the tableland, and it has high embankment walls that didn't allow the dog for escaping. The substratum of canals consists of rocks, stones, sand and muddy zones covered by numerous algae. When the dog arrived at the kennel, it presented symptoms of general body pain and oral bleeding. The generalized prostration signs were probably due to prolonged immersion in the river water, which had been occurring for at least three hr. On the contrary, the oral bleeding was observed to be linked to a fluctuant mass in its oral cavity, recognized by the veterinary

*CORRESPONDENCE TO: RAELE, D. A., Istituto Zooprofilattico Sperimentale della Puglia e della Basilicata, via Manfredonia, 20, 71121 Foggia, Italy. e-mail: raeled@yahoo.it

©2015 The Japanese Society of Veterinary Science

This is an open-access article distributed under the terms of the Creative Commons Attribution Non-Commercial No Derivatives (by-nc-nd) License <<http://creativecommons.org/licenses/by-nc-nd/3.0/>>.

technician nurse during the rescue operation. After a more accurate analysis, a live leech was attached on the gum in the vestibule under the upper lip (Fig. 1). The leech was then detached and removed by gentle traction with a forceps by the veterinary. The parasite was collected in a plastic vial with 70% alcohol and was sent for morphological identification to the Entomology Laboratory, Department of Virology, Istituto Zooprofilattico Sperimentale della Puglia e della Basilicata (IZSPB), Foggia, Italy. The leech was identified to be a *L. nilotica* according to Minelli morphological keys [21]. The specimen measured 18 mm in length and was gray in main color with two mild orange bands on the body dorsal surface. This leech species is characterized by a highly developed caudal sucker with a diameter equal to the width of the body (Fig. 2). The specimen was stored in glass vial with alcohol 70% in the laboratory of Entomology of IZSP.

Most of the cases of leech infestations are well documented in tropical or sub-tropical regions. Infestation associated to Nile leech has been reported several times in Iran and its neighboring countries, especially Iraq and Turkey. While the knowledge of the composition and geographic distribution of the Hirudinea fauna in Italy is nearly complete, the reports about leech infestation are rare. Of the 28 species of leeches found until today in Italy [23], only few species are obligate blood sucking ectoparasites of mammals.

Italian leech fauna is quite poor if compared with that of the Balkan countries and Central East Europe, and the variety of species decreases from North to South [22]. The parasites feed mainly on mammals, amphibians and birds which are abundantly present in the site of accidental leech attack. The mature form of *L. nilotica* lives in mud and silt in the depth of water holes, ponds or streams, and occasionally, it attacks animals or humans when they are exposed to infested water [26]. The juvenile form of Nile leech is smaller than the adult, and it is used to swim on the water surface and can be ingested more easily by humans or animals. As previously observed, the enlarged caudal sucker observed in this family can be an adaptation phenomenon of the species that mediates the binding to moist mucous membranes [27]. Furthermore, it is well established that Nile leech can survive two years floating on the water surface like small pieces of aquatic plants. It is for this reason that leech infestations are frequently associated to unsafe habits (e.g. drinking contaminated water) [24].

The extraordinary finding of *L. nilotica* in a stray dog in Italy suggests that any infestations in wild and domestic mammals, including humans, may be possible. For this reason, during the veterinary examination, Hirudinea ectoparasites should be included in the differential diagnoses for unexplained anemia, oral bleeding and caught in animals which may have been exposed to contaminated water not only in tropical regions but also in all areas where aquatic leeches are commonly found, included Italy. The animals may come in contact with leeches not only by drinking water, but also walking down the infested little rivers. Such route of transmission may also affect humans. Even though such water is not usually used for drinking, children often swim or play there. Therefore, a low but non negligible risk to become

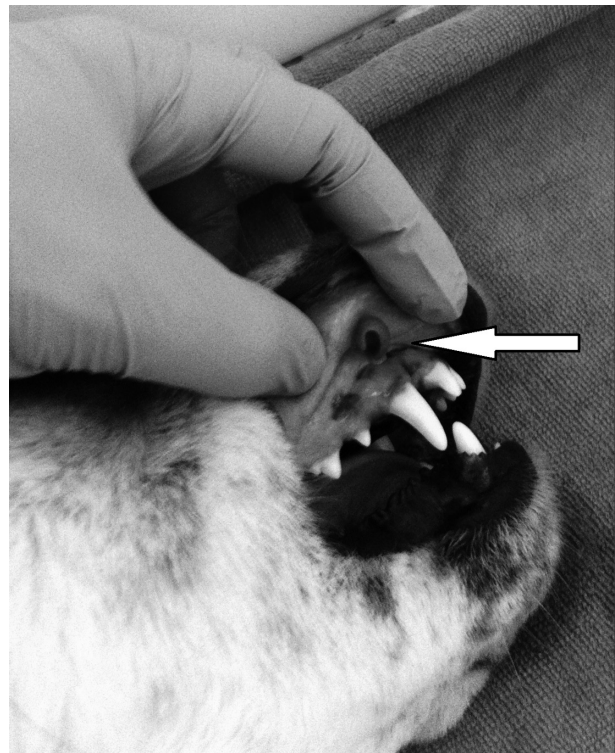

Fig. 1. *L. nilotica* gum of male stray dog (white arrow).

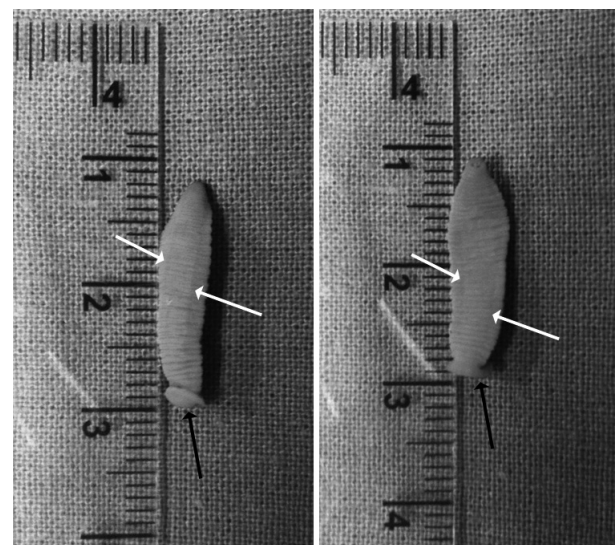


Fig. 2. The Nile leech, *L. nilotica*, obtained from the case: bands on dorsal and ventral surfaces (white arrows) and posterior sucker (black arrow).

infested does exist, raising the possibility of nasopharyngeal leech related infestation, especially in domestic animals and humans who have visited rural streams and have been exposed to freshwater. In the light of these, canals, ponds or natural pools with potentially contaminated water should be

clearly mapped and marked to prevent further infestation.

To the authors' knowledge, this is the first report of a dog infestation in Italy by the blood-sucking parasitic leech *L. nilotica*.

ACKNOWLEDGMENTS. The authors appreciated the Professor Minelli Alessandro for the valuable comments and instructions on leech identification

REFERENCES

1. Ağin, H., Ayhan, F. Y., Gülfidan, G., Cevik, D. and Derebaşı, H. 2008. Severe anemia due to the pharyngeal leech *Limnatis nilotica* in a child. *Türkiye Parazitol. Derg.* **32**: 247–248. [Medline]
2. Almallah, Z. 1968. Internal hirudiniasis as an unusual cause of haemoptysis. *Br. J. Dis. Chest* **62**: 215–218. [Medline] [CrossRef]
3. Alcelik, T., Cekic, O. and Totan, Y. 1997. Ocular leech infestation in a child. *Am. J. Ophthalmol.* **124**: 110–112. [Medline] [CrossRef]
4. Arenas, A., Moreno, T., Maldonado, A., Becerra, C. and Tarra-das, M. C. 1993. Leech *Limnatis nilotica* parasitism in wild red deer *Cervus elaphus* in west Sierra Morena Spain. *Erkrankungen der Zootiere* **35**: 209–211.
5. Bahmani, M., Golshahi, H., Ghotbian, F. and Bahmani, F. 2013. Internal hirudiniasis in a hen (*Gallus gallus domesticus*) The first report in literature. *Asian Pac. J. Trop. Dis.* **3**: 232–234. [CrossRef]
6. Bahmani, M., Eftekhari, Z., Mohsezaadeghan, A., Ghotbian, F. and Alighazi, N. 2012. Leech (*Limnatis nilotica*) causing respiratory distress in a pregnant cow in Ilam province in Iran. *Comp. Clin. Pathol.* **21**: 501–503. [CrossRef]
7. Bahmani, M., Nekouei, S. H., Parsaei, P., Saki, K. and Banihabib, E. K. 2011. Case report infestation with *Limnatis nilotica* in a Persian male dog from Shahrekord. *J. Food Microbiol.* **2**: 29–32.
8. Bahmani, M., Rasouli, M., Parsaei, P., Bahnihabib, E., Saki, K. and Ghotbian, F. 2013. *Limnatis nilotica* infestation in ram and kid in Dehloran city, Ilam province, west of Iran. *Asian Pac. J. Trop. Dis.* **3**: 155–157. [CrossRef]
9. Bilgen, C., Karci, B. and Uluöz, U. 2002. A nasopharyngeal mass: leech in the nasopharynx. *Int. J. Pediatr. Otorhinolaryngol.* **64**: 73–76. [Medline] [CrossRef]
10. Bulent, A., Ilknur, O., Beray, S., Tulin, C., Ulku, T. and Yildiz, D. 2010. An unusual cause of hemoptysis in a child: live leech in the posterior pharynx. *Trop. Biomed.* **27**: 208–210. [Medline]
11. Cook, G. C. 1996. Manson's Tropical Diseases, 1st ed., Saunders, London.
12. Cundall, D. B., Whitehead, S. M. and Hechtel, F. O. P. 1986. Severe anaemia and death due to the pharyngeal leech *Myxobdella africana*. *Trans. R. Soc. Trop. Med. Hyg.* **80**: 940–944. [Medline] [CrossRef]
13. d'Hondt, J. L. and Ben-Ahmed, R. 2009. Catalogue et clés tabulaires de détermination des Hirudiniées d'eau douce de la faune française. *Bull. Soc. Zool. Fr.* **134**: 263–298.
14. Estambale, B. B., Knight, R. and Chunge, R. 1992. Haematemes-sis and severe anaemia due to a pharyngeal leech (*Myxobdella africana*) in a Kenyan child: a case report. *Trans. R. Soc. Trop. Med. Hyg.* **86**: 458. [Medline] [CrossRef]
15. Ghazvinian, K., Rassouli, M., Darvishi, M. M. and Massoum, M. A. 2014. Heavy leech infestation in imported camels to Iran. *J. Camel. Sci.* **7**: 67–70.
16. Hassine, J. B. and Escoriza, D. 2014. *Bufo spinosus* in Tunisia: new data on occurrence, parasitism and tadpole morphology. *Herpetol. Bull.* **127**: 22.
17. Herter, K. 1968. Der Medizinische Blutegel und Seine Verwandten, 4th ed., NeueBrehm-Bücherei, Ziemsen Verlag, Wittenberg Lutherstadt.
18. Manoleli, D. 1972. A new species of leech *Limnatis bacescui* sp. Nov. (Hirudinoidea: Hirudinidae). *Rev. Roum. Biol. Zool.* **17**: 225–286.
19. Massei, F. 1874. Corpo estraneo nella laringe. Estrazione per le vie naturali. *Il Morgagni* **14**: 749.
20. Mehrzadi, S., Jalali, M. H. R., Bahmani, M. and Rahbar, A. 2007. Report infestation of *Limnatis nilotica* (leech) in sheep, cattle, dogs and donkeys in the city of Dehloran. In: Sixth National Conference Veterinarians Clinical Sciences, Islamic Azad University of Tabriz, 6–8 August, 2007, Azerbaijan.
21. Minelli, A. 1979. Hirudinea (Fauna d'Italia, 16), Calderini, Bologna.
22. Minelli, A. 2005. Anellida Hirudinea. pp. 77–78. In: Checklist e distribuzione della fauna Italiana, (Ruffo, F. and Stoch, F. eds.), Memorie del Museo Civico di Storia Naturale di Verona, Verona.
23. Minelli, A. 2008. Hirudinea. *Biol. Mar. Medit.* **15**: 379.
24. Monticelli, F. S. 1917. Di un caso di parassitismo accidentale di *Limnatis nilotica* Savigny nell'uomo. *Boll. età. Natur.* **30**: 124–129.
25. Nesemann, H. and Förster, R. 1997. First record of *Limnatis nilotica* from Oman (Hirudinea: Hirudinidae). *Miscnea. Zool. Hung.* **11**: 11–14.
26. Orevi, M., Eldor, A., Giguzin, I. and Rigbi, M. 2000. Jaw anatomy of the blood-sucking leeches, Hirudinea *Limnatis nilotica* and *Hirudo medicinalis*, and its relationship to their feeding habits. *J. Zool. (Lond.)* **250**: 121–127. [CrossRef]
27. Phillips, A. J., Arauco-Brown, R., Ocegüera-Figueroa, A., Gomez, G. P., Beltrán, M., Lai, Y. T. and Siddall, M. E. 2010. *Tyrannobdella rex* n. gen. n. sp. and the evolutionary origins of mucosal leech infestations. *PLoS ONE* **5**: e10057 [CrossRef]. [Medline]
28. Rajaei, S. M., Khorram, H., Ansari Mood, M., Mashhadi Rafie, S. and Williams, D. L. 2014. Oral infestation with leech *Limnatis nilotica* in two mixed-breed dogs. *J. Small Anim. Pract.* **55**: 648–651. [Medline] [CrossRef]
29. Raposeiro, P. M., Cruz, A. M., Hughes, S. J. and Costa, A. C. 2012. Azorean freshwater invertebrates: Status, threats and biogeographic notes. *Limnetica* **31**: 1322.
30. Sawyer, R. T. 1986. Leech Biology and Behaviour, 1st ed., Oxford University Press, Oxford.
31. Sciacchitano, I. 1931. Sulla presenza della *Limnatis nilotica* in Cirenaica. *Atti Soc. Nat. Mat. Modena* **62**: 43–45.
32. Shirzadeh, E. and Golmohammadi, R. 2012. Eye bleeding due to leech infestation in an ischemic heart-disease patient. *Iran Red Crescent Med J* **14**: 245–247. [Medline]
33. Sket, B. 1968. Zur Kenntnis der Egel-Fauna (Hirudinea) Jugoslaviens. Acad. Sei. Art. Slovenica CL. IV. *Pars Hist. Nat.* **9**: 127–178.
34. Sket, B. and Trontelj, P. 2008. Global diversity of leeches (Hirudinea) in freshwater. *Hydrobiologia* **595**: 129–137. [CrossRef]