

Immunohistochemistry and molecular epidemiology of avian paramyxovirus 1 from formalin-fixed and paraffin-embedded sections of Japanese doves (*Columba livia*) affected with neurological signs

Kikuyasu NAKAMURA^{1)*}, Hideo FUJIMORI²⁾, Akiko KOYAMA²⁾, Trinh Quang DAI³⁾, Kunitoshi IMAI³⁾, Mitsutaka IKEZAWA¹⁾ and Yu YAMAMOTO¹⁾

¹⁾National Institute of Animal Health, 3–1–5 Kannondai, Tsukuba, Ibaraki 305–0856, Japan

²⁾Tokyo Livestock Hygiene Center, 3–19–4 Fujimi-cho, Tachikawa, Tokyo 190–0013, Japan

³⁾Obihiro University of Agriculture and Veterinary Medicine, Inada-cho, Obihiro, Hokkaido 080–8555, Japan

(Received 5 January 2015/Accepted 27 February 2015/Published online in J-STAGE 29 March 2015)

ABSTRACT. Four doves (Nos. 1–4 birds) affected with neurological signs (ataxia, circling and torticollis) were investigated pathologically and microbiologically. Viral isolation was tried from the tracheal and cloacal swabs of all 4 birds and from liver, spleen, kidney, heart, lung and brain of Nos. 1 and 2 birds. No viruses were isolated from 4 birds, but they had high serum antibody titers against avian paramyxovirus 1 (APMV-1). Histologically, they had the characteristic histological changes of pigeon APMV-1 infection; nonpurulent encephalitis and interstitial nephritis. Immunohistochemically, APMV-1 antigens were detected in the necrotic renal tubular epithelial cells of 1 bird of them (No. 3 bird). Detection of APMV-1 ribonucleic acid (RNA) from formalin-fixed and paraffin-embedded (FFPE) sections was attempted by reverse transcription-polymerase chain reaction (RT-PCR). Sequencing the RT-PCR product showed the virus RNA belonged to the same APMV-1 genotype (VI) as the strains isolated from the world previous cases of pigeon APMV-1 infection. The RT-PCR of FFPE sections and sequencing of RT-PCR products are useful for molecular epidemiology of the virus when viral isolation from fresh samples is unsuccessful.

KEY WORDS: dove, formalin-fixed paraffin-embedded section, immunohistochemistry, Newcastle disease virus, PCR

doi: 10.1292/jvms.15-0004; *J. Vet. Med. Sci.* 77(7): 837–841, 2015

Newcastle disease (ND) is a listed disease of World Organization of Animal Health (OIE), one of notifiable infectious avian diseases having a great influence on the international trade. Proper vaccination can control ND in the chickens. ND is defined as an infection of birds caused by a virulent ND virus (avian paramyxovirus 1, APMV-1) [8].

More than 5 years passed since last outbreaks of ND in 2010 in Japan. Surveillances started from 2010 demonstrated no virulent APMV-1 infection was present in the Japanese poultry population. The poultry farms were inspected regularly by prefectural veterinary authority. Therefore, Japanese government declared that Japan was free from ND with vaccination in September 2012 [17]. APMV-1 infects a wide variety of wild birds [8]. They can't be vaccinated for APMV-1. So, APMV-1 infection in wild birds is a threat for poultry. Neurotropic presentation of APMV-1 infection was prevalent among the pigeons in Japan [7] and the world [1, 4, 6, 8] in 1980s. Outbreaks of ND in chickens linked

to pigeons were confirmed in United Kingdom [4]. There are a few reports on histopathology of pigeons infected with APMV-1, although there are many reports on virology of pigeons APMV-1 [1, 4, 6, 8]. Confirmation of characteristic histological changes is important in the diagnosis of pigeon APMV-1 infection. Maeda *et al.* [7] suggested that nonpurulent encephalitis and interstitial nephritis might be characteristic in pigeon ND.

Polymerase chain reaction (PCR) is useful technique of detecting the genes of pathogens in the tissue samples. PCR of fresh samples is very easy and sensitive. The fresh samples are best for PCR. However, PCR from formalin-fixed paraffin-embedded (FFPE) sections is necessary in cases of the unsuitable sampling or retrospective study.

We encountered the doves with neurological signs and nonpurulent encephalitis and interstitial nephritis. However, the viral isolation was unsuccessful. Therefore, we performed immunohistochemistry and reverse transcription-PCR (RT-PCR) of FFPE sections of doves affected with neurological signs. This paper describes the detection of APMV-1 antigen and the genotyping by sequencing of generated RT-PCR products from FFPE samples of doves.

MATERIALS AND METHODS

Birds: Four doves (*Columba livia*) (Nos. 1 to 4) were examined for pathology and microbiology. Nos. 1 and 3 were male, and Nos. 2 and 4 were female. The ages of them were unknown. Probably, Nos. 1 and 2 are adult, and Nos. 3 and

*CORRESPONDENCE TO: NAKAMURA, K., National Institute of Animal Health, 3–1–5 Kannondai, Tsukuba, Ibaraki 305–0856, Japan. Present address: Tokyo Pathological Center, Pathology Department, Drug Safety Research Laboratories, Shin Nippon Biomedical Laboratories, Ltd., St Luke's Tower 12F, 8–1 Akashi-cho, Chuo-ku, Tokyo 104–0044, Japan. e-mail: kikuyasu_nakamura@outlook.jp

©2015 The Japanese Society of Veterinary Science

This is an open-access article distributed under the terms of the Creative Commons Attribution Non-Commercial No Derivatives (by-nc-nd) License <<http://creativecommons.org/licenses/by-nc-nd/3.0/>>.

4 are young, judging from the maturity of productive organs and the ossification of tracheal cartilages.

Virology: Using chicken embryonated eggs, viral isolation was tried from the tracheal and cloacal swabs of all 4 birds and from organ samples of liver, spleen, kidney, heart, lung and brain of Nos. 1 and 2 birds. These swabs and organ samples were examined also for RT-PCR of APMV-1.

Serology: The sera from 4 birds were examined for hemagglutinin inhibition (HI) antibody against APMV-1 [16].

Bacteriology: We tried to isolate the bacteria from the liver, kidney, heart, spleen, lung and brain of Nos. 1 and 2 birds. Nos. 3 and 4 birds were not examined for bacteriology.

Pathology: The doves were euthanized and necropsied. The liver, spleen, kidney, heart, lung, duodenum, pancreas, small intestine, cecum, rectum, gizzard, proventriculus, brain, spinal cord, peripheral nerves, trachea, esophagus, reproductive organs (ovary and testis) and femur were removed and fixed in 10% buffered formalin after a post-mortem examination. The femurs were decalcified in 10% formic acid. All tissue samples were then embedded in paraffin, sectioned at 4 μ m and stained with hematoxylin and eosin (HE).

Immunohistochemistry: The paraffin sections were stained using the immunoperoxidase kit, Histofine Simple Stain PO (M) (Nichirei Inc., Tokyo, Japan) [10]. The primary antibody was a mouse monoclonal antibody against APMV-1 [10] and was used at 1:50,000 dilutions. After staining with 3-amino-9-ethylcarbazole (AEC), the sections were counterstained with hematoxylin.

Reverse transcription-polymerase chain reaction (RT-PCR): The FFPE kidney of No. 3 bird that was positive against APMV-1 antigen by immunohistochemistry was selected. Total RNA was extracted from the FFPE kidney of No. 3 bird using RNeasy[®]FFPE kit (Qiagen, Hilden, Germany). First-strand cDNA was synthesized from the RNA extracted by using random hexamer primers (Invitrogen, Carlsbad, CA, U.S.A.) and M-MLV reverse transcriptase (Invitrogen) under the following conditions: 25°C for 10 min, 37°C for 60 min and 65°C for 10 min. Using the cDNAs as templates, RT-PCR was conducted to amplify the partial Fusion protein gene of APMV-1 by using primers: forward primer (5'-GGT-GAGTCTATCCGGARGATACAAG-3') and reverse primer (5'-TCATTGGTTGCRGCAATGCTCT-3') [5].

The expected size of RT-PCR product is a 202 base pair (bp). The RT-PCR products obtained were separated by 1% agarose gel electrophoresis and purified using a QIAquick PCR Purification Kit (Qiagen).

Nucleotide sequencing and phylogenetic analysis: Sequences of the purified RT-PCR products were investigated by direct sequencing using a BigDye Terminator v3.1 cycle sequencing kit and Applied Biosystems 3500 Genetic Analyzer (Life Technologies, Carlsbad, CA, U.S.A.). Nucleotide sequences obtained in this study were analyzed using GENETYX ver.10 software (GENETYX Corp., Tokyo, Japan) and compared with available sequences of other APMV-1 strains using the BLAST program. The sequences were aligned by Clustal W [15]. A phylogenetic tree was constructed using the Neighbor-Joining method [12], supported

by 1,000 bootstrap replicates. The evolutionary distances were computed using the Tamura-Nei method and are in the units of the number of base substitutions per site. All positions containing alignment gaps and missing data were eliminated in complete deletion (complete deletion option) [13]. Evolutionary analyses were conducted in MEGA5 software [14].

RESULTS

Epidemiology and clinical signs: Four doves (*Columba livia*) having neurological signs, such as ataxia, circling and torticollis (Fig. 1), were detected in the cattle farm in Tokyo in January 2012. They could not fly. Before this event, 20 to 30 doves had wandered off into the cattle pen in December 2011. Six doves of them had been found dead in the pen. These dead birds had not been examined.

Virology: No viruses were isolated from all the samples of 4 birds examined. We could get positive reaction neither by RT-PCR for APMV-1 nor by real time PCR for avian influenza virus from these samples.

Serology: Serum HI antibodies against APMV-1 of Nos. 1 to 4 were 40, 40, 160 and 160, respectively.

Bacteriology: No bacterium was isolated from organs of Nos. 1 and 2 birds examined.

Histology: The common histological lesions of 4 birds were renal and neurological lesions. Moderate lymphocytic interstitial nephritis was in 4 birds. Multifocal lymphocytic infiltration was seen in the interstitium of kidneys (Fig. 2). Occasionally, the necroses of renal tubular epithelial cells were seen within the lymphocytic foci (Fig. 3) in No. 3 bird. Mild to moderate nonpurulent encephalitis, characterized by lymphocytic perivascular cuffing (Fig. 5), were observed in 4 birds. Nematodes (*Tetrameres* sp.) were observed in the distended glandular lumens of proventriculi of Nos. 1, 2 and 4 birds. There were arterial necroses in the liver and arteritis in the brain, and granuloma in the lung of No. 3 bird. Amyloid substances deposited in the interstitium of kidneys of Nos. 2 and 3 birds.

Immunohistochemistry: APMV-1 antigen was localized only in the necrotic renal epithelial cells (Fig. 4) of No. 3 bird. There was no positive reaction against APMV-1 in the organs other than the kidney of No. 3 bird and in all organs of Nos. 1, 2 and 4.

RT-PCR and sequencing: Electrophoretic figure of RT-PCR product of FFPE sections indicated that the RT-PCR product was positive for APMV-1 (Fig. 6). Sequencing and phylogenetic tree analysis of RT-PCR product showed that the APMV-1 of the present case belonged to genotype VI (Fig. 7). The present virus (APMV1/dove/Japan/Tokyo/2012) was distinct from the APMV-1 strains of pigeon APMV-1 infections occurred in Japan in 1980s and 1990s. It was most close to Chinese pigeon strain (APMV1/pigeon/China/JS/07/16/Pi) isolated in 2007 (Fig. 8).

DISCUSSION

There are few reports on histological lesions of pigeons




Fig. 1. Neurological sign of a dove. The dove shows torticollis.

Fig. 2. Multifocal lymphocytic infiltration in the kidney. No. 3 bird. Bar=500 μ m.HE.

Fig. 3. Necrosis of renal tubular epithelial cells (arrows) with lymphocytic infiltration in the kidney. No. 3 bird. Bar=100 μ m.HE.

Fig. 4. ND virus antigens are localized in the necrotic renal tubular epithelia in the kidney. No. 3 bird. Bar=100 μ m. Immunoperoxidase staining.

Fig. 5. Lymphocytic infiltration in perivascular space in the cerebrum. No. 3 bird. Bar=100 μ m.HE.

Fig. 6. Electrophoretic figure of RT-PCR product of FFPE sections. M=marker, S=sample.

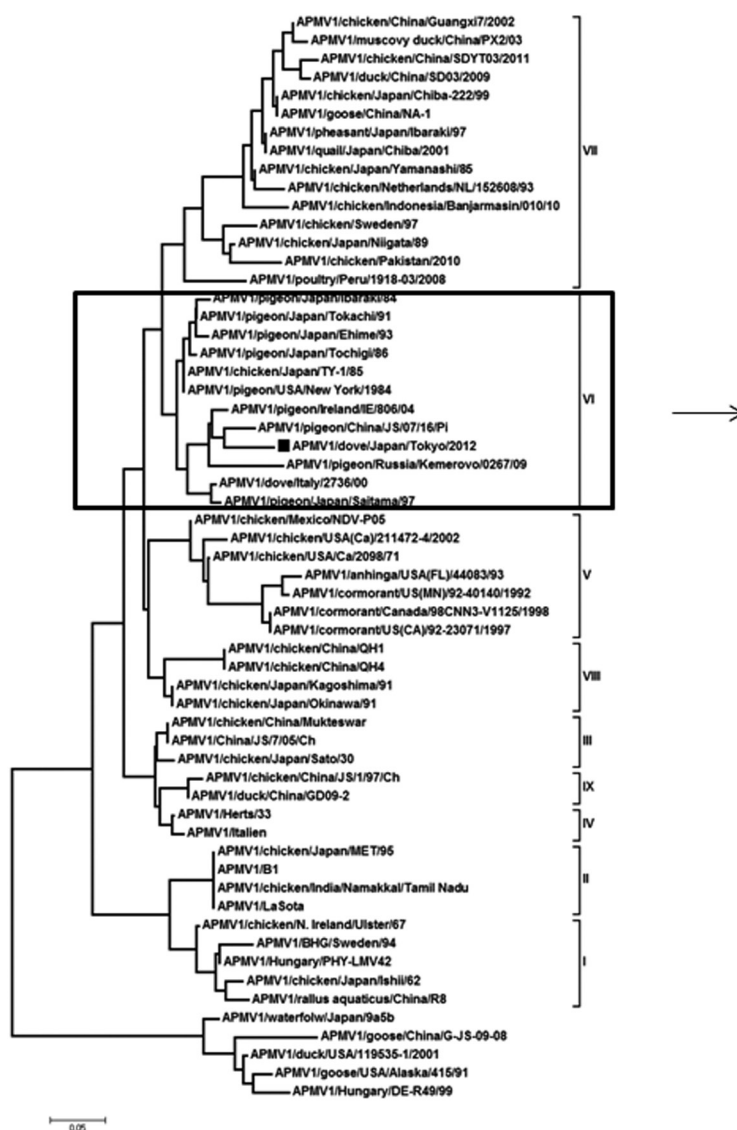


Fig. 7. Phylogenetic tree of APMV-1 strains on the basis of nucleotide sequences of the fusion protein cleavage site. All pigeon strains, including the present strain "APMV1/dove/Japan/Tokyo/2012", are categorized to genotype VI.



Fig. 8. Higher magnification of a part in Fig. 7. The present strain is most closely related to the Chinese strain "APMV1/pigeon/China/JS/07/16/Pi".

infected with APMV-1. The histological lesions observed in this study, nonpurulent encephalitis and interstitial nephritis, are characteristic changes in pigeons infected with APMV-1 [7, 11]. High serum antibody titers against APMV-1, low distribution of APMV-1 antigen and no virus isolation showed that the infectious stage of APMV-1 would be chronic phase. Vascular lesions of No. 3 bird would be associated with APMV-1 infection, because APMV-1 is able to induce the vascular damage [9, 10]. *Tetrameres* sp. infections in proventriculi were often observed in pigeons spontaneously [11]. The histological neurological lesions were mild, although the doves showed severe neurological signs in the present case. This is the character of brain lesions in APMV-1 infection of pigeons [11].

We could not isolate the APMV-1 from the doves affected with severe neurological signs. There are no reports to analyze APMV-1 genotype by PCR and sequencing of the FFPE sections. APMV-1 was neither isolated, and the detailed characterization of the virus was nor evaluated in the present case. Hence, the epidemiology of APMV-1 remains incompletely understood. Phylogenetic tree analysis suggests that the present virus may be originated from China.

Clinical signs, histology, immunohistochemistry and serology strongly indicate the APMV-1 causes the disease in doves. The viral isolation is important for diagnosis and epidemiology of the disease. Viral isolation and RT-PCR for APMV-1 from all fresh samples showed negative results. Fresh samples of the kidney of No. 3 bird were not taken for viral isolation and RT-PCR. However, immunohistochemistry of FFPE sections of kidneys in No. 3 bird showed positive APMV-1 antigen. Therefore, we could detect the APMV-1 RNA by RT-PCR of FFPE sections of the No. 3 bird kidney fortunately. The molecular examination of FFPE sections using PCR and sequencing is useful in the cases of sampling error like the present case.

There are a few outbreaks of ND in the chickens concerning the introduction of APMV-1 from pigeons to chickens. However, APMV-1 from pigeons was prevalent in the chicken flock in United Kingdom in 1984 [4]. The cause was the feedstuff contaminated with droppings from pigeons infected with APMV-1 [3]. Virulence of APMV-1 from pigeons for chickens was increased by passage through chickens [2]. Therefore, we should be careful for ND introduction of pigeons into chicken flocks, although now domestic chickens are free from ND in Japan.

ACKNOWLEDGMENTS. We thank Mr. M. Kobayashi and Miss M. Shimada, National Institute of Animal Health, for histological and immunohistochemical assistance.

REFERENCES

1. Aldous, E. W., Fuller, C. M., Mynn, J. K. and Alexander, D. J. 2004. A molecular epidemiological investigation of isolates of the variant avian paramyxovirus type 1 virus (PPMV-1) responsible for the 1978 to present panzootic in pigeons. *Avian Pathol.* **33**: 258–269. [Medline] [CrossRef]
2. Alexander, D. J. and Parsons, G. 1984. Avian paramyxovirus type 1 infections of racing pigeons: 2 pathogenicity experiments in pigeons and chickens. *Vet. Rec.* **114**: 466–469. [Medline] [CrossRef]
3. Alexander, D. J., Parsons, G. and Marshall, R. 1984. Infections of fowls with Newcastle disease virus by food contaminated with pigeon faeces. *Vet. Rec.* **115**: 601–602. [Medline]
4. Alexander, D. J., Russel, R. H. and Collins, M. S. 1984. Paramyxovirus type 1 infections of racing pigeons: 1. Characterization of isolated viruses. *Vet. Rec.* **114**: 444–446. [Medline] [CrossRef]
5. Creelan, J. L., Graham, D. A. and McCullough, S. J. 2002. Detection and differentiation of pathogenicity of avian paramyxovirus serotype 1 from field cases using one-step reverse transcriptase-polymerase chain reaction. *Avian Pathol.* **31**: 493–499. [Medline] [CrossRef]
6. Guo, H., Liu, X., Han, Z., Shao, Y., Chen, J., Zhao, S., Kong, X. and Liu, S. 2013. Phylogenetic analysis and comparison of eight strains of pigeon paramyxovirus type 1 (PPMV-1) isolated in China between 2010 and 2012. *Arch. Virol.* **158**: 1121–1131. [Medline] [CrossRef]
7. Maeda, M., Koizumi, S., Yachi, M., Iwasaki, M. and Okuda, T. 1987. Histological changes in Newcastle disease affecting racing pigeons in Japan. *Jpn. J. Vet. Sci.* **49**: 217–223. [Medline] [CrossRef]
8. Miller, P. J. and Koch, G. 2013. Newcastle disease. pp. 89–107. In: Diseases of Poultry, 13th ed. (Swayne, D. E., Glisson, J. R., McDougald, L. R., Nolan, L. K., Suarez, D. L. and Nair, V. L. eds.), John Wiley and Sons, Inc., Ames.
9. Nakamura, K., Ohta, Y., Abe, Y., Imai, K. and Yamada, M. 2004. Pathogenesis of conjunctivitis caused by Newcastle disease viruses in specific-pathogen-free chickens. *Avian Pathol.* **33**: 371–376. [Medline] [CrossRef]
10. Nakamura, K., Ohtsu, N., Nakamura, T., Yamamoto, Y., Yamada, M., Mase, M. and Imai, K. 2008. Pathologic and immunohistochemical studies of Newcastle disease (ND) in broiler chickens vaccinated with ND: severe nonpurulent encephalitis and necrotizing pancreatitis. *Vet. Pathol.* **45**: 928–933. [Medline] [CrossRef]
11. Randall, C. J. and Reece, R. L. 1996. pp. 26, 58 and 138. Color Atlas of Avian Histopathology. Mosby-Wolfe, London.
12. Saitou, N. and Nei, M. 1987. The neighbor-joining method: A new method for reconstructing phylogenetic trees. *Mol. Biol. Evol.* **4**: 406–425. [Medline]
13. Tamura, K. and Nei, M. 1993. Estimation of the number of nucleotide substitutions in the control region of mitochondrial DNA in humans and chimpanzees. *Mol. Biol. Evol.* **10**: 512–526. [Medline]
14. Tamura, K., Peterson, D. N., Peterson, G., Stecher, M., Nei, M. and Kumar, S. 2011. MEGA5: molecular evolutionary genetics analysis using maximum likelihood, evolutionary distance, and maximum parsimony methods. *Mol. Biol. Evol.* **28**: 2731–2739. [Medline] [CrossRef]
15. Thompson, J. D., Higgins, D. G. and Gibson, T. J. 1994. CLUSTAL W: improving the sensitivity of progressive multiple sequence alignment through sequence weighting, position-specific gap penalties and weight matrix choice. *Nucleic Acids Res.* **22**: 4673–4680. [Medline] [CrossRef]
16. World Organization for Animal Health (OIE). 2009. Chapter 2.3.14. Newcastle disease. pp. 576–589. In: Manual of Diagnostic Tests and Vaccines for Terrestrial Animals 2009. World Organization for Animal Health (OIE), Paris.
17. World Organization for Animal Health (OIE). 2012. Self-declaration from Japan on the recovery of its Newcastle disease-free status. pp. 83–85. In: Bulletin No.2012–4. World Organization for Animal Health (OIE), Paris.