

## Infectivity of *Cryptosporidium andersoni* and *Cryptosporidium muris* to Normal and Immunosuppressive Cynomolgus Monkeys

Koichi MASUNO<sup>1,2</sup>, Yasuhiro FUKUDA<sup>3</sup>, Masahito KUBO<sup>2,4</sup>, Ryo IKARASHI<sup>3</sup>, Takeshi KURAISHI<sup>5</sup>, Shosaku HATTORI<sup>5</sup>, Junpei KIMURA<sup>6</sup>, Chieko KAI<sup>5</sup>, Tokuma YANAI<sup>2</sup> and Yutaka NAKAI<sup>3</sup>\*

<sup>1</sup>)Drug Developmental Research Laboratories, Shionogi & Co., Ltd., 3-1-1, Futaba-Cho, Toyonaka, Osaka 561-0825, Japan

<sup>2</sup>)Veterinary Medicine, Gifu University, 1-1 Yanagido, Gifu, Gifu 501-1194, Japan

<sup>3</sup>)Laboratory of Sustainable Environmental Biology, Graduate School of Agricultural Science, Tohoku University, Naruko-Onsen, Osaki, Miyagi 989-6711, Japan

<sup>4</sup>)Laboratory of Veterinary Pathology, Yamaguchi University, 1677-1 Yoshida, Yamaguchi-City, Yamaguchi 753-8511, Japan

<sup>5</sup>)The Institute of Medical Science, The University of Tokyo, 4-6-1 Shirogane-dai, Minato-ku, Tokyo 108-8639, Japan

<sup>6</sup>)Korea Secretary General of Asian Society of Zoo and Wildlife Medicine, College of Veterinary Medicine, Seoul National University, Seoul 151-742, Korea

(Received 9 July 2013/Accepted 24 September 2013/Published online in J-STAGE 16 October 2013)

**ABSTRACT.** *Cryptosporidium andersoni* and *Cryptosporidium muris* infections have been found in the mice and/or cattle. The oocysts of *C. andersoni* and *C. muris* have been sporadically detected in human feces, but the infectious capacity and features have been unknown, because of the scarcity of reports involving human infections. To assess the infectivity and the clinical and pathological features of *C. andersoni* and *C. muris* in primates, an experimental infectious study was conducted using cynomolgus monkeys. The monkeys were orally inoculated with oocysts of two different *C. andersoni* Kawatabi types and *C. muris* RN-66 under normal and immunosuppressive conditions. The feces of the monkeys were monitored for about 40 days after the administration of oocysts using the flotation method, but no shedding oocysts were observed under either both normal or immunosuppressive conditions. Gross and histopathological examinations were performed on the immunosuppressive monkeys, but these revealed no evidence of *Cryptosporidium* infections, even though the monkeys were subjected to immunosuppressive conditions. It is hypothesized that *C. andersoni* and *C. muris* pose little danger of infection in primates even under immunosuppressive conditions.

**KEY WORDS:** *Cryptosporidium*, experimental animals, monkey, parasitology, pathology.

doi: 10.1292/jvms.13-0350; *J. Vet. Med. Sci.* 76(2): 169–172, 2014

*Cryptosporidium* (Apicomplexa: Cryptosporidiidae) causes emergent diarrhea and/or abdominal pain in both immunocompetent and immunocompromised patients, as well as in agriculturally important livestock species. In normal healthy animals, *Cryptosporidium parvum* is known to develop as a self-limiting infection localized to the intestinal tract [4]. In immunocompromised animals, infection by this protozoan is potentially life-threatening and may involve extraintestinal organs, such as the trachea, lungs, bile ducts and pancreas [3, 4, 23].

Since the first report of Cryptosporidiosis in humans, it has been recognized that only one species, *C. parvum*, poses a risk of infection to humans. However, based on analysis of the antigen and housekeeping gene, *C. parvum* was classified into two genotypes; type I and type II. Type I can infect only humans, and it has been named "*C. hominis*". Type II

can infect many kinds of animals, including humans, and it has been named "*C. parvum*". Most Cryptosporidiosis in humans are caused by these two species of *Cryptosporidium*.

In one report, 2,414 human feces samples were investigated, and *C. parvum* was detected in 1,354 samples (56.1%), *C. hominis* in 1,005 samples (41.7%) and both *C. parvum* and *C. hominis* in 21 samples (0.9%) [11]. In another report, 7,758 human feces samples were investigated, and *C. parvum* was detected in 3,564 samples (45.9%), *C. hominis* in 3,814 samples (49.2%) and both *C. parvum* and *C. hominis* in 40 samples (0.5%) [1]. On the strength of these studies, it was considered that *C. parvum* and *C. hominis* cause Cryptosporidiosis in humans in most cases. However, in these and other studies, other species of *Cryptosporidium* (*C. meleagridis*, *C. felis*, *C. canis*, *C. suis*, *C. muris* and *C. andersoni*) were also detected [1, 11, 16, 20].

Although the major hosts of *C. meleagridis*, *C. felis*, *C. canis*, *C. suis*, *C. muris* and *C. andersoni* are various animals (Table 1), some of those protozoa can cause Cryptosporidiosis in humans and it occasionally proves fatal [14, 22]. However, some earlier investigations may have detected only the elimination of oocysts, which may not suggest evidence of intestinal infection of *Cryptosporidium*.

A number of drugs, among them nitazoxanide, have been suggested to be effective in both animal models and clinical trials. These drugs improved diarrhea and decreased

\*CORRESPONDENCE TO: NAKAI, Y., Laboratory of Sustainable Environmental Biology, Graduate School of Agricultural Science, Tohoku University, Naruko-Onsen, Osaki, Miyagi 989-6711, Japan. e-mail: nakai@bios.tohoku.ac.jp

©2014 The Japanese Society of Veterinary Science

This is an open-access article distributed under the terms of the Creative Commons Attribution Non-Commercial No Derivatives (by-nc-nd) License <<http://creativecommons.org/licenses/by-nc-nd/3.0/>>.

Table 1. Major host of *Cryptosporidium* spp.

Species of <i>Cryptosporidium</i>	Major host
<i>C. parvum</i>	Cattle, sheep, goats, humans
<i>C. hominis</i>	Humans, monkeys
<i>C. meleagridis</i>	Turkeys, humans
<i>C. felis</i>	Feline
<i>C. canis</i>	Canine
<i>C. suis</i>	Swine
<i>C. muris</i>	Rodents, bactrian camels
<i>C. andersoni</i>	Cattle, bactrian camels

Table 2. Information of animal in both experimental infections

Animal No.	Sex	Origin	Treatment ( <i>Cryptosporidium</i> spp.)	Number of dosed oocysts
1	Male	Japan	<i>C. andersoni</i> K strain	10 <sup>6</sup>
2	Female	China	<i>C. andersoni</i> K strain	10 <sup>6</sup>
3	Female	China	<i>C. andersoni</i> A strain	10 <sup>7</sup>
4	Male	Indonesia	<i>C. andersoni</i> A strain	10 <sup>7</sup>
5	Male	Indonesia	<i>C. muris</i> RN66 strain	10 <sup>7</sup>
6	Male	Indonesia	<i>C. muris</i> RN66 strain	10 <sup>7</sup>
7	Female	Japan	—	—

Same seven monkeys were used in the normal and immunosuppressive experiments.

mortality rates in patients in poor condition [3, 5]. However, Cryptosporidiosis in humans is still important from a public health standpoint, and further investigation is needed [2].

In natural infection, *C. andersoni* has been found to have infected the abomasum with fecal excretion of oocysts in cattle, and *C. muris* has been found to have infected the stomach in mice [9, 10, 17]. Although affected cattle exhibit no apparent clinical signs, severe infections of *C. andersoni* can be identified in the abomasum by microscopy [12]. Experimental infectious studies of *C. muris* and *C. andersoni* Kawatabi type have been reported in SCID mice [6, 8, 21].

A large number of species of experimental animals exist, and simians are known to be closely related to humans as a species. In many kinds of infectious diseases, the clinical and pathologic conditions of humans can be reproduced in simians.

To our knowledge, there have been no reports on experimental studies of *C. muris* or *C. andersoni* infection in simians. We assessed the infectivity of *C. muris* and *C. andersoni* using cynomolgus monkeys under normal and immunosuppressive conditions.

## MATERIALS AND METHODS

**Experimental conditions:** After being quarantined, four male and three female cynomolgus monkeys (*Macaca fascicularis*) were housed individually in stainless steel cages in a controlled environment that was air conditioned at 28 ± 2°C with relative humidity of 55 ± 30% and a 12 hr/hr light-dark cycle. Throughout the study, the animals were fed a commercial diet (CMK-2; Clea Japan Inc., Tokyo, Japan) twice daily at 09.00 hr and 16.00 hr, and drinking water was

provided *ad libitum*. The origins of the monkeys were as follows; two females were born in China, three males were born in Indonesia and one male and one female were born in Japan (Table 2). Scatocopy and PCR analysis of all simian feces were performed in order to confirm that the animals were free of *Cryptosporidium* infection at the initiation of the study. They were handled and treated in accordance with the Regulations for Animal Care and Use of the University of Tokyo. The experimental protocol was approved by the Experimental Animal Committee at the Institute of Medical Science at the University of Tokyo (approval number: 20-54).

**Protozoa:** Two different strains of *C. andersoni* Kawatabi types and one *C. muris* strain (RN-66) were used to induce the experimental infection. In the *C. andersoni* Kawatabi types, K strain and A strain were applied. The former strain was originally established from grazing cattle on the experiment farm belonging to Tohoku university [8, 21], and the latter was newly established from cattle feces on a farm in Aomori Prefecture (Japan). *C. muris* RN-66 was originally isolated from a house rat strain [6]. The strains were successfully subcultured using SCID mice in our laboratory [6, 13, 21]. The oocysts were administered to the monkeys within one month of collection.

**Normal animals:** Seven cynomolgus monkeys (control; n=1, infected; n=6) were orally inoculated with purified fresh oocysts by means of pelletized meals. The treatments were as follows: 10<sup>6</sup> oocysts of the *C. andersoni* K strain were administered to animal Nos. 1 and 2, 10<sup>7</sup> oocysts of the *C. andersoni* A strain were administered to animal Nos. 3 and 4, 10<sup>7</sup> oocysts of the *C. muris* RN-66 strain were administered to animal Nos. 5 and 6 and no oocysts were administered to animal No. 7 (Table 2). For the administration, water containing the oocysts was poured on two pellets of the meal, air-dried and fed to the monkeys which had been kept under fasting conditions, as soon as possible, and it was confirmed that the monkeys ate the pellets (Fig. 1). The feces of the monkeys were collected into a tube containing 2.5% dichromic acid and were monitored from Days 2 to 40 of the study period to observe the shedding of oocysts by the flotation method. The monkeys were not sacrificed and were used again in later experiments.

**Immunosuppressive animals:** The same seven cynomolgus monkeys were used in the next experiment targeting immunosuppressive animals, and an attempt was made to infect the animals using the same method (Table 2). Before and between this study, monkeys were administered steroids to induce an immunodeficient condition. From 11 days before the study began until Day 10, once every seven days (Days -11, -4, 3 and 10), 10 mg/kg of methyl-prednisolone (Pfizer, New York, NY, U.S.A.) was administered intramuscularly under anesthesia, and 5 mg/kg of methyl-prednisolone was also administered once every seven days (Days 17, 24, 31 and 38) to maintain immunodeficiency. The feces of the monkeys were also collected in a tube containing 2.5% bi-chromic acid and monitored almost every day (from Days -11 to 40 of the study period, except for Days 1, 2 and 3) to observe the shedding of oocysts by the flotation method.



Fig. 1. Oocysts contained pellets were fed to the fasted monkeys.

On Day 44 or 45, all monkeys were euthanized by exsanguination by cutting both the posterior aorta and vena cava under anesthesia, and complete necropsy was done. Organs and tissues, including the liver, pancreas, spleen, kidneys, urinary bladder, adrenal glands, heart, lungs, trachea, thyroid glands, brain, testes, epididymis, prostate, seminal vesicle, esophagus, stomach (fundic and pyloric parts), duodenum, jejunum, ileum, cecum, colon, mesenteric lymph node, sternum (including bone marrow) and femur (including bone marrow) were collected and fixed in 10% neutral buffered formalin. After the fixation, to decalcify the sternum and femur, these tissues were macerated in formalin solution with formic acid. The fixed organs/tissues were routinely processed and embedded in paraffin, and paraffin sections were stained with hematoxylin and eosin and examined microscopically.

## RESULTS

*Normal animals:* No clinical signs or oocysts were detected in any of the animals at any point. Therefore, none of the monkeys were necropsied, and all were used in the immunosuppressive study.

*Immunosuppressive animals:* These animals were also free of clinical signs and oocysts at all time. No remarkable changes were observed in macroscopic observations.

In histopathological examination, chronic gastritis was observed in monkey Nos. 1, 2, 4, 5, 6 and 7. However, no infection by *Cryptosporidium* was seen in any of the organs or tissues, including any parts of the stomach. There were decreases in the number and size of the germinal center in the spleen, mesenteric lymph node and mucosal associated lymphoid tissue of the gastrointestinal tract (Fig. 2-1). The lymphoid tissues were compared with normal monkeys in histopathological sections of historical controls (Fig. 2-2). In addition, there were spirillum infections in the gastric pits of the stomach in three animals in the infectious groups.

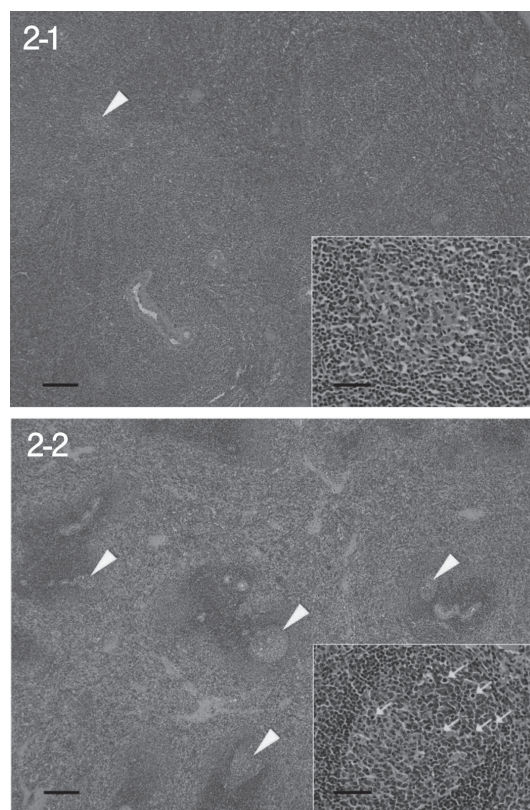


Fig. 2. 1) Germinal centers (arrowhead) of the spleen were seldom detected in the methyl-prednisolone treated animal. The size of germinal center was decreased, and few mitoses were observed. Animal no. 7, HE stain, bar: 20  $\mu$ m (inset: 5  $\mu$ m). 2) Some germinal centers (arrowheads) of the spleen were detected. The size of germinal center was normal, and many mitotic figures (arrows) were observed. Intact control animal in other study, HE stain, bar: 20  $\mu$ m (inset: 5  $\mu$ m).

## DISCUSSION

None of the normal or immunosuppressive monkeys exhibited clinical signs or oocysts at any point. It is suspected that they were not infected with *C. andersoni* or *C. muris*.

The monkeys were administered *Cryptosporidium* oocysts orally with the number of oocysts being  $10^6$  or  $10^7$ . These oocysts should have had infectious capacity, because the same method, oral administration, has been used in most other studies, including our previous studies [6, 21], and experimental infection of *Cryptosporidium* was successfully induced in the other studies. In addition, the number of the oocysts was sufficient for the transmission of infection [19].

In this study, the oocysts were added to the pellet meal and air-dried. Although it is well known that *Cryptosporidium* oocysts are capable of transmitting an infection under dry conditions [18], this process may have weakened of infectious capacity.

Methyl-prednisolone was administered intramuscularly.



Histopathological examination revealed decreases in the germinal center in the lymphoid tissues. Glucocorticoid suppresses the cells of the germinal center [7], and it is considered that methyl-prednisolone administration caused this atrophic change in the lymphoid tissue in the present study. In addition, there were spirillum infections. This bacterium has occasionally been observed in monkeys fed under conventional conditions, but the incidence seemed to be greater than in other studies. These results may possibly prove the evidence of immunosuppressive conditions in monkeys, and it was suspected that the dose level of methyl-prednisolone was high enough to produce immunocompromised animals. However, no hematological examination or serum cytokine analysis was conducted, and there were no intact control animals that could be compared to the dosed monkeys in the same study. Consequently, it is difficult to conclude that the monkeys were completely immunocompromised.

One report suggested that there are some mouse strains that have been resistant to infection by *C. muris* and *C. andersoni* [15]. A similar mechanism may exist in primates; cynomolgus monkeys may be resistant to gastric *Cryptosporidium* infection, but this hypothesis is considered unlikely.

Our present study suggests that *C. andersoni* Kawatabi types and *C. muris* were not able to infect the targeted animal species, namely monkey, even though natural hosts can be infected under normal condition. Possibly, *C. andersoni* and *C. muris* have no means for establishing infections in human.

In conclusion, *C. andersoni* and *C. muris* pose little danger of infection in primates even under immunosuppressive conditions.

## REFERENCES

- Chalmers, R. M., Elwin, K., Thomas, A. L., Guy, E. C. and Mason, B. 2009. Long-term *Cryptosporidium* typing reveals the aetiology and species-specific epidemiology of human cryptosporidiosis in England and Wales, 2000 to 2003. *Euro. Surveill.* **14**: 1–9. [Medline]
- Corso, P. S., Kramer, M. H., Blair, K. A., Addiss, D. G., Davis, J. P. and Haddix, A. C. 2003. Cost of illness in the 1993 waterborne *Cryptosporidium* outbreak, Milwaukee, Wisconsin. *Emerg. Infect. Dis.* **9**: 426–431. [Medline] [CrossRef]
- Davies, A. P. and Chalmers, R. M. 2009. Cryptosporidiosis. *B. M. J.* **339**: 963–967. [CrossRef]
- Fayer, R. 1997. *Cryptosporidium* and Cryptosporidiosis, CRC Press, Florida.
- Gargala, G. 2008. Drug treatment and novel drug target against *Cryptosporidium*. *Parasite* **15**: 275–281. [Medline] [CrossRef]
- Hikosaka, K. and Nakai, Y. 2005. A novel genotype of *Cryptosporidium muris* from large Japanese field mice, *Apodemus speciosus*. *Parasitol. Res.* **97**: 373–379. [Medline] [CrossRef]
- Holder, M. J., Knox, K. and Gordon, J. 1992. Factors modifying survival pathways of germinal center B cells. Glucocorticoids and transforming growth factor-beta, but not cyclosporin A or anti-CD19, block surface immunoglobulin-mediated rescue from apoptosis. *Eur. J. Immunol.* **22**: 2725–2728. [Medline] [CrossRef]
- Ikarashi, M., Fukuda, Y., Honma, H., Kasai, K., Kaneta, Y. and Nakai, Y. 2013. First description of heterogeneity in 18S rRNA genes in the haploid genome of *Cryptosporidium andersoni* Kawatabi type. *Vet. Parasitol.* (in press). [Medline] [CrossRef]
- Kaneta, Y. and Nakai, Y. 1998. Survey of *Cryptosporidium* oocysts from adult cattle in a slaughter house. *J. Vet. Med. Sci.* **60**: 585–588. [Medline] [CrossRef]
- Koyama, Y., Satoh, M., Maekawa, K., Hikosaka, K. and Nakai, Y. 2005. Isolation of *Cryptosporidium andersoni* Kawatabi type in a slaughterhouse in the northern island of Japan. *Vet. Parasitol.* **130**: 323–326. [Medline] [CrossRef]
- Leoni, F., Amar, C., Nichols, G., Pedraza-Díaz, S. and McLaughlin, J. 2006. Genetic analysis of *Cryptosporidium* from 2414 humans with diarrhoea in England between 1985 and 2000. *J. Med. Microbiol.* **55**: 703–707. [Medline] [CrossRef]
- Masuno, K., Yanai, T., Hirata, A., Yonemaru, K., Sakai, H., Satoh, M., Masegi, T. and Nakai, Y. 2006. Morphological and immunohistochemical features of *Cryptosporidium andersoni* in cattle. *Vet. Pathol.* **43**: 202–207. [Medline] [CrossRef]
- Masuno, K., Yanai, T., Sakai, H., Satoh, M., Kai, C. and Nakai, Y. 2013. Pathological features of *Cryptosporidium andersoni*-induced lesions in SCID mice. *Exp. Parasitol.* **134**: 381–383. [Medline] [CrossRef]
- Matos, O., Alves, M., Xiao, L., Cama, V. and Antunes, F. 2004. *Cryptosporidium felis* and *C. meleagridis* in persons with HIV, Portugal. *Emerg. Infect. Dis.* **10**: 2256–2257. [Medline] [CrossRef]
- Modrý, D., Hofmannová, L., Antalová, Z., Sak, B. and Kváč, M. 2012. Variability in susceptibility of voles (Arvicolinae) to experimental infection with *Cryptosporidium muris* and *Cryptosporidium andersoni*. *Parasitol. Res.* **111**: 471–473. [Medline] [CrossRef]
- Morse, T. D., Nichols, R. A., Grimason, A. M., Campbell, B. M., Tembo, K. C. and Smith, H. V. 2007. Incidence of cryptosporidiosis species in paediatric patients in Malawi. *Epidemiol. Infect.* **135**: 1307–1315. [Medline] [CrossRef]
- Nakai, Y., Hikosaka, K., Sato, M., Sasaki, T., Kaneta, Y. and Okazaki, N. 2004. Detection of *Cryptosporidium muris* type oocysts from beef cattle in a farm and from domestic and wild animals in and around the farm. *J. Vet. Med. Sci.* **66**: 983–984. [Medline] [CrossRef]
- Nasser, A. M., Tweto, E. and Nitzan, Y. 2007. Die-off of *Cryptosporidium parvum* in soil and wastewater effluents. *J. Appl. Microbiol.* **102**: 169–176. [Medline] [CrossRef]
- Okhuysen, P. C., Chappell, C. L., Crabb, J. H., Sterling, C. R. and DuPont, H. L. 1999. Virulence of three distinct *Cryptosporidium parvum* isolates for healthy adults. *J. Infect. Dis.* **180**: 1275–1281. [Medline] [CrossRef]
- Robinson, G., Elwin, K. and Chalmers, R. M. 2008. Unusual *Cryptosporidium* genotypes in human cases of diarrhea. *Emerg. Infect. Dis.* **14**: 1800–1802. [Medline] [CrossRef]
- Satoh, M., Hikosaka, K., Sasaki, T., Suyama, Y., Yanai, T., Ohta, M. and Nakai, Y. 2003. Characteristics of a novel type of bovine *Cryptosporidium andersoni*. *Appl. Environ. Microbiol.* **69**: 691–692. [Medline] [CrossRef]
- Xiao, L., Fayer, R., Ryan, U. and Upton, S. J. 2004. *Cryptosporidium* taxonomy: recent advances and implications for public health. *Clin. Microbiol. Rev.* **17**: 72–97. [Medline] [CrossRef]
- Yanai, T., Chalifoux, L. V., Mansfield, K. G., Lackner, A. A. and Simon, M. A. 2000. Pulmonary cryptosporidiosis in simian immunodeficiency virus-infected rhesus macaques. *Vet. Pathol.* **37**: 472–475. [Medline] [CrossRef]