

## NOTE

# Spontaneous Recovery from Hypopituitarism in a Man with Lymphocytic Hypophysitis: A Case Report

HIROSHI NOTO, KAZUHISA TSUKAMOTO, SHUHEI HAYASHI, KOJI TAKANO\*, TOSHIRO FUJITA\* AND SATOSHI KIMURA

*Department of Diabetes and Metabolism, Tokyo University Hospital, Hongo, Bunkyo-ku, Tokyo 113–8655, Japan*

*\* Department of Nephrology and Endocrinology, Tokyo University Hospital 7–3–1 Hongo, Bunkyo-ku, Tokyo 113–8655, Japan*

**Abstract.** A 50-year-old man presented with hypopituitarism and a pituitary lesion on magnetic resonance imaging scan. He was diagnosed as having lymphocytic hypophysitis, and replacement therapy with hydrocortisone and thyroxine was started. He regained normal pituitary function after 10 months. Reports of spontaneous recovery from lymphocytic hypophysitis in men are rare. While the natural history of lymphocytic hypophysitis remains elusive and its management is not well established, our report shows that spontaneous resolution may occur with steroid supplementation even in men.

**Key words:** Lymphocytic hypophysitis, Hypopituitarism

(*Endocrine Journal* 48: 483–486, 2001)

**LYMPHOCYTIC** hypophysitis is an inflammatory disease of the pituitary gland predominantly affecting women at the end of gestation or during early postpartum. It is occasionally associated with other autoimmune diseases and antipituitary antibodies. These facts suggest an autoimmune pathogenesis [1]. Although it has been reported with increasing frequency, its natural history is variable and its management is controversial. It used to be treated with surgical removal of the lesion leading to severe endocrinological deficiencies. Use of corticosteroid is often recommended when lymphocytic hypophysitis is suspected, but optimal duration of treatment and doses of corticosteroid are unknown.

Spontaneous recovery of the pituitary function has been addressed in several female cases whereas

reports of spontaneous recovery in men have been extremely rare in the medical literature [2]. We describe a male patient with hypopituitarism highly suggestive of lymphocytic hypophysitis who recovered spontaneously.

## Case Report

A 50-year-old man with no known past medical history presented with progressive fatigue, depression, appetite loss, cold intolerance, decreased libido, and impotence for 2 weeks. He did not report weakness, weight loss, constipation, headache, or visual disturbances.

The patient was a pale, depressed man with a sparse beard. His blood pressure was 102/64 mmHg without orthostatic changes. Skin turgor was normal and there was no edema on his legs. Axillary and pubic hair were preserved. Testes were 10 ml in volume (normal: >15 ml). Neurological examination was normal and visual fields were intact.

Received: January 5, 2001

Accepted: April 23, 2001

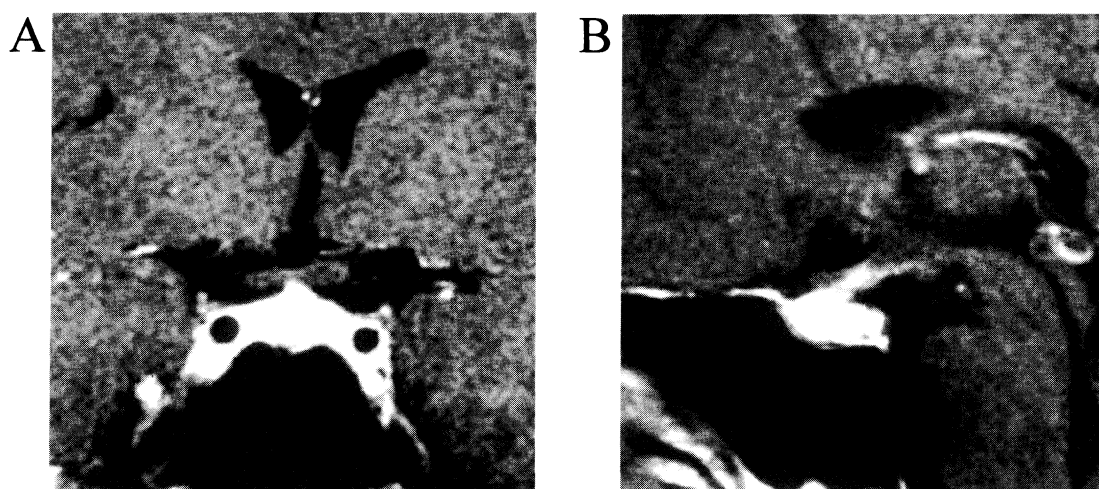
Correspondence to: Hiroshi NOTO, M.D., Department of Diabetes and Metabolism, Tokyo University Hospital, 7–3–1 Hongo, Bunkyo-ku, Tokyo 113–8655, Japan

Laboratory studies included a normal complete blood count and white blood differential counts, sodium 140 mEq/l, potassium 3.8 mEq/l, calcium 8.9 mg/dl, glucose 93 mg/dl, CRP <0.3 mg/dl, ESR 21 mm/h, angiotensin-converting enzyme 18.4 IU/l (normal: 8.3–21.4 IU/l). Viral antibodies were as follows: viral capsid antigen (VCA)-IgG 1:160, VCA-IgM negative, early antigen-IgG negative, Epstein-Barr virus-determined nuclear antigen negative, rubella-IgG negative, rubella-IgM 0.03 ng/ml, and measles-IgM 0.13 ng/ml. Rapid plasma reagin test was negative. Purified protein dermoreaction skin test was positive (status post bacillus Calmette-Guerin vaccination). Chest radiograph was normal. Magnetic resonance imaging (MRI) scan revealed a slightly enlarged pituitary gland with early diffuse homogeneous uptake of gadolinium contrast medium and slightly swollen stalk; the posterior lobe was not well visualized and no enhancement was seen in dura, diaphragm of sella, or cavernous sinus (Fig. 1). We did not perform surgical exploration of the pituitary gland because the MRI findings were consistent with lymphocytic hypophysitis and there was no mass effect.

Endocrinological evaluation revealed panhypopituitarism with free thyroxine (fT<sub>4</sub>) 0.40 ng/dl (normal: 0.91–1.82 ng/dl), free triiodothyronine (fT<sub>3</sub>) 4.4 pg/ml (normal: 2.7–5.5 pg/ml), TSH 0.08  $\mu$ U/ml (normal: 0.57–4.00  $\mu$ U/ml), morning ACTH 12 pg/ml (normal: 9–52 pg/ml), cortisol 1.0  $\mu$ g/dl (nor-

mal: 5.0–15.0  $\mu$ g/dl), GH 0.80 ng/ml (normal: <1.46 ng/ml), insulin-like growth factor-I 120 ng/ml (normal: 43–178 ng/ml), testosterone less than 5 ng/dl (normal: 270–1070 ng/dl), LH 1.0 mIU/ml (normal: 1.1–8.8 mIU/ml), FSH 5.8 mIU/ml (normal: 1.8–13.6 mIU/ml), PRL 6.0 ng/ml (normal: 1.5–9.7 ng/ml), and ADH 1.0 pg/ml (normal: 0.3–4.2 pg/ml). Peak value of cortisol following intramuscular administration of cosyntropin (250  $\mu$ g) was 3.7  $\mu$ g/dl (normal: >18.0  $\mu$ g/dl). Insulin tolerance test demonstrated no responses of ACTH and GH, low and delayed responses of cortisol; the dual stimulation test with TRH and gonadotropin-releasing hormone (GnRH) showed low and delayed responses of TSH and LH, normal responses of PRL and FSH (Table 1). None of the antibodies were detected against nucleus, thyroglobulin, microsome, TSH-receptor, adrenals (indirect fluorescent antibody assay), pituitary gland (indirect fluorescent antibody assay), gastric parietal cells (fluorescent antibody assay), mitochondria, and smooth muscles.

Based on a presumptive diagnosis of hypopituitarism secondary to lymphocytic hypophysitis, he was started on replacement therapy with thyroxine 50  $\mu$ g/day and hydrocortisone 20 mg/day. Subsequently, his initial complaints started to ameliorate. Since his urine output increased to 2,900 ml/day, masked diabetes insipidus was suspected and a water deprivation test was done. After the test, urinary osmolality increased to 800 mOsm/kg.



**Fig. 1.** (A) Coronal and (B) sagittal brain T<sub>1</sub>-weighted MRI scan after intravenous administration of gadolinium, showing a lesion in the pituitary gland with slightly thickened stalk.

**Table 1.** Endocrinological investigations: insulin (0.1 U/kg), TRH (500 µg), and GnRH (100 µg) were given intravenously.

	0 min	30 min	60 min	120 min
Insulin tolerance test				
Cortisol (µg/dl)	2.3	2.6	2.8	3.2
ACTH (pg/ml)	15	14	16	19
GH (ng/ml)	1.54	1.14	1.15	1.36
Glucose (mg/dl)	97	43	85	92
TRH, GnRH stimulation test				
TSH (µU/ml)	0.02	0.18	0.24	0.12
PRL (ng/ml)	11.0	22.0	19.0	15.0
LH (mIU/ml)	<2.0	6.1	8.4	9.1
FSH (mIU/ml)	8.3	12.0	18.0	24.6

He gradually regained his usual states of beard growth and sexual function within four months. Levels of fT<sub>4</sub>, fT<sub>3</sub>, ACTH, and cortisol gradually improved as well, and replacement therapy was tapered off over the course of nine months. One month after the end of treatment, his basal endocrinological data were as follows: fT<sub>4</sub> 1.10 ng/dl, fT<sub>3</sub> 2.7 pg/ml, TSH 0.73 µU/ml, morning ACTH 38 pg/ml, cortisol 11.0 µg/dl, GH 0.27 ng/ml, testosterone 232 ng/dl, LH 6.4 mIU/ml, FSH 12.0 mIU/ml, and PRL 5.0 ng/ml. Stimulation with intramuscular cosyntropin (250 µg) showed an improved cortisol response with the peak value of 19.0 µg/dl. He refused to undergo repeated MRI scan because of worsened claustrophobia. He has been well for 10 months without further medication.

## Discussion

The present patient presented with hypopituitarism and a pituitary lesion on MRI scan. Endocrinological stimulation tests demonstrated impaired response in multiple anterior-pituitary hormones, which suggests impairment of the pituitary gland or the hypothalamus. Further MRI study revealed a lesion highly suggestive of inflammation of the pituitary gland [3]; consequently, we speculated that he had most likely developed lymphocytic hypophysitis.

Basal PRL level was normal in this patient; in lymphocytic hypophysitis, hyperprolactinemia is documented in about 36% and hypoprolactinemia in about 32% [1]. On the other hand, diabetes insipi-

dus accompanies lymphocytic hypophysitis in about 16% [1]; although the posterior lobe of the pituitary gland was not well visualized in this case, the result of the water deprivation test was normal. We did not perform stimulation tests with CRH and GRH; additional provocative testing for GH has been reported to be unnecessary in patients with multiple anterior-pituitary deficiencies [4].

Differential diagnosis in this setting includes pituitary adenoma, sarcoidosis, tuberculosis, syphilis, Langerhans cell histiocytosis, and hemochromatosis. Pituitary adenoma was not likely because gadolinium uptake by the pituitary gland was homogeneous and prominent. Other possibilities were also unlikely because there was no evidence of systemic manifestations or laboratory findings suggestive of them, diabetes insipidus was not present, and spontaneous recovery from these disorders is less likely to occur [2, 5].

Since the benefit of corticosteroid treatment is unclear, we decided to closely observe this patient with hormonal replacement. Follow-up stimulation test with cosyntropin showed a recovery of pituitary function, although the change of the pituitary mass was unknown. There have been several reports of spontaneous recovery of pituitary function, but, to our knowledge, there has been only one male case [2]. Spontaneous regression of the pituitary mass has been reported as well. However, resumption of normal hormonal function does not always correlate with regression of the mass [6].

Current opinion in treating lymphocytic hypophysitis is in favor of conservative management [3, 6–10],

and we did not consider performing surgical exploration of the pituitary lesion in light of the fact that surgical decompression was not necessary, there was potential for recovery of pituitary function, and his clinical course was uneventful.

While the natural history of lymphocytic hypophysitis remains to be elucidated and its management is not well established, our report illustrates that spontaneous resolution may occur simply with steroid supplementation, even in men.

## References

1. Hashimoto K, Takao T, Makino S (1997) Lymphocytic adenohypophysitis and lymphocytic infundibuloneurohypophysitis. *Endocr J* 44: 1–10.
2. Gonzalez-Gonzalez JG, Mancillas-Adame LG, Lavalle-Gonzalez FJ, Villarreal-Perez JZ (1997) Transient pituitary enlargement and dysfunction due to lymphocytic hypophysitis. *Endocrinologist* 7: 357–363.
3. Powrie JK, Powell M, Ayers AB, Lowy C, Sonksen PH (1995) Lymphocytic hypophysitis: magnetic resonance imaging features of two new cases and a review of the literature. *Clin Endocrinol* 42: 315–322.
4. Lamberts SWJ, de Herder WW, van der Lely AJ (1998) Pituitary insufficiency. *Lancet* 352: 127–134.
5. Garber JR, Hedley-Whyte ET (1995) Case records of the Massachusetts General Hospital, Case 25–1995. *N Engl J Med* 333: 441–447.
6. Beressi N, Beressi J-P, Cohen R, Modigliani E (1999) Lymphocytic hypophysitis: A review of 145 cases. *Ann Med Interne* 150: 327–341.
7. Cohen R, Beressi N, Modigliani E (1995) Lymphocytic hypophysitis (letter). *Clin Endocrinol* 43: 769.
8. Hughes JM, Ellsworth CA, Harris BS (1995) Clinical case seminar: A 33-year-old woman with a pituitary mass and panhypopituitarism. *J Clin Endocrinol Metab* 80: 1521–1525.
9. Nishioka H, Ito H, Fukushima C (1997) Recurrent lymphocytic hypophysitis: case report. *Neurosurgery* 41: 684–687.
10. Kamel N, Ilgin SD, Gullu S, Tonyukuk VC, Deda H (1999) Lymphocytic hypophysitis and infundibuloneurohypophysitis; clinical and pathological evaluations. *Endocr J* 46: 505–512.