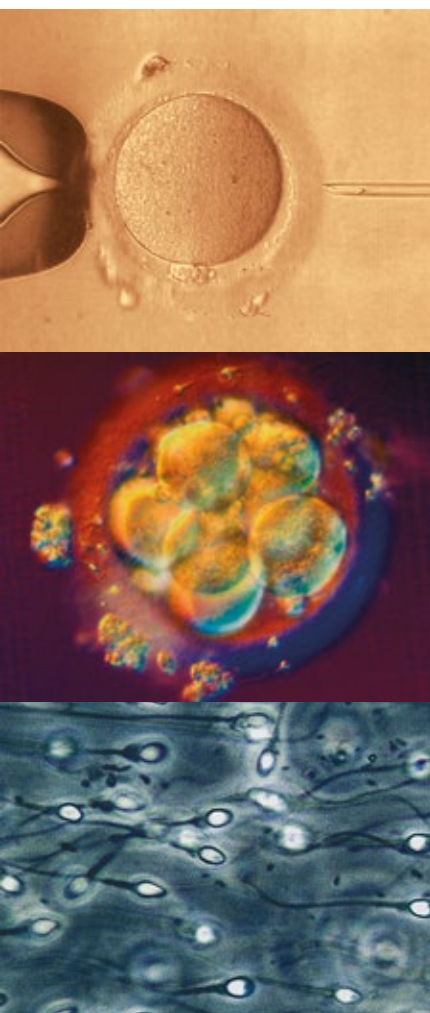


Journal für

Reproduktionsmedizin und Endokrinologie

– Journal of Reproductive Medicine and Endocrinology –

Andrologie • Embryologie & Biologie • Endokrinologie • Ethik & Recht • Genetik
Gynäkologie • Kontrazeption • Psychosomatik • Reproduktionsmedizin • Urologie



How to Diagnose and Treat Adenomyosis in Patients with Endometriosis

Krentel H, DeWilde RL

J. Reproduktionsmed. Endokrinol 2018; 15 (5-6)

262-269

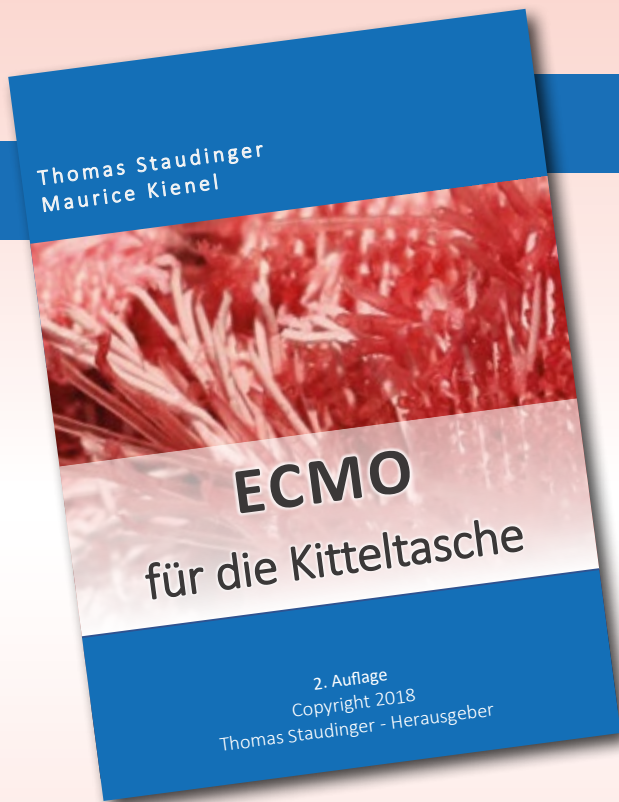
www.kup.at/repromedizin

Online-Datenbank mit Autoren- und Stichwortsuche

Offizielles Organ: AGRBM, BRZ, DVR, DGA, DGGEF, DGRM, DIR, EFA, OEGRM, SRBM/DGE

Indexed in EMBASE/Excerpta Medica/Scopus

Krause & Pachernegg GmbH, Verlag für Medizin und Wirtschaft, A-3003 Gablitz



Ab sofort in unserem Verlag

Thomas Staudinger
Maurice Kienel

ECMO für die Kitteltasche

2. Auflage Jänner 2019
ISBN 978-3-901299-65-0
78 Seiten, div. Abbildungen
19.80 EUR

Krause & Pachernegg
GmbH

Bestellen Sie noch heute Ihr Exemplar auf
www.kup.at/cd-buch/75-bestellung.html

How to Diagnose and Treat Adenomyosis in Patients with Endometriosis

H. Krentel¹, RL. De Wilde²

Since some years the uterus has become part of the discussion about treatment concepts in patients with peritoneal and deep infiltrating endometriosis, especially in subfertile women. Anyhow adenomyosis is still underdiagnosed and its impact on symptomatology in patients with endometriosis, on subfertility especially in young premenopausal women and on the right choice of treatment approaches is still underestimated. An age related incidence is not yet known. This might be related to the difficulties in diagnosing adenomyosis. Transvaginal ultrasound and MR imaging have a high accuracy in the hands of the skilled examiner, but the global awareness on how to diagnose adenomyosis has just begun. Pretherapeutical screening for adenomyosis allows the identification of subgroups and thus individualization of medical and surgical treatment. In the following the actual not yet evidence based diagnostic and therapeutic options, especially in patients with adenomyosis and subfertility are reviewed and discussed. **J Reproduktionsmed Endokrinol Online 2018; 15 (5-6): 262–9.**

Key words: Adenomyosis, uterine endometriosis, infertility, dysmenorrhea, transvaginal ultrasound, adenomyomectomy, focal adenomyosis, diffuse adenomyosis, dienogest, gonadotropin-releasing hormone agonists, levonorgestrel-releasing intrauterine system, high-intensity focused ultrasound, uterine artery embolization

■ Introduction

While peritoneal and deep infiltrating endometriosis play an important role in the international scientific literature, adenomyosis is still underrepresented, although it is a frequent symptomatic uterine disease affecting the central genital organ in premenopausal women. An incidence of more than 30% of adenomyosis in hysterectomy specimens has been detected by histopathological examination [1], however the incidence in younger women with ongoing family planning remains unknown. Less than 5% of all patients with adenomyosis have no symptoms. The most frequent symptom is dysmenorrhea followed by bleeding disorders, chronic pelvic pain and dyspareunia [2]. Different publications also indicate that adenomyosis has a negative impact on fertility, reporting reduced pregnancy and live birth rates and increased miscarriage rates after IVF in patients with adenomyosis [3–6]. In recent literature reviews the relation of adenomyosis to the increased risk of obstetrical complications like preterm birth, preterm premature rupture of membranes, uterine rupture and uterine atony is discussed [7, 8]. At the same time it has been reported in various publications that medical and surgical treatment of adenomyosis may improve fertility [9, 10], although a standard for the treatment

of infertile women with adenomyosis has not yet been established [11]. These data show that adenomyosis has to be included in the diagnostic procedures in patients with endometriosis and specific treatment options should be considered and discussed with the patients in case of adenomyosis [12].

■ Methods

PubMed search has been realized using the keywords adenomyosis, hysteroscopy, 2D transvaginal sonography, 3D transvaginal sonography, doppler sonography, elastography, MR imaging and laparoscopy, adenomyomectomy, infertility, subfertility, focal adenomyosis, diffuse adenomyosis, dienogest, gonadotropin-releasing hormone agonists, levonorgestrel-releasing intrauterine system, high-intensity focused ultrasound, uterine artery embolization

■ Results and Discussion

1. Diagnosis of Adenomyosis

Different diagnostic tools like 2D and 3D transvaginal ultrasound, doppler sonography, sonoelastography, MR imaging and diagnostic hysteroscopy and laparoscopy with their specific findings play an important role in the diagnosis of adenomyosis [13]. Especially when combined with clinical history and examination

[14] [15] the imaging techniques offer a good specificity and sensitivity in the hands of the skilled examiner. The diagnostic findings can change in relation to patients age, hormonal treatment and menstrual cycle [16]. As dysmenorrhea is the most common symptom of adenomyosis, the disease should be assumed in case of persistent dysmenorrhea after laparoscopic resection of peritoneal or deep infiltrating endometriosis even when typical imaging findings are missing [17]. In case of deep infiltrating endometriosis the probability of simultaneous adenomyosis is almost 50%. In this group the pain reduction by surgical treatment of the deep infiltrating endometriosis is less effective than in patients without adenomyosis [18]. However a reliable standard in the diagnosis of adenomyosis so far does not exist.

Transvaginal Ultrasound

Transvaginal ultrasound is the most accessible and cost-effective diagnostic tool. Typical sonographic features have been described in the last years: heterogeneous myometrium, hyperechoic or hypoechoic linear striation in the myometrium, myometrial anechoic lacunae or cysts, subendometrial microcysts, asymmetrical myometrial thickening of the uterine wall, globally uterine enlargement, the so called question mark sign, thickening of the junctional zone and hy-

Received: August 3, 2018; accepted: September 22, 2018 (responsible Editor: Prof. L. Kiesel, Münster)

From the ¹Clinic of Gynecology, Obstetrics and Gynecological Oncology, Bethesda Hospital, Duisburg, Germany, and the ²Clinic of Gynecology, Obstetrics and Gynecological Oncology, University Hospital for Gynecology, Pius-Hospital Oldenburg, Medical Campus University of Oldenburg, Germany

Correspondence: Harald Krentel, Clinic of Gynecology, Obstetrics, Gynecological Oncology & Senology, Bethesda Hospital, Heerstraße 219, 47053 Duisburg, Germany; e-mail: krentel@cpgpa.org

perechoic myometrial areas [19–22]. In a recent review Andres et al evaluated the literature in the last 10 years in order to determine the accuracy of transvaginal ultrasound and its imaging features [23]. The pooled sensitivity and specificity for 2D transvaginal ultrasound was 83.8% and 63.9%. The feature heterogeneous myometrium reached the highest pooled sensitivity with 86 %, while globular uterine enlargement was the most specific sign. The combination with the feature question mark sign increased the accuracy. In a similar review Bazot et al showed comparable results pointing out the high heterogeneity between the included studies and the missing consensus in adenomyosis classification [24].

In 2014 Dartmouth et al also reviewed the literature and concluded that uterine asymmetry is not an accurate sign, but myometrial cysts, linear myometrial striations, poor delineation of the JZ and a heterogeneous myometrium define adenomyosis in transvaginal ultrasound [25]. Different publications show a high variation in the most useful ultrasound features changing between linear striation, myometrial cysts, question mark sign, heterogeneous myometrium and asymmetrical myometrial thickening [26–28]. However not only the most accurate transvaginal ultrasound feature remains still uncertain, but also the most sensitive and specific combination of features and thus the question of a possible ultrasound score in the detection of adenomyosis. Dueholm stated that adenomyosis is likely in the presence of three or more ultrasound signs [29]. In a next step additional techniques can help to ensure the suggested diagnosis.

In the assessment of the junctional zone the 3D transvaginal ultrasound seems to be more accurate than the 2D technique [27]. In 86% of patients with adenomyosis Sharma et al detected an irregular junctional zone in 3D transvaginal ultrasound [30]. Luciano et al described $JZ(max) > 8$ mm, myometrial asymmetry and hypoechoic striation as most specific parameters in 3D transvaginal ultrasound. The combination of two features reached an accuracy of 90% [31]. However the use of 3D transvaginal ultrasound did not improve the pooled overall accuracy in the most recent review. Poor junctional zone definition showed the highest sensitivity (86.0%) and specificity (56.0%). In

the differentiation between adenomyosis and myomas transvaginal ultrasound with additional color Doppler reached a high accuracy (sensitivity 95.6%, specificity 93.4%) [23]. Leiomyomas showed peripheral vascularity in 89%, while central vascularity was found in 93 % of adenomyosis lesions in additional doppler sonography [30]. Another tool in order to discriminate uterine lesions is sonoelastography measuring the specific tissue stiffness and color patterns [32, 33]. In conclusion the transvaginal ultrasound examination is a good diagnostic tool in order to determine adenomyosis. However its accuracy depends on examination criteria selection and the examiners experience. In 2015 the MUSA (Morphological Uterus Sonographic Assessment) group reported a consensus statement on sonographic uterine features summarizing parameters and the use of terminology [34].

MR Imaging

MR imaging offers an additional diagnostic approach in order to detect adenomyosis, to differentiate focal and diffuse adenomyosis, to localize and measure affected uterine tissue prior to surgical interventions and in order to differentiate adenomyosis from fibroids [35]. Focal or diffuse thickening of the junctional zone ($JZ(max) > 12$ mm, a $JZ(max)$ to myometrial thickness ratio $> 40\%$, areas of myometrial low-signal-intensity and high-signal-intensity spots in the T2-weighted technique are the typical findings [36, 37]. Stamatopoulos et al described a sensitivity of 46.1% and specificity of 99.2% of MRI in the diagnosis of adenomyosis [38]. Bazot et al. compared transvaginal ultrasound with magnetic resonance imaging and reported no difference in accuracy. In patients with additional uterine myomas the sensitivity was higher in MR imaging [36].

Hysteroscopy and Laparoscopy

The role of hysteroscopy in adenomyosis has been recently reviewed [39, 40]. Superficial endometrial openings, irregular endometrium, hypervascularization and cystic hemorrhagic lesions have been described as the main hysteroscopic findings suspecting adenomyosis [22, 41, 42]. The possibility to proof the diagnosis by histopathologic examination after hysteroscopic retrieval of subendometrial adenomyotic tissue has been already reported in 1992 [43]. With modern of-

fice hysteroscopy Dakhly et al showed an increased specificity in the combination of transvaginal ultrasound and endomyometrial biopsy [44].

Probable laparoscopic parameters in adenomyosis are uterine enlargement, a pillowy resistance of the uterine wall, the blue sign and cystic subserous hemorrhagic lesions [22]. Jeng et al described the laparoscopy-guided myometrial biopsy as a valuable tool for obtaining a definite diagnosis in patients with clinical suggestion of adenomyosis [45]. The histologic proof of adenomyosis can facilitate therapeutic decisions, especially in case of adenomyosis-related subfertility. Additionally both minimally invasive surgical approaches offer a variety of treatment options in patients with adenomyosis.

In conclusion the diagnosis or exclusion of adenomyosis in patients with endometriosis should be possible by the experienced gynecologist. The individual combination of different diagnostic tools including imaging techniques and minimally invasive surgical approaches offer a high accuracy in the diagnosis of adenomyosis and in some cases even histological certainty. Thus adenomyosis can be included in the respective individual treatment concept.

2. Treatment of Adenomyosis

When adenomyosis has been diagnosed, the reliability of the diagnostic methods, the symptoms of the disease, the impact on fertility and the respective treatment options should be mentioned and discussed with the patients. According to the family planning the treatment options in patients with adenomyosis can be divided into two groups: patients with ongoing family planning and patients with completed family planning.

In case of ongoing family planning the presence of adenomyosis represents a serious adverse factor. Recent data show that medical or surgical treatment of adenomyosis can improve fertility. Thus in patients who wish to conceive in the future the treatment should be planned in order to improve symptoms and fertility, preserving the integrity of the uterus. Another factor for choosing the treatment method is the age depending moment of diagnosis of adenomyosis. Better diagnostic methods and global adenomyo-

sis awareness recently allow an earlier diagnose of the disease in very young women who still do not have actual wish of conception. In these cases a long-term treatment with low complication rates and the aim to prevent a worsening of the uterine situation is required. Surgical solutions does not play an important role in these patients as the adenomyotic lesions in most of these cases are minimal and almost invisible by transvaginal ultrasound and MR imaging and thus surgical therapy planification is difficult. The use of low dose LNG-IUDs, which are especially designed for young nulliparous patients, could be an option. However the effectiveness of these IUDs on adenomyosis related symptoms needs to be proven by prospective studies.

In many cases adenomyosis is just diagnosed in correlation with ongoing diagnostic steps in infertility treatment. Thus the immediate improvement of the uterine situation is required. This aim can be achieved by medical or surgical interventions or a combination of both. Prospective studies leading to an evidence based recommendation are missing so far. In a recent literature review Dueholm gives an overview of minimal invasive treatment options including medical and surgical methods, highlighting treatment strategies, but also the lack of knowledge and the difficulties in suggesting evidence-based treatments [46]. However actual literature shows a variety of different medical and surgical possibilities in the treatment of adenomyosis regarding both groups of patients.

a) Medical approach

The medical therapeutic options in patients with adenomyosis have been recently reviewed by Vannuccini et al [47], Pontis et al [48] and Tsui et al [49]. Each conclude that the use of suppressive hormonal treatment with high dose progestins, oral contraceptives, levonorgestrel-IUDs, GnRH agonists, aromatase inhibitors, selective estrogen receptor modulator (SERMs) and selective progesterone receptor modulator (SPRM's) are able to reduce symptoms by reduction of adenomyosis. However each therapy is related to specific side effects. Actually all medical approaches represent an off-label use as no medical solution is licensed in the specific treatment of adenomyosis. In daily practice

and also in literature combinations of the above mentioned medical treatment options can be found.

Dienogest and other Progestins

While the daily administration of 2 mg of dienogest in patients with peritoneal and deep infiltrating endometriosis is a standard procedure, the use of dienogest in patients with adenomyosis can not be adopted without further evaluation. The package insert describes the possibility of severe uterine bleedings in patients with adenomyosis while using dienogest. In 2012 Nagata et al described that adenomyosis patients treated with dienogest have a higher risk of treatment discontinuation due to bleeding disorders, especially when they are of young age, have anemia before treatment and/or have mildly suppressed or unsuppressed estradiol after they started dienogest treatment [50].

Nishino et al described an acute massive uterine bleeding under dienogest treatment in a patient with adenomyosis [51]. However Hirata et al. showed that dienogest reduces adenomyosis-related pelvic pain in 15 patients with treatment for up to 24 weeks. But also in this publication 5 patients experienced metrorrhagia [52]. In two publications Osuga et al reported the treatment of 130 and 67 adenomyosis patients with dienogest for 52 and 16 weeks. They described an effective pain reduction but also irregular uterine bleedings as most common adverse reaction. However they concluded that the treatment was well-tolerated by most of the patients [53, 54]. As possible mechanisms a reduction in proliferation, NGF expression and nerve fiber density has been shown [55]. In another study the number of natural killer cells increased in glandular structures after treatment with dienogest [56].

In conclusion dienogest seems to significantly reduce pain in patients with adenomyosis, while the impact of side effects like bleeding disorders and depression on the discontinuation of the treatment should be evaluated in larger prospective and age-depending studies. Also other progestins like MPA or norethisterone acetate can reduce pain in patients with adenomyosis, but are related to side effects such as acne, edema and reduction of libido causing high withdrawal rates [57–59].

Combined Oral Contraceptives (COCs) Especially in the treatment of symptomatic endometriosis, the COC's play an important role when Dienogest is not tolerated by the patients. The combination of low dose estrogen with dienogest can cope with the progestin-related adverse effects. COC's also may reduce adenomyosis-related pain, but lead to irregular bleedings in many cases [49, 60]. However in case of adenomyosis the treatment with COC's does not represent a specific approach, but just one more possibility in a non-evidence-based situation. Shaaban et al compared low-dose oral contraceptive with levonorgestrel-releasing intrauterine system (LNG-IUS) and showed that both approaches reduced symptoms after six month. However LNG-IUS is more effective in reducing pain and menstrual blood loss [61].

Levonorgestrel Intrauterine Device

The effectiveness of LNG-IUDs in the treatment of adenomyosis related symptoms has been shown in various publications [62–65]. LNG-IUDs are equal or superior in comparison with systemic progestins or oral contraceptives. LNG-IUDs are used in young women with adenomyosis with ongoing family planning, in women with completed family planning instead of hysterectomy [66], as a maintenance therapy after adenomyosis surgery [67] and in patients with fertility treatment before assisted reproduction. In a retrospective analyze Park et al described the treatment with LNG-IUS in patients with large uterine adenomyosis and heavy menstrual bleeding. In all patients an improvement in dysmenorrhea and menstrual bleeding has been shown. 10% of patients underwent premature LNG-IUS removal and 16.7% underwent subsequent hysterectomy [68]. However a high patient satisfaction of about 80% in women after 35 years has been shown [69]. In a prospective cohort study Li et al investigated changes in menstruation patterns and adverse effects in patients with adenomyosis treated by LNG-IUD. During the follow-up period up to 60 month, the rate of amenorrhea and shortened menstruation increased, while adverse effects decreased [70]. Lee et al showed that there is a relationship between treatment failure rate and uterine volume in the use of LNG-IUDs [71].

The incidence of spontaneous expulsion of the IUS is higher in patients with

adenomyosis and/or uterine fibroids than in normal uterus [72] and seems to depend on the insertion technique [73] and the placement timing [74]. In the postsurgical situation Lin et al described that the use of levonorgestrel-releasing intrauterine system after conservative surgery and temporary administration of gonadotropin-releasing hormone in patients with adenomyosis, guaranteed a greater reduction of dysmenorrhea in a 24-month follow-up period than the control group without additional LNG-IUD [67]. Zhang et al reported the combination of LNG-IUD with gonadotropin-releasing hormone analogue as a efficacious treatment alternative [75]. The role of levonorgestrel-releasing intrauterine systems in the treatment of adolescent or very young women with adenomyosis, especially the use of low-dose IUD's, has to be investigated in the future. Low-dose IUD's with 13.5 or 19.5 mg of levonorgestrel are suitable in nulliparous women, but the approved non-contraceptive effects of 52 mg IUD's can not be estimated yet for this new generation of IUDs [76]. In daily practice of fertility treatment the application of LNG-IUDs prior to assisted reproduction also plays a role, which is not yet evaluated by respective studies.

Gonadotropin-Releasing Hormone Analogues

Gonadotropin-releasing hormone agonists also play an important role in the treatment of adenomyosis. The application can be presurgical, postsurgical, prior to assisted reproductive techniques or as individual medical treatment approach instead of other therapies. Tan et al analyzed the value of gonadotropin-releasing hormone agonist pretreatment before adenomyomectomy and showed that the pretreatment reduces peri- and postoperative complications [77, 78]. The combination of gonadotropin-releasing hormone agonist application with conservative surgery seems to result in longer durable symptom-control and better reproductive outcomes in symptomatic and subfertile patients with adenomyosis compared with gonadotropin-releasing hormone treatment alone [9, 79, 80].

However Chong et al investigated the long-term efficacy of adenomyomectomy with or without postoperative gonadotropin-releasing hormone agonist

administration and found no differences in symptom control in both groups [81]. In infertile women with adenomyosis the treatment with gonadotropin-releasing hormone agonist is indicated before fertility treatment in order to improve the results [47, 82]. Tremellen treated four patients with repeated unsuccessful in vitro fertilisation with ultra-long pituitary downregulation and reported pregnancy in all cases [83]. Mijatovic et al showed that adenomyosis had no adverse effects on IVF/ICSI outcomes in patients with endometriosis when pretreated with long-term downregulation [84]. Niu et al showed that in frozen embryo transfer the long-term GnRH agonist pretreatment increased pregnancy outcomes [85]. They compared 194 patients with down-regulation and stimulation with 145 patients with stimulation only. In a recent publication Dueholm et al describe actual clinical considerations in case of adenomyosis and assisted reproductive techniques [86]. In a case series Mansouri et al demonstrated the efficacy of gonadotropin-releasing hormone agonists in adolescents with refractory chronic pelvic pain, failed COC therapy and positive MR imaging for adenomyosis. The treatment improved symptoms and repeated MR imaging showed regression of the lesions [87]. Akira et al described the maintenance of therapeutic effects with low-dose long-term gonadotropin-releasing hormone agonist therapy achieving a plasma estradiol level within the therapeutic window [88].

Aromatase Inhibitors

Estrogen, estrogen receptors and aromatase play a role in the pathogenesis of adenomyosis [89]. Thus the use of aromatase inhibitors represents another attempt in the treatment of adenomyosis and its symptoms. Badawy et al showed that aromatase inhibitors are as effective as gonadotropin-releasing hormone agonists in reducing adenomyoma volumen and improving symptoms. 32 patients were randomly treated with letrozole (2.5 mg/d) or subcutaneous goserelin for 12 weeks. Interestingly two patients became pregnant during treatment with letrozole [90]. Kimura et al reported a case of simultaneous treatment of severe symptomatic adenomyosis with anastrozole and gonadotropin-releasing hormone agonist. They described a reduction of uterine volumen by 60% after

eight weeks of treatment [91]. The synthesis of estrogen in adenomyotic tissues has been shown in the early 90s [92]. Its role for the pathogenesis of adenomyosis, treatment approaches and the relation to malignancy arising from adenomyosis has to be shown in further investigations.

Selective Progesterone Receptor Modulator

Selective progesterone receptor modulator also seem to be able to reduce symptoms in patients with adenomyosis. However only very few publications on this topic exist so far. In a single-center retrospective observational study Gracia et al used a 12-week course of ulipristal acetate (UPA) on 41 patients with adenomyosis and uterine fibroids. In 90 % of the patients amenorrhea was achieved and the pain was reduced [93]. Further investigations are needed to evaluate the efficacy and safety of this approach, especially in combination with fertility treatment.

Selective Oestrogen Receptor Modulator, Valproic Acid, Anti-platelets Therapy

This group of medicaments represent an even more experimental approach than the above mentioned. In a recent clinical trial Harada et al showed the pain reducing effect of a novel selective oestrogen receptor modulator (SR-16234) in patients with endometriosis and adenomyosis. Also total dysmenorrhea score as a secondary endpoint of the study was improved [94]. Liu et al showed in a case series that valproic acid treatment for three month in patients with confirmed adenomyosis led to a complete resolution of dysmenorrhea and an average reduction of uterine size by 26% [95, 96]. In animal models the positive influence of valproic acid, epigallocatechin-3-gallate, resveratrol, leonurine and anti-platelet therapy on adenomyosis-related pain has been shown [97–101].

Several medical treatment options exist in order to reduce adenomyosis related symptoms. The most effective and safe method, without severe side effects seems to be the use of LNG-IUD's. The possible role of new low-dose IUDs should be investigated. In combination with fertility treatment the use of gonadotropin-releasing hormone agonists prior to conception or assisted reproductive techniques

seems to improve pregnancy rates. However this literature review shows that data is limited and prospective, comparative studies are needed in order to find out the evidence based way. So far the medical treatment of adenomyosis especially in patients with ongoing family planning is an individual recommendation, while the situation in patients with completed family planning is based on a large number of publications, especially regarding the LNG-IUDs.

b) Surgical Approach

If the family planning is completed minimally invasive total or supracervical hysterectomy can effectively treat bleeding disorders and dysmenorrhea caused by adenomyosis [82]. The laparoscopic supracervical hysterectomy with intraabdominal in-bag morcellation is a surgical method with a very low risk of complications [102, 103] and can be easily combined with laparoscopic resection of peritoneal endometriosis. In case of simultaneous cervical or retrocervical adenomyosis or deep infiltrating endometriosis of the retrocervical region or the parametrium the total laparoscopic hysterectomy, laparoscopically assisted vaginal hysterectomy or vaginal hysterectomy is safe and feasible [104, 105].

The global endometrial ablation offers a less invasive treatment option in patients who want to preserve the uterus. Philip et al. described the use of radiofrequency global endometrial ablation in 43 patients with adenomyosis with a 36 month follow up. The intervention was effective in the treatment of adenomyosis related symptoms, but the efficacy in controlling bleeding decreased over time [106]. The correlation between failure rate of endometrial ablation and adenomyosis has been described in various publications [107–110]. Thus Nakamura et al described multiple endometrial ablations repeating the procedure three times achieving higher satisfaction rates in controlling adenomyosis related menorrhagia [111]. Ota et al recently reported the combination of microwave endometrial ablation and postoperative dienogest administration [112]. The combination of endometrial ablation and LNG-IUS, especially the 13.5 and 19.5 mg versions should be investigated in patients who want to preserve the uterus and avoid side effects by hormonal treatment. If possible a reliable control of symptoms

with low complication rates and without systemic hormonal side effects should be first choice in this group.

However more women with adenomyosis wish to conceive a child in the future and hysterectomy is not the only effective therapy any longer [113]. If patients want to preserve the uterus, desire preservation or improvement of fertility the surgical resection of focal or diffuse adenomyosis by hysteroscopy, laparoscopy or open surgery also represents an individual approach. Focal subendometrial or intramural cystic adenomyotic lesions and intracavitary polypoid adenomyoma can be resected by bipolar or monopolar hysteroscopy. New instruments with lower diameter offer a minimally invasive approach especially in very young nulliparous women. The hysteroscopic resection of submucous adenomyotic lesions improves dysmenorrhea and bleeding disorders [114–117]. The influence of these surgical approaches on patients fertility requires further investigations. However it is crucial to avoid the postsurgical formation of intrauterine adhesions by IUD application or temporary insertion of a Foley catheter. Laparoscopic or abdominal surgery offer a variety of surgical techniques in patients with adenomyosis. In an actual review Younes et al analyzed 27 studies including 1398 patients. Resection of adenomyotic lesions is effective for symptom control and most probably for adenomyosis-related infertility. More than 75 % of patients experience improvement of symptoms. Pregnancy rates varied after surgery depending on the method and the additional medical treatment of adenomyosis [118]. Most of the surgical interventions can be realized by laparoscopy. The minimally invasive approach permits the excision of subserous cystic lesions [119] and focal adenomyomas [120, 121]. Also laparoscopic techniques for diffuse adenomyosis with uterine artery blocking and double-flap method have been described [122–124]. Recently Kwack et al compared the laparoscopic and open surgical approach in 224 cases of uterine adenomyomectomy with transient occlusion of the uterine arteries [125]. They concluded that surgery is effective to reduce symptoms regardless of the approach, but laparotomy seems to be more suitable for diffuse and laparoscopy more suitable for focal adenomyosis.

Chong et al reported that laparoscopic or robotic adenomyomectomy are feasible and safe methods in patients with adenomyosis. The postsurgical administration of gonadotropin-releasing hormone agonist cycles did not improve the surgical result [81]. The surgical excision of the adenomyotic tissue helps to reduce dysmenorrhea and menorrhagia. In relation to adenomyosis-associated subfertility Kishi et al described age as a determinant in fertility outcomes. In a retrospective cohort study they analyzed pregnancy rates in 102 patients who underwent laparoscopic adenomyomectomy depending on the patients age. Women < 39 years old showed a clinical pregnancy rate of 41.3 % and women > 40 years only a rate of 3.7 % [126]. In 2017 Dueholm et al reviewed the reproductive outcome of patients with adenomyosis after different surgical approaches and in vitro fertilization [9], describing the results of different open and laparoscopic surgical techniques. The authors underlined that surgery might be helpful in matters of fertility, but the effect of surgery needs to be proven in the future. They emphasized the lack of controlled studies, the missing clear diagnostic criteria, the missing reliable information about the impact of adenomyosis in fertility, the missing correlation between fertility and stage or type of adenomyosis and the lack of a severity classification of the disease. In an actual review Rocha et al described an overall clinical pregnancy rate of 18.2% after surgical treatment of adenomyosis. The additional postoperative treatment with gonadotropin-releasing hormone agonists increased the rate up to 40 % [127]. In another recent review Tan et al described a mean pregnancy rate of 52.7% in patients after surgery for focal adenomyosis and 34.1% in patients with diffuse adenomyosis. Uterine rupture was reported in no patient with focal adenomyosis, but 6.8 % of patients with surgery for diffuse adenomyosis. The authors concluded that the decision for surgery should be individual considering patients with adenomyosis with medical treatment failure and women with infertility despite assisted reproductive techniques [128]. However complications should be considered and further studies are needed in order to proof the safety and effectiveness of surgical methods in patients with adenomyosis [129], including the possible affection by concomitant endometriosis [130] and the possible

benefit of additional medical treatments prior to or after surgery.

If patients want to avoid surgery and/or desire fertility preservation or improvement different interventional methods exist and therefore are currently under discussion [131]. The high-intensity focused ultrasound is an alternative treatment method in focal and diffuse adenomyosis. High-intensity focused ultrasound offers symptom relief and a low rate of major and minor complications considering the specific selection criteria. Additionally patients showed high conception and live birth rates after treatment [132, 133]. The safety and efficacy of the method has been evaluated in various publications highlighting also its cost-effectiveness and improvement of female sexual function index [134–137]. In a prospective study 54 of 68 patients treated with high-intensity focused ultrasound got pregnant and 21 delivered healthy babies. No uterine rupture occurred [138]. However the role of high-intensity focused ultrasound in patients who wishes to get pregnant should be further investigated.

Hai et al also described the transcervical radiofrequency ablation for symptomatic adenomyosis as a safe and effective method. No serious complications occurred, however two patients developed intrauterine adhesions [139]. Also uterine artery embolization can reduce symptoms and improve quality of life in patients with symptomatic adenomyosis. In a recent meta-analysis de Bruijn et al reported an overall improvement of symptoms in 83.1 % of the patients (872/1049) [140]. Liang et al described the technique as an effective uterus-sparing option for women with adenomyosis-related symptoms. Clinical success was achieved in 89 % of the patients (117) without major complications [141]. The impact of uterine artery embolization on fertility and pregnancy requires has been recently reviewed and requires further evaluation [142].

Another non-surgical alternative in both groups of patients is the use of a levonorgestrel-IUD alone or the postsurgical application as described above. A conscious or often unconscious option, due to failed diagnosis of adenomyosis, is the eschewal of any particular treatment. In daily routine this seems to play

a certain role also in fertility treatment, as no general treatment recommendation exists and/or no importance is attached to the presence of adenomyosis, although corresponding literature shows that the presence of adenomyosis reduces the pregnancy and birth rates after in vitro fertilization [3–6]. Prospective studies are needed in order to show which way is the best to improve fertility in patients with adenomyosis.

Conclusion

The cited data shows a wide range of different experimental attempts in order to treat adenomyosis. Recently every method seems possible but none is proven in relation to effectiveness, fertility outcome, reliability and side effects. As the incidence of adenomyosis is much higher and the population much younger than we thought, and thus the impact on fertility considerable, a consensus on diagnosis and treatment in adenomyosis is needed.

A condition for adequate treatment is the diagnosis of the uterine disease adenomyosis in patients with endometriosis. This can be achieved by a combination of clinical history, gynecological examination transvaginal ultrasound and additionally MR imaging when needed. As a function of individual patients family planning and the type of adenomyosis different treatment options offer a wide range of medical and surgical treatment approaches. Prospective studies are needed in order to describe the best way for our patients in the future.

Conflict of interest

The author declares that there is no conflict of interest regarding the publication of this paper.

References

- Yeniel O, Cirpan T, Ulukus M, Ozbal A, Gundem G, et al. Adenomyosis: prevalence, riskfactors, symptoms and clinical findings. *Clin Exp Obstet Gynecol* 2007; 34: 163–7.
- Li X, Liu X, Guo SW. Clinical profiles of 710 premenopausal women with adenomyosis who underwent hysterectomy. *J Obstet Gynaecol Res* 2014; 40: 485–94.
- Younes G, Tulandi T. Effects of adenomyosis on in vitro fertilization treatment outcomes: a meta-analysis. *Fertil Steril* 2017; 108: 483–90.
- Salim R, Riris S, Saab W, Abramov B, Khadum I, Serhal P. Adenomyosis reduces pregnancy rates in infertile women undergoing IVF. *Reprod Biomed Online* 2012; 25: 273–7.
- Tremellen K, Thalluri V. Impact of adenomyosis on pregnancy rates in IVF treatment. *Reprod Biomed Online* 2013; 26: 299–300.

- Thalluri V, Tremellen KP. Ultrasound diagnosed adenomyosis has a negative impact on successful implantation following GnRH antagonists IVF treatment. *Hum Reprod* 2012; 27: 3487–92.
- Buggio L, Monti E, Gattei U, Drudi D, Vercellini P. Adenomyosis: fertility and obstetric outcome. A comprehensive literature review. *Minerva Ginecol* 2018; 295–302.
- Vlahos NF, Theodoridis TD, Partsinevelos GA. Myomas and adenomyosis: Impact on reproductive outcome. *Bio-med Res Int* 2017; 2017: 5926470.
- Dueholm M. Uterine adenomyosis and infertility, review of reproductive outcome after in vitro fertilization and surgery. *Acta Obstet Gynecol Scand* 2017; 96: 715–26.
- Sunkara SK, Khan KS. Adenomyosis and female fertility: a critical review of the evidence. *J Obstet Gynaecol* 2012; 32: 113–6.
- Tamura H, Kishi H, Kitade M, Asai-Sato M, Tanaka A, et al. Clinical outcomes of infertility treatment for women with adenomyosis in Japan. *Reprod Med Biol* 2017; 16: 276–82.
- Alabiso G, Alio L, Arena S, Barbasetti di Prun A, Bergamini V, et al. Adenomyosis: what the patient needs. *J Minim Invasive Gynecol* 2016; 23: 476–88.
- Krentel H, Cezar C, Becker S, Di Spizio Sardo A, Tanos V, et al. From clinical symptoms to MR imaging: diagnostic steps in adenomyosis. *Biomed Res Int* 2017; 2017: 1514029.
- Bernardi M, Lazzari L, Perelli F, Reis FM, Petraglia F. Dysmenorrhea and related disorders. *F1000Res* 2017; 6: 1645.
- Yeniel O, Cirpan T, Ulukus M, Ozbal A, Gundem G, et al. Adenomyosis: prevalence, riskfactors, symptoms and clinical findings. *Clin Exp Obstet Gynecol* 2007; 34: 163–7.
- Benagiano G, Brosens I, Habiba M. Adenomyosis: a life-cycle approach. *Reprod Biomed Online* 2015; 30: 220–32.
- Ferrero S, Camerini G, Menada MV, Biscaldi E, Ragni N, Remorgida V. Uterine adenomyosis in persistence of dysmenorrhea after surgical excision of pelvic endometriosis and colorectal resection. *J Reprod Med* 2009; 54: 366–72.
- Lazzari L, Di Giovanni A, Exacoustos C, Tosti C, Pinzauti S, et al. Preoperative and postoperative clinical and transvaginal ultrasound findings of adenomyosis in patients with deep infiltrating endometriosis. *Reprod Sci* 2014; 21: 1027–33.
- Di Donato N, Bertoldo V, Montanari G, Zannoni L, Caprara G, Seracchioli R. Question mark form of uterus: a simple sonographic sign associated with the presence of adenomyosis. *Ultrasound Obstet Gynecol* 2015; 46: 126–7.
- Valentini AL, Specca S, Gui B, Soglia G, Micco M, Bonomo L. Adenomyosis: from the sign to the diagnosis. Imaging, diagnostic pitfalls and differential diagnosis: a pictorial review. *Radiol Med* 2011; 116: 1267–87.
- Sakhel K, Abuhamad A. Sonography of adenomyosis. *J Ultrasound Med* 2012; 31: 805–8.
- Graziano A, Lo Monte G, Piva I, Caserta D, Karner M, et al. Diagnostic findings in adenomyosis: a pictorial review on the major concerns. *Eur Rev Med Pharmacol Sci* 2015; 19: 1146–54.
- Andres MP, Borelli GM, Ribeiro J, Baracat EC, Abrão MS, Kho RM. Transvaginal ultrasound for the diagnosis of adenomyosis: systematic review and meta-analysis. *J Minim Invasive Gynecol* 2018; 25: 257–64.
- Bazot M, Darai E. Role of transvaginal sonography and magnetic resonance imaging in the diagnosis of uterine adenomyosis. *Fertil Steril* 2018; 109: 389–97.
- Dartmouth K. A systematic review with meta-analysis: the common sonographic characteristics of adenomyosis. *Ultrasound* 2014; 22: 148–57.
- Kepkep K, Tuncay YA, Göynümer G, Tatal E. Transvaginal sonography in the diagnosis of adenomyosis: which findings are most accurate? *Ultrasound Obstet Gynecol* 2007; 30: 341–5.
- Exacoustos C, Brienza L, Di Giovanni A, Szabolcs B, Romanini ME, et al. Adenomyosis: three-dimensional sonographic findings of the junctional zone and correlation with histology. *Ultrasound Obstet Gynecol* 2011; 37: 471–9.
- Pinzauti S, Lazzari L, Tosti C, Centini G, Orlandini C, et al. Transvaginal sonographic features of diffuse adenomyosis in 18–30-year-old nulligravid women without endometriosis: association with symptoms. *Ultrasound Obstet Gynecol* 2015; 46: 730–6.

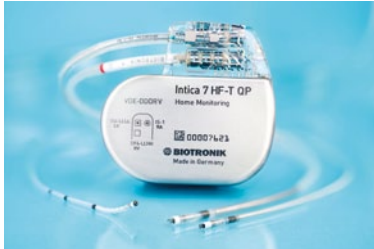29. Dueholm M. Transvaginal ultrasound for diagnosis of adenomyosis: a review. *Best Pract Res Clin Obstet Gynaecol* 2006; 20: 569–682.
30. Sharma K, Bora MK, Venkatesh BP, Barman P, Roy SK, et al. Role of 3D ultrasound and doppler in differentiating clinically suspected cases of leiomyoma and adenomyosis of uterus. *J Clin Diagn Res* 2015; 9: QC08–12.
31. Luciano DE, Exacoustos C, Albrecht L, LaMonica R, Proffer A, Zupi E, et al. Three-dimensional ultrasound in diagnosis of adenomyosis: histologic correlation with ultrasound targeted biopsies of the uterus. *J Minim Invasive Gynecol* 2013; 20: 803–10.
32. Stoelinga B, Hehenkamp WJ, Brölmann HA, Huime JA. Real-time elastography for assessment of uterine disorders. *Ultrasound Obstet Gynecol* 2014; 43: 218–26.
33. Acar S, Millar E, Mitkova M, Mitkov V. Value of ultrasound shear wave elastography in the diagnosis of adenomyosis. *Ultrasound* 2016; 24: 205–13.
34. Van den Bosch T, Dueholm M, Leone FP, Valentin L, Rasmussen CK, et al. Terms, definitions and measurements to describe sonographic features of myometrium and uterine masses: a consensus opinion from the Morphological Uterus Sonographic Assessment (MUSA) group. *Ultrasound Obstet Gynecol* 2015; 46: 284–98.
35. Tamai K, Koyama T, Umeoka S, Saga T, Fujii S, Togashi K. Spectrum of MR features in adenomyosis. *Best Pract Res Clin Obstet Gynaecol* 2006; 20: 583–602.
36. Bazot M, Cortez A, Darai E, Rouger J, Chopier J, et al. Ultrasonography compared with magnetic resonance imaging for the diagnosis of adenomyosis: correlation with histopathology. *Hum Reprod* 2001; 16: 2427–33.
37. Novellas S, Chassang M, Delotte J, Toullan O, Chevallier A, et al. MRI characteristics of the uterine junction: from normal to the diagnosis of adenomyosis. *AJR Am J Roentgenol* 2011; 196: 1206–13.
38. Stamatopoulos CP, Mikos T, Grimbizis GF, Dimitriadis AS, Efstratiou I, et al. Value of magnetic resonance imaging in diagnosis of adenomyosis and myomas of the uterus. *J Minim Invasive Gynecol* 2012; 19: 620–6.
39. Di Spiezo Sardo A, Calagna G, Santangelo F, Zizolfi B, Tanos V, et al. The role of hysteroscopy in the diagnosis and treatment of adenomyosis. *Biomed Res Int* 2017; 2017: 2518396.
40. Gordts S, Grimbizis G, Campo R. Symptoms and classification of uterine adenomyosis, including the place of hysteroscopy in diagnosis. *Fertil Steril* 2018; 109: 380–8.
41. Fernández C, Ricci P, Fernández E. Adenomyosis visualized during hysteroscopy. *J Minim Invasive Gynecol* 2007; 14: 555–6.
42. Molinas CR, Campo R. Office hysteroscopy and adenomyosis. *Best Pract Res Clin Obstet Gynaecol* 2006; 20: 557–67.
43. McCausland AM. Hysteroscopic myometrial biopsy: its use in diagnosing adenomyosis and its clinical application. *Am J Obstet Gynecol* 1992; 166: 1619–26.
44. Dakhly DM, Abdel Moety GA, Saber W, Gad Allah SH, Hashem AT, Abdel Salam LO. The accuracy of hysteroscopic endomyometrial biopsy in diagnosis of adenomyosis. *J Minim Invasive Gynecol* 2016; 23: 364–71.
45. Jeng CJ, Huang SH, Shen J, Chou CS, Tzeng CR. Laparoscopy-guided myometrial biopsy in the definite diagnosis of diffuse adenomyosis. *Hum Reprod* 2007; 22: 2016–9.
46. Dueholm M. Minimally invasive treatment of adenomyosis. *Best Pract Res Clin Obstet Gynaecol* 2018; 18: 30034–8.
47. Vannuccini S, Luisi S, Tosti C, Sorbi F, Petraglia F. The role of medical therapy in the management of uterine adenomyosis. *Fertil Steril* 2018; 109: 398–405.
48. Pontis A, D'Alterio MN, Pirarba S, de Angelis C, Tinelli R, Angioni S. Adenomyosis: a systematic review of the medical treatment. *Gynecol Endocrinol* 2016; 32: 696–700.
49. Tsui KH, Lee WL, Chen CY, Sheu BC, Yen MS, et al. Medical treatment for adenomyosis and/or adenomyoma. *Taiwan J Obstet Gynecol* 2014; 53: 459–65.
50. Nagata C, Yanagida S, Okamoto A, Morikawa A, Sugimoto K, et al. Risk factors of treatment discontinuation due to uterine bleeding in adenomyosis patients treated with dienogest. *J Obstet Gynaecol Res* 2012; 38: 639–44.
51. Nishino K, Hayashi K, Chaya J, Kato N, Yamamuro O. Effective salvage of acute massive uterine bleeding using intrauterine balloon tamponade in a uterine adenomyosis patient on dienogest. *J Obstet Gynaecol Res* 2013; 39: 738–41.
52. Hirata T, Izumi G, Takamura M, Saito A, Nakazawa A, et al. Efficacy of dienogest in the treatment of symptomatic adenomyosis: a pilot study. *Gynecol Endocrinol* 2014; 30: 726–9.
53. Osuga Y, Watanabe M, Hagino A. Long-term use of dienogest in the treatment of painful symptoms in adenomyosis. *J Obstet Gynaecol Res* 2017; 43: 1441–8.
54. Osuga Y, Fujimoto-Okabe H, Hagino A. Evaluation of the efficacy and safety of dienogest in the treatment of painful symptoms in patients with adenomyosis: a randomized, double-blind, multicenter, placebo-controlled study. *Fertil Steril* 2017; 108: 673–8.
55. Takeuchi A, Koga K, Miyashita M, Makabe T, Sue F, et al. Dienogest reduces proliferation, NGF expression and nerve fiber density in human adenomyosis. *Eur J Obstet Gynecol Reprod Biol* 2016; 207: 157–61.
56. Prathoomthong S, Tingthanatikul Y, Lertvirkool S, Rodrat N, Waiyaput W, et al. The effects of dienogest on macrophage and natural killer cells in adenomyosis: a randomized controlled study. *Int J Fertil Steril* 2018; 11: 279–86.
57. Brown J, Kives S, Akhtar M. Progestagens and anti-progestagens for pain associated with endometriosis. *Cochrane Database Syst Rev* 2012; 3: CD002122.
58. Vercellini P, Vigano P, Somigliana E, Fedele L. Endometriosis: pathogenesis and treatment. *Nat Rev Endocrinol* 2014; 10: 261–75.
59. Ferrero S, Remorgida V, Venturini PL. Endometriosis. *BMJ Clin Evid* 2010; 2010: pii: 0802.
60. Schindler AE. Non-contraceptive benefits of oral hormonal contraceptives. *Int J Endocrinol Metab* 2013; 11: 41–7.
61. Shaaban OM, Ali MK, Sabra AM, Abd El Aal DE. Levonorgestrel-releasing intrauterine system versus a low-dose combined oral contraceptive for treatment of adenomyotic uteri: a randomized clinical trial. *Contraception* 2015; 92: 301–7.
62. Imai A, Matsunami K, Takagi H, Ichigo S. Levonorgestrel-releasing intrauterine device used for dysmenorrhea: five-year literature review. *Clin Exp Obstet Gynecol* 2014; 41: 495–8.
63. Kim ML, Seong SJ. Clinical applications of levonorgestrel-releasing intrauterine system to gynecologic diseases. *Obstet Gynecol Sci* 2013; 56: 67–75.
64. Sheng J, Zhang WY, Zhang JP, Lu D. The LNG-IUS study on adenomyosis: a 3-year follow-up study on the efficacy and side effects of the use of levonorgestrel-releasing intrauterine system for the treatment of dysmenorrhea associated with adenomyosis. *Contraception* 2009; 79: 189–93.
65. Fedele L, Bianchi S, Raffaelli R, Portuese A, Dorta M. Treatment of adenomyosis-associated menorrhagia with a levonorgestrel-releasing intrauterine device. *Fertil Steril* 1997; 68: 426–9.
66. Uysal A, Taner CE, Mun S, Uysal F, Cleimli FH. Use of levonorgestrel-releasing intrauterine device in the treatment of adenomyosis associated heavy menstrual bleeding. *J Pak Med Assoc* 2013; 63: 1349–52.
67. Lin CJ, Hsu TF, Chang YH, Huang BS, Jiang LY, et al. Postoperative maintenance levonorgestrel-releasing intrauterine system for symptomatic uterine adenomyoma. *Taiwan J Obstet Gynecol* 2018; 57: 47–51.
68. Park DS, Kim ML, Song T, Yun BS, Kim MK, et al. Clinical experiences of the levonorgestrel-releasing intrauterine system in patients with large symptomatic adenomyosis. *Taiwan J Obstet Gynecol* 2015; 54: 412–5.
69. Mansukhani N, Unni J, Dua M, Darbari R, Malik S, et al. Are women satisfied when using levonorgestrel-releasing intrauterine system for treatment of abnormal uterine bleeding? *J Midlife Health* 2013; 4: 31–5.
70. Li L, Leng JH, Zhang JJ, Jia SZ, Li XY, et al. Changes of menstruation patterns and adverse effects during the treatment of LNG-IUS for symptomatic adenomyosis. *Zhonghua Fu Chan Ke Za Zhi* 2016; 51: 657–62.
71. Lee KH, Kim JK, Lee MA, Ko YB, Yang JB, et al. Relationship between uterine volume and discontinuation of treatment with levonorgestrel-releasing intrauterine devices in patients with adenomyosis. *Arch Gynecol Obstet* 2016; 294: 561–6.
72. Youm J, Lee HJ, Kim SK, Kim H, Jee BC. Factors affecting the spontaneous expulsion of the levonorgestrel-releasing intrauterine system. *In J Gynaecol Obstet* 2014; 126: 165–9.
73. Peng FS, Wu MY, Yang JH, Chen SU, Ho HN, Yang YS. Insertion of the Mirena intrauterine system for the treatment of adenomyosis-associated menorrhagia: a novel method. *Taiwan J Obstet Gynecol* 2010; 49: 160–4.
74. Li L, Leng JH, Zhang JJ, Jia SZ, Li XY, et al. A prospective cohort study on the impact of placement timing of LNG-IUS for adenomyosis. *Zhonghua Yi Xue Za Zhi* 2016; 96: 2415–20.
75. Zhang P, Song K, Li L, Yukuwa K, Kong B. Efficacy of combined levonorgestrel-releasing intrauterine system with gonadotropin-releasing hormone analog for the treatment of adenomyosis. *Med Princ Pract* 2013; 22: 480–3.
76. Grandi G, Farulla A, Sileo FG, Facchinetti F. Levonorgestrel-releasing intrauterine systems as female contraceptives. *Expert Opin Pharmacother* 2018; 19: 677–86.
77. Tan AL, Luo RY, Gong M. Value of using gonadotropin-releasing hormone agonist pretreatment in adenomyosis patients before adenomyectomy. *Zhonghua Fu Chan Ke Za Zhi* 2016; 51: 909–13.
78. Lin J, Sun C, Li R. Gonadotropin releasing hormone agonists in the treatment of adenomyosis with infertility. *Zhonghua Fu Chan Ke Za Zhi* 1999; 34: 214–6.
79. Al Jama FE. Management of adenomyosis in subfertile women and pregnancy outcome. *Oman Med J* 2011; 26: 178–81.
80. Wang PH, Fuh JL, Chao HT, Liu WM, Cheng MH, Chao KC. Is the surgical approach beneficial to subfertile women with symptomatic extensive adenomyosis? *J Obstet Gynaecol Res* 2009; 35: 495–502.
81. Chong GO, Lee YH, Hong DG, Cho YL, Lee YS. Long-term efficacy of laparoscopic or robotic adenomyectomy with or without medical treatment for severely symptomatic adenomyosis. *Gynecol Obstet Invest* 2016; 81: 346–52.
82. Streuli I, Dubuisson J, Santulli P, de Ziegler D, Batteux F, Chapron C. An update on the pharmacological management of adenomyosis. *Expert Opin Pharmacother* 2014; 15: 2347–60.
83. Tremellen K, Russell P. Adenomyosis is a potential cause of recurrent implantation failure during IVF treatment. *Aust N Z J Obstet Gynaecol* 2011; 51: 280–3.
84. Mijatovic V, Florijn E, Halim N, Schats R, Hompes P. Adenomyosis has no adverse effects on IVF/ICSI outcomes in women with endometriosis treated with long-term pituitary down-regulation before IVF/ICSI. *Eur J Obstet Gynecol Reprod Biol* 2010; 151: 62–5.
85. Niu Z, Chen Q, Sun Y, Feng Y. Long-term pituitary downregulation before frozen embryo transfer could improve pregnancy outcomes in women with adenomyosis. *Gynecol Endocrinol* 2013; 29: 1026–30.
86. Dueholm M, Aagaard J. Adenomyosis and IVF/ICSI treatment: clinical considerations and recommendations. *Expert Rev Endocrinol Metab* 2018; 13: 177–9.
87. Mansouri R, Santos XM, Bercaw-Pratt JL, Dietrich JE. Regression of adenomyosis on magnetic resonance imaging after a course of hormonal suppression in adolescents: a case series. *J Pediatr Adolesc Gynecol* 2015; 28: 437–40.
88. Akira S, Mine K, Kuwabara Y, Takeshita T. Efficacy of long-term, low-dose gonadotropin-releasing hormone agonist therapy (draw-back therapy) for adenomyosis. *Med Sci Monit* 2009; 15: CR1–4.
89. Zeng YY, Guan YG, Li KY. Role of estrogen, estrogen receptors and aromatase in the pathogenesis of uterine adenomyosis. *Nan Fang Yi Ke Da Xue Xue Bao* 2017; 37: 383–7.
90. Badawy AM, Elnashar AM, Mosbah AA. Aromatase inhibitors or gonadotropin-releasing hormone agonists for the management of uterine adenomyosis. A randomized controlled trial. *Acta Obstet Gynecol Scand* 2012; 94: 89–95.
91. Kimura F, Takahashi K, Takebayashi K, Fujiwara M, Kita N, et al. Concomitant treatment of severe uterine adenomyosis in a premenopausal woman with an aromatase inhibitor and a gonadotropin-releasing hormone agonist. *Fertil Steril* 2007; 87: 1468.
92. Yamamoto T, Noguchi T, Tamura T, Kitawaki J, Okada H. Evidence for estrogen synthesis in adenomyotic tissues. *Am J Obstet Gynecol* 1993; 169: 734–8.
93. Gracia M, Alcalá M, Ferreri J, Rius M, Ros C, et al. Ulipristal acetate improves clinical symptoms in women with adenomyosis and uterine myomas. *J Minim Invasive Gynecol* 2018; 25: 1274–80.

94. Harada T, Ohta I, Endo Y, Sunada H, Noma H, Taniguchi F. SR-16234, a novel selective estrogen receptor modulator for pain symptoms with endometriosis: an open-label clinical trial. *Yonago Acta Med* 2018; 60: 227–33.
95. Liu X, Yuan L, Guo SW. Valproic acid as a therapy for adenomyosis. A comparative case series. *Reprod Sci* 2010; 17: 904–12.
96. Liu X, Guo SW. A pilot study on the off-label use of valproic acid to treat adenomyosis. *Fertil Steril* 2008; 89: 246–50.
97. Liu X, Guo SW. Valproic acid alleviates generalized hyperalgesia in mice with induced adenomyosis. *J Obstet Gynaecol Res* 2011; 37: 696–708.
98. Chen Y, Zhu B, Zhang H, Liu X, Guo SW. Epigallocatechin-3-gallate reduces myometrial infiltration, uterine hyperactivity, and stress levels and alleviates generalized hyperalgesia in mice induced with adenomyosis. *Reprod Sci* 2013; 20: 1478–91.
99. Zhu B, Chen Y, Zhang H, Liu X, Guo SW. Resveratrol reduces myometrial infiltration, uterine hyperactivity and stress levels and alleviates generalized hyperalgesia in mice with induced adenomyosis. *Reprod Sci* 2015; 22: 1336–49.
100. Nie J, Liu X, Leonurine attenuates hyperalgesia in mice with induced adenomyosis. *Med Sci Monit* 2017; 23: 1701–6.
101. Zhu B, Chen Y, Shen X, Liu X, Guo SW. Anti-platelet therapy holds promises in treating adenomyosis: experimental evidence. *Reprod Biol Endocrinol* 2016; 14: 66.
102. Krentel H, De Wilde RL. Complications in laparoscopic supracervical hysterectomy (LASH), especially the morcellation related. *Best Pract Res Clin Obstet Gynecol* 2016; 35: 44–50.
103. Rimbach S, Schemperschofe M. In-bag morcellation as a routine for laparoscopic hysterectomy. *Biomed Res Int* 2017; 2017: 6701916.
104. Yavuzcan A, Basbug A, Bastan M, Caglar M, Özdemir I. The effect of adenomyosis on the outcomes of laparoscopic hysterectomy. *J Turk Ger Gynecol Assoc* 2016; 17: 150–4.
105. Andres MP, Borrelli GM, Abrao MS. Advances on minimally invasive approach for benign total hysterectomy: a systematic review. *F1000Res* 2017; 6: 1295.
106. Philip CA, Le Mitouard M, Maillet L, de Saint-Hilaire P, Huisoud C, et al. Evaluation of Novasure global endometrial ablation in symptomatic adenomyosis: a longitudinal study with a 36 month follow-up. *Eur J Obstet Gynecol Reprod Biol* 2018; 227: 46–51.
107. Riley KA, Davies MF, Harkins GJ. Characteristics of patients undergoing hysterectomy for failed endometrial ablation. *JSLs* 2013; 17: 503–7.
108. Wishall KM, Price J, Pereira N, Butts SM, Della Badia CR. Postablation risk factors for pain and subsequent hysterectomy. *Obstet Gynecol* 2014; 124: 904–10.
109. Simon RA, Qudus MR, Lawrence WD, Sung CJ. Pathology of endometrial ablation failures: a clinicopathologic study of 164 cases. *Int J Gynecol Pathol* 2015; 34: 245–52.
110. Mengerink BB, van der Wurff AA, ter Haar JF, van Rooij IA, Pijnenborg JM. Effect of undiagnosed deep adenomyosis after failed NovaSure endometrial ablation. *J Minim Invasive Gynecol* 2015; 22: 239–44.
111. Nakamura K, Nakayama K, Ishikawa M, Katagiri H, Katagiri A, et al. Efficacy of multiple microwave endometrial ablation technique for menorrhagia resulting from adenomyosis. *J Obstet Gynaecol Res* 2015; 41: 1769–72.
112. Ota K, Takahashi T, Shiraishi S, Mizunuma H. Combination of microwave endometrial ablation and postoperative dienogest administration is effective for treating symptomatic adenomyosis. *J Obstet Gynecol Res* 2018; 1287–92.
113. Li JJ, Chung JPW, Wang S, Li TC, Duan H. The investigation and management of adenomyosis in women who wish to improve or preserve fertility. *Biomed Res Int* 2018; 2018: 6832685.
114. Pontrelli G, Bounous VE, Scarperi S, Minelli L, Di Spizio Sardo A, Florio P. Rare case of giant cystic adenomyoma mimicking a uterine malformation, diagnosed and treated by hysteroscopy. *J Obstet Gynaecol Res* 2015; 41: 1300–4.
115. Gordts S, Campo R, Brosens I. Hysteroscopic diagnosis and excision of myometrial cystic adenomyosis. *Gynecol Surg* 2014; 11: 273–8.
116. Giana M, Montella F, Surico D, Vigone A, Bozzola C, Ruspa G. Large intramyometrial cystic adenomyosis: a hysteroscopic approach with bipolar resectoscope: case report. *Eur J Gynaecol Oncol* 2005; 26: 462–3.
117. Sun W, Guo X, Zhu L, Fei X, Zhang Z, Li D. Hysteroscopic treatment of a cystic adenomyosis. *J Minim Invasive Gynecol* 2018; 25: 374–5.
118. Younes G, Tulandi T. Conservative Surgery for adenomyosis and results: a systematic review. *J Minim Invasive Gynecol* 2018; 25: 265–76.
119. Koukoura O, Kapsalaki E, Daponte A, Pistofidis G. Laparoscopic treatment of a large uterine cystic adenomyosis in a young patient. *BMJ Case Rep* 2015; 1: 2015.
120. Grimbizis GF, Mikos T, Tarlatzis B. Uterus-sparing operative treatment for adenomyosis. *Fertil Steril* 2014; 101: 472–87.
121. Kwack JY, Kwon YS. Laparoscopic surgery for focal adenomyosis. *JSLs* 2017; 21: pii: e2017.00014.
122. Huang X, Huang Q, Chen S, Zhang J, Lin K, Zhang X. Efficacy of laparoscopic adenomyomectomy using double-flat method for diffuse uterine adenomyosis. *BMC Womens Health* 2015; 15: 24.
123. Li Y, Qi H, Ma W, Wu C, Li X, et al. Temporarily blocking the uterine artery to dig out a diffused adenomyosis lesion treated laparoscopically. *J Minim Invasive Gynecol* 2017; 24: 349–52.
124. Kim JK, Shin CS, Ko YB, Nam SY, Yim HS, Lee KH. Laparoscopic assisted adenomyomectomy using double flap method. *Obstet Gynecol Sci* 2014; 57: 128–35.
125. Kwack JY, Im KS, Kwon YS. Conservative surgery of uterine adenomyosis via laparoscopic versus laparotomic approach in a single institution. *J Obstet Gynaecol Res* 2018; 44: 1268–73.
126. Kishi Y, Yabuta M, Taniguchi F. Who will benefit from uterus-sparing surgery in adenomyosis-associated subfertility? *Fertil Steril* 2014; 102: 802–7.
127. Rocha TP, Andres MP, Borelli GM, Abrao MS. Fertility-sparing treatment of adenomyosis in patients with infertility: a systematic review of current options. *Reprod Sci* 2018; 25: 480–6.
128. Tan J, Moriarty S, Taskin O, Allaire C, Williams C, Yong P, Bedaiwy MA. Reproductive outcomes after fertility-sparing surgery for focal and diffuse adenomyosis: a systematic review. *J Minim Invasive Gynecol* 2018; 25: 608–21.
129. Oliveira MAP, Crispi CP Jr, Brollo LC, Crispi CP, De Wilde RL. Surgery in adenomyosis. *Arch Gynecol Obstet* 2018; 297: 581–9.
130. Soave I, Wenger JM, Pluchino N, Marci R. Treatment options and reproductive outcome for adenomyosis-associated infertility. *Curr Med Res Opin* 2018; 34: 839–49.
131. Alvi FA, Glaser LM, Chaudhari A, Tsai S, Milad MP. New paradigms in the conservative surgical and interventional management of adenomyosis. *Curr Opin Obstet Gynecol* 2017; 29: 240–8.
132. Zhang L, Rao F, Setzen R. High intensity focused ultrasound for the treatment of adenomyosis: selection criteria, efficacy, safety and fertility. *Acta Obstet Gynecol Scand* 2017; 96: 707–14.
133. Cheung VY. Current status of high-intensity focused ultrasound for the management of uterine adenomyosis. *Ultrasonography* 2017; 36: 95–102.
134. Liu XF, Huang LH, Zhang C, Huang GH, Yan LM, He J. A comparison of the cost-utility of ultrasound-guided high-intensity focused ultrasound and hysterectomy for adenomyosis: a retrospective study. *BJOG* 2017; 124 (Suppl 3): 40–5.
135. Long L, Chen J, Xiong Y, Zou M, Deng Y, et al. Efficacy of high-intensity focused ultrasound ablation for adenomyosis therapy and sexual life quality. *Int J Clin Exp Med* 2015; 8: 11701–7.
136. Chen J, Chen W, Zhang L, Ki K, Peng S, et al. Safety of ultrasound-guided ultrasound ablation for uterine fibroids and adenomyosis: a review of 9988 cases. *Ultrason Sonochem* 2015; 27: 671–6.
137. Zhou M, Chen JY, Tang LD, Chen WZ, Wang ZB. Ultrasound-guided high-intensity focused ultrasound ablation for adenomyosis: the clinical experience of a single center. *Fertil Steril* 2011; 95: 900–5.
138. Zhou CY, Xu XJ, He J. Pregnancy outcomes and symptom improvement of patients with adenomyosis treated with high intensity focused ultrasound ablation. *Zhonghua Fu Chan Ke Za Zhi* 2016; 51: 845–9.
139. Hai N, Hou Q, Ding X, Dong X, Jin M. Ultrasound-guided transcervical radiofrequency ablation for symptomatic uterine adenomyosis. *Br J Radiol* 2017; 90: 20160119.
140. de Bruijn AM, Smink M, Lohle PNM, Huirne JAF, Twisk JWR, et al. Uterine artery embolization for the treatment of adenomyosis: a systematic review and meta-analysis. *J Vasc Interv Radiol* 2017; 28: 1629–42.
141. Liang E, Brown B, Rachinsky M. A clinical audit on the efficacy and safety of uterine artery embolization for symptomatic adenomyosis: results in 117 women. *Aust N Z J Obstet Gynaecol* 2018; DOI: 10.1111/ajo. 12767.
142. Keung JJ, Spies JB, Caridi TM. Uterine artery embolization: a review of current concepts. *Best Pract Res Clin Obstet Gynaecol* 2018; 46: 66–73.

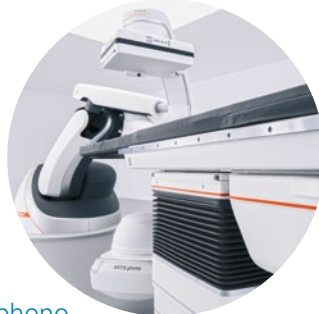Mitteilungen aus der Redaktion

Besuchen Sie unsere Rubrik

☒ Medizintechnik-Produkte



Neues CRT-D Implantat
Intica 7 HF-T QP von Biotronik



Artis pheno
Siemens Healthcare Diagnostics GmbH



Philips Azurion:
Innovative Bildgebungslösung

Aspirator 3
Labotect GmbH



InControl 1050
Labotect GmbH

e-Journal-Abo

Beziehen Sie die elektronischen Ausgaben dieser Zeitschrift hier.

Die Lieferung umfasst 4–5 Ausgaben pro Jahr zzgl. allfälliger Sonderhefte.

Unsere e-Journale stehen als PDF-Datei zur Verfügung und sind auf den meisten der marktüblichen e-Book-Readern, Tablets sowie auf iPad funktionsfähig.

☒ Bestellung e-Journal-Abo

Haftungsausschluss

Die in unseren Webseiten publizierten Informationen richten sich **ausschließlich an geprüfte und autorisierte medizinische Berufsgruppen** und entbinden nicht von der ärztlichen Sorgfaltspflicht sowie von einer ausführlichen Patientenaufklärung über therapeutische Optionen und deren Wirkungen bzw. Nebenwirkungen. Die entsprechenden Angaben werden von den Autoren mit der größten Sorgfalt recherchiert und zusammengestellt. Die angegebenen Dosierungen sind im Einzelfall anhand der Fachinformationen zu überprüfen. Weder die Autoren, noch die tragenden Gesellschaften noch der Verlag übernehmen irgendwelche Haftungsansprüche.

Bitte beachten Sie auch diese Seiten:

[Impressum](#)

[Disclaimers & Copyright](#)

[Datenschutzerklärung](#)