



# Memory immune responses and protection of chickens against a nephropathogenic infectious bronchitis virus strain by combining live heterologous and inactivated homologous vaccines

Romeu Moreira dos SANTOS<sup>1)\*</sup>, Filipe Santos FERNANDO<sup>1)</sup>,  
Maria de Fátima Silva MONTASSIER<sup>1)</sup>, Ketherson Rodrigues SILVA<sup>1)</sup>,  
Priscila Diniz LOPES<sup>1)</sup>, Caren PAVANI<sup>1)</sup>, Mariana Monezi BORZI<sup>1)</sup>,  
Cintia Hiromi OKINO<sup>2)</sup> and Helio José MONTASSIER<sup>1)</sup>

<sup>1)</sup>Department of Veterinary Pathology, Laboratory of Virology and Immunology, Universidade Estadual Paulista Júlio de Mesquita Filho (FCAV-UNESP), Jaboticabal, SP 14884-900, Brazil

<sup>2)</sup>Embrapa Pecuária Sudeste, São Carlos, SP 13560-970, Brazil

**ABSTRACT.** In this study, we evaluated antibody and cell-mediated immune (CMI) responses in the mucosal and systemic compartments and protection against challenge with a nephropathogenic Brazilian (BR-I) strain of infectious bronchitis virus (IBV) in chickens submitted to a vaccination regime comprising a priming dose of heterologous live attenuated Massachusetts vaccine followed by a booster dose of an experimental homologous inactivated vaccine two weeks later. This immunization protocol elicited significant increases in serum and lachrymal levels of anti-IBV IgG antibodies and upregulated the expression of CMI response genes, such as those encoding CD8 $\beta$  chain and Granzyme homolog A in tracheal and kidney tissues at 3, 7, and 11 days post-infection in the vaccinated chickens. Additionally, vaccinated and challenged chickens showed reduced viral loads and microscopic lesion counts in tracheal and kidney tissues, and their antibody and CMI responses were negatively correlated with viral loads in the trachea and kidney. In conclusion, the combination of live attenuated vaccine containing the Massachusetts strain with a booster dose of an inactivated vaccine, containing a BR-I IBV strain, confers effective protection against infection with nephropathogenic homologous IBV strain because of the induction of consistent memory immune responses mediated by IgG antibodies and TCD8 cells in the mucosal and systemic compartments of chickens submitted to this vaccination regime.

**KEY WORDS:** avian coronavirus, cell-mediated immunity, humoral immunity, mucosal immunity, oil adjuvant

*J. Vet. Med. Sci.*

81(4): 612–619, 2019

doi: 10.1292/jvms.18-0065

Received: 7 February 2018

Accepted: 18 February 2019

Published online in J-STAGE:  
12 March 2019

For protecting chickens against infectious bronchitis virus (IBV) infection, live attenuated vaccines [4, 20] that ideally contain the most prevalent IBV genotype/serotype in the particular region or country are usually administered [11]. However, live attenuated vaccines often elicit reduced immune responses and protection against heterologous variant strains because commercially available vaccines are unable to confer a wider spectrum of protection against these viruses. Vaccination using two heterologous attenuated vaccine strains has been recommended to circumvent this limitation and can provide a wider spectrum of protection against some field variant IBV strains [11]. However, it is still difficult to determine the combinations of attenuated heterologous viruses that may confer a more effective protection against variant IBV strains [1, 11]. Additionally, live attenuated IBV vaccine strains can be involved in the emergence of more pathogenic recombinant IBV variants [1].

An alternative for controlling IBV infection is the use of inactivated vaccines, particularly when these vaccines are preceded by one or more doses of live attenuated vaccines, including commercially available attenuated vaccines. In addition, the combined vaccination regime is more frequently used in layers and breeders for preventing relevant drops in egg production and renal lesions due to IBV strains with tropism for the urogenital tract [2, 22, 26, 35].

Immune response against IBV infection is associated with antibody and cell-mediated immune (CMI) responses [7]. In fact,

\*Correspondence to: Santos, R. M. D.: romeumdsantos@hotmail.com

©2019 The Japanese Society of Veterinary Science



This is an open-access article distributed under the terms of the Creative Commons Attribution Non-Commercial No Derivatives (by-nc-nd) License. (CC-BY-NC-ND 4.0: <https://creativecommons.org/licenses/by-nc-nd/4.0/>)

anti-IBV antibodies of IgG and IgA isotypes as well as T cell (TCD8)-mediated immune responses, particularly at mucosal sites, have been consistently associated with effective protection against IBV infection elicited by previous infection or by vaccination with live attenuated IBV vaccines [7–9, 17, 18, 21, 27]. However, antibody and TCD8 memory immune responses induced by combining live heterologous and inactivated homologous vaccines against variant nephropathogenic IBV strains as well as the correlation of these immune responses for conferring effective protection induced by the vaccination regime against this IBV pathotype remain to be better characterized. Nevertheless, it has been reported that inactivated vaccines when used without priming with live attenuated vaccines induce poor systemic immune responses and no effective protection against tracheal ciliostasis, renal lesions, and loss in egg production caused by virulent IBV strains [1, 4, 26].

In Brazil, since the last decade, despite the frequent use of Massachusetts IBV vaccines, a high number of variant IBV isolates have emerged; these strains have been phylogenetically classified by S1 gene sequencing under a separate genotype of Brazilian strains (BR-I genotype) [5, 12, 13, 16, 19, 24, 36]. In addition, some BR-I IBV strains have been characterized as nephropathogenic strains after experimental infection of specific-pathogen-free (SPF) chickens [12, 14, 15]. Recently, protectotype analysis of some nephropathogenic BR-I IBV strains demonstrated that Massachusetts live attenuated vaccines conferred only partial protection to tracheal and kidney tissues [12, 14], although the combination of Massachusetts and 793B live attenuated vaccines improved protection against these BR-I nephropathogenic strains [12]. Additionally, virus neutralization tests (VNT) showed that some BR-I genotype strains do not belong to the Massachusetts serotype [5, 34].

Thus, we conducted this study to evaluate mucosal and systemic antibody and CMI responses induced by a combined IBV vaccination regime, consisting of a priming dose with live attenuated heterologous vaccine followed by a booster dose with an inactivated homologous vaccine, to characterize the protection status against infection with a nephropathogenic BR-I virulent IBV strain and to correlate this protection status with the induced immune responses.

## MATERIALS AND METHODS

### *Virus*

A field variant strain of IBV (IBVPR-05), previously isolated and genetically characterized [24] as BR-I genotype (GenBank accession ID: GQ169242.1), was used for the preparation of an experimental inactivated vaccine using an oil adjuvant. The virus was propagated, and its infectivity titer (50% embryo infective doses, EID<sub>50</sub>) was evaluated in specific pathogen free (SPF) embryonated chicken eggs [31]. The same variant strain was also used for the experimental infection of vaccinated and non-vaccinated SPF chickens.

### *Preparation of the experimental vaccine*

A previously described general protocol [10] was adopted for the formulation of the inactivated vaccine using beta-propiolactone (BPL). In short, the viral suspension was obtained from the chorioallantoic fluid (CAF), collected from embryonated chicken eggs after inoculation with IBVPR05 strain. Before adding 0.05% BPL to inactivate IBV, the viral suspension was concentrated to  $1 \times 10^8$  EID<sub>50</sub>/ml with polyethylene glycol (PEG)-NaCl [3]. Inactivated IBVPR-05 was inoculated in SPF embryos at 9 days of age as the control of residual infectious virus, and the presence and/or absence of pathological lesions was monitored for 96 hr. After confirming viral inactivation, the oil adjuvant MONTANIDE ISA 71 VG® (SEPPIC, Puteaux, France) was added to the IBV-inactivated suspension at a proportion of 70–30% of antigen suspension, and the emulsion was prepared according to the recommendations of the manufacturer.

### *Experimental design*

Twenty-six SPF chickens of the White Leghorn lineage were divided into three groups, viz., vaccinated and challenged (Vac. Group), non-vaccinated and challenged (Non-vac Group), and non-vaccinated and non-challenged (Non-vac/Non-chal. Group). All these groups were housed separately in positive-pressure isolators with *ad libitum* access to water and food throughout the experiment. The protocol followed the Ethical Principles of Animal Experimentation adopted by the Brazilian College of Experimentation (COBEA) and was approved by the Committee on Ethics and Animal Welfare (CEBEA) of FCAV-UNESP, according to the protocol number 01193/13.

Ten chickens from the Vac. Group were vaccinated when 1 day old with a commercially available vaccine containing the live attenuated Massachusetts strain via the oculo-nasal route at the dose recommended by the manufacturer ( $10^4$  EID<sub>50</sub>). These chickens were re-vaccinated at 14 days of age with the experimental inactivated oil-adjuvanted vaccine formulated with IBVPR05 strain. At 35 days of age, vaccinated and non-vaccinated chickens were challenged with IBVPR-05 strain ( $10^4$  EID<sub>50</sub>) via the oculo-nasal route. The control chickens (Non-vac/non-chal. Group) were non-vaccinated and mock-infected at 35 days of age by administering PBS via the same route as the negative control of the infection. Samples of blood (5 ml/bird) and lachrymal secretion after the addition of 30  $\mu$ l/eyelid of saline (200  $\mu$ l/bird) were collected from chickens of all groups immediately before they were euthanized at 3, 7, and 11 days post-infection (dpi) to collect the trachea and kidney. Proximal, medial, and distal parts of trachea and kidneys samples were processed for histopathology examination, and the remaining tissue samples were subjected to rapid freezing in liquid nitrogen and stored at  $-70^\circ\text{C}$  until they were processed for RNA extraction and real time quantitative RT-PCR (RT-qPCR). Serum and lachrymal samples were stored at  $-20^\circ\text{C}$  until they were processed for the sandwich-ELISA-concanavalin A (S-ELISA-Con A) technique.

**Table 1.** Primers for specific exon regions for quantification of CD8, Granzyme A and GAPDH beta-chain gene expression

Gene	Primers (5'-3')	Acession number	Location (nt)	Product size (bp)	Exon boundary
GAPDH	Forward: AGCTGAATGGGAAGCTTACTGG Reverse: GCAGGTCAGGTCAACAACAGAG	NM_204305.1	719–792	74	4/5
CD8 $\beta$	Forward: CTGCATGGCTCCGACAATGG Reverse: ATCGACCACGTCAAGCTGGG	NM_205247.2	710–802	93	2/3
Granzyme A	Forward: GCGTAGCAGGATGGGGACAA Reverse: CCACCTGAATCCCCTCGACA	NM_204457.1	429–627	199	4/5

### Evaluation of mucosal and systemic anti-IBV antibodies

For measuring anti-IBV antibodies of the IgG isotype, the S-ELISA-Con A test described by Bronzoni *et al.* [3] and Okino *et al.* [27] was performed with a minor modification. An antigenic suspension of IBVPR05 IBV strain was used to detect specific anti-IBV antibodies of IgG isotype in the serum and lachrymal secretion samples obtained from all groups, regardless of the vaccination status, and submitted to experimental infection. The antibody levels determined by the S-ELISA-Con A test were measured as S/P values according to Bronzoni *et al.* [3]. Briefly, for each serum or lachrymal secretion test sample, the mean optical density (OD<sub>MTS</sub>) was expressed in relation to the positive reference serum/lachrymal secretion mean OD (OD<sub>MPRS</sub>) and negative reference serum/lachrymal secretion mean OD (OD<sub>MNRS</sub>) to determine positive ratios (S/P) according to the following formula:

$$S/P = \frac{OD_{MTS} - OD_{MNRS}}{OD_{MPRS} - OD_{MNRS}}$$

IBV-negative reference serum and lachrymal secretion samples consisted of a pool of four sera or lachrymal secretions collected from adult White Leghorn SPF chickens, whereas the IBV-positive reference serum/lachrymal secretion consisted of a pool of serum or lachrymal secretion samples from four White Leghorn SPF chickens, which were challenged with two doses of 10<sup>5</sup> EID<sub>50</sub> of live IBVPR05 strain administered per bird via the oculo–nasal route at three-week intervals, and these chickens were sampled one week after the second immunization. IBV-negative and IBV-positive reference sera and lachrymal secretions and experimental serum and lachrymal secretion samples were assayed in single dilutions of 1:100 (sera) and 1:20 (lachrymal secretions) by S-ELISA-Con A.

### Evaluation of viral loads and expression of CMI response genes

**RNA isolation and RT-qPCR:** Total RNA from tracheal and renal tissue samples was extracted using TRIzol Reagent® (Invitrogen, Carlsbad, CA, U.S.A.). cDNAs were obtained by reverse transcription (RT) using the Superscript III kit® (Invitrogen, Carlsbad, CA, U.S.A.). After cDNA synthesis, qPCR was performed for quantification of the viral load and CMI response genes, such as CD8 beta chain (CD8 $\beta$ ) and Granzyme homologous A, as well as the constitutive GAPDH gene following the procedures described by Okino *et al.* [27, 29]. Forward and reverse primer sets for the quantification of relative expression by qPCR of the three genes were designed to anneal to specific exons of the genes in a manner that only mRNA would serve as the template for amplification during real-time qPCR (Table 1) [29]. Another primer set specific for a region of S1 gene (forward-5'-CACGTGATGTTGGTAACACCTCTTTT-3' and reverse 5'-CCGCGGAGAACGTCTAAAACGACG-3') of IBV [27] was used to quantify the viral load in tracheal and renal tissue samples collected from all experimental groups. Linear regression was determined by plotting the logarithmic values of the copy number of the plasmid DNA containing the S1 gene insert against the cycle threshold (Ct) values to convert the Ct values of the tissue samples to the number of S1 gene copies [28]. The relative expression of CMI responses genes in tracheal and renal samples of vaccinated or non-vaccinated and infected chickens was measured as fold-change relative to the non-vaccinated and non-infected group (negative control group), and the gene expression from each tissue sample was standardized using the Cq value of GAPDH for the same tissue sample [27].

### Evaluation of microscopic lesions

After harvesting, tracheal and renal tissue samples were processed by usual histological techniques, including fixation, dehydration, diaphanization, and staining with hematoxylin-eosin (HE). Microscopic lesions were analyzed as previously recommended [6, 25] and classified as follows: –, no lesions; +, mild lesions; ++, moderate lesions; +++, severe lesions.

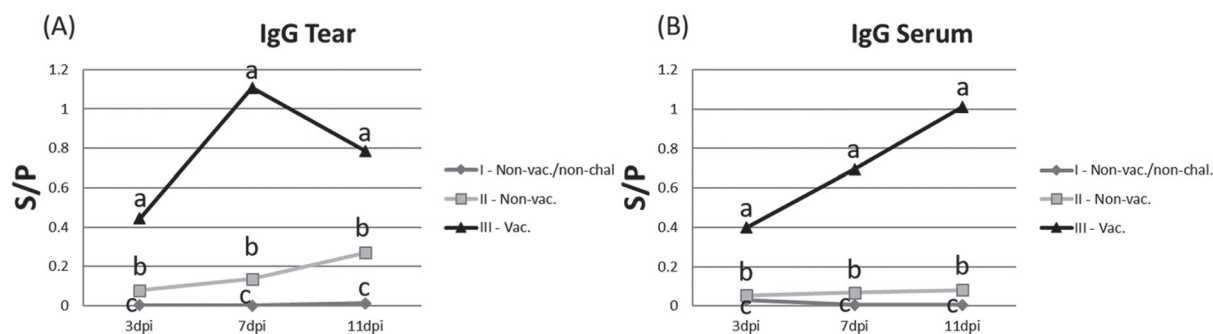
### Statistical analysis

All statistical analyses were performed using the Graphpad Prism v.6.0 software (GraphPad Software), and non-parametric tests were performed following the general recommendations of Okino *et al.* [27]. Mann-Whitney U-test (two experimental groups) was used to determine the median differences between ELISA and qPCR experimental groups. Between the trials, 95% confidence intervals were applied, and descriptive levels of  $\leq 0.05$  were considered statistically significant. Correlation analyses between the trials were determined by the Spearman method at a significance level of 5%.

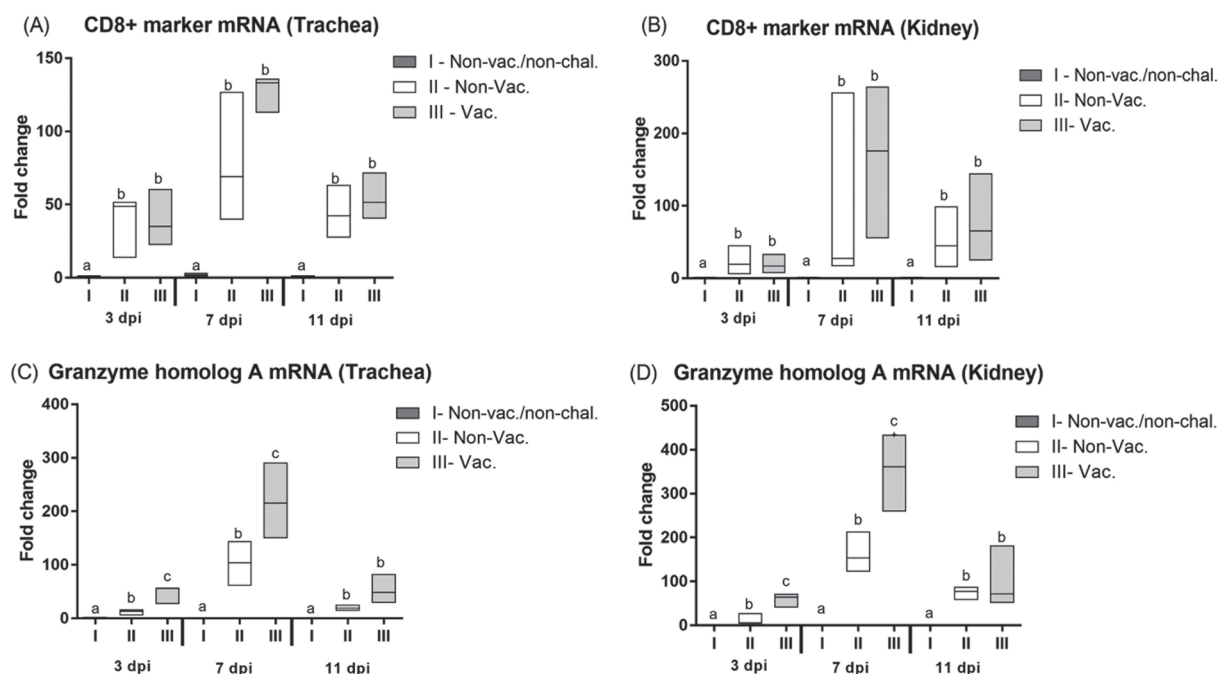
## RESULTS

### Antibody responses in the systemic and mucosal compartments

The Vac. Group showed significant and continual increases in the levels of systemic and mucosal anti-IBV IgG antibodies at all



**Fig. 1.** Kinetic profile of the anti-IBV IgG antibody responses in the lachrymal secretion (A) and serum (B) measured as median S/P values by the S-ELISA-Con A test in vaccinated (Vac. Group), non-vaccinated (Non-vac. Group) and non-vaccinated and non-challenged (Non-vac./Non-chal. Group) chickens at 3, 7, and 11 days post-infection (dpi) with BR-I virulent strain (IBVPR05). Median S/P values with different letters indicate significant difference ( $P \leq 0.05$ ), as determined by Mann-Whitney  $U$ -test.



**Fig. 2.** Kinetic profile of the relative expression of CMI response genes in tracheal and kidney samples of vaccinated (Vac. Group), non-vaccinated (Non-vac. Group) and non-vaccinated and non-challenged (Nonvac./Non-chal. Group) chickens measured as median of fold change by RT-qPCR at 3, 7, and 11 dpi. CD8 $\beta$  gene expression in tracheal (A) and kidney (B) samples and Granzyme homolog A gene expression in tracheal (C) and kidney samples (D). Medians of fold change with different letters indicate significant difference ( $P \leq 0.05$ ), as determined by Mann-Whitney  $U$ -test.

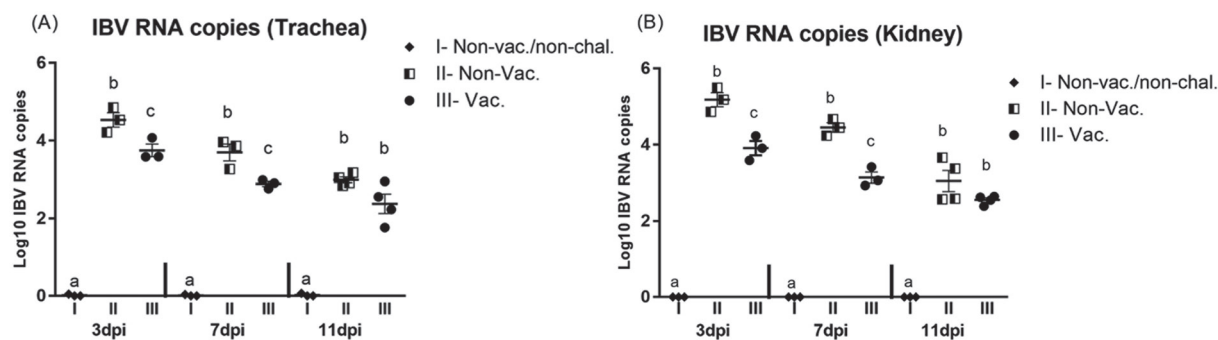
post-infection intervals (3, 7, and 11 dpi), whereas the levels of anti-IBV antibodies remained low or showed lower and delayed increases in the systemic and mucosal compartments in the Non-vac Group (Fig. 1). The Non-vac/Non-chal. Group showed absence of specific anti-IBV IgG antibodies (Fig. 1).

#### *CMI responses determined by the expression of CD8 $\beta$ and Granzyme homolog A genes*

A marked increase in the expression of CD8 $\beta$  gene was detected from 3 to 7 dpi in the trachea and kidneys samples of the Vac. and Non-vac. Groups submitted to infection with virulent IBVPR05 strain. High levels of CD8 $\beta$  gene expression were observed in these tissue samples of the Vac. Group at 7 dpi, although no significant differences were recorded between the levels of CD8 $\beta$  gene expression between the Vac. and Non-vac Groups. At 11 dpi, the expression levels of CD8 $\beta$  declined moderately and were close to the levels recorded at 3 dpi in the Vac. and Non-vac Groups (Fig. 2A and 2B).

Similar high increases were observed in the expression profile of Granzyme homolog A gene after challenging the chickens with IBVPR05 strain; however, increases in the expression of this gene were significantly different in tracheal and renal tissue samples





**Fig. 3.** Viral load measured as log10 number of copies of the S1 gene of IBV by RT-qPCR in tracheal (A) and kidney (B) tissues of vaccinated (Vac Group), non-vaccinated (Non-vac Group) and non-vaccinated and non-challenged (Non-vac./Non-chal. Group) chickens. Medians of number of copies of the S1 gene of IBV with different letters indicate significant difference ( $P \leq 0.05$ ), as determined by Mann-Whitney *U*-test.

**Table 2.** Microscopic pathological changes observed in the kidney and trachea of groups vaccinated and challenged with IBVPR-05 variant (Vac. Group) and non-vaccinated and challenged (Non-vac. Group) with IBVPR-05 variant

Tissue		Trachea						No. Affected/ No. Tested <sup>b)</sup>	Kidney						No. Affected/ No. Tested <sup>b)</sup>
Days post-infection	3 dpi	7 dpi		11 dpi		3 dpi	7 dpi		11 dpi						
Group	Microscopic lesions						Microscopic lesions								
	Ep. Dec.	Infl. Inf.	Ep. Dec.	Infl. Inf.	Ep. Dec.	Infl. Inf.	Ep. Deg.	Infl. Inf.	Ep. Deg.	Infl. Inf.	Ep. Deg.	Infl. Inf.			
Vac.	—	—	—	+(1/3) a)	—	—	1/10	—	—	—	—	—	—	0/10	
Non-vac.	—	—	+++ <sup>(3/3)</sup>	+++ <sup>(3/3)</sup>	—	+(1/3)	7/10	++ <sup>(1/3)</sup>	+(2/3)	—	+++ <sup>(2/3)</sup>	—	+++ <sup>(2/3)</sup>	7/10	

Score of microscopic lesions: (–), no lesions; (+), mild lesions; (++) moderate lesions; (+++), severe lesions. a) (Number of chickens with microscopic lesions / number of examined chickens per group and post infection interval). Ep. Dec.: Epithelial deciliation; Infl. Inf.: Inflammatory infiltration; Ep. Deg.: Epithelial degeneration. b) Number out of 10 challenged chickens showing any microscopic lesions in trachea and/or kidney. c) Number out of 10 showing any sign indicative of IB-induced kidney damage.

of the Vac. Group compared to those observed in the Non-vac. Group at 3 and 7 dpi (Fig. 2C and 2D). At 11 dpi, the expression of Granzyme homolog A gene declined markedly in the Vac. and Non-vac Groups compared to the expression levels observed at 7 dpi.

The Non-vac./Non-chal. Group showed basal levels of expression of CD8 $\beta$  and Granzyme homolog A genes.

#### Evaluation of IBV replication in the trachea and kidney

IBV replication, measured as copy number of IBV S1 gene (viral load), in tracheal and kidney samples of the Vac. Group was significantly lower ( $P \leq 0.05$ ) than that detected in the same tissue samples of the Non-vac. Group at 3 and 7 dpi. At 11 dpi, the copy number of IBV S1 gene further declined by 10- and 100-fold in the Non-vac. Vac. Group, respectively (Fig. 3). No copies of IBV S1 gene were detected in the Non-vac./Non-chal. Group.

#### Microscopic pathological alterations

Histological analysis revealed lower scores of tracheal and renal microscopic lesions, and fewer vaccinated birds in the Vac. Group were affected compared to those in Non-vac. Group (Table 2). Moreover, more abundant and prominent microscopic lesions were observed in tracheal and kidney samples of the Non-vac. Group, whereas slight or no microscopic lesions were detected in these organs of the Vac. Group (Table 2).

#### Correlation between antibody and CMI responses and tissue viral loads

IgG anti-IBV antibody levels in the mucosal (lachrymal secretion) and systemic (serum) compartments exhibited high negative correlation coefficients (*r*) with the viral loads detected in the trachea and kidney. The correlation coefficients for tracheal viral load were  $-0.71$  and  $-0.78$  for lachrymal and serum IgG anti-IBV antibodies, respectively, whereas for kidney viral load, the correlation coefficients were  $-0.87$  and  $-0.86$  for lachrymal and serum IgG antibodies, respectively.

By comparing the results of viral replication and expression levels of CMI genes, moderate negative correlations were observed for Granzyme homolog A and CD8 $\beta$  gene expression in tracheal and kidney samples. The correlation coefficients were  $-0.40$  and  $-0.38$  for Granzyme homolog A gene expression in tracheal and kidney samples, respectively, and  $-0.46$  and  $-0.36$  for CD8 $\beta$  gene expression, respectively.

## DISCUSSION

In the current study, based on the absence of relevant microscopic lesions in the trachea and kidneys and the presence of lower viral loads in these organs, all chickens primed with Massachusetts live attenuated vaccine at 1 day of age and revaccinated two weeks later with the oil-adjuvanted vaccine, containing the inactivated BR-I IBV strain, were effectively protected against the infection with homologous nephropathogenic strain of this genotype. The vaccinated birds produced high levels of lachrymal and serum IgG anti-IBV antibodies and exhibited increased expression of CMI genes, such as those encoding CD8 $\beta$  and Granzyme homolog A, in tracheal and kidney tissues after challenge.

Regarding anti-IBV IgG antibody responses in the Vac. Group, we assumed that the kinetic profile of this response was due to the development of memory B lymphocytes in these birds after administration of Massachusetts live attenuated vaccine at 1 day of age and revaccination with inactivated BR-I IBV strain in an oil adjuvanted vaccine two weeks later compared to that observed in the Non-vac. Group.

Although IgA anti-IBV antibodies are vital in conferring protection to the upper respiratory mucosa of chickens [7, 8, 27, 30], we did not evaluate the isotype of these antibodies in the current study because we targeted mucosal and systemic antibody responses, which are predominantly mediated by IgG antibodies, as they play more relevant roles against nephropathogenic IBV strains [22]. Moreover, mucosal IgG anti-IBV antibodies are also effectively associated with conferring immune protection against IBV infection [17, 27]. Indeed, memory humoral immune response induced by booster dose of IBV attenuated vaccines is characterized by the upregulation of  $\gamma$  immunoglobulin heavy chain (IgG) gene expression [17] and predominance of IgG anti-IBV secreting cells and antibodies compared to other isotypes in the mucosal compartment of chickens [30].

Contrary to the importance of anti-IBV antibodies in the protective mechanisms, a lack of relevant correlation between pre-challenge levels of serum IgG anti-IBV antibodies and the protection of upper respiratory tract has been reported [4, 7, 33]. However, little has been investigated with regard to the post-challenge levels of mucosal and systemic anti-IBV IgG antibodies and their association with protection against IBV infection, which was demonstrated in this study, because the increase in these antibody titers after a challenge indicates the activation of memory B cell responses in immunized chickens [17, 18, 27, 32]. Additionally, anti-IBV IgG antibody levels in our study were negatively correlated with the viral loads in tracheal and kidney tissues of the Vac. Group.

Moreover, administration of live attenuated Massachusetts vaccine followed by BR-I IBV inactivated vaccine after challenging the chickens resulted in the induction of memory CMI responses in the mucosal and systemic compartments. In the current study, these CMI responses were characterized by a significant and earlier upregulation in the expression of Granzyme homolog A gene in tracheal and kidney samples of the Vac. Group at 3 and 7 dpi.

Although the expression of CD8 $\beta$  gene increased markedly in tracheal and kidney samples of the Vac. Group at the same post-infection time-points, the expression levels of this gene did not differ significantly from those recorded in the Non-vac. Group. We hypothesized that the significant differences in the expression of Granzyme homolog A gene could be ascribed to the increased expression of this gene by effector cytotoxic effector T cells (CTLs), which are present in higher numbers in IBV-infected tissues of the Vac. Group. However, we also assumed that immature TCD8 cells were strongly recruited to the IBV-infected tissues of both the Vac. and Non-vac. Groups, in which these T cells proliferated, thereby increasing the expression of CD8 $\beta$  gene but not that of Granzyme homolog A. Therefore, no significant difference was observed between the expression of CD8 $\beta$  gene between the Vac. and Non-vac. Groups.

Similar to Gurjar *et al.* [18], we observed CMI memory responses, characterized by increases in the expression of Granzyme homolog A gene, by performing an immunization protocol by combining live attenuated priming vaccine followed by a booster dose with an inactivated IBV vaccine in experimentally infected chickens. Conversely, it can be speculated that Granzyme homolog A is also produced by natural killer (NK) cells, but in our study, the kinetic profile of Granzyme homolog A gene expression in the Vac. Group was associated with the expression of CD8 $\beta$  gene, which is an exclusive marker of CTLs [23, 28, 29]. Interestingly, CTLs are associated with the clearance of virus-infected cells and effective protection against another nephropathogenic IBV (Gray strain) in naïve chickens receiving adoptive transference of memory TCD8 cells [9].

In addition, the importance of CMI responses induced by combining live attenuated Massachusetts vaccine with BR-I IBV inactivated vaccine affording protection to tracheal and kidney tissues is also supported by the moderate negative correlations found between the expression of CD8 $\beta$  and Granzyme homolog A genes and the viral loads detected in tracheal and renal samples of the Vac. Group. Indeed, the correlations we observed confirmed the previous findings of Okino *et al.* [27] who determined CMI responses by measuring the expression of CD8 and Granzyme homolog A genes in tracheal tissues of chickens immunized with Massachusetts live attenuated vaccine and challenged with virulent M41 strain of IBV.

In conclusion, a combination of the commercially available live attenuated vaccine containing Massachusetts strain and the inactivated vaccine containing a BR-I IBV strain has the ability to confer effective immune protection against infection with nephropathogenic homologous IBV strain because of the induction of consistent memory immune responses mediated by IgG antibodies and effector TCD8 cells in the mucosal and systemic compartments in chickens submitted to this vaccination regime. Additionally, the antibody and CMI memory responses induced by this vaccination protocol are relevantly associated with the protection status of chickens vaccinated and challenged with a nephropathogenic IBV strain, highlighting the importance of these immune responses to confer protection against this pathotype of IBV and stressing the potential of combining heterologous live attenuated vaccines with homologous inactivated vaccines for efficiently controlling infection caused by nephropathogenic variant IBV strains, such as those of BR-I genotype.

CONFLICT OF INTEREST. The authors declare that they have no conflict of interest.

ACKNOWLEDGMENTS. The authors are grateful to Conselho Nacional de Desenvolvimento Científico e Tecnológico (CNPq Proc. 578453/2008-8) and FAPESP (Proc. 01/14950-3 and Proc. 07/55070-2) for financial support and CAPES for MsC scholarship to RMS. The authors wish to acknowledge Embrapa Swine and Poultry, Concórdia, SC, Brazil, for providing some laboratory reagents and SPF embryonated chicken eggs; Dr. Neuza Maria Frazatti Gallina from Instituto Butantan-SP, Brazil, for donating beta-propiolactone; and Sérgio Cabral from SEPPIC Brazil for supplying the Montanide ISA 71 adjuvant.

## REFERENCES

1. Bande, F., Arshad, S. S., Bejo, M. H., Moeini, H. and Omar, A. R. 2015. Progress and challenges toward the development of vaccines against avian infectious bronchitis. *J. Immunol. Res.* **2015**: 424860. [Medline] [CrossRef]
2. Box, P. G. and Ellis, K. R. 1985. Infectious bronchitis in laying hens: interference with response to emulsion vaccine by attenuated live vaccine. *Avian Pathol.* **14**: 9–22. [Medline] [CrossRef]
3. Bronzoni, R. V. M., Fatima, M., Montassier, S., Pereira, G. T., Gama, N. M., Sakai, V. and Montassier, H. J. 2005. Detection of infectious bronchitis virus and specific anti-viral antibodies using a Concanavalin A-Sandwich-ELISA. *Viral Immunol.* **18**: 569–578. [Medline] [CrossRef]
4. Cavanagh, D. 2007. Coronavirus avian infectious bronchitis virus. *Vet. Res.* **38**: 281–297. [Medline] [CrossRef]
5. Chacón, J. L., Rodrigues, J. N., Assayag Júnior, M. S., Peloso, C., Pedroso, A. C. and Ferreira, A. J. P. 2011. Epidemiological survey and molecular characterization of avian infectious bronchitis virus in Brazil between 2003 and 2009. *Avian Pathol.* **40**: 153–162. [Medline] [CrossRef]
6. Chen, B. Y., Hosi, S., Nunoya, T. and Itakura, C. 1996. Histopathology and immunohistochemistry of renal lesions due to infectious bronchitis virus in chicks. *Avian Pathol.* **25**: 269–283. [Medline] [CrossRef]
7. Chhabra, R., Chantrey, J. and Ganapathy, K. 2015a. Immune Responses to Virulent and Vaccine Strains of Infectious Bronchitis Viruses in Chickens. *Viral Immunol.* **28**: 478–488. [Medline] [CrossRef]
8. Chhabra, R., Forrester, A., Lemiere, S., Awad, F., Chantrey, J. and Ganapathy, K. 2015b. Mucosal, Cellular, and Humoral Immune Responses Induced by Different Live Infectious Bronchitis Virus Vaccination Regimes and Protection Conferred against Infectious Bronchitis Virus Q1 Strain. *Clin. Vaccine Immunol.* **22**: 1050–1059. [Medline] [CrossRef]
9. Collisson, E. W., Pei, J., Dzielawa, J. and Seo, S. H. 2000. Cytotoxic T lymphocytes are critical in the control of infectious bronchitis virus in poultry. *Dev. Comp. Immunol.* **24**: 187–200. [Medline] [CrossRef]
10. Coria, M. F. and Booth, G. D. 1972. Immune response in chickens to infectious bronchitis virus, strain 33. 3. Beta-propiolactone-inactivated and live-virus vaccines compared by statistical methods. *Avian Dis.* **16**: 767–773. [Medline] [CrossRef]
11. De Wit, J. J., Cook, J. K. A. and van der Heijden, H. M. 2011. Infectious bronchitis virus variants: a review of the history, current situation and control measures. *Avian Pathol.* **40**: 223–235. [Medline] [CrossRef]
12. De Wit, J. J., Brandão, P., Torres, C. A., Koopman, R. and Villarreal, L. Y. 2015. Increased level of protection of respiratory tract and kidney by combining different infectious bronchitis virus vaccines against challenge with nephropathogenic Brazilian genotype subcluster 4 strains. *Avian Pathol.* **44**: 352–357. [Medline] [CrossRef]
13. Felipe, P. A. N., da Silva, L. H. A., Santos, M. M. A. B., Spilki, F. R. and Arns, C. W. 2010. Genetic diversity of avian infectious bronchitis virus isolated from domestic chicken flocks and coronaviruses from feral pigeons in Brazil between 2003 and 2009. *Avian Dis.* **54**: 1191–1196. [Medline] [CrossRef]
14. Fernando, F. S., Montassier, M. F. S., Silva, K. R., Okino, C. H., Oliveira, E. S., Fernandes, C. C., Bandarra, M. B., Gonçalves, M. C. M., Borzi, M. M., Santos, R. M., Vasconcelos, R. O., Alessi, A. C. and Montassier, H. J. 2013. Nephritis associated with a S1 variant Brazilian isolate of infectious bronchitis virus and vaccine protection test in experimentally infected chickens. *Int. J. Poult. Sci.* **11**: 639–646. [CrossRef]
15. Fernando, F. S., Okino, C. H., Silva, K. R., Fernandes, C. C., Gonçalves, M. C. M., Montassier, M. F. S., Vasconcelos, R. O. and Montassier, H. J. 2015. Increased expression of interleukin-6 related to nephritis in chickens challenged with an avian infectious bronchitis virus variant. *Pesqui. Vet. Bras.* **35**: 216–222. [CrossRef]
16. Fraga, A. P., Balestrin, E., Ikuta, N., Fonseca, A. S., Spilki, F. R., Canal, C. W. and Lunge, V. R. 2013. Emergence of a new genotype of avian infectious bronchitis virus in Brazil. *Avian Dis.* **57**: 225–232. [Medline] [CrossRef]
17. Guo, X., Rosa, A. J., Chen, D. G. and Wang, X. 2008. Molecular mechanisms of primary and secondary mucosal immunity using avian infectious bronchitis virus as a model system. *Vet. Immunol. Immunopathol.* **121**: 332–343. [Medline] [CrossRef]
18. Gurjar, R. S., Gulley, S. L. and van Ginkel, F. W. 2013. Cell-mediated immune responses in the head-associated lymphoid tissues induced to a live attenuated avian coronavirus vaccine. *Dev. Comp. Immunol.* **41**: 715–722. [Medline] [CrossRef]
19. Jackwood, M. W., Hall, D. and Handel, A. 2012. Molecular evolution and emergence of avian gammacoronaviruses. *Infect. Genet. Evol.* **12**: 1305–1311. [Medline] [CrossRef]
20. Jackwood, M. W. and De Wit, J. J. 2013. Infectious bronchitis. pp. 139–159. In: Diseases of Poultry, 13th ed. (Swayne, G., McDougald, L. R., Nolan, L. K., Suarez, D. L. and Nair, V. L. eds.), Blackwell Publishing Professional, Ames.
21. Kotani, T., Wada, S., Tsukamoto, Y., Kuwamura, M., Yamate, J. and Sakuma, S. 2000. Kinetics of lymphocytic subsets in chicken tracheal lesions infected with infectious bronchitis virus. *J. Vet. Med. Sci.* **62**: 397–401. [Medline] [CrossRef]
22. Ladman, B. S., Pope, C. R., Ziegler, A. F., Swieczkowski, T., Callahan, C. J., Davison, S. and Gelb, J. Jr. 2002. Protection of chickens after live and inactivated virus vaccination against challenge with nephropathogenic infectious bronchitis virus PA/Wolgemuth/98. *Avian Dis.* **46**: 938–944. [Medline] [CrossRef]
23. Luhtala, M. 1998. Chicken CD4, CD8alpha, and CD8alphaalpha T cell co-receptor molecules. *Poult. Sci.* **77**: 1858–1873. [Medline] [CrossRef]
24. Montassier, M. F. S., Brentano, L., Richtzenhain, L. J. and Montassier, H. J. 2006. Genetic diversity on s1 glycoprotein of avian infectious bronchitis virus strains isolated in Brazil between 1988–2000. pp. 119–131. In: International Symposium on Avian Coronavirus, 5. Germany, Proceedings International Symposium On Avian Coronavirus.
25. Nakamura, K., Cook, J. K. A., Otsuki, K., Huggins, M. B. and Frazier, J. A. 1991. Comparative study of respiratory lesions in two chicken lines of different susceptibility infected with infectious bronchitis virus: histology, ultrastructure and immunohistochemistry. *Avian Pathol.* **20**: 241–257. [Medline] [CrossRef]
26. OIE 2013. Terrestrial manual. pp. 1–15. In: Avian Infectious Bronchitis, Chapter 2.3.2, Office International des Epizooties, Paris.

27. Okino, C. H., Alessi, A. C., Montassier, M. F., Rosa, A. J. M., Wang, X. and Montassier, H. J. 2013. Humoral and cell-mediated immune responses to different doses of attenuated vaccine against avian infectious bronchitis virus. *Viral Immunol.* **26**: 259–267. [[Medline](#)] [[CrossRef](#)]
28. Okino, C. H., dos Santos, I. L., Fernando, F. S., Alessi, A. C., Wang, X. and Montassier, H. J. 2014. Inflammatory and cell-mediated immune responses in the respiratory tract of chickens to infection with avian infectious bronchitis virus. *Viral Immunol.* **27**: 383–391. [[Medline](#)] [[CrossRef](#)]
29. Okino, C. H., Mores, M. A. Z., Trevisol, I. M., Coldebella, A., Montassier, H. J. and Brentano, L. 2017. Early immune responses and development of pathogenesis of avian infectious bronchitis viruses with different virulence profiles. *PLoS One* **12**: e0172275. [[Medline](#)] [[CrossRef](#)]
30. Orr-Burks, N., Gulley, S. L., Toro, H. and van Ginkel, F. W. 2014. Immunoglobulin A as an early humoral responder after mucosal avian coronavirus vaccination. *Avian Dis.* **58**: 279–286. [[Medline](#)] [[CrossRef](#)]
31. Owen, R. L., Cowen, B. S., Hattel, A. L., Naqi, S. A. and Wilson, R. A. 1991. Detection of viral antigen following exposure of one-day-old chickens to the Holland-52 strain of IBV. *Avian Pathol.* **20**: 663–673. [[Medline](#)] [[CrossRef](#)]
32. Pei, J. and Collisson, E. W. 2005. Specific antibody secreting cells from chickens can be detected by three days and memory B cells by three weeks post-infection with the avian respiratory coronavirus. *Dev. Comp. Immunol.* **29**: 153–160. [[Medline](#)] [[CrossRef](#)]
33. Raggi, L. G. and Lee, G. G. 1965. Lack of correlation between infectivity, serologic response and challenge results in immunization with an avian infectious bronchitis vaccine. *J. Immunol.* **94**: 538–543. [[Medline](#)]
34. Santos Fernando, F., Coelho Kasmanas, T., Diniz Lopes, P., da Silva Montassier, M. F., Zanella Mores, M. A., Casagrande Mariguela, V., Pavani, C., Moreira Dos Santos, R., Assayag, M. S. Jr. and Montassier, H. J. 2017. Assessment of molecular and genetic evolution, antigenicity and virulence properties during the persistence of the infectious bronchitis virus in broiler breeders. *J. Gen. Virol.* **98**: 2470–2481. [[Medline](#)] [[CrossRef](#)]
35. Timms, L. M. and Bracewell, C. D. 1983. Cell mediated and humoral immune response of chickens to inactivated oil-emulsion infectious bronchitis vaccine. *Res. Vet. Sci.* **34**: 224–230. [[Medline](#)] [[CrossRef](#)]
36. Villarreal, L. Y. B., Sandri, T. L., Souza, S. P., Richtzenhain, L. J., de Wit, J. J. and Brandao, P. E. 2010. Molecular epidemiology of avian infectious bronchitis in Brazil from 2007 to 2008 in breeders, broilers, and layers. *Avian Dis.* **54**: 894–898. [[Medline](#)] [[CrossRef](#)]