

## Original Article

### *Bartonella henselae* Neuroretinitis in Patients without Cat Scratch

Hande Celiker<sup>1\*</sup>, Haluk Kazokoglu<sup>1</sup>, Muhsin Eraslan<sup>1</sup>, Eren Cerman<sup>1</sup>, and Levent Karabas<sup>2</sup>

<sup>1</sup>Department of Ophthalmology, Marmara University School of Medicine, Istanbul; and

<sup>2</sup>Department of Ophthalmology, Kocaeli University School of Medicine, Kocaeli, Turkey

**SUMMARY:** Cat scratch disease (CSD) is a syndrome characterized by lymphadenopathy, fever, and skin lesions following a cat scratch or bite. *Bartonella henselae* is the primary bacterial agent responsible for CSD. In this report, we describe cases with atypical presentation of serologically proven *B. henselae* neuroretinitis. In this study, 3 patients with neuroretinitis were evaluated. Animal contact histories; results of ocular examinations and systemic investigations; clinical findings; and treatment compliance of the patients were assessed. All patients denied history of contact with cats or other animals, and they did not have CSD findings. Serologic testing via indirect immunofluorescence assay (IFA) was used to diagnose *Bartonella* neuroretinitis. The IFA test results were positive for all patients. Two patients were treated with antibiotics. Optic disc edema and macular exudates resolved gradually, and at their last follow-up visits, all signs had disappeared. There was no disease recurrence after the completion of treatment. Serious complications were seen in the untreated patient. In conclusion, *B. henselae* infection should be considered even when there are no systemic signs and symptoms of CSD in patients with neuroretinitis.

## INTRODUCTION

Neuroretinitis (NR) is an uncommon inflammatory optic neuropathy characterized by optic disc swelling and formation of a partial or complete macular star figure. Cat scratch disease (CSD), which is caused by the gram-negative aerobic bacillus *Bartonella henselae*, has been implicated as a cause of NR (1). CSD typically presents with subacute lymphadenopathy, fever, malaise, chills, and small skin lesions following a cat scratch or bite. Contact with infected animals (cats, kittens, or cat fleas) through scratched skin lesions and inoculation with *B. henselae* causes CSD (1). Ocular involvement has been estimated to occur in 5% to 10% of patients with CSD, with NR occurring in 1% to 2% of patients (1,2). Almost all patients with CSD give a history of contact with a cat, and about 73% of cases have history of traumatic cat exposure (3). At the time of primary *B. henselae* infection, a small macule, papule, pustule, or vesicle may form at the inoculation site, which can advance to the systemic reaction characterized by regional lymphadenopathy and the other symptoms (1,4). It is unusual to have ocular findings without systemic CSD (3). This report describes cases of serologically proven *B. henselae* neuroretinitis that had no signs of systemic involvement and did not have cat or other animal contact histories.

## MATERIALS AND METHODS

The study protocol was approved by the local institutional ethics board, and the study was conducted according to the tenets of the Declaration of Helsinki. Informed consent for various treatments was acquired from the patients. Uveitis was described using the Standardization of Uveitis Nomenclature (SUN) Working Group terminology (5).

Between January 2013 and September 2017, 3 patients with unilateral neuroretinitis were referred to our institute. All of them denied a history of a cat scratch, yet they all had CSD findings, such as lymphadenopathy, flu-like illness with coryzal symptoms, and dermatological signs. All patients were immunocompetent. Complete ophthalmologic examinations, including assessment of the best-corrected visual acuity (VA), slit-lamp biomicroscopy, tonometry, and funduscopy, were performed during the visit to the ophthalmology clinic. In all cases, the pupils were isocoric and reacted to light in the affected eye. Digital color fundus photography and optical coherence tomography (OCT) were performed at least once and additionally whenever necessary. Presence of macular edema was assessed using OCT and followed. In suitable patients, fundus angiography (FA) was used for the evaluation of posterior segment inflammation. Anterior chamber (AC) inflammation was treated with topical prednisolone acetate 1% administered every hour per day and topical cyclopentolate hydrochloride 1% twice per day. Patients were also evaluated by rheumatology, neurology, and infectious disease consultants. Two of the patients were treated with empiric systemic antibiotics based on the suspicion for CSD at the initial examination. All results of laboratory work-up, including complete blood count, biochemistry profile, erythrocyte sedimentation rate, and tuberculin skin test, were within normal limits. Results of serologic studies excluded the presence of *Toxoplasma*

Received December 13, 2017. Accepted May 25, 2018.

J-STAGE Advance Publication June 29, 2018.

DOI: 10.7883/yoken.JJID.2017.518

\*Corresponding author: Mailing address: Fevzi Çakmak Mah. Muhsin Yazıcıoğlu Cad. No:10 Pendik-İstanbul/Turkey Marmara University School of Medicine Department of Ophthalmology. Tel: +90 532 1577740, Fax: +90 216 6570695, E-mail: drhandeceliker@yahoo.com

Table 1. The clinical characteristics of the Bartonella neuroretinitis patients  
Demographic features, systemic and ophthalmic manifestations, treatment modalities and responses were summarized

	Case 1	Case 2	Case 3
Age	21	20	10
Gender	F	M	F
Systemic findings	No	No	No
Lymphadenopathy	No	No	No
History of cat contact	No	No	No
Involved eye	Right	Left	Left
APD	Trace	Trace	Trace
Anterior uveitis	Yes	No	No
Vitritis	Yes	No	No
Papillitis	Diffuse	Diffuse	Diffuse
Macular star	Yes	Yes	Yes
IFA titers	(IgM 1/100; IgG 1/512)	(IgM 1/512; IgG 1/100)	(IgM 1/128; IgG 1/320)
Initial VA	20/40	20/400	20/100
Topical Tx	Yes	No	No
Systemic Tx	No	Cip, Dox, Rif	Azt, Dox, Rif, CS
Days before Tx	—	14	7
Last VA	20/25	20/20	20/20
Initial OCT (micron)	395	276	347
Last OCT (micron)	354	240	No data
Ocular complication	Recurrent ME, mild IOP elevations, ERM	No	Mild optic disc pallor
Follow-up time (month)	38	24	10

APD, afferent pupillary defect; Azt, azithromycin; Cip, ciprofloxacin; CS, corticosteroid; Dox, doxycycline; ERM, epiretinal membrane; IFA, immunofluorescence antibody analysis; IOP, intra ocular pressure; ME, macular edema; OCT, optical coherence tomography; Rif, rifampicin; Tx, treatment; VA, visual acuity.

*gondii*, *Borrelia burgdorferi*, *Treponema pallidum*, human immunodeficiency virus, and herpes simplex virus. In all cases, serologic testing with indirect immunofluorescence assay (IFA) (EUROIMMUN® Medizinische Labordiagnostika AG, Luebeck, Germany) was used to diagnose Bartonella neuroretinitis (positive ranges: IgM > 1:16, IgG > 1:64). Results of serological tests for *B. henselae* were positive in all patients. Subsequently, their treatments were switched to convenient antibiotics. The *B. henselae* serological tests were repeated in the infectious disease department due to the absence of systemic findings. Patients' characteristics are summarized in Table 1.

## RESULTS

**Case 1:** A 21-year-old woman complained of sudden reduction in vision in the right eye (RE) for 2 weeks. At the initial ophthalmic examination, the VA was 20/40 in the RE and 20/25 in the left eye (LE). The intraocular pressure (IOP) was 16 mm Hg in the RE and 15 mm Hg in the LE; the slit-lamp examination revealed mild (2+) cells in the AC and vitreous of the RE, and the AC and vitreous body were normal in the LE. Fundus examination of the RE revealed optic disc (OD) swelling and serous macular detachment with hard stellate exudates. The left fundus was unremarkable. The presence of macular edema (ME) was confirmed by using OCT. Results of FA examination were normal in the LE; the RE showed diffuse optic nerve leakage. Leakage was noted from the OD toward the fovea during the late phase of the angiography. The patient did not report flu-like symptoms and did not have lymphadenopathy. The patient did not own any cats. Based on the findings on

the systemic examination, which was performed by an infectious disease consultant, there was no evidence of CSD or any other infectious disease. Paravulbar steroid injection of methylprednisolone Acetate (Depo-Medrol®, 40 mg/ml., Pfizer, New York, NY, USA) was applied to the RE. Topical treatment was started for anterior uveitis. Although her follow-up visit was scheduled, the patient was not admitted to our clinic until 3 months later. Titers of *B. henselae* antibodies were positive (at a dilution of 1:100 for IgM and 1:512 for IgG). The patient was not treated with any systemic medication due to her delayed control examination. During the follow-up period, the patient suffered from recurrent ME attacks. She was treated with intravitreal anti-vascular endothelial growth factor injections. When the IOP increased, anti-glaucoma medications were used intermittently. At the last ophthalmic examination, the VA was 20/25 in both eyes; the slit-lamp examination revealed trace cells in the right AC and no cells in the LE; and IOP was 12 mm Hg in the RE and 11 mm Hg in the LE. Fundus examination revealed no remarkable findings suggestive of active posterior uveitis in either eye; nevertheless, the epiretinal membrane remained in the RE.

**Case 2:** A 20-year-old Chechen male patient complained of acute blurred vision in the LE for 2 weeks. The VA was 20/20 in the RE and 20/400 in the LE. The IOP was 14 mm Hg in both eyes, and the slit-lamp examination revealed no cells in the AC or vitreous bilaterally. Results of fundus examination of the RE were normal. In the LE, OD swelling with a stellate pattern of lipid exudates surrounding the macula was observed. OCT examination ruled out serous macular detachment, and regional lymphadenopathy and flu-like symptoms were absent. He denied being scratched by

a cat or any other animal. He was suspected to have Bartonella neuroretinitis, and ciprofloxacin (750 mg per day) was initiated. All systemic evaluations (including an infectious disease assessment) were performed, and there were no remarkable findings. Titers of *B. henselae* antibodies were positive at a dilution of 1:512 for IgM and 1:100 for IgG. Based on these serologic results, the treatment was switched to doxycycline (200 mg per day) and rifampicin (600 mg per day) for 6 weeks. Three weeks later, convalescent serologic test results were positive for IgM (1:256) and for IgG (1:320). The fundoscopic examination revealed the OD swelling and macular exudates had partially resolved in the LE (Fig. 1). No severe complications occurred during the follow-up period. At the final ophthalmic examination, the VA was 20/20 in both eyes; the slit-lamp examination revealed normal findings in both eyes; and the IOP was 14 mm Hg in the RE and 13 mm Hg the LE. Results of fundus evaluation were normal in the RE. Examination revealed no sequelae in the affected eye.

**Case 3:** A 10-year-old girl presented with loss of vision in the LE for one week. The VA was 20/20 in the RE and 20/100 in the LE. The IOP was 16 mm Hg in both eyes, and the slit-lamp examination revealed no cells in the AC or vitreous bilaterally. The right fundus

was normal. The left fundus showed OD edema concomitant with macular stellate exudates. Serous macular detachment was detected by using OCT, and there were hyperreflective dots in the inner retinal layers casting a shadow on the posterior retinal layers and choroid. The child, as well as the parents, denied any previous contact with or trauma associated with a cat. The parents stated that the child had no systemic signs of the disease. Azithromycin (400 mg per day for 5 days) was started due to the suspicion of Bartonella neuroretinitis. The pediatric infectious disease specialist concluded that there were no signs of active CSD. Results of neurological assessment were normal. Titers of *B. henselae* antibodies were positive for IgM (1:128) and for IgG (1:320). Afterward, the treatment was switched to doxycycline (200 mg per day) and rifampicin (200 mg per day) for 6 weeks by a pediatric infectious disease specialist. A corticosteroid (CS) (methylprednisolone, 40 mg per day) was added to this antibiotic treatment for 2 weeks. At the fourth week of the treatment, the VA was 20/20 in the RE and 20/50 in the LE; the slit-lamp examination revealed normal AC findings bilaterally; and the IOP was 10 mm Hg in the RE and 11 mm Hg in the LE. Results of fundus examination were normal in the RE, and slight OD edema and reduced macular exudates were present in the

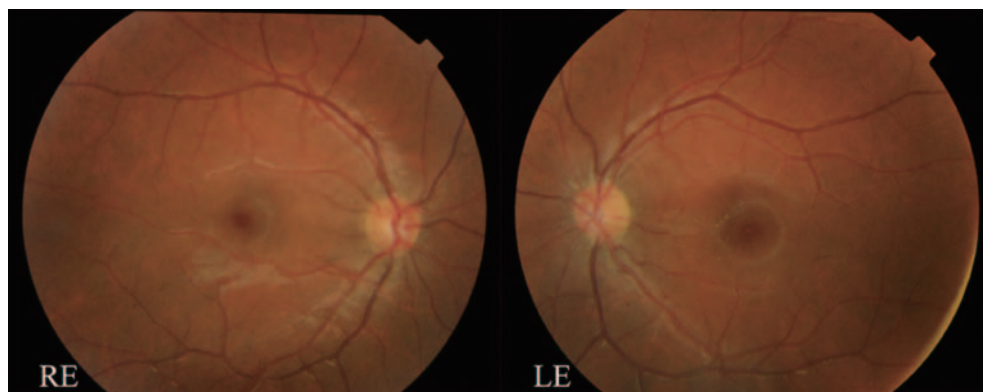


Fig. 1. (Color online) Color fundus photographs of the Case 2 at the third week of the treatment. Photography of the normal right eye (RE) for comparison. Optic disc swelling disappeared and resolution of the macular stellate pattern was observed in the left eye (LE).

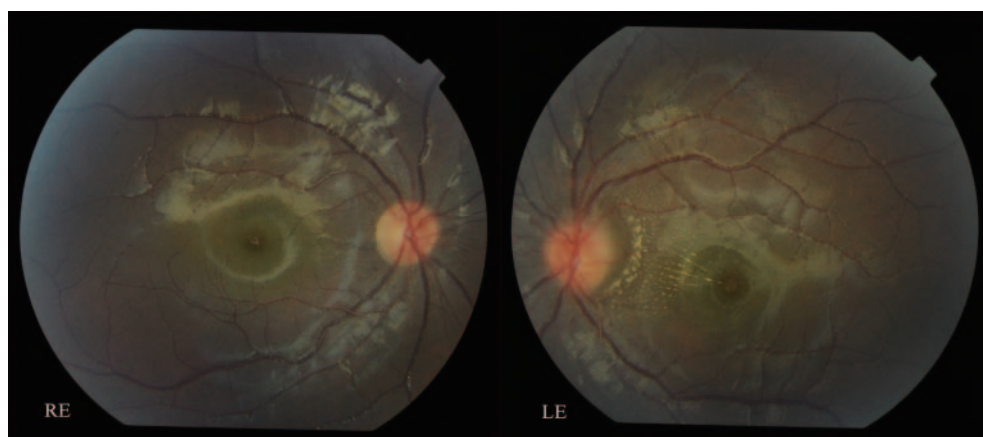


Fig. 2. (Color online) Color fundus photographs of the Case 3 at the fourth week of the treatment. Photography of the normal right eye (RE) for comparison. Optic disc swelling decreased and the macular star exudates which remained only at papillomacular bundle area resolved in the left eye (LE).



LE (Fig. 2). At the end of the 2 years' follow-up, there was no disease recurrence. No adverse effects of the treatment were observed in the child. At the last ophthalmic examination, the VA was 20/20 in both eyes; the slit-lamp examination revealed normal findings in both eyes; and the IOP was 12 mm Hg in the RE and 15 mm Hg in the LE. Results of fundus evaluation were normal in the RE, whereas mild OD pallor remained in the LE.

## DISCUSSION

Neuroretinitis is a manifestation of CSD; however, in the literature, CSD is reported to be rare (2,6). The classic clinical diagnosis of CSD requires that at least 3 of the following 4 criteria be met: (i) a history of traumatic cat exposure; (ii) a positive skin test for CSD antigen; (iii) characteristic regional lymphadenopathies; and (iv) negative results of laboratory tests for unexplained lymphadenopathy (7–9). None of these criteria were fulfilled in the present cases; nevertheless, it is obvious that all of our 3 patients with neuroretinitis were serologically confirmed to have CSD. None of the patients had traumatic or non-traumatic cat contact. According to the classical knowledge, the main source of infection for cats and humans seems to be the inoculation of *B. henselae* through a cat scratch. Transmission to humans can also occur as a result of a cat bite or exposure to cat saliva through an open wound (4). How then can we explain a person who has had no cat contact but is infected, as in the present cases? Although they are very rare, such cases have been reported in the literature (10–12). Transmission between cats depends on the arthropod vector *Ctenocephalides felis* (13). *B. henselae* can reproduce within the digestive system of *C. felis* and survive for several days in the flea feces. The main origin of infection for cats and humans seems to be the inoculation through a cat scratch inflicted by cat claws contaminated with flea feces (14). The flea feces, which contain *B. henselae*, can also be transferred by other vectors, such as birds, arthropods, and flying insects; and inoculation of humans can occur through a small open wound. In such cases, where a patient has no history of cat contact but exhibits this pathological condition, the disease might be called “cat flea transition disease” instead of CSD. Mucous membranes, such as the conjunctiva, may be the avenue of the transmission of the disease (15). Eye rubbing or contact with contaminated cosmetics may lead to direct conjunctival inoculation. However, it is not clear whether conjunctival transmission can explain the progression of the disease with only eye involvement without systemic effects. It is also noteworthy that, in the presented cases, there was not only the absence of traumatic cat exposure but also the absence of the systemic findings of CSD. Lymphadenopathy may become chronic and be of long duration; in one recorded case of CSD, adenitis recurred periodically for more than 18 months (16). Leith et al. have reported about a patient had no history of exposure to cats, which made their case more interesting. They assumed in that case that the disease was acquired from a sick bird without the intervention of a cat (11). Ramharter and Kremser have reported a case with bilateral Bartonella neuroretinitis accompanied by lymphadenopathy, fever and a cat contact history (17). Metz et al. have described

a 6-year-old boy who reported frequent contacts with cats and had lymphadenopathy (18). Another case report described CSD neuroretinitis in a child who presented with pyrexia and cervical lymphadenopathy. The child had close contact with cats, but she could not recall any cat scratches or bites (19). Kilonback et al. described a case of neuroretinitis in a woman who had a history of regular cat contact and had experienced flu-like symptoms, headache, and fever (20).

Although *B. henselae* is the most common infectious etiology of neuroretinitis, treatment remains controversial due to the self-limiting nature of the disease. According to 2 experts, management of Bartonella neuroretinitis is complicated by the rarity of the disease (21). Lee is of the opinion that antimicrobial therapy shortens the symptomatic illness, and one should consider treating it with antibiotics until the laboratory workup is complete. Conversely, according to Bhatti, there is no improved cure rate with treatment (21). Given the rarity of Bartonella neuroretinitis, however, a recruitment goal for a randomized controlled trial would be very difficult to accomplish and would require a multicenter study (22). Reed et al. have reported quicker visual improvement and shortened disease duration with antibiotics (23). Chi et al. did not observe an improvement in visual outcomes in treated patients (antibiotics, CS, or both) compared with outcomes in untreated patients (24). Rostad et al. treated an 8-year-old boy with oral doxycycline (60 mg) every 12 hours for *B. henselae* (25). In the present cases, case 2 was treated with ciprofloxacin, doxycycline, and rifampicin, and case 3 was treated with CS, azithromycin, doxycycline, and rifampicin. Case 2 had no disease recurrence after stopping the treatment, and no sequelae was noted. Case 1 did not undergo any treatment. She had serious complications. It is obvious that it is not reasonable to conclude based on the outcome of a single patient, but it should be noted that serious complications in this small case series were seen only in the untreated patient.

In conclusion, *B. henselae* infection should be considered in patients with neuroretinitis, despite the absence of systemic signs and symptoms of CSD, and serological tests should be performed. In our cases, we relied upon IFA for diagnosis. CSD can occur in subjects who do not have a cat or any other animal contact history even if infectious disease specialists and microbiologists would think otherwise. Thus, the 4 classic diagnostic criteria for the disease should be revised. Owing to the rarity of Bartonella neuroretinitis, there are few large scale studies in the literature; therefore, in our opinion, reports of the atypical cases are valuable. We hope that this small case series will lead to larger, controlled, prospective, multicenter studies in the future.

**Conflict of interest** None to declare.

## REFERENCES

1. Cunningham ET, Koehler JE. Ocular bartonellosis. *Am J Ophthalmol*. 2000;130:340-9.
2. Ormerod LD, Dailey JP. Ocular manifestations of cat-scratch disease. *Curr Opin Ophthalmol*. 1999;10:209-16.
3. Jones DB. Cat-scratch disease. In: Pepose JS, Holland GN, Wilhelmus KR, editors. *Ocular Infection and Immunity*. St. Louis: Mosby-Year Book; 1996;1389-96.

4. Chomel BB, Boulouis HJ, Maruyama S, et al. *Bartonella* spp. in pets and effect on human health. *Emerg Infect Dis.* 2006;12:389-94.
5. Jabs DA, Nussenblatt RB, Rosenbaum JT. Standardization of Uveitis Nomenclature (SUN) Working Group. Standardization of uveitis nomenclature for reporting clinical data. Results of the first international workshop. *Am J Ophthalmol.* 2005;140:509-16.
6. Berger JR. The Interface of infectious disease and neuroophthalmology. *J Neuroophthalmol.* 2012;32:195-6.
7. Koehler JE, Relman DA. *Bartonella* species. In: Yu WL, Merigan TC Jr, Barriere SL, editors. *Antimicrobial Therapy and Vaccines.* Baltimore: Williams and Wilkins; 1999;578-83.
8. Spach DH, Koehler JE. *Bartonella*-associated infections. *Infect Dis Clin North Am.* 1998;12:137-55.
9. Anderson BE, Neuman MA. *Bartonella* spp. as emerging human pathogens. *Clin Microbiol Rev.* 1997;10:203-19.
10. Blattner RJ. Cat-scratch disease without cat contact. *J Pediatr.* 1963;63:676-8.
11. Leith W, Tabah EJ, Pirozynski W. Asymptomatic cat scratch disease. *Can Med Assoc J.* 1963;88:854-5.
12. Lezrek O, Laghmari M, Jait A, et al. Neuroretinitis in ocular bartonellosis. *J Pediatr.* 2015;166:496-96.e1.
13. Chomel BB, Kasten RW, Floyd-Hawkins K, et al. Experimental transmission of *Bartonella henselae* by the cat flea. *J Clin Microbiol.* 1996;34:1952-6.
14. Chomel BB, Boulouis HJ, Breitschwerdt EB, et al. Ecological fitness and strategies of adaptation of *Bartonella* species to their hosts and vectors. *Vet Res.* 2009;40:29.
15. Foil L, Andress E, Freeland RL, et al. Experimental infection of domestic cats with *Bartonella henselae* by inoculation of *Ctenocephalides felis* (Siphonaptera: Pulicidae) feces. *J Med Entomol.* 1998;35:625-8.
16. Rosof BM. Cat-scratch disease as a cause of lymphadenopathy of long duration. *JAMA.* 1961;178:328-9.
17. Ramharter A, Kremser B. Bilateral panuveitis with serous retinal detachment. *Ophthalmologe.* 2009;106:351-5. German.
18. Metz CH, Buer J, Bornfeld N, et al. Bilateral *Bartonella henselae* neuroretinitis with stellate maculopathy in a 6-year-old boy. *Infection.* 2012;40:191-4.
19. Chu BC, Tam VT. A serologically proven case of cat-scratch disease presenting with neuroretinitis. *Hong Kong Med J.* 2009;15:391-3.
20. Kilonback AC, Guly C, Bernatoniene J, et al. Unilateral neuroretinitis secondary to *Bartonella henselae* infection. *Arch Dis Child.* 2014;99:70.
21. Bhatti MT, Lee MS. Should patients with bartonella neuroretinitis receive treatment? *J Neuroophthalmol.* 2014;34:412-6.
22. Prutsky G, Domecq JP, Mori L, et al. Treatment outcomes of human bartonellosis: a systematic review and meta-analysis. *Int J Infect Dis.* 2013;17:e811-9.
23. Reed JB, Scales DK, Wong MT, et al. *Bartonella henselae* neuroretinitis in cat scratch disease: diagnosis, management, and sequelae. *Ophthalmology.* 1998;105:459-66.
24. Chi SL, Stinnett S, Eggenberger E, et al. Clinical characteristics in 53 patients with cat scratch optic neuropathy. *Ophthalmology.* 2012;119:183-7.
25. Rostad CA, McElroy AK, Hilinski JA, et al. *Bartonella henselae*-mediated disease in solid organ transplant recipients: two pediatric cases and a literature review. *Transpl Infect Dis.* 2012;14:E71-81.