



# Endplate lesions in the lumbar spine: a novel MRI-based classification scheme and epidemiology in low back pain patients

Marco Brayda-Bruno<sup>1</sup> · Domenico Albano<sup>2</sup> · Guglielmo Cannella<sup>2</sup> · Fabio Galbusera<sup>3</sup> · Alberto Zerbi<sup>2</sup>

Received: 30 May 2018 / Accepted: 1 October 2018 / Published online: 10 October 2018  
© Springer-Verlag GmbH Germany, part of Springer Nature 2018

## Abstract

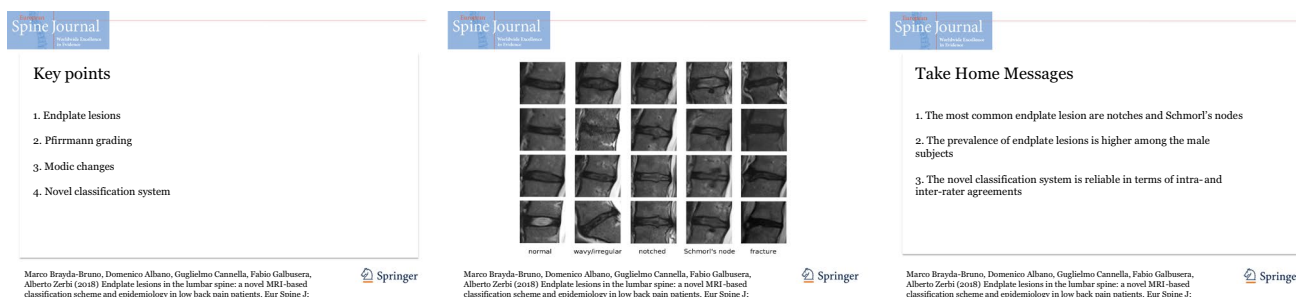**Purpose** The aims of the study were to introduce a classification scheme for endplate lesions based on T2-weighted magnetic resonance imaging and to detect possible associations between endplate lesions and other variables such as age, sex, disc degeneration and Modic changes in a large population.

**Methods** MRI images of 996 low back pain patients were collected. All intervertebral spaces were classified as “normal”, “wavy/irregular”, “notched”, “Schmorl’s node” and “fracture”. The associations between endplate lesions and age, sex, disc degeneration and Modic changes were determined in the considered population.

**Results** The most common endplate lesions were “notched” and “Schmorl’s nodes”. The prevalence was higher among the male subjects. In most patients (62.8%), no endplate lesions were detected, with a significant difference between male (57.5%) and female subjects (67.9%) ( $p < 0.001$ ). Lesions were found to be associated with intervertebral disc degeneration (relative risk 2.49) and signal alterations (relative risk 3.08). Fleiss kappas of 0.73 and 0.89 were, respectively, assessed for the inter- and intra-observer reliabilities of the new classification system.

**Conclusions** Endplate lesions were detected, classified with a novel scheme and analysed in a large population of patients suffering from low back pain based on MRI images. The reliability of the novel classification system was demonstrated.

**Graphical abstract** These slides can be retrieved under Electronic Supplementary Material.



**Keywords** Endplate lesions · Endplate defects · Pfirrmann grading · Modic changes · Classification system

## Introduction

Endplate lesions have been first described by Schmorl [1, 2] and Putschar [3] in 1927 as herniations of discal tissue inside the vertebral body, which tend to be surrounded by sclerotic borders [4]. Such defects are now known as Schmorl’s nodes and have been the subject over the years of extensive research [5], both from the pathogenetic side [6–8] and from

**Electronic supplementary material** The online version of this article (<https://doi.org/10.1007/s00586-018-5787-6>) contains supplementary material, which is available to authorized users.

✉ Fabio Galbusera  
fabio.galbusera@grupposandonato.it

Extended author information available on the last page of the article

the clinical side. As a matter of fact, associations between Schmorl's nodes and disc degeneration [9, 10] as well as with low back pain [11–14] were hypothesized; however, the published literature is controversial, especially about pain. Although symptomatic Schmorl's node can be identified and even treated surgically [15–17], the majority of Schmorl's node is asymptomatic, and their radiological discovery is frequently incidental [5].

Wang and co-workers [18] suggested that a possible explanation for the controversial nature of the published results could be referred to the lack of a precise definition for Schmorl's node and to the strong differences in sensitivity and specificity of the methods used for their identification. Indeed, the authors mentioned that the prevalence of Schmorl's nodes detected in cadaveric spines was much higher than that identified in magnetic resonance imaging (MRI), with obvious implications if the two methods are used indiscriminately in clinical studies. For example, Mok et al. [10] observed Schmorl's nodes in 16.4% of a large population investigated by means of MRI, whereas a prevalence of 67–75% was found in a cadaveric study [19]. To support the standardization of the investigations and thus mitigate such controversial results, Wang and co-workers proposed a precise classification system for endplate lesions based on the examination of cadaveric specimens. The system included Schmorl's node following the classical description as local indentation of the vertebral bone surrounded by an osseous casing, as well as other types of lesions such as fractures (fissures, clefts, fractures with an irregular shape, rough margin and no obvious osseous casing), erosion (thin lytic lesions frequently showing a worm-eaten aspect) and calcification (wide accumulation of calcium upon the endplate, which assumes a rough appearance). The new classification system provided excellent intra-rater and inter-rater reliabilities, and its use in an autopsy study contributed to support the association between endplate lesions, especially erosion defects, with low back pain and disc degeneration [20].

Despite the usefulness of this classification system in basic research studies, it does not satisfy the need for a standardized system to be used in clinical studies, which are necessarily based only on imaging data rather than visual inspection of specimens. Indeed, a few papers suggested classification criteria on CT and MRI scans of the lumbar spine. Weiner et al. [21] used CT images to identify and quantitatively assess the size of endplate lesions in patients subjected to discectomy. Rajasekaran et al. [22] introduced an “endplate score” based on T1-weighted MRI scans, which was then used to correlate the presence of lesions with the transport of a contrast agent into the intervertebral disc. The classification system considered six possible endplate types, which took into account the presence of focal thinnings of the cartilage endplate layer, the size of the lesion and the

possible occurrence of Modic changes [23] at the same level. The score was subsequently used in other studies concerning disc and endplate degeneration [24]. To our knowledge, the score was neither validated nor used in studies conducted on large populations.

The aim of the present study was to introduce and validate a novel classification system for endplate lesions in the lumbar spine based on T2-weighted MRI scans, resulting from an adaptation and simplification of the score mentioned above [22], as well as from its translation to T2-weighted images. The secondary aim of the study was to retrospectively examine a large population of patients suffering from low back pain, in order to detect possible associations between the different types and the distribution of endplate lesions and other relevant variables such as age, sex, disc degeneration and Modic changes.

## Materials and methods

### Population

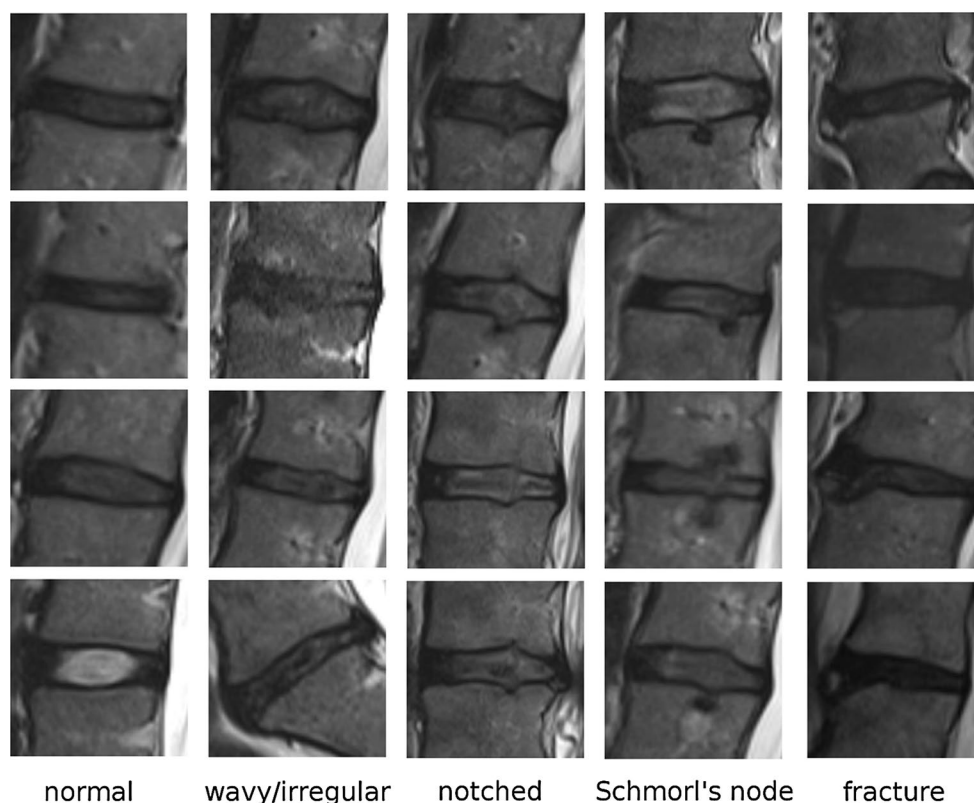
T1-weighted and T2-weighted images of 996 consecutive patients with age less than 70 years seeking medical care for low back pain at IRCCS Istituto Ortopedico Galeazzi from June 2016 to January 2017 were retrospectively analysed. Patients with vertebral fractures, previous back surgery and spondylodiscitis were excluded. Age and sex of all patients were collected; no clinical data, for example, related to the functional condition of the patient and the level of pain, as well as other imaging data, were available for the subsequent data analysis.

Images were acquired either with a 1.5T scanner (Avanto and Espree, Siemens AG, Erlangen, Germany) or with a 1.0T scanner (Harmony, Siemens AG, Erlangen, Germany). All images were evaluated by a single observer, i.e. a radiologist with 4 years of experience under the supervision of a senior radiologist.

### Classification and scoring system for the endplate lesions

All intervertebral spaces from L1–L2 to L5–S1 were labelled on T2-weighted sagittal images as (Fig. 1):

- “*Normal*”: no lesions can be visually detected in all the sagittal MRI slices encompassing the intervertebral space. The curvature of both endplates is physiological.
- “*Wavy/irregular*”: no specific lesions are detectable in the intervertebral space. However, the shape of at least one of the endplates shows alterations with respect to the physiological curvature.



**Fig. 1** Examples of labelling of the intervertebral spaces on T2-weighted sagittal MRI scans

- “*Notched*”: a V-shaped or circular small lesion visible in at least one sagittal MRI slice.
- “*Schmorl's node*”: a deep focal defect of the vertebral endplate with a smooth margin and a rounded appearance.
- “*Fracture*”: the presence of a limbus vertebra, i.e. a well-corticated bone fragment on the corner of the endplate, or other fractures of the endplate with similar size of the fragments.

All sagittal slices encompassing the intervertebral space were evaluated in order to label it; the absence of visible alterations in the mid-sagittal slice did not therefore necessarily indicate that the intervertebral space should be labelled as “normal”.

To validate the classification system, inter-observer reliability was determined by means of Fleiss kappa statistics. To this aim, the images of 30 consecutive patients extracted from the collected data set, for a total of 150 lumbar intervertebral levels, were classified by two additional independent raters. Additionally, one of the raters repeated the evaluation of the same 30 patients for two times at a distance of 2 days between each repetition, in order to assess the intra-rater reliability.

### Epidemiological and statistical analysis

The prevalence of the various types of endplate lesions and their association with disc degeneration and alterations of the MRI signal were determined. To this aim, the degenerative degree of all lumbar intervertebral discs in the population was assessed by means of the Pfirrmann classification on the T2-weighted images. Furthermore, Modic changes (type I/II/III) were identified, as well as signal alterations involving only an isolated small region of the anterior corner of the vertebral body with no extension to the majority of the endplate. Subgroups of the populations were created based on the age (less or equal than 40 years, 41–50, 51–60 or 61–70 years) of the patients when medical care was sought for low back pain, as well as based on sex. Comparisons between the prevalence of endplate lesions in male and female subjects were performed by means of Chi-squared tests. Associations between endplate lesions, age, sex, Pfirrmann grades of the intervertebral disc and signal alterations such as Modic changes were assessed by means of scatter plots and conditional percentages. Relative risks (RR) were calculated when appropriate. The significance threshold was set at  $p = 0.05$ .

## Results

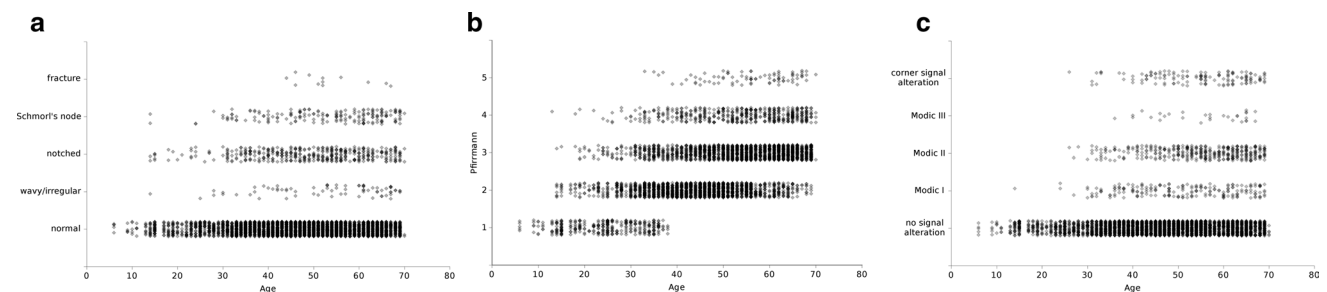
### Epidemiology of endplate lesions

In contrast with the degenerative degree of the lumbar intervertebral discs, the presence of endplate defects was weakly associated with the age of the patient at the time of the MRI scan (Fig. 2). Similarly, signal alterations such as Modic changes showed only a slight tendency to a higher prevalence in older patients. The type of endplate lesion most commonly observed in the population was the “notched”, followed by the “Schmorl’s node” (Table 1). For both types of lesion, the observed prevalence was higher among the male subjects rather than the female ones [10% vs. 7.2% for the “notched” ( $p < 0.001$ ) and 4.6% vs 2.9% for the “Schmorl’s node” ( $p < 0.001$ )]. “Wavy/irregular” and “fracture” lesion types were relatively uncommon, having prevalence of 1.5% and 0.2%, respectively, and negligible differences among male and

female subjects ( $p = 0.57$  for “wavy/irregular” and  $p = 0.89$  for “fracture”).

In most patients (62.8% of the considered population), no endplate lesion could be detected in the whole lumbar spine (Table 2), with a marked difference between the male (57.5%) and the female subjects (67.9%) ( $p < 0.001$ ). 18.7% of the subjects (20.7% of the males and 16.7% of the females ( $p = 0.02$ )) had endplate lesions only in one intervertebral level; the prevalence of lesions involving more levels progressively decreased.

A clear association between the presence of endplate defects and disc degeneration was observed (Fig. 3) ( $RR = 2.49$  for discs graded Pfirrmann 4 or 5 with respect to Pfirrmann 1–3). The fraction of intervertebral levels showing no lesions steadily decreased with progressing disc degeneration, whereas the prevalence of all types of lesions generally increased. Interestingly, the prevalence of “wavy/irregular” endplates resulted to be strongly associated with severe disc degeneration ( $RR = 16.09$  for discs graded Pfirrmann 4 or 5), thus confirming to



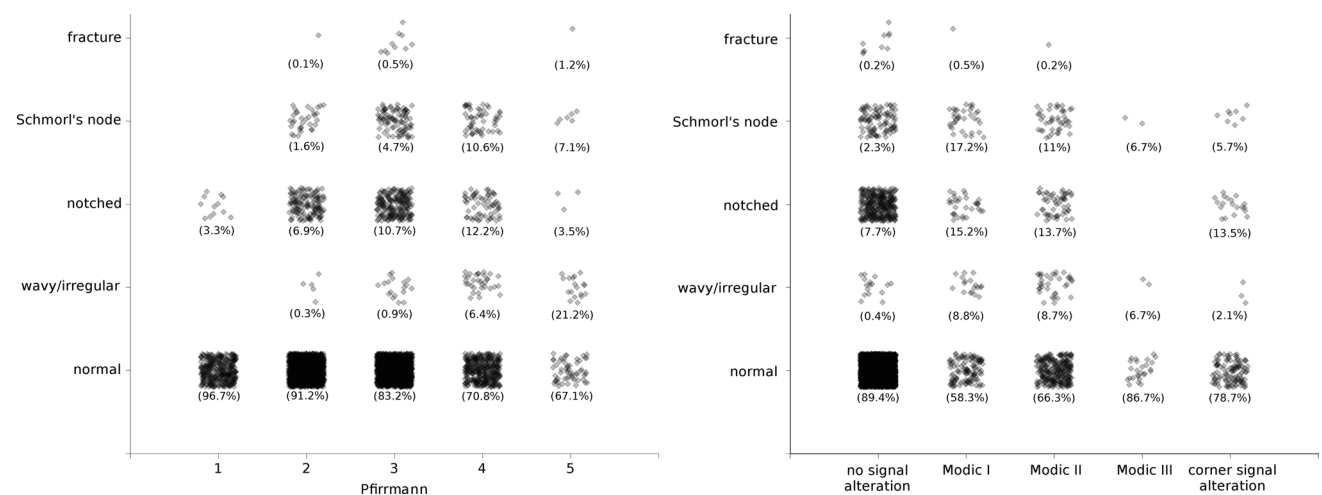
**Fig. 2** Occurrence of the various types of endplate lesions (a), disc degeneration grades following the Pfirrmann scale (b) and signal alterations (c) in the considered population, plotted with respect to the age of the patient when medical care for low back pain was sought

**Table 1** Endplate lesions detected in the recruited patients, subdivided by patient’s age and sex

	Age	Levels	Normal shape	Wavy/irregular	Notched	Schmorl’s node	Fracture
All patients	1–70	4980	4279 (85.9%)	74 (1.5%)	428 (8.6%)	197 (4%)	12 (0.2%)
	1–40	1450	1294 (89.2%)	13 (0.9%)	107 (7.4%)	36 (2.5%)	0 (0%)
	41–50	1330	1174 (88.3%)	13 (1%)	103 (7.7%)	36 (2.7%)	4 (0.3%)
	51–60	1195	999 (83.6%)	17 (1.4%)	129 (10.8%)	45 (3.8%)	5 (0.4%)
	61–70	1005	812 (80.8%)	31 (3.1%)	89 (8.9%)	70 (7%)	3 (0.3%)
Male patients	1–70	2460	2056 (83.6%)	38 (1.5%)	246 (10%)	114 (4.6%)	6 (0.2%)
	1–40	760	645 (84.9%)	9 (1.2%)	76 (10%)	30 (3.9%)	0 (0%)
	41–50	740	637 (86.1%)	7 (0.9%)	69 (9.3%)	26 (3.5%)	1 (0.1%)
	51–60	565	446 (78.9%)	9 (1.6%)	76 (13.5%)	29 (5.1%)	5 (0.9%)
	61–70	395	328 (83%)	13 (3.3%)	25 (6.3%)	29 (7.3%)	0 (0%)
Female patients	1–70	2520	2223 (88.2%)	36 (1.4%)	182 (7.2%)	73 (2.9%)	6 (0.2%)
	1–40	690	649 (94.1%)	4 (0.6%)	31 (4.5%)	6 (0.9%)	0 (0%)
	41–50	590	537 (91%)	6 (1%)	34 (5.8%)	10 (1.7%)	3 (0.5%)
	51–60	630	553 (87.8%)	8 (1.3%)	53 (8.4%)	16 (2.5%)	0 (0%)
	61–70	610	484 (79.3%)	18 (3%)	64 (10.5%)	41 (6.7%)	3 (0.5%)

**Table 2** Number of intervertebral levels showing endplate defects (“wavy/irregular”, “notched”, “Schmorl’s node” and “fracture”) detected for each patient

	Age	Patients	No defects	1 level	2 levels	3 levels	4 levels	5 levels
All patients	1–70	996	625 (62.8%)	186 (18.7%)	91 (9.1%)	51 (5.1%)	35 (3.5%)	8 (0.8%)
	1–40	290	204 (70.3%)	42 (14.5%)	25 (8.6%)	13 (4.5%)	5 (1.7%)	1 (0.3%)
	41–50	266	174 (65.4%)	56 (21.1%)	17 (6.4%)	10 (3.8%)	9 (3.4%)	0 (0%)
	51–60	239	139 (58.2%)	46 (19.2%)	30 (12.6%)	9 (3.8%)	12 (5%)	3 (1.3%)
	61–70	201	108 (53.7%)	42 (20.9%)	19 (9.5%)	19 (9.5%)	9 (4.5%)	4 (2%)
Male patients	1–70	492	283 (57.5%)	102 (20.7%)	51 (10.4%)	29 (5.9%)	22 (4.5%)	5 (1%)
	1–40	152	91 (59.9%)	28 (18.4%)	18 (11.8%)	10 (6.6%)	4 (2.6%)	1 (0.7%)
	41–50	148	88 (59.5%)	36 (24.3%)	11 (7.4%)	7 (4.7%)	6 (4.1%)	0 (0%)
	51–60	113	57 (50.4%)	24 (21.2%)	15 (13.3%)	6 (5.3%)	8 (7.1%)	3 (2.7%)
	61–70	79	47 (59.5%)	14 (17.7%)	7 (8.9%)	6 (7.6%)	4 (5.1%)	1 (1.3%)
Female patients	1–70	504	342 (67.9%)	84 (16.7%)	40 (7.9%)	22 (4.4%)	13 (2.6%)	3 (0.6%)
	1–40	138	113 (81.9%)	14 (10.1%)	7 (5.1%)	3 (2.2%)	1 (0.7%)	0 (0%)
	41–50	118	86 (72.9%)	20 (16.9%)	6 (5.1%)	3 (2.5%)	3 (2.5%)	0 (0%)
	51–60	126	82 (65.1%)	22 (17.5%)	15 (11.9%)	3 (2.4%)	4 (3.2%)	0 (0%)
	61–70	122	61 (50%)	28 (23%)	12 (9.8%)	13 (10.7%)	5 (4.1%)	3 (2.5%)

**Fig. 3** Association of the various types of endplate lesions with the Pfirrmann grade of the intervertebral disc (left) and with the possible presence of signal alterations (right). Conditional percentages (i.e.

percentage of levels showing a specific endplate lesion among the levels having either a specific Pfirrmann grade or signal alteration) are reported in brackets

be a characteristic feature of the degenerative process. Similarly, endplate lesions were associated with signal alterations ( $RR = 3.08$ ) (Fig. 3). Specifically, associations were observed for endplates labelled as “wavy/irregular”, “notched” and “Schmorl’s node” ( $RR = 19.64$ ,  $RR = 1.76$ ,  $RR = 4.92$ , respectively). As a matter of fact, the prevalence of notches was approximately double in case of Modic changes of type I and II or corner signal alterations, and an even stronger association was found for the Schmorl’s nodes.

### Validation of the classification system

Kappa statistics revealed a substantial agreement between the three independent raters and an excellent agreement for the three evaluations carried out by the same rater. Indeed, Fleiss kappas of 0.73 and 0.89 were, respectively, assessed for the inter- and intra-observer reliabilities of the classification of the endplate defects.



## Discussion

In this paper, we retrospectively assessed the presence of endplate lesions in the lumbar spine of a large population of patients suffering from low back pain, and we introduced a novel classification system based on T2-weighted MRI scans. The epidemiological analysis highlighted that male subjects are most commonly affected by endplate lesions than females and that notches and Schmorl's nodes are the most common lesion types. Furthermore, although lesions in general were associated with disc degeneration and signal alterations, wavy and irregular endplates were found to be strongly linked to the degenerative process.

An MRI-based classification and scoring scheme for the condition of the endplates was previously introduced and served as basis for the development of the novel one. Rajasekaran et al. [22] introduced a score based on T1-weighted MRI images which classified the endplates into six categories, covering cartilage thinning, marrow contacts, Schmorl's nodes and gross irregularities. As a matter of fact, the authors did not include any mention neither to an altered endplate shape, similar to our “wavy/irregular”, nor to fracture. Despite these differences, the two classification systems for the single intervertebral level share many similarities. As a matter of fact, the modifications introduced in the novel system were aimed to simplify the classification process described in [22] and by neglecting Modic changes (which in our opinion should be evaluated independently from the endplate lesions in the diagnostic assessment), and to extend its coverage of clinical scenarios by introducing alterations to the endplate shape and fractures. Another recent paper proposed a scheme aimed to the specific characterization of Schmorl's node only, based on MRI images [25]. The authors introduced a classification based on six domains, i.e. the lumbar level, the involvement of the cranial, caudal or both endplates for the specific level, the shape of the lesion, its size, its location in the anteroposterior direction and the possible presence of Modic changes. In contrast to the current study, the classification system did not cover lesions different from Schmorl's nodes. A recent study evaluated the associations between the geometrical features of the cartilaginous endplate evaluated on ultra-high-field MRI and variables such as donor age, disc degeneration and anatomy [26], in a limited number of cadaveric specimens. Despite the high scientific importance of the findings of the study, the methodologies there employed are not currently available and validated for the use in human living subjects.

The present study was aimed solely to the introduction of a reliable method to classify endplate defects on

MRI images and to analyse their distribution in a large low back pain population, without any specific reference to clinical aspects such as pain and functional disability. As a matter of fact, we followed the approach used by Pfirrmann et al. [27] in their classification scheme for intervertebral disc degeneration, which aimed to a standardized and reliable, purely radiological assessment based on the disc morphology. Indeed, an association between lesions and clinical quantities such as pain has been observed in previous studies [28]. Wang et al. [20] found a clear association between the presence, size and type of endplate lesions and back pain, both occasional and frequent. The authors justified their findings in the light of the strong innervation of the vertebral endplate [29], a lesion of which could activate the sensory nociceptors more directly than with a fissure in the poorly intervertebral disc [30]. Besides, innervation may increase in the proximity of endplate lesions [31], thus supporting the concept of the endplate and its defects as sources of pain.

Aside from the definition and the validation of the novel classification system, the retrospective analysis of such a large low back pain population provided interesting epidemiological data about endplate lesions. In agreement with previous studies [32], lesions were more common in male than in female patients. Severe lesions such as Schmorl's nodes and fractures were associated with intervertebral disc degeneration at the same level [20, 32]. The majority of patients exhibiting lesions had them localized at one intervertebral level, and the prevalence of further defects decreased with the number of defects [10]. A weak association between the presence of lesions and the age of the patient was also assessed, in agreement with some literature data [18], whereas other papers did not find any association [32]. However, it should be noted that the age refers to the time point when the patient sought medical care for low back pain, and the possible prior presence of the lesions cannot be inferred. Interestingly, the association between endplate lesions and age was stronger in female patients than in males. This constitutes a novel finding which was never observed in previous studies.

To summarize, endplate lesions were detected, classified with a novel scheme and analysed in a large population of patients suffering from low back pain, based on MRI images. Associations between lesion types and distribution in the lumbar spine and variables such as age and sex were detected. The new classification system proved to be reliable in terms of intra- and inter-rater agreements.

## Compliance with ethical standards

**Conflict of interest** The authors declare that they have no conflict of interest.

**Informed consent** Written informed consent for the use of the data for research purposes was obtained and double anonymization of patients' data was performed.

## References

- Schmorl G (1927) Über die an den Wirbelbandscheiben vorkommenden Ausdehnungs- und Zerreissungsvorgänge und die dadurch an ihnen und der Wirbelspongiosa hervorgerufenen Veränderungen. *Verhandlungen Dtsch Ges Für Pathol* 22:250–262
- Schmorl G, Junghanns H (1971) The human spine in health and disease. Grune and Stratton, New York
- Putschar W (1927) Zur Kenntnis der Knorpelinseln in den Wirbelkörpern. *Beitr Path Anat* 79:150
- Perey O (1957) Fracture of the vertebral end-plate in the lumbar spine: an experimental biomechanical investigation. *Acta Orthop Scand* 28(sup25):1–101
- Kyere KA, Than KD, Wang AC, Rahman SU, Valdivia-Valdivia JM, La Marca F, Park P (2012) Schmorl's nodes. *Eur Spine J* 21(11):2115–2121
- Coventry MB, Ghormley RK, Kernohan JW (1945) The intervertebral disc: its microscopic anatomy and pathology: part III. Pathological changes in the intervertebral disc. *J Bone Joint Surg* 27(3):460–474
- Hilton RC, Ball J, Benn RT (1976) Vertebral end-plate lesions (Schmorl's nodes) in the dorsolumbar spine. *Ann Rheum Dis* 35(2):127–132
- Zhang N, Li F, Huang Y, Teng C, Chen W (2010) Possible key role of immune system in Schmorl's nodes. *Med Hypotheses* 74(3):552–554
- Pfirrmann CW, Resnick D (2001) Schmorl nodes of the thoracic and lumbar spine: radiographic–pathologic study of prevalence, characterization, and correlation with degenerative changes of 1,650 spinal levels in 100 cadavers. *Radiology* 219(2):368–374
- Mok FP, Samartzis D, Karppinen J, Luk KD, Fong DY, Cheung KM (2010) ISSLS prize winner: prevalence, determinants, and association of Schmorl nodes of the lumbar spine with disc degeneration: a population-based study of 2449 individuals. *Spine (Phila Pa 1976)* 35(21):1944–1952
- Hamanishi C, Kawabata T, Yosii T, Tanaka S (1994) Schmorl's nodes on magnetic resonance imaging: their incidence and clinical relevance. *Spine* 19(4):450–453
- McCall IW, Park WM, O'Brien JP, Seal V (1985) Acute traumatic intraosseous disc herniation. *Spine* 10(2):134–137
- Hsu KY, Zucherman JF, Derby R, White AH, Goldthwaite N, Wynne G (1988) Painful lumbar end-plate disruptions: a significant discographic finding. *Spine* 13(1):76–78
- Williams F, Manek N, Sambrook P, Spector T, Macgregor A (2007) Schmorl's nodes: common, highly heritable, and related to lumbar disc disease. *Arthritis Care Res* 57(5):855–860
- Peng B, Chen J, Kuang Z, Li D, Pang X, Zhang X (2009) Diagnosis and surgical treatment of back pain originating from endplate. *Eur Spine J* 18(7):1035–1040
- Hasegawa K, Ogoe A, Morita T, Hirata Y (2004) Painful Schmorl's node treated by lumbar interbody fusion. *Spinal Cord* 42(2):124–128
- Wenger M, Markwalder T (2009) Fluoronavigation-assisted, lumbar vertebroplasty for a painful Schmorl node. *J Clin Neurosci* 16(9):1250–1251
- Wang Y, Videman T, Battie MC (2012) Lumbar vertebral endplate lesions: prevalence, classification, and association with age. *Spine (Phila Pa 1976)* 37(17):1432–1439
- Saluja G, Fitzpatrick K, Bruce M, Cross J (1986) Schmorl's nodes (intravertebral herniations of intervertebral disc tissue) in two historic British populations. *J Anat* 145:87–96
- Wang Y, Videman T, Battie MC (2012) ISSLS prize winner: lumbar vertebral endplate lesions: associations with disc degeneration and back pain history. *Spine (Phila Pa 1976)* 37(17):1490–1496
- Weiner BK, Vilendecic M, Ledic D, Eustacchio S, Varga P, Gorenssek M, Fernandez-Moure J, Hipp JA (2015) Endplate changes following discectomy: natural history and associations between imaging and clinical data. *Eur Spine J* 24(11):2449–2457
- Rajasekaran S, Venkatadass K, Naresh Babu J, Ganesh K, Shetty AP (2008) Pharmacological enhancement of disc diffusion and differentiation of healthy, ageing and degenerated discs: results from in vivo serial post-contrast MRI studies in 365 human lumbar discs. *Eur Spine J* 17(5):626–643
- Modic MT, Masaryk TJ, Ross JS, Carter JR (1988) Imaging of degenerative disk disease. *Radiology* 168(1):177–186
- Farshad-Amacker NA, Hughes A, Herzog RJ, Seifert B, Farshad M (2017) The intervertebral disc, the endplates and the vertebral bone marrow as a unit in the process of degeneration. *Eur Radiol* 27(6):2507–2520
- Samartzis D, Mok F, Karppinen J, Fong D, Luk K, Cheung K (2016) Classification of Schmorl's nodes of the lumbar spine and association with disc degeneration: a large-scale population-based MRI study. *Osteoarthritis Cartilage* 24(10):1753–1760
- DeLucca JF, Peloquin JM, Smith LJ, Wright AC, Vresilovic EJ, Elliott DM (2016) MRI quantification of human spine cartilage endplate geometry: comparison with age, degeneration, level, and disc geometry. *J Orthop Res* 34(8):1410–1417
- Pfirrmann CW, Metzdorf A, Zanetti M, Hodler J, Boos N (2001) Magnetic resonance classification of lumbar intervertebral disc degeneration. *Spine* 26(17):1873–1878
- de Hooze M, de Bruin F, de Beer L, Bakker P, van den Berg R, Ramiro S, van Gaalen F, Fagerli K, Landewé R, van Oosterhout M, Ramonda R, Huizinga T, Bloem H, Reijnen M, van der Heijde D (2017) Is the site of back pain related to the location of magnetic resonance imaging lesions in patients with chronic back pain? Results from the Spondyloarthritis Caught Early cohort. *Arthritis Care Res* 69(5):717–723
- Fagan A, Moore R, Vernon Roberts B, Blumbergs P, Fraser R (2003) ISSLS prize winner: the innervation of the intervertebral disc: a quantitative analysis. *Spine (Phila Pa 1976)* 28(23):2570–2576
- Ashton I, Roberts S, Jaffray D, Polak J, Eisenstein S (1994) Neuropeptides in the human intervertebral disc. *J Orthop Res* 12(2):186–192
- Brown MF, Hukkanen MV, McCarthy ID, Redfern DR, Batten JJ, Crock HV, Hughes SP, Polak JM (1997) Sensory and sympathetic innervation of the vertebral endplate in patients with degenerative disc disease. *J Bone Joint Surg Br* 79(1):147–153
- Zehra U, Flower L, Robson-Brown K, Adams MA, Dolan P (2017) Defects of the vertebral end plate: implications for disc degeneration depend on size. *Spine J* 17(5):727–737

## Affiliations

**Marco Brayda-Bruno<sup>1</sup> · Domenico Albano<sup>2</sup> · Guglielmo Cannella<sup>2</sup> · Fabio Galbusera<sup>3</sup>  · Alberto Zerbi<sup>2</sup>**

<sup>1</sup> Department of Spine Surgery III, IRCCS Istituto Ortopedico Galeazzi, Milan, Italy

<sup>2</sup> Unit of Diagnostic and Interventional Radiology, IRCCS Istituto Ortopedico Galeazzi, Milan, Italy

<sup>3</sup> Laboratory of Biological Structures Mechanics, IRCCS Istituto Ortopedico Galeazzi, Via Galeazzi 4, 20161 Milan, Italy