



Prevalence and pattern of thoracolumbar caudal articular process anomalies and intervertebral disk herniations in pugs

Hidetaka NISHIDA^{1,2)}, Kohei NAKATA²⁾, Sadatoshi MAEDA^{1,2)} and Hiroaki KAMISHINA^{1-3)*}

¹⁾Joint Department of Veterinary Medicine, Faculty of Applied Biological Sciences, Gifu University, Gifu 501-1193, Japan

²⁾The United Graduate School of Veterinary Sciences, Gifu University, Gifu 501-1193, Japan

³⁾Center for Highly Advanced Integration of Nano and Life Sciences, Gifu University, Gifu 501-1193, Japan

ABSTRACT. Thoracolumbar intervertebral disk herniation (TL-IVDH) with caudal articular process anomalies has been reported in Pugs. It currently remains unclear whether congenital caudal articular process aplasia/hypoplasia predisposes to the development of TL-IVDH. However, there are difficulties in proving the causal relationship between caudal articular process anomalies and TL-IVDH. The aim of this study was to describe the prevalence of TL-IVDH at the vertebral space containing anomalous and normal caudal articular processes in Pugs. Fifty-seven pugs were eligible to be included in this study. Caudal articular process aplasia/hypoplasia affected 52/57 (91.2%) dogs. The caudal articular process anomalies were most frequently located between T10 and T13. Colocalization of caudal articular process aplasia/hypoplasia and TL-IVDH was detected in 11 dogs (19.3%). The prevalence of TL-IVDH at vertebral spaces containing abnormal caudal articular processes was 12.3%, whereas the prevalence of TL-IVDH at vertebral spaces containing normal articular processes was 2.4%. With the increase in the number of vertebrae with caudal articular process anomalies, the prevalence of TL-IVDH also increased. The results of this study suggested the prevalence of caudal articular process anomalies was high in Pugs. The caudal articular process anomalies could be associated with TL-IVDH. A large cohort is needed to prove the causal relationship between caudal articular process anomalies and TL-IVDH.

KEY WORDS: caudal articular process anomalies, intervertebral disk herniation, pug

J. Vet. Med. Sci.
81(6): 906–910, 2019
doi: 10.1292/jvms.18-0521

Received: 30 August 2018
Accepted: 10 April 2019
Published online in J-STAGE:
15 May 2019

Articular processes are the projections of the vertebrae that fit with an adjacent vertebra. Caudal and cranial articular processes contribute to stabilization of the spine and restriction of the ventrodorsal and lateral bending [5]. Articular process malformations have been documented in Pugs, Pomeranians, Cavalier King Charles Spaniels, and German Shepherds [11, 16, 21]. Although the precise pathophysiology of these malformations is unknown, failure of ossification due to an insufficient blood supply during their fetal life has been suggested to underlie the condition [4, 18].

Constrictive myelopathy due to thoracolumbar intervertebral disk herniation (TL-IVDH), arachnoid diverticula, and fibroid constructs with caudal articular process anomalies has recently been reported in Pugs [11]. However, there have been difficulties in proving the causal relationship between caudal articular process anomalies and TL-IVDH. The aim of this retrospective study was to describe the prevalence of TL-IVDH at the vertebral spaces containing anomalous and normal caudal articular processes in Pugs.

MATERIALS AND METHODS

Animals

The imaging database of the Animal Medical Center of Gifu University was reviewed to identify Pugs that had undergone computed tomography (CT) between 2011 and 2016. Cases were included in this study if the vertebral region from T10 to L7 or thorax and abdomen were scanned. Magnetic resonance imaging (MRI) was performed in dogs with neurological deficits. Neurological deficits were determined and recorded. Acute presentations were defined as neurological signs progressed within 3 weeks. Chronic presentations were defined as neurological signs presented for >3 weeks, as described by Moissonnier *et al* [14]. Exclusion criteria were as follows: slice thickness of CT scans exceeding 2 mm and/or images of non-diagnostic quality. Dogs with

*Correspondence to: Kamishina, H.: kamicna@gifu-u.ac.jp

©2019 The Japanese Society of Veterinary Science



This is an open-access article distributed under the terms of the Creative Commons Attribution Non-Commercial No Derivatives (by-nc-nd) License. (CC-BY-NC-ND 4.0: <https://creativecommons.org/licenses/by-nc-nd/4.0/>)

vertebral fracture/luxation and vertebral/spinal tumors were also excluded.

CT and MRI

CT images (Asteion Super 4 CT Scanner, Canon Medical Systems, Tochigi, Japan) of each dog were retrieved. The standard protocol used was a contiguous slice thickness of 0.5–2.0 mm (120 kV, 40–80 mA), then reconstruction in a low spatial reconstruction algorithm and high spatial resolution. MRI was acquired with 0.4 Tesla scanner (APERTO Lucent Open MRI, Hitachi Healthcare Manufacturing, Kashiwa, Japan). MR images of spinal cord were acquired using T1 weighted sagittal sequences (TE=13, TR=400, slice thickness=3 mm), T1 weighted transverse sequences (TE=13, TR=450, slice thickness=3.5 mm), T2 weighted sagittal sequences (TE=120, TR=2,500, slice thickness=3 mm), T2 weighted transverse sequences (TE=105, TR=1600, slice thickness=3.5 mm), and contrast enhanced T1 weighted sagittal and transverse sequences after intravenous injection of 0.1 mmol/kg of gadodiamide hydrate (OMNISCAN, Daiichi-Sankyo, Tokyo, Japan). Images were displayed using an open-source PACS Workstation DICOM viewer (Osirix Imaging Software, Pixmeo, Bernex, Switzerland).

Image evaluation

Two observers, who were unaware of the clinical signs and final diagnoses, independently evaluated images in the region from T10 to L7. The following parameters were evaluated: the location and number of caudal articular process anomalies using 3D volume rendering CT images, the occurrence of IVDH defined as the presence of disk material dorsal to the disk space or calcified materials in the vertebral canal using CT images, and occurrence of spondylosis deformans defined as the presence of ventral osseous proliferation or enthesopathy at the margins of the endplates using CT images. IVDH were classified into disk extrusion and protrusion if MRI was performed. Disk herniations were classified as extrusion if the disks herniated through all layers of the anulus fibrosus and appeared as a focal epidural mass, as described by Besalti *et al* [3]. Disk herniations were classified as protrusion if the disk protruded in the central direction or to the left and right and appeared as a symmetrical extension of the disk beyond the margin of the intervertebral space. The observers had the option of manipulating images on PACS during evaluation, including but not limited to magnifying and windowing. If the two observers conflicted on their opinion, images were reevaluated together and a consensus was reached.

Each caudal articular process anomaly was classified as follows (Fig. 1): absent process (aplasia), incomplete formation (hypoplasia), and normal process formation [11]. Caudal articular processes were classified as normal if the caudal articular processes crossed the intervertebral space and have a rounded cursive W-shape when viewed from the dorsal side. The vertebrae were classified as vertebrae with abnormal or normal articular processes. Vertebral malformations were also evaluated using the previously reported classification [12]. Vertebral malformations included dorsal hemivertebra, lateral hemivertebra, dorso-lateral hemivertebra, butterfly vertebra, ventral wedge shape vertebra, and lateral wedge shape vertebra.

Statistical analysis

All analyses were performed with a statistical analysis software (Graphpad Prism software, La Jolla, CA, U.S.A.). The association between the total number of vertebrae with caudal articular process anomalies and the presence of TL-IVDH were examined with Cochran-Armitage trend test. The association between the prevalence of TL-IVDH and the articular process anomalies was evaluated by Fisher's exact test. $P < 0.05$ was considered statistically significant.

RESULTS

Fifty-seven Pugs were eligible for inclusion to be included in this study. They consisted of 27 males and 30 females that were between 7 months old and 14 years old (median, 9 years) and weighed between 5.0 and 13.2 kg (median, 7.8 kg). Five dogs were imaged for neurological deficits. Thirty-seven dogs were imaged for thoracic and abdominal metastasis check. Fifteen dogs were imaged for screening of the thorax and abdomen. Thoracolumbar caudal articular process anomalies were found in 52/57 (91.2%) dogs. Caudal articular process anomalies were located at T10 (39 dogs, 68.4%), T11 (46 dogs, 80.7%), T12 (42 dogs, 73.7%), T13 (17 dogs, 29.8%), L1 (1 dog, 1.8%), L3 (1 dog, 1.8%), and L7 (1 dog, 1.8%, Fig. 2). One hundred forty-four out of 147 anomalous caudal articular processes (98.0%) were concentrated in the region between T10 and T13. There was no cranial articular process anomaly at the region from T10 to L7. Nineteen dogs had 6 lumbar vertebrae. No vertebral body malformations were found.

TL-IVDH was detected in 19 dogs. They were between 6 years and 14 years old (median, 10 years). Disk herniations were located at T10–11 in 1 dog (5.3%), T11–12 in 7 dogs (36.8%), T12–13 in 7 dogs (36.8%), T13–L1 in 2 dogs (10.5%), L1–2 in 1 dog (5.3%), L3–4 in 4 dogs (21.1%), L4–5 in 2 dogs (10.5%), and L5–6 in 4 dogs (13.6%, Fig. 2). Four of these dogs had a history of ataxia and paraparesis.

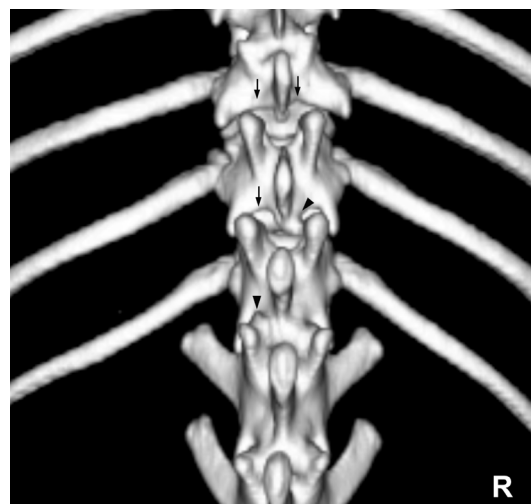


Fig. 1. A dorsal view of a 3D volume rendering CT image of the thoracolumbar vertebrae of a Pug. The arrowheads denote hypoplasia of the caudal articular process, and arrows denote aplasia of the caudal articular facet. The other articular processes were normal.

Forty out of 57 dogs (70.2%) had spondylosis deformans. They were located at T10–T11 in 5 dogs (12.5%), T11–T12 in 8 dogs (20.0%), T12–T13 in 12 dogs (30.0%), T13–L1 in 8 dogs (20.0%), L1–L2 in 6 dogs (15.0%), L2–L3 in 20 dogs (50.0%), L3–L4 in 14 dogs (35.0%), L4–L5 in 14 dogs (35.0%), L5–L6 in 8 dogs (12.5%), and L6–L7 in 2 dogs (5.0%, Fig. 2).

Colocalization of caudal articular process aplasia/hypoplasia and TL-IVDH was detected in 11 dogs (Table 1). Six of these dogs had 2 or more sites of TL-IVDH. Four out of the 6 dogs with TL-IVDH at multiple sites had histories of neurological signs including chronic non-painful progressive paraparesis. The mean duration of neurological signs was 7.5 months (range, 2 to 12 months). MRI was performed in these dogs with neurological deficits. All the disk herniations of these dogs were diagnosed with protrusions. Two of these dogs had dorsal constrictive compression and 3 of these dogs had enlargement of the dorsal subarachnoid space. TL-IVDH without colocalized caudal articular process anomalies were detected in 8 dogs. These dogs had no neurological sign. Thirty-three dogs had caudal articular process anomalies but did not accompany TL-IVDH. Another 5 dogs had neither caudal articular process anomalies nor TL-IVDH. They were between 7 months and 14 years old (median, 8.5 years).

The prevalence of TL-IVDH at the vertebral spaces containing anomalous caudal articular processes and normal caudal articular processes was shown in Tables 2 and 3. The prevalence of TL-IVDH at the vertebral spaces containing anomalous and normal caudal articular processes was 12.3% (18/146 vertebrae) and 2.4% (10/424 vertebrae), respectively. The prevalence of TL-IVDH at the vertebral spaces containing bilateral and unilateral anomalous caudal articular processes was 15.0% (17/113) and 3.0% (1/33), respectively. With the increase in the number of vertebrae with caudal articular process anomalies, the prevalence of TL-IVDH also increased ($P < 0.001$, Table 4). The prevalence of TL-IVDH in dogs with more than 3 vertebrae with articular process anomalies was 50% (18/36 dogs), and that containing 0–2 vertebrae with articular process anomalies was 4.7% (1/21 dogs, $P < 0.001$).

DISCUSSION

The overall prevalence of caudal articular process anomalies was 91.2% (52/57) in this study. Most anomalous caudal articular processes were concentrated in the region between T10 and T13. Cranial articular process anomaly was not observed in Pugs included in this study. The retrospective nature and the small number of cases in our study precluded the establishment of the exact prevalence of caudal articular process anomalies in the general population of Pugs; however, a large proportion of Pugs seemed to have caudal articular process anomalies which might underlie late onset myelopathies in this specific breed. The prevalence of IVDH in our study was 19.8% (11/57). Most cases received only CT scans in our study, therefore some disk herniations, fibrous hypertrophy and arachnoid diverticula might have been overlooked, possibly accounting for the lower prevalence of TL-IVDH. A report showed that the sensitivity of CT was 88.6% and that of MRI was 98.5% for the diagnosis of TL-IVDH [6].

Postmortem studies showed that the bilateral defects of articular facets were associated with 28% increase in its range of movement, 43% decrease in its strength [20], and 10% increase in its instability [19]. A previous study reported that the congenital absence of the lumbar facet joint triggered IVDH in humans [18]. The prevalence of TL-IVDH at the vertebral spaces containing bilateral anomalous caudal articular processes was higher than that containing unilateral anomalous caudal articular process in this study. This finding was consistent with the results of cadaver study [7]. Hemilaminectomy has proven not to significantly decrease the stability of the spine [7]. Chronic physicommechanical overload and trauma are known to cause intervertebral disk degeneration [2]. Stress myelography was helpful for diagnosing dynamic compression due to disk herniation and dorsal compression [1]. It might be useful for the evaluation of the extent of spinal instability and further corroborate the roles of caudal articular process anomalies on the development of TL-IVDH. The majority of TL-IVDH in small breed dogs would be expected to locate between T10 and L2. Therefore, it was difficult to prove the causal relationship between caudal articular process anomalies and TL-IVDH. A large cohort would be needed to prove the causal relationship between caudal articular process anomalies and TL-IVDH.

The exact cause of spondylosis deformans is unknown, but is considered to be associated with degenerative changes in the annulus fibrosus of intervertebral disks due to chronic mild instability [8, 15]. The frequency of spondylosis deformans in dogs was previously reported to be the highest in the intervertebral spaces between L2–L3 and L7–S1 [13, 14]. In the present study, L2–L3 disk spaces had the highest frequency of spondylosis deformans. There seemed no relationship between the prevalence of caudal articular process anomalies and spondylosis deformans.

We targeted the vertebral region between T10 and L7. The cranial and mid-thoracic regions were excluded because of the presence of intercaped ligaments that prevent extrusion of the intervertebral disks. Articular processes from T1 to T9 have similar

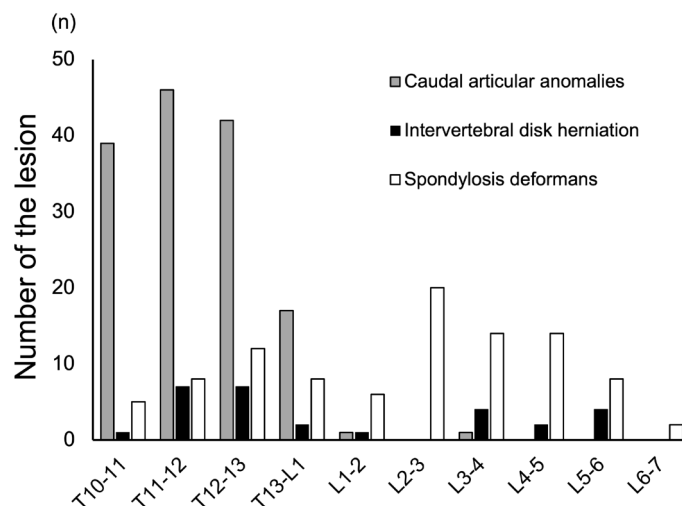


Fig. 2. Locations of caudal articular process anomalies, intervertebral disk herniations, and spondylosis deformans in 57 Pugs.

Table 1. The locations and types of caudal articular process anomalies in 19 Pugs with intervertebral disk herniations

Dog	Signalment			Caudal articular process anomalies						IVDH	Neurological deficits
	Age (years)	Sex	Weight (kg)	T10	T11	T12	T13	L1	L3		
1	10	F	8.2	B: aplasia	B: aplasia	B: aplasia	B: aplasia			T11–12, T12–13	Chronic paraparesis
2	12	F	7.1		B: aplasia	L: aplasia, R: hypoplasia	L: hypoplasia			T11–12, T12–13	Chronic ataxia
3	9	M	7.8	B: aplasia	B: aplasia	B: aplasia	B: aplasia			T12–13, T13–L1	Chronic ataxia
4	10	F	5	B: aplasia	B: aplasia	B: aplasia	R: aplasia		B: aplasia	T12–13, T13–L1	Chronic ataxia
5	11	F	6.1	B: aplasia	B: aplasia	B: aplasia	B: aplasia	L: hypoplasia, R: aplasia		L1–2	
6	12	F	9.2	B: aplasia	L: aplasia, R: hypoplasia	L: aplasia, R: hypoplasia	B: aplasia			T11–12, T12–13	
7	10	F	7.7	B: aplasia	B: aplasia	B: aplasia	B: aplasia			T10–11, T11–12, T12–13, L3–4	
8	8	F	8.1	B: aplasia	B: aplasia	B: aplasia	B: aplasia			T11–12	
9	9	M	7.7	B: aplasia	B: aplasia	B: hypoplasia				T11–12	
10	8	F	9.4	B: aplasia	B: aplasia	B: hypoplasia				T12–13	
11	12	M	5.7	B: aplasia	B: aplasia	B: aplasia				T11–12	
12	7	M	6.9	B: aplasia	B: aplasia	B: aplasia				L3–4	
13	9	M	11		R: aplasia					L5–6	
14	11	M	7.6	B: aplasia	R: aplasia	L: aplasia, R: hypoplasia	L: aplasia, R: hypoplasia			L4–5	
15	11	M	8.5	L: Hypoplasia	R: Hypoplasia	R: Hypoplasia				L5–6	
16	14	M	8.9	B: aplasia						L4–5, L5–6	
17	10	F	6.2	B: aplasia	B: aplasia	B: aplasia				L3–4	
18	6	M	5.5	B: aplasia	B: aplasia	B: aplasia	L: aplasia			L5–6	
19	6	M	7.8	B: aplasia	B: aplasia	B: aplasia				L3–4	

M: male, F: female, B: bilateral, L: left, R: right.

Table 2. The prevalence of IVDH at the vertebral spaces containing anomalous and normal caudal articular processes

	Prevalence of IVDH										Total
	T10–11	T11–12	T12–13	T13–L1	L1–2	L2–3	L3–4	L4–5	L5–6	L6–7	
Anomalous processes (n=146)	1/39 (2.6%)	7/46 (15.2%)	7/42 (16.7%)	2/17 (11.8%)	1/1 (100%)	0/0	0/1 (0%)	0/0	0/0	0/0	18/146 (12.3%)
Normal processes (n=424)	0/18 (0%)	0/11 (0%)	0/15 (0%)	0/40 (0%)	0/56 (0%)	0/57 (0%)	4/56 (7.1%)	2/57 (3.5%)	4/57 (7%)	0/57 (0%)	10/424 (2.4%)

 $P < 0.0001$.

Table 3. Relationship between the types of caudal articular process anomalies and the prevalence of colocalized IVDH

Types of caudal articular process anomalies	Prevalence of IVDH
Bilateral aplasia (n=87)	13/87 (14.9%)
Aplasia and hypoplasia (n=17)	3/17 (17.6%)
Bilateral hypoplasia (n=9)	1/9 (11.1%)
Unilateral aplasia (n=16)	1/16 (6.3%)
Unilateral hypoplasia (n=17)	0/17 (0%)
Normal (n=424)	10/424 (2.4%)

Table 4. The prevalence of IVDH in dogs with different numbers of vertebrae affected by caudal articular process anomalies

Total number of vertebrae with caudal articular process anomalies	Prevalence of IVDH
0	0/5 (0%)
1	1/9 (11.1%)
2	0/7 (0%)
3	9/23 (39.1%)
4	8/12 (66.7%)
5	1/1 (100%)

shapes and their orientations are in a corresponding caudoventral direction [6]. The articular processes of L1–7 have similar shapes and restrict lateral flexion. The vertebrae from T10 to T13 represent a transitional portion of the spine [5]. The shape and function of articular processes in the region of T10–13 differ from those of other regions and additional stabilizing structures of costovertebral articulations are absent in the caudal thoracic spine [9, 10]. Disk herniations were quite prevalent at thoracolumbar junction in aged dogs. Therefore, not only the presence of caudal articular process anomalies, but also other factors could be involved with the occurrence of TL-IVDH.

No vertebral body malformations were found in the vertebral region between T10 and L7. However, recent research indicated that vertebral body malformation was found most commonly between T7–9 [17]. Further studies are needed to establish causal relationship between vertebral body malformations and TL-IVDH in dogs.

Our results indicated the prevalence of caudal articular process anomalies was high in Pugs. The caudal articular process anomalies could be associated with TL-IVDH. A large cohort is needed to further prove the causal relationship between caudal articular process anomalies and TL-IVDH.

CONFLICT OF INTEREST. The authors declare no conflict of interest to this report.

ACKNOWLEDGMENT. We thank M. Yamazaki, Y. Nakano, and M. Narita for their technical assistance.

REFERENCES

1. Aikawa, T., Shibata, M. and Sadahiro, S. 2013. Hemilaminectomy and vertebral stabilization for thoracolumbar intervertebral disc associated dynamic compression in 11 dogs. *Vet. Comp. Orthop. Traumatol.* **26**: 498–504. [Medline] [CrossRef]
2. Bergknut, N., Smolders, L. A., Grinwis, G. C., Hagman, R., Lagerstedt, A. S., Hazewinkel, H. A., Tryfonidou, M. A. and Meij, B. P. 2013. Intervertebral disc degeneration in the dog. Part 1: Anatomy and physiology of the intervertebral disc and characteristics of intervertebral disc degeneration. *Vet. J.* **195**: 282–291. [Medline] [CrossRef]
3. Besalti, O., Pekcan, Z., Sirin, Y. S. and Erbas, G. 2006. Magnetic resonance imaging findings in dogs with thoracolumbar intervertebral disk disease: 69 cases (1997–2005). *J. Am. Vet. Med. Assoc.* **228**: 902–908. [Medline] [CrossRef]
4. Blumel, J., Evans, E. B., Hadnott, J. L. and Eggers, G. W. 1962. Congenital skeletal anomalies of the spine: an analysis of the charts and roentgenograms of 264 patients. *Am. Surg.* **28**: 501–509. [Medline]
5. Bouma, J. L. 2016. Congenital malformations of vertebral articular processes in dogs. *Vet. Clin. North Am. Small Anim. Pract.* **46**: 307–326. [Medline] [CrossRef]
6. Cooper, J. J., Young, B. D., Griffin, J. F. 4th., Fosgate, G. T. and Levine, J. M. 2014. Comparison between noncontrast computed tomography and magnetic resonance imaging for detection and characterization of thoracolumbar myelopathy caused by intervertebral disk herniation in dogs. *Vet. Radiol. Ultrasound* **55**: 182–189. [Medline] [CrossRef]
7. Corse, M. R., Renberg, W. C. and Friis, E. A. 2003. In vitro evaluation of biomechanical effects of multiple hemilaminectomies on the canine lumbar vertebral column. *Am. J. Vet. Res.* **64**: 1139–1145. [Medline] [CrossRef]
8. Dewey, C. W. and da Costa, R. C. 2016. Myelopathies: disorders of the spinal cord. pp. 329–404. In: *Practical Guide to Canine and Feline Neurology*, 3rd ed., Wiley Blackwell, Ames.
9. Evans, H. E. 1993. The skeleton: the vertebral column. pp. 166–181. In: *Miller's Anatomy of the Dog*, 3rd ed., WB Saunders, Philadelphia.
10. Evans, H. E. 1993. Arthrology: ligaments and joints of the vertebral column. pp. 225–233. In: *Miller's Anatomy of the Dog*, 3rd ed., WB Saunders, Philadelphia.
11. Fisher, S. C., Shores, A. and Simpson, S. T. 2013. Constrictive myelopathy secondary to hypoplasia or aplasia of the thoracolumbar caudal articular processes in Pugs: 11 cases (1993–2009). *J. Am. Vet. Med. Assoc.* **242**: 223–229. [Medline] [CrossRef]
12. Gutierrez-Quintana, R., Guevar, J., Stalin, C., Faller, K., Yeamans, C. and Penderis, J. 2014. A proposed radiographic classification scheme for congenital thoracic vertebral malformations in brachycephalic “screw-tailed” dog breeds. *Vet. Radiol. Ultrasound* **55**: 585–591. [Medline] [CrossRef]
13. Levine, G. J., Levine, J. M., Walker, M. A., Pool, R. R. and Fosgate, G. T. 2006. Evaluation of the association between spondylosis deformans and clinical signs of intervertebral disk disease in dogs: 172 cases (1999–2000). *J. Am. Vet. Med. Assoc.* **228**: 96–100. [Medline] [CrossRef]
14. Moissonnier, P., Meheust, P. and Carozzo, C. 2004. Thoracolumbar lateral corpectomy for treatment of chronic disk herniation: technique description and use in 15 dogs. *Vet. Surg.* **33**: 620–628. [Medline] [CrossRef]
15. Morgan, J. P., Ljunggren, G. and Read, R. 1967. Spondylosis deformans (vertebral osteophytosis) in the dog. A radiographic study from England, Sweden and U.S.A. *J. Small Anim. Pract.* **8**: 57–66. [Medline] [CrossRef]
16. Penderis, J., Schwarz, T., McConnell, J. F., Garosi, L. S., Thomson, C. E. and Dennis, R. 2005. Dysplasia of the caudal vertebral articular facets in four dogs: results of radiographic, myelographic and magnetic resonance imaging investigations. *Vet. Rec.* **156**: 601–605. [Medline] [CrossRef]
17. Ryan, R., Gutierrez-Quintana, R., Ter Haar, G. and De Decker, S. 2017. Prevalence of thoracic vertebral malformations in French bulldogs, Pugs and English bulldogs with and without associated neurological deficits. *Vet. J.* **221**: 25–29. [Medline] [CrossRef]
18. Shim, D. M. and Oh, S. K. 2008. Congenital absence of unilateral lumbar articular process - a case report -. *Asian Spine J.* **2**: 106–108. [Medline] [CrossRef]
19. Shires, P. K., Waldron, D. R. and Hedlund, C. S. 1991. A biomechanical study of rotational instability in unaltered and surgically altered canine thoracolumbar vertebral motion units. *Prog. Vet. Neurology* **2**: 6–14.
20. Smith, G. K. and Walter, M. C. 1988. Spinal decompressive procedures and dorsal compartment injuries: comparative biomechanical study in canine cadavers. *Am. J. Vet. Res.* **49**: 266–273. [Medline]
21. Werner, T., McNicholas, W. T., Kim, J., Baird, D. K. and Breur, G. J. 2004. Aplastic articular facets in a dog with intervertebral disk rupture of the 12th to 13th thoracic vertebral space. *J. Am. Anim. Hosp. Assoc.* **40**: 490–494. [Medline] [CrossRef]