

CASE REPORT

Iatrogenic bilateral hypoglossal palsy following spinal surgery

Shrijit Panikkar¹  · Govind Tol² · Irfan Siddique¹

Received: 6 January 2017 / Revised: 29 June 2017 / Accepted: 5 July 2017 / Published online: 11 July 2017
© Springer-Verlag GmbH Germany 2017

Abstract

Introduction Bilateral hypoglossal palsy is a rare complication during airway management in surgery.

Case presentation Isolated bilateral hypoglossal palsy was noted post-operatively in a patient who underwent multiple spinal surgeries associated with prone anaesthesia.

Discussion Risk factors include difficult, multiple intubations, prolonged surgical time, throat pack, and hyperextension of the neck during intubation.

Conclusion We aim to create awareness about this complication which has a significant morbidity and negative effect on patient outcomes.

Keywords Bilateral hypoglossal · Palsy · Spinal surgery · Prone

Introduction

We report here a case of bilateral hypoglossal palsy developing in a patient who underwent multiple spinal surgeries and embolization for his lumbar metastasis from

a renal cell cancer. This was understood to be due to an intubation or position-related trauma from the airway management. This is a rare complication of airway management and/or positioning in surgery with significant morbidity. The review of the literature has revealed only few case reports but none mention a bilateral hypoglossal palsy from a prone positioning for spinal surgery.

Case presentation

A 49-year-old man with a weight of 70.9 kg of presented with worsening back pain and numbness in legs. Investigations revealed a lytic L1 (lumbar) vertebral metastasis from a newly diagnosed renal cell carcinoma with early compression of the cauda equina and conus. He was admitted to the spinal unit for surgery. Embolization of the tumour was attempted under general anaesthesia, and on the next day, he underwent an antero-lateral procedure to debulk and decompress the L1 (lumbar) vertebral metastasis along with an anterior reconstruction. He recovered well from the operation. He was only allowed limited mobilisation. A week later, he was planned for a posterior stabilisation. He underwent a successful endovascular embolization of the L1 (lumbar) vertebral metastasis prior to the second spinal surgery. The next day, he underwent a posterior stabilisation from T11 (thoracic) to L3 (lumbar) in a prone position on an Allen table. This was a 5-h-long surgery. There were no throat packs used and the cuff pressure was maintained between 15 and 20 mm of mercury. This was an endotracheal intubation. Post-operatively, he was noticed to have slurring of speech and had difficulty in swallowing when he was transferred to the high dependency unit after about 2 h of surgery. He was also noted to have an inability to move his tongue. This

✉ Shrijit Panikkar
jpshrijit@yahoo.com

Govind Tol
Govind.Tol@srft.nhs.uk

Irfan Siddique
Irfan.siddique@srft.nhs.uk

¹ Department of Spinal Surgery, Salford Royal NHS Foundation Trust, Stott Lane, Salford, Manchester M6 8HD, UK

² Department of Anaesthesia, Salford Royal NHS Foundation Trust, Stott Lane, Salford, Manchester M6 8HD, UK

was initially thought to be due to possible pharyngeal and glottic oedema following an intubation trauma. This did not improve in 48 h despite a short course of steroids. The otolaryngology review and a direct laryngoscopy revealed no significant oedema and that the vocal cords were fully mobile. As he still could not move his tongue and had severe difficulty in initiating deglutition, a clinical diagnosis of bilateral hypoglossal palsy was made. This was treated conservatively. He had further investigation with scans of the skull base and the neck to rule out any other compressive pathology and to visualise possible injury to the nerve. The magnetic resonance imaging (MRI) scans did not show any obvious cause. His deglutition improved gradually and he was discharged home. He could take oral feeds in 3–4 weeks. He made a gradual recovery over the course of the next 2–3 months and his speech also improved. He underwent a delayed nerve conduction and electromyographic study after 2 months when his symptoms were improving. This revealed a mild reduction in the interference pattern on the left side and chronic partial denervation and reinnervation changes on the right side. This was suggestive of neuropraxia on the left and possible axonotmesis on the right.

Discussion

Bilateral hypoglossal palsy after airway management is very rare with just a handful of case reports in the literature [1]. Majority of the patients are male and most cases are seen following endotracheal intubation in supine and semi-supine position [2]. The surgical procedures cited in most case reports are related to otolaryngology, shoulder surgery, or with prolonged life support [3]. Repeated airway attempts, intra- and post-operative intubation would increase the iatrogenic trauma to airway mucosa and underlying nerves [2].

The hypoglossal nerve is purely motor. It arises from the hypoglossal nuclei in the medulla and exits through the hypoglossal canal in close relation to the IX, X, and XI cranial nerves. It descends caudally, with the internal carotid artery, vagus, and jugular vein in the cervical neurovascular bundle. At the angle of mandible, it lies deep to the posterior belly of digastric in the submandibular region, continuing antero-superior to the greater cornu of hyoid before finally branching under the tongue to supply the intrinsic muscles. This puts the nerve in proximity to the airway management equipment.

The mechanism of injury is thought to include compression, stretching, shearing, or impingement of the nerve during airway management. Nerve compression can occur over the hyoid bone, where the nerve is relatively superficial, as may happen during a difficult intubation with

application of cricoid pressure [4]. The nerve may be stretched along the lateral aspect of transverse process of first cervical vertebra after hyperextension of neck or during prolonged intubation. There may be shearing of the distal nerve fibres as they enter the tongue during oropharyngeal manipulation. Most injuries are neuropraxic and self-resolving. However, axonotmesis may occur which is characterized by slow recovery.

Typical clinical features include difficulty in manipulating food in the mouth, difficulty in initiating deglutition, dysarthria, and at times even dyspnoea. Examination reveals a flaccid tongue with fasciculation characteristic of denervation reinnervation injury [5]. Diagnosis is often delayed and is one of the exclusion after imaging and consultation with ear nose throat specialist and neurology to rule out more critical diagnoses such as stroke, hematoma, or airway obstruction. An MRI scan of the head and neck regions can help trace the nerve in a segmental manner to detect any significant pathologies [6]. Needle electromyography of genioglossus can detect acute denervation injury as well as can pick up recovery, but is difficult to perform and needs patient cooperation.

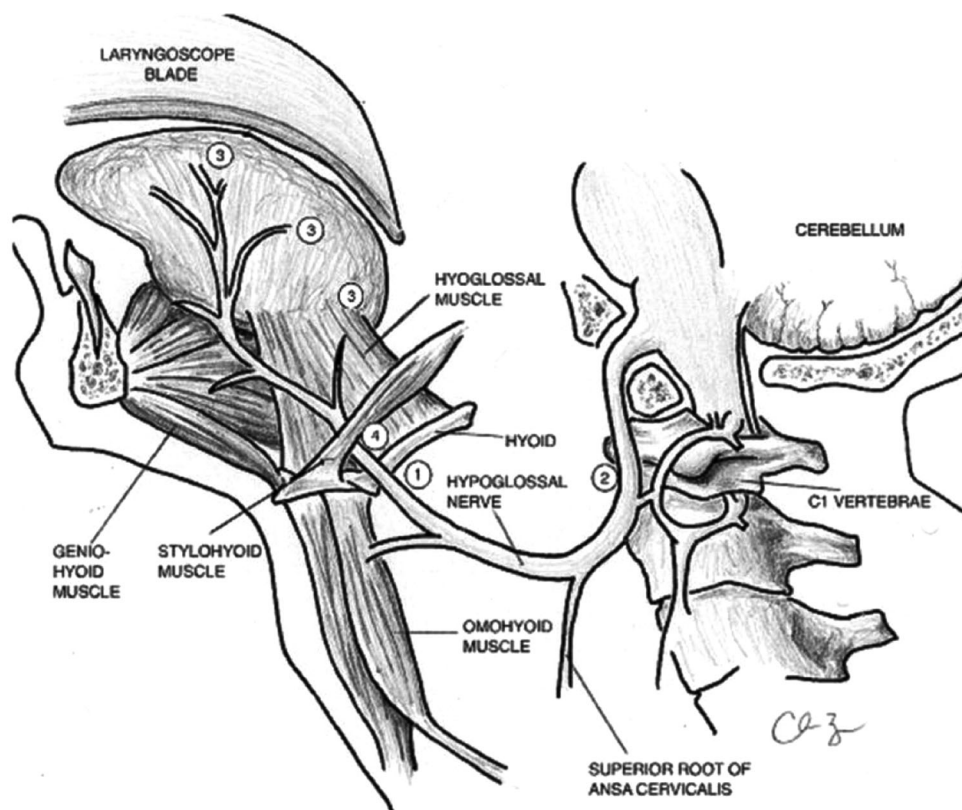
Many mechanisms have been postulated to cause this. The commonest are use of a laryngeal mask, erroneous positioning of the mask, high cuff pressures in endotracheal tubes, and positioning of the patient which include neck extension. The duration of the surgery has a direct relation as the pressure is sustained for a longer period causing more damage [2, 10].

In this particular case, the patient already had previous procedures in the lateral position for an anterior corpectomy which lasted for almost 5 h, followed by further procedures for embolisation in the supine position. He made a good recovery from these procedures without developing any post-operative problems. The major risk factors in this case were repeated intubations over a short period, a long procedure, and prone positioning which could have predisposed him to have the neck in extension.

Management is largely supportive and symptomatic including supplementary oxygen, speech and language assessment [7], and appropriate rehabilitation. Corticosteroids are indicated if there is airway oedema, though literature review showed similar outcomes in non-treated patients [8]. In patients who have difficulty in swallowing, alternative feeding methods and oral care and management of secretions are essential to prevent aspiration-related complications (Fig. 1).

Preventive measures are largely focussed on a proper positioning of patient especially avoiding hyperextension during positioning, using a shorter blade laryngoscope, monitoring the cuff pressure, and periodically deflating the cuff in prolonged surgeries [9].

Fig. 1 Anatomic locations for hypoglossal nerve injury during airway management [2]. 1 Nerve compression or impingement can occur at the hyoid bone, where the nerve is relatively superficial in its course [9, 11–15]. 2 Nerve stretching can occur at the lateral aspect of the transverse process of the first cervical vertebrae (C1). 3 Pressure exerted by the laryngoscope blade can lead to lateral retraction and shearing of the distal nerve fibres that supply motor input to the tongue. 4 A calcified stylohyoid ligament has also been reported in association with hypoglossal nerve impingement. Drawing courtesy of Dr. C. Barnes



Conclusion

This is a very rare complication of anaesthesia, but has a significant morbidity due to its effect on speech and swallowing. This causes severe emotional and mental trauma to the patient. One needs to anticipate situations, where patients might need multiple or prolonged intubation and possibly use fibre optic aids to assist intubation. Special attention to patient position, airway securing and monitoring of patients with risk factors is essential due to delayed presentation. Due to significant associated morbidity, it raises a question as to whether this should be included in the consent as a complication of intubation in patients undergoing prolonged or repeated procedures.

Compliance with ethical standards

Conflict of interest None of the authors has any potential conflict of interest.

Informed consent Informed consent has been obtained from all individuals included in the study.

References

1. Sommer M, Schuldt M, Runge U, Gielen-Wijffels S, Marcus M (2004) Bilateral hypoglossal nerve injury following the use of the laryngeal mask without the use of nitrous oxide. *Acta Anaesthesiol Scand* 48(3):377–378
2. Shah A, Barnes C, Spiekerman C, Bollag L (2015) Hypoglossal nerve palsy after airway management for general anesthesia. *Anesth Analg* 120(1):105–120
3. Fritz M, Kang B, Fox T (2017) Practical neurology—iatrogenic hypoglossal nerve palsy (Internet). *Practical Neurology*. <http://practicalneurology.com/2014/02/iatrogenic-hypoglossal-nerve-palsy/>. Cited 14 March 2017
4. Evers K, Eindhoven G, Wierda J (1999) Transient nerve damage following intubation for trans-sphenoidal hypophysectomy. *Can J Anesth* 46(12):1143–1145
5. Streppel M, Bachmann G, Stennert E (1997) Hypoglossal nerve palsy as a complication of transoral intubation for general anesthesia. *Anesthesiology* 86(4):1007
6. Lin H, Barkhaus P (2009) Cranial nerve XII: the hypoglossal nerve. *Semin Neurol* 29(01):045–052
7. Alves P (2010) Imaging the hypoglossal nerve. *Eur J Radiol* 74(2):368–377
8. Laskawi R, Rohrbach S (2005) Impaired motor functions. Surgical and conservative procedures for restoring motor functions of the facial nerve, accessory nerve, hypoglossal nerve. *Laryngorhinootologie* 84(Suppl 1):S142–S155
9. Lopes G, Denoel C, Desuter G, Docquier MA (2009) Two cases of isolated unilateral paralysis of hypoglossal nerve after uncomplicated orotracheal intubation. *Acta Anaesthesiol Belg* 60:191–193
10. Tesei F, Poveda L, Strali W, Tosi L, Magnani G (2006) Unilateral laryngeal and hypoglossal paralysis following rhinoplasty in general anaesthetic. *Acta Otorhinolaryngol Ital* 26(4):219–221
11. Dzielas R, Ludemann P (2002) Hypoglossal nerve palsy as complication of oral intubation, bronchoscopy and use of the laryngeal mask airway. *Eur Neurol* 47:239–243

12. Mullins RC, Drez D Jr, Cooper J (1992) Hypoglossal nerve palsy after arthroscopy of the shoulder and open operation with the patient in the beach-chair position. A case report. *J Bone Joint Surg Am* 74:137–139
13. Haslam B, Collins S (2013) Unilateral hypoglossal neurapraxia following endotracheal intubation for total shoulder arthroplasty. *AANA* 81:233–236
14. Nagai K, Sakuramoto C, Goto F (1994) Unilateral hypoglossal nerve paralysis following the use of the laryngeal mask airway. *Anaesthesia* 49:603–604
15. Ratnaraj J, Todorov A, McHugh T, Cheng MA, Laurysen C (2002) Effects of decreasing endotracheal tube cuff pressures during neck retraction for anterior cervical spine surgery. *J Neurosurg* 97:176–179