

RESEARCH

A meta-analysis for the echocardiographic assessment of right ventricular structure and function in ARVC: a Study by the Research and Audit Committee of the British Society of Echocardiography

Mohammad Qasem¹, Victor Utomi¹, Keith George¹, John Somauroo^{1,2}, Abbas Zaidi³, Lynsey Forsythe¹, Sanjeev Bhattacharya³, Guy Lloyd³, Bushra Rana⁴, Liam Ring⁵, Shaun Robinson⁴, Roxy Senior⁶, Nabeel Sheikh⁷, Mushemi Sitali⁸, Julie Sandoval⁹, Richard Steeds¹⁰, Martin Stout¹¹, James Willis¹² and David Oxborough¹

¹Research Institute for Sport and Exercise Sciences, Liverpool John Moores University, Liverpool, UK

²Countess of Chester Hospital, NHS Trust, Chester, UK

³Barts Heart Centre, St Bartholomew's Hospital, London, UK

⁴Papworth Hospital NHS Trust, Cambridge, UK

⁵West Suffolk NHS Trust, Bury St Edmunds, UK

⁶National Heart and Lung Institute, Imperial College, London, UK

⁷St Georges University Hospital, London, UK

⁸Guys and St Thomas's NHS Trust, London, UK

⁹Leeds Teaching Hospitals NHS Trust, Leeds, UK

¹⁰University Hospitals Birmingham NHS Trust and Institute of Cardiovascular Sciences, University of Birmingham, Birmingham, UK

¹¹Department of Cardiology, University Hospital of South Manchester, Manchester, UK

¹²Royal United Hospital, Bath, UK

Correspondence should be addressed to D Oxborough
Email
d.l.oxborough@ljamu.ac.uk

Abstract

Introduction: Arrhythmogenic right ventricular cardiomyopathy (ARVC) is an inherited pathology that can increase the risk of sudden death. Current task force criteria for echocardiographic diagnosis do not include new, regional assessment tools which may be relevant in a phenotypically diverse disease. We adopted a systematic review and meta-analysis approach to highlight echocardiographic indices that differentiated ARVC patients and healthy controls.

Methods: Data was extracted and analysed from prospective trials that employed a case-control design meeting strict inclusion and exclusion as well as *a priori* quality criteria. Structural indices included proximal RV outflow tract (RVOT₁) and RV diastolic area (RVD_{area}). Functional indices included RV fractional area change (RVFAC), tricuspid annular systolic excursion (TAPSE), peak systolic and early diastolic myocardial velocities (S' and E', respectively) and myocardial strain.

Results: Patients with ARVC had larger RVOT₁ (mean \pm s.d.; 34 vs 28 mm, $P < 0.001$) and RVD_{area} (23 vs 18 cm², $P < 0.001$) compared with healthy controls. ARVC patients also had lower RVFAC (38 vs 46%, $P < 0.001$), TAPSE (17 vs 23 mm, $P < 0.001$), S' (9 vs 12 cm/s, $P < 0.001$), E' (9 vs 13 cm/s, $P < 0.001$) and myocardial strain (−17 vs −30%, $P < 0.001$).

Key Words

- echocardiography
- arrhythmogenic right ventricular cardiomyopathy
- ARVC

Conclusion: The data from this meta-analysis support current task force criteria for the diagnosis of ARVC. In addition, other RV measures that reflect the complex geometry and function in ARVC clearly differentiated between ARVC and healthy controls and may provide additional diagnostic and management value. We recommend that future working groups consider this data when proposing new/revised criteria for the echocardiographic diagnosis of ARVC.

Introduction

Arrhythmogenic right ventricular cardiomyopathy/dysplasia (ARVC/D) is a genetic disease that is characterized by (i) fibro-fatty replacement, (ii) myocardial atrophy, (iii) fibrosis, and (iv) chamber dilation and aneurysms (1). Pathological changes occur predominantly in the right ventricle (RV) and culminate in heart failure (1, 2, 3) with sudden cardiac death (SCD), a common outcome (1, 2, 4). It is clearly important to identify those with ARVC as early as possible in order to treat and reduce health risk.

The prevalence of ARVC in the general population has been reported to be 1:5000, affecting men more frequently than women with a ratio of 3:1 (5, 6). The accuracy of available prevalence data is, however, still debated largely due to the complexities in diagnosing the disease (7). Currently, the diagnosis of ARVC can be established using a set of major and minor criteria proposed by an International Task Force in 1994 and updated/revised in 2010 (8, 9). The structural and functional assessment of the RV, using transthoracic echocardiography, is central to ARVC diagnosis in the original and updated task force criteria. Although the recent task force revision has improved specificity of diagnosis, there has been little impact upon diagnostic sensitivity (3) which may be due to the reliance on only two RV anatomical measures (the RV outflow tract from a parasternal long (RVOT_{PLAX}) and short axis (RVOT₁)) and one functional measure (RV fractional area change (RVFAC)). It is likely that these parameters do not fully reflect the complexities of RV structure and function specifically in ARVC where phenotype expression is variable (1, 7) and regional changes in structure and function are likely. A more comprehensive echocardiographic assessment of the RV in ARVC patients is warranted (10) in order to potentially improve diagnostic accuracy.

The use of techniques, such as tissue Doppler imaging and speckle tracking echocardiography (STE), that quantifies regional myocardial deformation/strain have the potential to provide new information in ARVC (11, 12, 13). Likely, due to the low prevalence of the disease,

these studies are often based on relatively small sample sizes that restrict generalizability to all populations (13, 14, 15). A qualitative assessment of recent research in this area highlights limitations such as a lack of a matched control group and variability in echocardiographic tools and techniques. To determine if new echocardiographic data may provide additional diagnostic options this study employed a systematic review (with clear quality control and inclusion/exclusion criteria) alongside a meta-analysis to determine which RV structural and functional parameters are different between patients with ARVC and matched, healthy control subjects.

Methods

Search criteria and processes

Study selection We identified all transthoracic echocardiographic studies that examined ARVC patients and recorded parameters related to RV structure and/or function published between 1990 and 2015 and written with an English language abstract. Electronic search engines used included Pub Med; Discover; Scopus; Web of Science; Cochrane, and we employed relevant Medical Subject Headings and keywords related to our search. The following search keyword strings were used:

- Echocardiography AND (ARVC OR ARVD) AND (arrhythmogenic right ventricular cardiomyopathy OR arrhythmogenic right ventricular dysplasia).

The initial search identified 966 records. The first level of filtration included screening of titles, authors and abstracts and was completed independently by two reviewers (M Q, D O). In the case of discrepancy between reviewers a third independent reviewer was invited to feedback and subsequently a final review meeting was undertaken to determine a consensus opinion. Initial filtration removed case studies, duplications, reviews, animal studies as well as comparing the abstract against

the following inclusion criteria: (i) genotype-positive ARVC patients, (ii) age range 16–65 years, and (iii) all participants had echocardiography and reported RV parameters, (16), which matched description of the task force criteria (8, 9). This filtration identified 45 studies for complete evaluation of the full research paper by the same two independent reviewers. These 45 papers were also subjected to a quality assessment using a checklist modified by the research team from the PRISMA (17) and STROBE (18) statements, to develop the systematic evaluation of the quality of observational studies. A threshold of 40% adherence of the quality criteria checklist was adopted. From the 45 papers identified 19 were excluded based on incomplete data sets with abstract only, 12 due to lack of including both an ARVC and a control groups, 2 non-English manuscripts that were missed by the original filtration process, and 2 with poor overall quality scores. The remaining 10 papers were subject to full data extraction and meta-analysis. The overall filtration process is detailed in Fig. 1.

Data extraction Data extraction was undertaken by two investigators (M Q, D O) and where present included data for the following RV structural parameters: the proximal outflow tract from a parasternal short axis (RVOT₁), distal outflow tract from a parasternal short

axis (RVOT₂), proximal outflow tract from a parasternal long axis (RVOTplax), basal inflow diameter (RVD₁), mid-inflow diameter (RVD₂), base-to-apex length (RVD₃) and RV end-diastolic area (RVD_{area}). In addition, the following functional RV parameters were extracted: fractional area change (RVFAC), tricuspid annular plane systolic excursion (TAPSE), peak systolic myocardial velocity (RVS'), peak early diastolic myocardial velocity (RVE'), peak late diastolic myocardial velocity (RVA'), peak global longitudinal strain (RV ϵ) and peak global systolic strain rate (RVSRS'). Demographic data of age, body surface area and body mass index were also collected. All relevant data were extracted directly from the 10 papers into a spreadsheet (Excel 2010, Microsoft). Control and ARVC groups were coded discretely for each study.

Statistical analysis

Continuous data for RV morphology and functional data were recorded as group mean \pm S.D. for each study. Due to insufficient study numbers, RVOT₂, RVOTplax, RVD₁, RVD₂, RVD₃, RVA' and RVSRS' were not included in the meta-analysis but instead were assessed qualitatively. All statistical analysis was carried out with comprehensive meta-analysis software Version 3.3.070 (Biostat, Englewood, NJ, USA). A random effect meta-analysis model was used to quantify the weighted mean difference (WMD) (i.e. difference in means) and 95% confidence intervals of ARVC group compared with control group allowing the production of parameter-specific forest plots. To estimate or quantify the impact of between-study variation (heterogeneity) of the studies, I^2 and τ^2 were used (19). Cut-off values were established to provide clinically meaningful data utilizing the pooled range data. Where there was overlap between groups a consensus approach was used which drew on the expertise of the working group. This is common practice in guideline development where ambiguous or inconclusive findings are evident (20). No ethical clearance required for this meta-analysis, all studies used have been previously published.

Results

Baseline characteristics of the ARVC patients are summarized in Table 1 and characteristics of included studies in Table 2. The pooled mean data for the specific echocardiographic parameters, cut-off values and an assessment of heterogeneity are presented in Table 3.

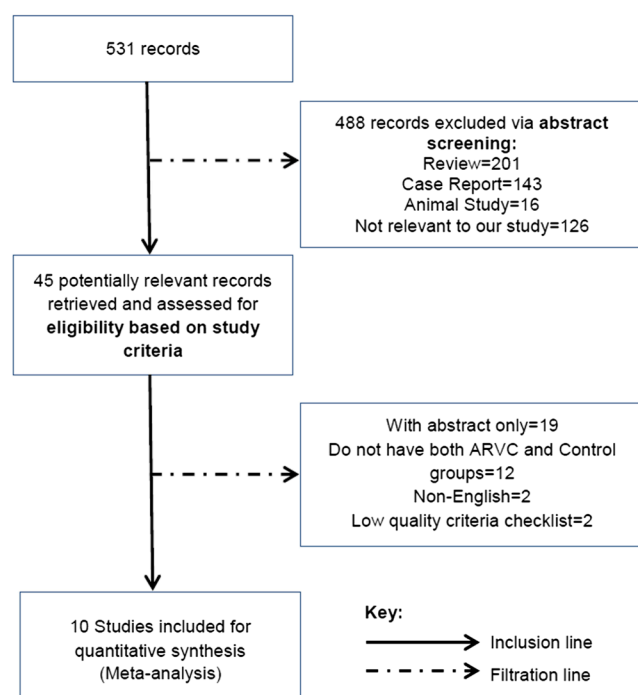


Figure 1
Flow diagram of literature filtration process.

Table 1 Characteristics of included studies.

Reference	Location	Code ^a	Sample size	Ages	Task force criteria	RVOT ₁ (mm)	RVD _{area} (cm ²)	RVFAC (%)	TAPSE (mm)	RV S' (cm/s)	RVE' (cm/s)	RV strain (%)
(13)	Sweden	1	25 (11 M/14 F)	38	1994	NR	NR	NR	25.9 ± 2.8	13.7 ± 2	14.6 ± 3.4	NR
		2	15 (10 M/5 F)	39 ± 12.6					22.1 ± 5.5	11.9 ± 3	10.5 ± 3.1	NR
(40)	USA	1	29 (17 M/12 F)	37.1 ± 14.2	1994	31.1 ± 4.7	17.9 ± 3.5	41 ± 7	NR	NR	NR	NR
		2	29 (17 M/12 F)	37 ± 14.2		38.9 ± 4.7	25.2 ± 7.7	27 ± 16				
(46)	USA	1	35 (23 M/13 F)	32 ± 8	1994	28 ± 4	NR	40 ± 9	18.7 ± 3.5	9 ± 1.6	9.4 ± 2	-28 ± 11
		2	30 (19 M/11 F)	38 ± 12		34 ± 8	NR	35 ± 12	13.7 ± 5.8	6.4 ± 2.2	6.7 ± 2.7	-10 ± 6
(14)	USA	1	43 (27 M/16 F)	32 ± 11	1994	NR	NR	54 ± 7	19.5 ± 3.9	10.2 ± 1.5	NR	-33.3 ± 10.4
		2	10 (6 M/4 F)	34 ± 12				43 ± 8	16.8 ± 3.4	7.9 ± 1.5	NR	-17.2 ± 10.1
(38)	Italy	1	40 (26 M/14 F)	28 ± 12	1994	29.6 ± 5	19.3 ± 3.7	46 ± 6	NR	NR	NR	NR
		2	40 (28 M/12 F)	28 ± 8		35.6 ± 6.8	25.7 ± 3	40 ± 8	NR			
(4)	USA	1	25 (18 M/7 F)	32 ± 6	1994	26 ± 2	17 ± 3	44 ± 7	NR	9.9 ± 1.2	NR	-25 ± 9
		2	52 (22 M/30 F)	41 ± 12		29 ± 4	20 ± 5	32 ± 8	22.5 ± 2.6	7.4 ± 2.1	13.7 ± 2.4	-19 ± 7
(34)	Netherlands	1	34 (19 M/15 F)	35 ± 9	1994	NR	NR	NR	17.2 ± 4	11.2 ± 1.9	8.2 ± 3.6	-29.6 ± 3
		2	34 (20 M/14 F)	45 ± 14					NR	7.4 ± 1.9	14.7 ± 2.7	-17.8 ± 6.4
(15)	Italy	1	25 (21 M/4 F)	45 ± 10	1994	26 ± 3.2	16.5 ± 4.2	46 ± 6	NR	14.4 ± 2.7	11.8 ± 3	NR
		2	15 (14 M/1 F)	44 ± 15		30.9 ± 2.9	19.2 ± 3.8	42 ± 7	25.3 ± 2.9	13 ± 2.1	NR	NR
(36)	Sweden	1	22 (M)	36	1994	NR	NR	NR	19.1 ± 5	8.2 ± 2.5	NR	NR
		2	17 (M)	49					23.1 ± 2.3	12.9 ± 1.4	NR	-28.6 ± 2.8
(3)	Italy	1	19 (12 M/7 F)	42.2 ± 13.2	1994	NR	NR	50 ± 4	18.6 ± 1.9	9.8 ± 1.8	NR	-20.4 ± 4.7
		2	19 (12 M/7 F)	41.9 ± 13.2				43 ± 4				

^aSub group within study 1=control, 2=ARVC.

RV proximal outflow (RVOT₁), RV end-diastolic area (RVD_{area}), RV fractional area change (RVFAC), tricuspid annular plane systolic excursion (TAPSE), RV peak systolic myocardial velocity (RV S'), RV peak early diastolic myocardial velocity (RVE') and RV global longitudinal strain (RV ε), NR, not reported.

Table 2 Baseline characteristics.

Study	Syncope	Palpitations	Family history	Anti-arrhythmic	Beta-blockers	Defibrillator	RV systolic pressure (mmHg)	Ventricular tachycardia	Ventricular arrhythmias	Other
(13)		10		3	11	2	NR	9	NR	4
(46)	11	16	NR	NR	20	21	30 ± 18	NR	NR	NR
(14)	3	9	4	3	5	1	1 ^a	NR	NR	NR
(38)	NR	NR	17	NR	NR	NR	NR	7	28	NR
(4)	13	18	NR	NR	NR	45	29 ± 6	14	NR	9
(34)		3	NR	2	17	12	NR		22	NR
(15)	NR	NR	NR	NR	14	11	NR	NR	NR	NR
(36)	NR	NR	NR	13	NR	9	NR	NR	NR	NR
(3)	NR	NR	NR	Drug therapy was not discontinued	NR	NR	NR	NR	NR	NR
(46)	NR	NR	NR	NR	NR	NR	NR	NR	NR	NR

^aMean RV systolic pressure was within normal range in both groups with only a single patient with ARVC demonstrating significant tricuspid regurgitation. NR, not reported.

The meta-analysis highlighted a significantly larger RVOT₁ ($P < 0.00$, 95% CI: 3.649–7.112mm) and RVD_{area} ($P < 0.00$, 95% CI: 2.607–7.060cm²) in the ARVC group compared with controls.

RV functional data was significantly lower for RV ϵ ($P < 0.00$, 95% CI: 8–15%), RVFAC ($P < 0.00$, 95% CI: –11 to –6%), TAPSE ($P < 0.00$, 95% CI: –5.488 to –4mm), RVS' ($P < 0.00$, 95% CI: –3 to –2cm/s) and RVE' ($P < 0.00$, 95% CI: –5 to –2cm/s) (Table 1). Exemplar forest plots are presented in Fig. 2.

Discussion

The main findings from this systematic review and meta-analysis are (i) there are significant differences in a range of structural and functional echocardiographic parameters

between ARVC patients and healthy, control participants, and (ii) data from tissue Doppler and STE may represent useful additional tools when attempting to differentiate RV phenotype of ARVC patients from healthy controls.

Right ventricular structure

ARVC is a genetic disease that may present with atrophy of the RV myocardium, leading to aneurysmal dilation and wall motion abnormalities (21, 22). Although this is a typical morphological pattern, the genotype–phenotype expression is variable often leading to heterogeneous structural adaptation (23, 24). That aside, a ‘triangle of dysplasia’ in terms of both structure and function is frequently described which leads to localized dilation and dysfunction at the inflow tract (sinus), apex and RVOT (25, 26) or infundibulum (RVOT₂) (27).

Table 3 Data are pooled mean estimates (95% CI), [number of studies, number of participants].

Parameters	ARVC	Control	Cut-off	Difference in mean (95% CI)	Heterogeneity test		
					Heterogeneity	P (%)	P value
RVOT ₁ (mm)	34 (30–38) [$n=5$; 166]	28 (26–30) [$n=5$; 155] ^a	31	5.4 (3.6–7.1)	3	66	0.02
RVD _{area} (cm ²)	23 (19–26) [$n=4$; 136]	18 (17–19) [$n=4$; 119] ^a	20	4.8 (2.6–7.1)	3.7	75	0.007
RVFAC (%)	37.6 (33.4–41.9) [$n=7$; 195]	45.9 (42.4–49.5) [$n=7$; 217] ^a	42	–8.1 (–10.6 to –5.6)	0.01	64	0.012
TAPSE (mm)	18 (16–20) [$n=6$; 125]	23 (20–25) [$n=6$; 179] ^a	20	–4.7 (–5.5 to –3.9)	0	51	0.444
RVS' (cm/s)	9 (8–10) [$n=8$; 192]	12 (10–13) [$n=8$; 229] ^a	10	–2.7 (–3.2 to –2.2)	0.2	37	0.135
RVE' (cm/s)	9 (7–11) [$n=4$; 94]	13 (10–16) [$n=4$; 120] ^a	10	–3.8 (–5.2 to –2.4)	1.42	69	0.021
RV strain (%)	–17 (–21 to –13) [$n=5$; 154]	–29 (–31 to –27) [$n=5$; 157] ^a	–21	11.5 (7.7–15.3)	15	83	0

^a $P < 0.001$ vs ARVC.

RV proximal outflow (RVOT₁), RV end-diastolic area (RVD_{area}), RV fractional area change (RVFAC), tricuspid annular plane systolic excursion (TAPSE), RV peak systolic myocardial velocity (RVS'), RV peak early diastolic myocardial velocity (RVE') and RV global longitudinal strain (RV ϵ).

Heterogeneity evaluation: (1) $P = 25\%$ low heterogeneity, 50% moderate heterogeneity, 50–75% high heterogeneity, (2) $P < 0.1$ for statistical significance, (3) $\tau^2 > 1$, statistical significant for heterogeneity.

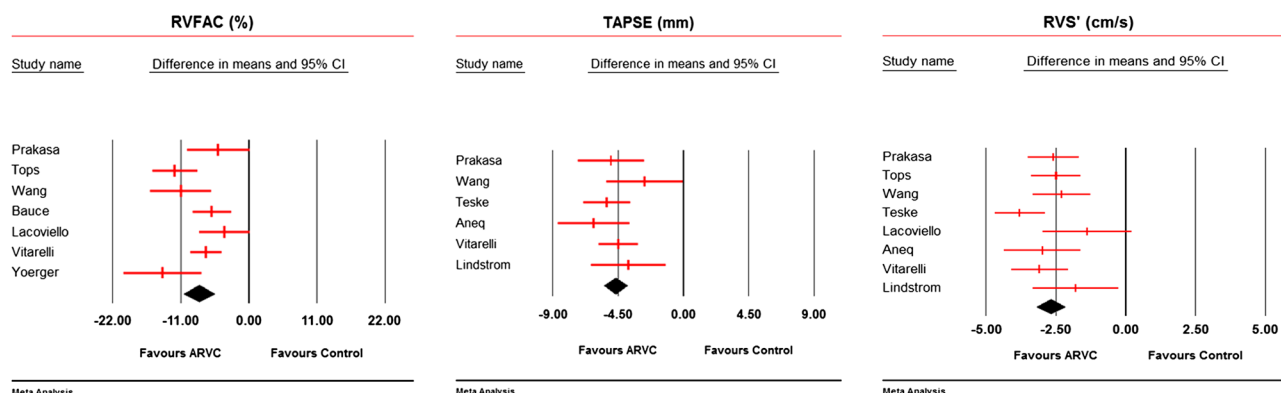


Figure 2

Exemplar forest plots for selected RV structural and functional parameters: RV fractional area change (RVFAC), tricuspid annular plane systolic excursion (TAPSE) and peak systolic myocardial velocity (RVS).

Apical involvement is often seen in more advanced stages of the disease (25, 26) and the RVOT is the most common starting point of non-ischemic ventricular arrhythmias (28). This leads to the RVOT and/or inflow of the RV being the primary focus for early detection and subsequent serial assessment (25).

The current echocardiographic component of the task force criteria focuses on determining any localized structural dilatation of the outflow tract from either a short or long axis only. Data from the current systematic review and meta-analysis supports this. Interestingly, we present no overlap in RVOT₁ between controls and ARVC patients with a cut-off of 30 mm clearly discriminating among the two groups. This cut-off is lower than the current task force as well as the normative guidelines proposed by the American Society of Echocardiography (ASE) and raises the potential for a false-negative result when using existing criteria. Our data also demonstrate the importance of providing a holistic echocardiographic assessment of RV structure. The enlarged RVD_{area} seen in ARVC patients compared with the healthy controls suggests that chamber enlargement occurs at the inflow and apex also. The RVD_{area} cut-off based on our analysis is 19 cm² but this is much lower than the normal value as proposed by the ASE. This may be a consequence of the specific age-matched control groups employed in the selected studies but clearly highlights the need for further clarification of normality.

Due to an insufficient number of studies reporting data for RVD₁, we were unable to conduct a meaningful meta-analysis on this parameter. Qualitative assessment of those few studies that did implement this parameter provides additional support for RV enlargement in ARVC

patients. It is apparent that these additional parameters should be considered in conjunction with the outflow tract in order to better detail RV morphology in patients with ARVC. This supports the fundamental pathological mechanisms of disease progression and the known distribution of fatty infiltration.

Right ventricular function

Both major and minor task force criteria for ARVC include the presence of regional wall motion abnormalities and/or aneurysms (9). This clearly highlights the importance of functional RV wall degradation as part of the disease process. It is important to note that this is based on a subjective assessment, which is dependent on operator experience as well as image quality. Subtle changes in function may be missed, which could increase the risk of false-negative findings (29, 30). The current criteria also support an assessment of RVFAC, albeit this is only complementary and still must be in the presence of subjective regional wall motion abnormalities. Data from this meta-analysis provides additional insight including an RVFAC cut-off at 42% compared with 33% in the task force criteria. Data from the matched controlled groups ($n=217$), however, did not present with values below 42% raising the question of what is considered normal.

The complex nature of RV structure results in an equally complex 'picture' related to function. In healthy individuals, RV ejection is predominantly driven by a combination of stored kinetic mechanics derived from gravity and inspiration as well as longitudinal shortening (31). It has been demonstrated that this functional response may vary in different disease models in order to

compensate for changes in the structural and functional integrity of the RV (32, 33). In view of this a number of studies have assessed longitudinal RV function in ARVC utilizing TAPSE and TDI indices (1, 3, 15, 34). These data highlight the potential for detection in the early stages of the disease (1, 3) with a clear differential from healthy controls when using a 10cm/s cut-off for systolic and diastolic myocardial tissue velocities. Aneq *et al.* (36), demonstrated that both TAPSE and systolic myocardial velocities were strong diagnostic parameters for ARVC but further highlight the superiority of TDI particularly in detecting ARVC at its early stage (35, 36). Because of the inverse relationship between myocardial velocities and ageing process (37), the risk of a false-positive result for ARVC would increase with advancing age and hence caution is required when interpreting in older age groups. Consequently, addition of parameters of intrinsic RV myocardial indices (TDI) provides additional diagnostic and/or monitoring benefit over and above RVFAC alone.

STE is a useful technique in the assessment of RV longitudinal function, with many studies demonstrating its value in variable disease states (3, 33, 38). In a study assessing the diagnostic utility of STE in ARVC, it was observed that RV ϵ was the strongest independent predictor of cMR-derived reduction in RV ejection fraction (39). In addition, Greiner *et al.* (33) demonstrated that when screening 94 patients (13 with ARVC), RV ϵ provided additional diagnostic accuracy such that reduced false-negative results were noted compared with the use of traditional echocardiographic parameters alone (33). In addition, both Yoerger *et al.* (40) and Sarvari *et al.* (41) reported that RV ϵ has the highest sensitivity and specificity for the diagnosis of ARVC (40, 41). In the current meta-analysis, global systolic ϵ was reported as an average of either the free wall or the RV portion of the septum. There were no ARVC patients demonstrating a peak RV ϵ above -21% ($n=154$); this is much lower than the currently accepted normal RV ϵ of -28% and lower than the control measure of -29% . On this basis, RV ϵ may well provide additional value in the diagnosis and management of patients with ARVC.

Clinical/imaging implications

There is ongoing debate in relation to the value of task force criteria in ARVC (42, 43). Some authors noted a significant reduction in the sensitivity of the revised task force criteria (3, 44) and it has been suggested that false-positive results may be a consequence of

‘overinterpretation’ of subtle wall motion abnormalities (i.e. regional hypokinesia), which fall within the wide spectrum of normal RV function (3, 43). It is likely that the current task force criteria are limited by the number of measures undertaken. Additional parameters highlighted in this meta-analysis may improve diagnostic accuracy. As the current task force criteria is based on a multidisciplinary approach including clinical assessment, ECG, echocardiography, cMR, genetics and family history, any addition to the utilization of echocardiography needs to be made in this context and would likely add further corroborative information.

Limitations and future directions

First, it is important to note that due to the nature of this type of study there is the real risk of methodological and selection bias and specifically related to blinding or non-blinding of outcome assessment. The homogeneity and heterogeneity values presented here highlight that this is only a minor effect, however, it is important to acknowledge this potential limitation when interpreting the findings.

Due to the importance of establishing well-defined quality criteria, as well as the variable methods employed by individual studies, some of the standard RV echocardiographic indices were not incorporated into the meta-analysis. Future work in this area should consider standardizing echocardiographic methods for assessment of structure and function. The model of this study does not support a sensitivity or specificity analysis; this would be a sensible next step with our proposed cut-off data.

We are now aware that ARVC is not just a disease of the RV. Recent studies have highlighted the gross and cellular impact on LV myocardial tissue (3, 21, 25, 45). Future work should continue to establish the extent and magnitude of LV involvement in ARVC and whether this can act as an important diagnostic or prognostic indicator.

STE offers the potential to provide regional peak and time-to-peak ϵ data of RV wall segments. However, few studies have attempted to incorporate this into their outcomes (3, 4, 14, 34, 46). Data for all RV wall segments (i.e. basal and apical) as well as the temporal relationship between RV structure and function could provide additional diagnostic value. At this stage, it is important to note that although most of the studies reviewed utilized GE systems to acquire and analyse STE some studies did use other manufacturers. The presence of inter-vendor variability has been previously documented (47). It is clear that further work is required to develop

consistent and valid RV ϵ data across platforms as well as further elucidating normality.

Conclusion

The data from this meta-analysis support task force criteria for the diagnosis of ARVC. In addition, the inclusion of other measures of RV structure that better reflect the complex geometry may provide diagnostic value. Specifically, the application of TDI and myocardial ϵ in combination with RVFAC and TAPSE may also provide additional value in this setting. We recommend that future working groups consider this data when proposing new/revised criteria for the echocardiographic diagnosis of ARVC.

Declaration of interest

The authors declare that there is no conflict of interest that could be perceived as prejudicing the impartiality of the research reported.

Funding

This research did not receive any specific grant from any funding agency in the public, commercial or not-for-profit sector.

Acknowledgements

We thank Liverpool John Moores University and British Society of Echocardiography for their support with this study.

References

- 1 Astrom Aneq M, Engvall J, Brudin L & Nylander E 2012 Evaluation of right and left ventricular function using speckle tracking echocardiography in patients with arrhythmogenic right ventricular cardiomyopathy and their first degree relatives. *Cardiovascular Ultrasound* **10** 37–45. (doi:10.1186/1476-7120-10-37)
- 2 Romero J, Mejia-Lopez E, Manrique C & Lucariello R 2013 Arrhythmogenic right ventricular cardiomyopathy (ARVC/D): a systematic literature review. *Clinical Medicine Insights: Cardiology* **7** 97–114. (doi:10.4137/CMC.S10940)
- 3 Vitarelli A, Cortes Morichetti M, Capotosto L, Cicco VD, Ricci S, Caranci F & Vitarelli M 2013 Utility of strain echocardiography at rest and after stress testing in arrhythmogenic right ventricular dysplasia. *American Journal of Cardiology* **111** 1344–1350. (doi:10.1016/j.amjcard.2013.01.279)
- 4 Tops LF, Prakasa K, Tandri H, Dalal D, Jain R, Dimaano VL, Dombroski D, James C, Tichnell C, Daly A, *et al.* 2009 Prevalence and pathophysiologic attributes of ventricular dyssynchrony in arrhythmogenic right ventricular dysplasia/cardiomyopathy. *Journal of the American College of Cardiology* **54** 445–451. (doi:10.1016/j.jacc.2009.04.038)
- 5 Gemayel C, Pelliccia A & Thompson PD 2001 Arrhythmogenic right ventricular cardiomyopathy. *Journal of the American College of Cardiology* **38** 1773–1781. (doi:10.1016/S0735-1097(01)01654-0)
- 6 Corrado D & Thiene G 2006 Arrhythmogenic right ventricular cardiomyopathy/dysplasia: clinical impact of molecular genetic studies. *Circulation* **113** 1634–1637. (doi:10.1161/CIRCULATIONAHA.105.616490)
- 7 Sorrell VL, Kumar S & Kalra N 2009 Cardiac imaging in right ventricular cardiomyopathy/dysplasia--how does cardiac imaging assist in understanding the morphologic, functional, and electrical changes of the heart in this disease? *Journal of Electrocardiology* **42** 137.e1–137.e10 (doi:10.1016/j.jelectrocard.2008.12.019)
- 8 McKenna WJ, Thiene G, Nava A, Fontaliran F, Blomstrom-Lundqvist C, Fontaine G & Camerini F 1994 Diagnosis of arrhythmogenic right ventricular dysplasia/cardiomyopathy. Task Force of the Working Group Myocardial and Pericardial Disease of the European Society of Cardiology and of the Scientific Council on Cardiomyopathies of the International Society. *British Heart Journal* **71** 215–218. (doi:10.1136/hrt.71.3.215)
- 9 Marcus FI, McKenna WJ, Sherrill D, Basso C, Bauce B, Bluemke DA, Calkins H, Corrado D, Cox M, Daubert JP, *et al.* 2010 Diagnosis of arrhythmogenic right ventricular cardiomyopathy/dysplasia: proposed modification of the task force criteria. *Circulation* **121** 1533–1541. (doi:10.1161/circulationaha.108.840827)
- 10 Zaidi A, Sheikh N, Jongman JK, Gati S, Panoulas VF, Carr-White G, Papadakis M, Sharma R, Behr ER, Sharma S, *et al.* 2015 Clinical differentiation between physiological remodeling and arrhythmogenic right ventricular cardiomyopathy in athletes with marked electrocardiographic repolarization anomalies. *Journal of the American College of Cardiology* **65** 2702–2711. (doi:10.1016/j.jacc.2015.04.035)
- 11 Moen CA, Salminen P-R, Grong K & Matre K 2011 Left ventricular strain, rotation, and torsion as markers of acute myocardial ischemia. *American Journal of Physiology: Heart and Circulatory Physiology* **300** H2142–H2154. (doi:10.1152/ajpheart.01012.2010)
- 12 Bansal M & Kasliwal RR 2013 How do i do it? Speckle-tracking echocardiography. *Indian Heart Journal* **65** 117–123. (doi:10.1016/j.ihj.2012.12.004)
- 13 Lindström L, Wilkenshoff UM, Larsson H & Wranne B 2001 Echocardiographic assessment of arrhythmogenic right ventricular cardiomyopathy. *Heart* **86** 31–38. (doi:10.1136/heart.86.1.31)
- 14 Wang J, Prakasa K, Bomma C, Tandri H, Dalal D, James C, Tichnell C, Corretti M, Bluemke D, Calkins H, *et al.* 2007 Comparison of novel echocardiographic parameters of right ventricular function with ejection fraction by cardiac magnetic resonance. *Journal of the American Society of Echocardiography* **20** 1058–1064. (doi:10.1016/j.echo.2007.01.038)
- 15 Iacoviello M, Forleo C, Puzzovivo A, Nalin I, Guida P, Anaclerio M, Marangelli V, Sorrentino S, Monitillo F, Ciccone MM, *et al.* 2011 Altered two-dimensional strain measures of the right ventricle in patients with Brugada syndrome and arrhythmogenic right ventricular dysplasia/cardiomyopathy. *European Journal of Echocardiography* **12** 773–781. (doi:10.1093/ejehocardiography/erj139)
- 16 Rudski LG, Lai WW, Afilalo J, Hua L, Handschumacher MD, Chandrasekaran K, Solomon SD, Louie EK & Schiller NB 2010 Guidelines for the echocardiographic assessment of the right heart in adults: a report from the American Society of Echocardiography endorsed by the European Association of Echocardiography, a registered branch of the European Society of Cardiology, and the Canadian Society of Echocardiography. *Journal of the American Society of Echocardiography* **23** 685–713. (doi:10.1016/j.echo.2010.05.010)
- 17 Moher D, Liberati A, Tetzlaff J, Altman DG & Altman G 2009 Preferred reporting items for systematic reviews and meta-analyses: the PRISMA statement all use subject to JSTOR terms and conditions REPORTING items preferred for systematic reviews reporting

- meta-analyses: the PRISMA statement. *British Medical Journal* **339** 332–336. (doi:10.1136/bmj.b253)
- 18 Von Elm E, Altman DG, Egger M, Pocock SJ, Gøtzsche PC & Vandenbroucke JP 2014 The strengthening the reporting of observational studies in epidemiology (STROBE) statement: guidelines for reporting observational studies. *International Journal of Surgery* **12** 1495–1499. (doi:10.1016/j.ijsu.2014.07.013)
 - 19 Higgins JPT & Thompson SG 2002 Quantifying heterogeneity in a meta-analysis. *Statistics in Medicine* **21** 1539–1558. (doi:10.1002/sim.1186)
 - 20 Plana JC, Galderisi M, Barac A, Ewer MS, Ky B, Scherrer-Crosbie M, Ganame J, Sebag IA, Agler DA, Badano LP, *et al.* 2014 Expert consensus for multimodality imaging evaluation of adult patients during and after cancer therapy: a report from the American Society of Echocardiography and the European Association of Cardiovascular Imaging. *Journal of the American Society of Echocardiography* **27** 911–939. (doi:10.1016/j.echo.2014.07.012)
 - 21 Sen-Chowdhry S, Syrris P, Prasad SK, Hughes SE, Merrifield R, Ward D, Pennell DJ & McKenna WJ 2008 Left-dominant arrhythmogenic cardiomyopathy: an under-recognized clinical entity. *Journal of the American College of Cardiology* **52** 2175–2187. (doi:10.1016/j.jacc.2008.09.019)
 - 22 Marcus FI, Zareba W, Calkins H, Towbin JA, Basso C, Bluemke DA, Mark Estes NA III, Picard MH, Sanborn D, Thiene G, *et al.* 2009 Arrhythmogenic right ventricular cardiomyopathy/dysplasia clinical presentation and diagnostic evaluation: results from the North American Multidisciplinary Study. *Heart Rhythm* **6** 984–992. (doi:10.1016/j.hrthm.2009.03.013)
 - 23 Pamuru PR, Dokuparthi MVN, Remersu S, Calambur N & Nallari P 2010 Comparison of Uhl's anomaly, right ventricular outflow tract ventricular tachycardia (RVOT VT) & arrhythmogenic right ventricular dysplasia/cardiomyopathy (ARVD/C) with an insight into genetics of ARVD/C. *Indian Journal of Medical Research* **131** 35–45.
 - 24 Pinamonti B 2014 Arrhythmogenic right ventricular cardiomyopathy: from genetics to diagnostic and therapeutic challenges. *World Journal of Cardiology* **6** 1234. (doi:10.4330/wjc.v6.i12.1234)
 - 25 Åström Aneq M 2011 *Arrhythmogenic Right Ventricular Cardiomyopathy: Is It Right?* Linköping University Medical dissertations no. 1257.
 - 26 Te Riele ASJM, James CA, Philips B, Rastegar N, Bhonsale A, Groeneweg JA, Murray B, Tichnell C, Judge DP, Cramer MJM, *et al.* 2013 Mutation positive arrhythmogenic right ventricular dysplasia/cardiomyopathy: the triangle of dysplasia displaced. *Journal of Cardiovascular Electrophysiology* **24** 1311–1320. (doi:10.1111/jce.12222)
 - 27 Basso C, Thiene G, Corrado D, Angelini A, Nava A & Valente M 1996 Arrhythmogenic right ventricular cardiomyopathy dysplasia, dystrophy, or myocarditis? *Circulation* **94** 983–991. (doi:10.1161/01.cir.94.5.983)
 - 28 Conti G, Cipolletta L, Marino V, Zucchetti M, Russo E, Pizzamiglio F, Al-Mohani G, Pala S, Catto V, Biase LD, *et al.* 2015 Right ventricular outflow tract arrhythmias: benign or early stage arrhythmogenic right ventricular cardiomyopathy/dysplasia? *Journal of Atrial Fibrillation* **7** 75–84.
 - 29 Hoffmann R, Lethen H, Marwick T, Arnese M, Fioretti P, Pingitore A, Picano E, Buck T, Erbel R, Flachskampf, *et al.* 1996 Analysis of interinstitutional observer agreement in interpretation of dobutamine stress echocardiograms. *Journal of the American College of Cardiology* **27** 330–336. (doi:10.1016/0735-1097(95)00483-1)
 - 30 Abraham TP, Dimaano VL & Liang H-Y 2007 Role of tissue Doppler and strain echocardiography in current clinical practice. *Circulation* **116** 2597–2609. (doi:10.1161/circulationaha.106.647172)
 - 31 Haddad F, Hunt SA, Rosenthal DN & Murphy DJ 2008 Right ventricular function in cardiovascular disease, part I: anatomy, physiology, aging, and functional assessment of the right ventricle. *Circulation* **117** 1436–1448. (doi:10.1161/circulationaha.107.653576)
 - 32 Voelkel NF, Quaife RA, Leinwand LA, Barst RJ, McGoon MD, Meldrum DR, Dupuis J, Long CS, Rubin LJ, Smart FW, *et al.* 2006 Right ventricular function and failure: report of a National Heart, Lung, and Blood Institute Working Group on cellular and molecular mechanisms of right heart failure. *Circulation* **114** 1883–1891. (doi:10.1161/circulationaha.106.632208)
 - 33 Greiner S, Heimisch M, Aurich M, Heß J-A & Katus H & Meres D 2014 Multiplane two-dimensional strain echocardiography for segmental analysis of right ventricular mechanics. *Clinical Research in Cardiology* **103** 817–824. (doi:10.1007/s00392-014-0723-1)
 - 34 Teske AJ, Cox MG, De Boeck BW, Doevendans PA, Hauer RN & Cramer MJ 2009 Echocardiographic tissue deformation imaging quantifies abnormal regional right ventricular function in arrhythmogenic right ventricular dysplasia/cardiomyopathy. *Journal of the American Society of Echocardiography* **22** 920–927. (doi:10.1016/j.echo.2009.05.014)
 - 35 Kjaergaard J, Snyder EM, Hassager C, Oh JK & Johnson BD 2006 Impact of preload and afterload on global and regional right ventricular function and pressure: a quantitative echocardiography study. *Journal of the American Society of Echocardiography* **19** 515–521. (doi:10.1016/j.echo.2005.12.021)
 - 36 Aneq MÅ, Lindström L, Fluor C & Nylander E 2008 Long-term follow-up in arrhythmogenic right ventricular cardiomyopathy using tissue Doppler imaging. *Scandinavian Cardiovascular Journal* **42** 368–374. (doi:10.1080/14017430802372384)
 - 37 Dalen H, Thorstensen A, Aase SA, Ingul CB, Torp H, Vatten LJ & Stoylen A 2010 Segmental and global longitudinal strain and strain rate based on echocardiography of 1266 healthy individuals: the HUNT study in Norway. *European Journal of Echocardiography* **11** 176–183. (doi:10.1093/ejehocardi/jep194)
 - 38 Baucé B, Frigo G, Benini G, Michieli P, Basso C, Folino AF, Rigato I, Mazzotti E, Daliento L, Thiene G, *et al.* 2010 Differences and similarities between arrhythmogenic right ventricular cardiomyopathy and athlete's heart adaptations. *British Journal of Sports Medicine* **44** 148–154. (doi:10.1136/bjism.2007.042853)
 - 39 Focardi M, Cameli M, Carbone SF, Massoni A, De Vito R, Lisi M & Mondillo S 2014 Traditional and innovative echocardiographic parameters for the analysis of right ventricular performance in comparison with cardiac magnetic resonance. *Imaging European Heart Journal: Cardiovascular Imaging* **16** 47–52. (doi:10.1093/ehjci/jeu156)
 - 40 Yoerger DM, Marcus F, Sherrill D, Calkins H, Towbin JA, Zareba W & Picard MH 2005 Echocardiographic findings in patients meeting task force criteria for arrhythmogenic right ventricular dysplasia: new insights from the multidisciplinary study of right ventricular dysplasia. *Journal of the American College of Cardiology* **45** 860–865. (doi:10.1016/j.jacc.2004.10.070)
 - 41 Sarvari SI, Haugaa KH, Anfinsen O, Leren TP, Smiseth OA, Kongsgaard E, Amlie JP & Edvardsen T 2011 Right ventricular mechanical dispersion is related to malignant arrhythmias: a study of patients with arrhythmogenic right ventricular cardiomyopathy and subclinical right ventricular dysfunction. *European Heart Journal* **32** 1089–1096. (doi:10.1093/eurheartj/ehr069)
 - 42 Ellinor PT, MacRae CA & Thierfelder L 2010 Arrhythmogenic right ventricular cardiomyopathy. *Heart Failure Clinics* **6** 161–177. (doi:10.1016/j.hfc.2009.12.003)
 - 43 Protonotarios N, Anastasakis A, Antoniadis L, Chlouverakis G, Syrris P, Basso C, Asimaki A, Theopistou A, Stefanadis C, Thiene G, *et al.* 2011 Arrhythmogenic right ventricular cardiomyopathy/dysplasia on the basis of the revised diagnostic criteria in affected families with desmosomal mutations. *European Heart Journal* **32** 1097–1104. (doi:10.1093/eurheartj/ehr043)

- 44 Teske AJ, Cox MGPJ & Riele ASJM 2012 Early detection of regional functional abnormalities in asymptomatic ARVD/Cg gene carriers. *Journal of the American Society of Echocardiography* **25** 997–1006. (doi:10.1016/j.echo.2012.05.008)
- 45 Coats CJ, Quarta G, Flett AS, Pantazis AA, McKenna WJ & Moon JC 2009 Arrhythmogenic left ventricular cardiomyopathy. *Circulation* **120** 2613–2614. (doi:10.1161/CIRCULATIONAHA.109.874628)
- 46 Prakasa KR, Wang J, Tandri H, Dalal D, Bomma C, Chojnowski R, James C, Tichnell C, Russell S, Judge D, *et al.* 2007 Utility of tissue Doppler and strain echocardiography in arrhythmogenic right ventricular dysplasia/cardiomyopathy. *American Journal of Cardiology* **100** 507–512. (doi:10.1016/j.amjcard.2007.03.053)
- 47 Koopman LP, Slorach C, Hui W, Manlhiot C, McCrindle BW, Friedberg MK, Jaeggi ET & Mertens L 2010 Comparison between different speckle tracking and color tissue Doppler techniques to measure global and regional myocardial deformation in children. *Journal of the American Society of Echocardiography* **23** 919–928. (doi:10.1016/j.echo.2010.06.014)

Received in final form 27 September 2016

Accepted 29 September 2016

Accepted Preprint published online 29 September 2016