

CASE REPORT

A male with multiple cardiac masses

Manasawee Indrabhinduwat MD^{1,2}, Maria C Arciniegas Calle MD¹, Joseph P Colgan MD¹ and Hector R Villarraga MD¹

¹Cardiovascular Diseases Department, Mayo Clinic, Rochester, Minnesota, USA

²Bhumibol Adulyadej Hospital, Bangkok, Thailand

Correspondence should be addressed to H R Villarraga: villarraga.hector@mayo.edu

Summary

Thirty-seven-year-old male presented with cough, dyspnea, significant weight loss (20 kg) and subacute fever for the past 2 months. Physical examination revealed inspiratory and expiratory wheezing bilaterally. A normal S1, S2 and a 3/6 systolic ejection murmur at the left upper parasternal border with respiratory variation were found during cardiac auscultation. Kidney and bone marrow biopsy reported a high-grade B-cell lymphoma. Echocardiography and cardiac CT findings consisted of multiple intracardiac masses affecting the right ventricular (RV) outflow track, RV apex, medial portion of the right atrium and posterior left atrium, as well as mild impairment of the RV systolic function. The masses in the RV outflow track caused partial obstruction (pulmonary valve peak velocity 2.3 m/s) with a RV systolic pressure of 43 mmHg. The infiltrative mass in the interatrial septum extended into both the right and left atrial cavities. The right superior pulmonary vein was occluded. This patient was treated with aggressive chemotherapy and had a good clinical response that resulted in mass size reduction after the first course of chemotherapy. Multimodality imaging techniques such as echocardiography, cardiac CT and PET scan can provide complementary information to better evaluate, stage and manage these patients.

Key Words

- ▶ 2D echocardiography
- ▶ cardiac mass
- ▶ right ventricular mass
- ▶ cancer
- ▶ pulmonary vein

Learning points:

- Lymphoma can be found as a primary tumor in cardiac tissue, but secondary cardiac lymphoma is far more common.
- Appropriate investigation, histopathology, immunophenotype, staging and risk assessment are required for definite diagnosis and treatment.
- Cardiac lymphoma frequently manifests as an ill-defined, infiltrative mass. Typical location is in the atrium (right atrium is the most common site). Pericardial thickening or effusion is also common.
- Echocardiography is a quick, bedside, non-invasive assessment of anatomical involvement and hemodynamics affected by cardiac lymphoma. Echocardiographic findings of cardiac lymphoma include a hypoechoic, ill-defined infiltrative masses in the myocardium, nodular protrusion into cardiac chambers and pericardial effusion. Obstruction of inflow/outflow track can also be found.
- If a diagnosis of cardiac lymphoma is made, the most effective treatment is chemotherapy. Surgical treatment may have a role when hemodynamic compromise does not respond to chemotherapy and radiotherapy.

Background

Cardiac lymphoma can be primary or secondary. Primary cardiac lymphoma is rare and comprises 0.5% of all extranodal lymphomas while secondary cardiac lymphoma is more common. Echocardiography is an important tool in detecting cardiac involvement. In this case report, we present a case of secondary cardiac lymphoma with multiple cardiac masses complicated by partial right ventricular (RV) outflow track and right upper pulmonary vein obstruction.

Case presentation

A 37-year-old male presented to his primary care provider with subacute fever, cough, dyspnea and significant weight loss for the past 2 months. Physical examination revealed inspiratory and expiratory wheezing from both lungs. Cardiac auscultation showed normal S1, S2 and a 3/6 systolic ejection murmur at the left upper parasternal border with respiratory variation. No edema of extremities was noted.

Due to his worsening symptoms, a CT was performed, which demonstrated a large mediastinal mass and bilateral renal masses. Kidney and bone marrow biopsy showed a high-grade B-cell lymphoma.

Investigation

EKG showed a HR of 75 beats/min and a sinus rhythm with first-degree AV block, markedly abnormal T waves in lead I, aVL, V1 and V2 (Fig. 1). Laboratory findings were unremarkable. CBC, creatinine and liver function were within normal limits. HIV and hepatitis B and C were all negative.

Echocardiography showed multiple intracardiac masses affecting the RV outflow track, RV apex, medial portion of the right atrium and posterior left atrium, as well as mild impairment of the RV systolic function. The masses in the right ventricular outflow track caused partial obstruction (PV peak velocity 2.3 m/s) with a right ventricular systolic pressure of 43 mmHg. The mass in the left atrium was obstructing the flow from the right upper pulmonary vein. LVEF was estimated to be 60% (Fig. 2).

Cardiac CT showed multiple cardiac masses. The mass in the RV apex measured approximately $4.1 \times 4.4 \times 4.7$ cm. Adjacent masses involved the entire anterior wall, superior portion of the LV apex, mid-apical lateral wall and pericardium. The free wall of the right ventricle was also involved with multiple lobulated masses encroaching the RV outflow tract with resultant luminal narrowing. There was also an infiltrative mass in the interatrial septum extending into both the right and left atrial cavities and extending superiorly along

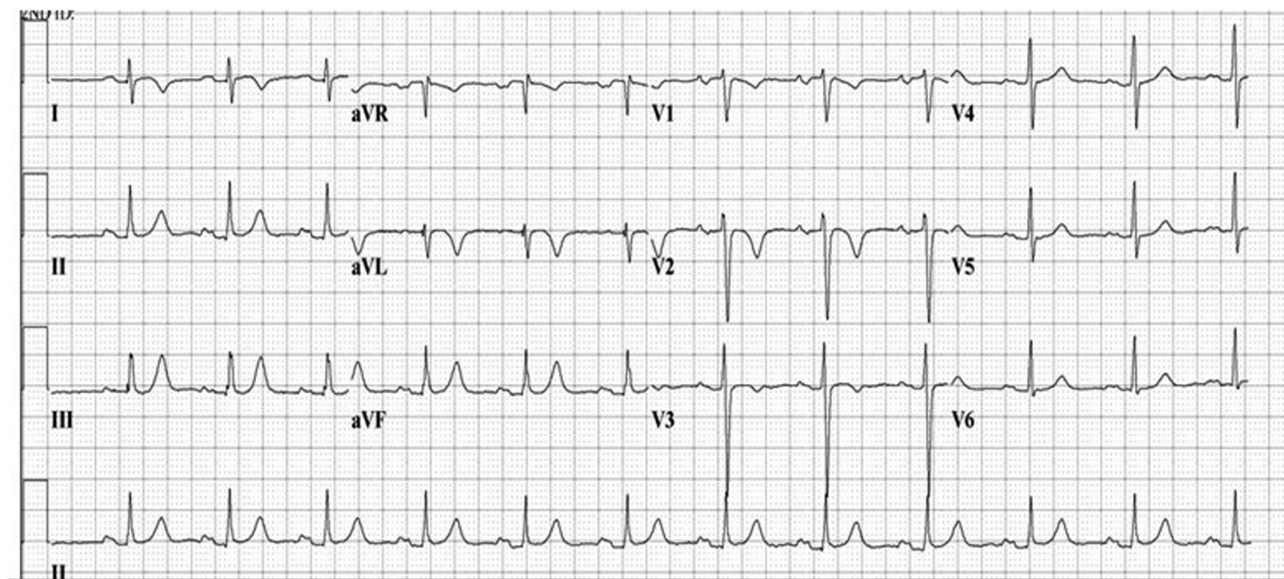


Figure 1

EKG showing a HR 75 beats/min, sinus rhythm with first degree AV block, markedly abnormal T waves in lead I, aVL, V1 and V2.

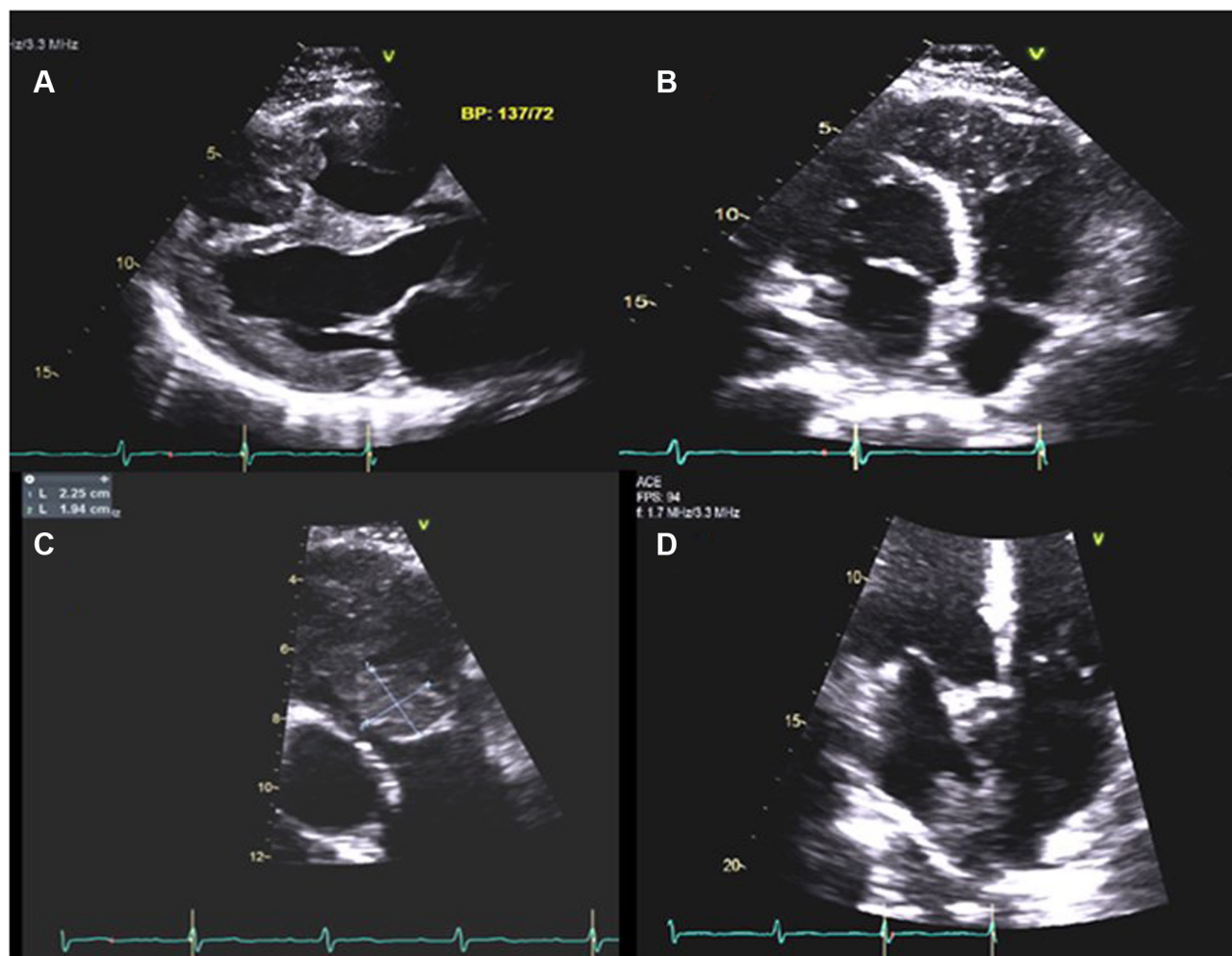


Figure 2

(A and B) Transthoracic echocardiography showing multiple intracardiac masses affecting the interventricular septum and right ventricular apex. (C) Mass measuring 2.25 x 1.94 cm at RVOT causing partial obstruction. (D) Mass in the left atrium obstructing the right upper pulmonary vein.

the superior wall of the left atrium. The right superior pulmonary vein was occluded and the right inferior pulmonary vein was partially encased by tumor (Fig. 3A and B). PET scan showed very extensive, intensely FDG-avid tissue outlining and invading the mediastinum with narrowing of the right bronchus and cardiac structures. Intense FDG uptake in the pancreas and bilateral kidneys was also noticed (Fig. 3C).

The patient was admitted to the ICU for close cardiac monitoring, particularly in the event of RVOT obstruction or arrhythmia. He was diagnosed with high-grade B-cell lymphoma with significant cardiac, renal, pulmonary and pancreatic involvement. Immunophenotypical presence of *BCL2*, *BCL6* and *MYC* (triple-hit lymphoma) was confirmed.

Treatment and outcome

He was treated with aggressive chemotherapy (CODOX-M/IVAC regimen) including rituximab, vincristine, doxorubicin, cyclophosphamide, methotrexate and intrathecal cytarabine for the first course. Echocardiography was performed for reevaluation at 1 week after chemotherapy was started (Fig. 4). At that time point, there had been decrease in size of masses in multiple sites (interatrial septum, RV apex, RV outflow track). The patient was stable, no hypotension, no arrhythmias and adequate oxygen saturation. He was discharged after completing the first course of chemotherapy and continued treatment at a nearby hospital.

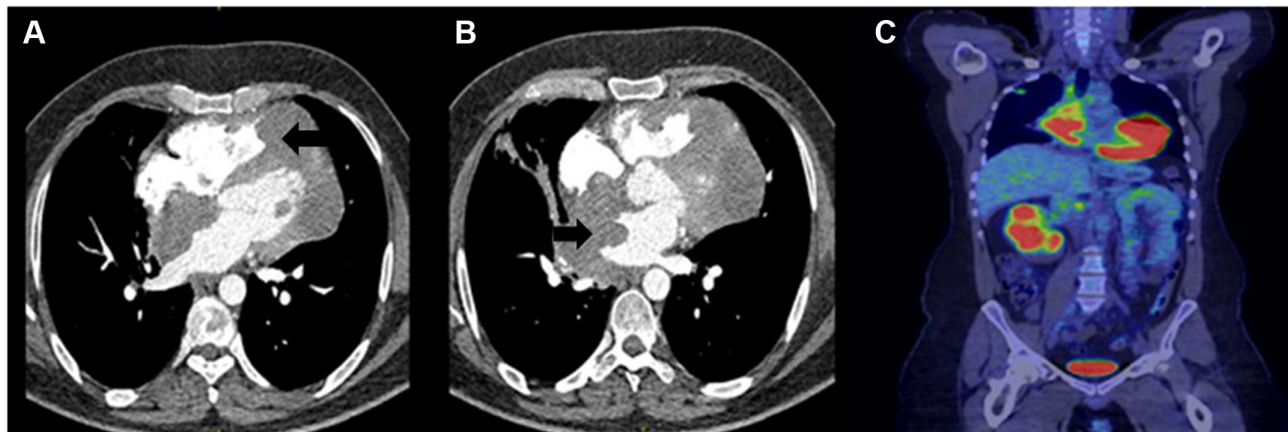


Figure 3

(A) Cardiac CT showing mass in the right ventricular apex measuring approximately 4.1×4.4×4.7 cm (arrow). Adjacent mass involving the entire anterior wall, superior portion of the LV apex, mid-apical lateral wall and pericardium. (B) Cardiac CT showing infiltrative mass in the interatrial septum extending into both the right and left atrial cavities and extending superiorly along the superior wall of the left atrium. The right superior pulmonary vein is occluded (arrow). (C) PET scan showing very extensive, intensely FDG avid tissue at mediastinum and cardiac structures and intense FDG uptake at pancreatic and bilateral renal masses.

Discussion

Lymphoma of the heart and pericardium usually presents as disseminated disease and rarely occurs as a primary malignancy. Secondary cardiac involvement in patients with systemic lymphoma is well documented, with an incidence between 9 and 24% of lymphoma patients (1), commonly B-cell in origin.

Lymphomas affect the heart by three pathways: (1) via direct extension from mediastinal lymphoma, (2) via lymphatic vessels along coronary arteries and epicardium and (3) via hematogenous spread. Cardiac valves do not appear to contain lymphatic vessels, which explain why valvular involvement is rare (2).

Cardiac lymphoma manifests in a variety of ways. Depending on the location of the masses, inflow or outflow tract obstruction can be found such as SVC/IVC obstruction or thrombosis (3). RVOT obstruction can cause right-sided heart failure or hemodynamic instability (4), invasion of the conduction pathways can cause arrhythmias such as atrioventricular blocks ranging from first- to third-degree blocks, infiltration to the myocardium can cause VT and invasion of the pericardium can produce pericardial effusion and tamponade. Finally, tumor embolization (5) or mass encasing a coronary can cause ischemic symptoms (6).

Echocardiography is a quick non-invasive assessment that can aid in identifying masses and flow obstruction. Lymphomatous involvement of the myocardium may appear as ill-defined hypoechoic masses infiltrating the myocardium. They can also appear as homogeneous,

infiltrating masses leading to ‘wall thickening’ and restrictive hemodynamics or as nodular masses intruding into the heart chambers, preferentially the right heart chambers (7). Pericardial thickening and effusion are often seen. Furthermore, echocardiography gives hemodynamic data such as degree of inflow/outflow obstruction, myocardial systolic and diastolic function and tamponade physiology. Left ventricular function and global longitudinal strain can also be utilized for the assessment and follow-up of cancer therapy-related cardiac dysfunction especially in those treated with high-dose doxorubicin.

Cardiac CT in cardiac lymphoma typically shows an ill-defined infiltrative mass in the myocardium. Atrial location is common, particularly in the right atrium, with infiltration of atrial and ventricular walls. Tumor extension along the epicardial surfaces of the heart can be evident as attenuation to hypo-attenuation of the epicardium relative to the myocardium. Heterogeneous enhancement after administration of intravenous contrast can also be found. Pericardial thickening and effusion are also common (8).

Cardiac MRI is the best technique to show the extent of myocardial and pericardial infiltration. It also has high spatial resolution and better tissue characterization than cardiac CT. Masses can be relatively hypointense on T1-weighted images and hyperintense on T2-weighted images. Delayed-enhancement imaging is also used to identify the extent of tumor.

Differential diagnoses include metastatic carcinoma (most common lung and melanoma) and primary cardiac

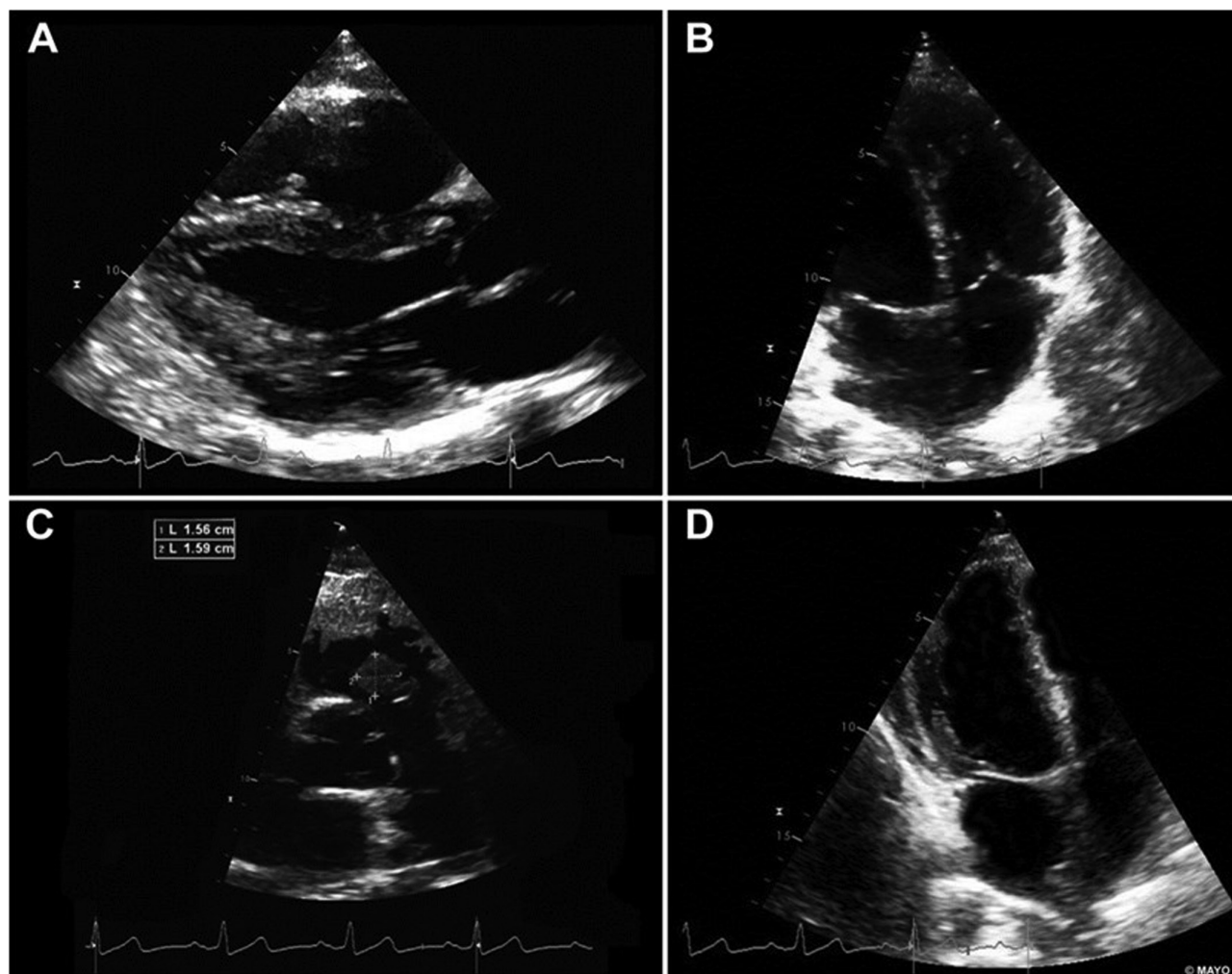


Figure 4

(A, B, C and D) Transthoracic echocardiography after 1 week of chemotherapy. Masses decreased in size.

tumor such as angiosarcoma. However, findings from echocardiography, CT and CMR are non-specific; thus, histopathologic diagnosis is required to confirm diagnosis and begin treatment (9).

The European Society of Medical Oncology (ESMO) Clinical Practice Guidelines 2015 for diagnosis, treatment and follow-up of diffuse large B-cell lymphoma (DLBCL) (10) recommends fluorodeoxyglucose positron emission tomography (FDG-PET)/CT as the gold standard for staging DLBCL patients. PET/CT is more accurate than contrast-enhanced CT with increased sensitivity for nodal and extra nodal sites.

In this case, the patient had multiple extranodal sites and an immunophenotype that showed the concurrent expression of *BCL2*, *BCL6* and *MYC* (triple-hit lymphoma), which is associated with a poor outcome. He was treated with aggressive chemotherapy and follow-up

echocardiography showed reduced tumor size and degree of RVOT obstruction. There are case reports of primary cardiac lymphomas with signs of right-sided obstruction due to huge right atrial masses where the tumor was inoperable and palliative surgery was performed (Fontan's operation) to bypass venous blood from systemic to pulmonary circulation (4).

Declaration of interest

The authors declare that there is no conflict of interest that could be perceived as prejudicing the impartiality of this case report.

Funding

This work did not receive any specific grant from any funding agency in the public, commercial or not-for-profit sector.

Patient consent

Written consent has been obtained from the patient for publication of the submitted article and accompanying images.

Author's contribution statement

M I obtained images and wrote manuscript. M A obtained informed consent, wrote and critically revised manuscript. H V critically revised manuscript. J C was the primary physician overseeing the case.

References

- 1 Petrich A, Cho SI & Billett H. Primary cardiac lymphoma. An analysis of presentation, treatment and outcome patterns. *Cancer* 2011 **117** 581–589. (<https://doi.org/10.1002/cncr.25444>)
- 2 Bradham RR, Parker EF & Greene WB. Lymphatics of the atrioventricular valves. *Archives of Surgery* 1973 **106** 210–213. (<https://doi.org/10.1001/archsurg.1973.01350140068019>)
- 3 Johri A, Baetz T, Isotalo PA, Nolan RL, Sanfilippo AJ & Ropchan G. Primary cardiac diffuse large B cell lymphoma presenting with superior vena cava syndrome. *Canadian Journal of Cardiology* 2009 **25** e210–e212. ([https://doi.org/10.1016/S0828-282X\(09\)70110-2](https://doi.org/10.1016/S0828-282X(09)70110-2))
- 4 Jonavicius K, Salcius K, Meskauskas R, Valeviciene N, Tarutis V & Sirvydis V. Primary cardiac lymphoma: two cases and a review of literature. *Journal of Cardiothoracic Surgery* 2015 **10** 138. (<https://doi.org/10.1186/s13019-015-0348-0>)
- 5 Baztarrica GP, Nieva N, Gariglio L, Salvaggio F & Porcile R. Primary cardiac lymphoma: a rare case of pulmonary tumor embolism. *Circulation* 2010 **121** 2249–2250. (<https://doi.org/10.1161/CIRCULATIONAHA.109.863126>)
- 6 Mahony DO, Piekarz RL, Bandettini WP, Arai AE, Wilson WH & Bates SE. Cardiac involvement with lymphoma: a review of the literature. *Clinical Lymphoma and Myeloma* 2008 **8** 249–252. (<https://doi.org/10.3816/CLM.2008.n.034>)
- 7 Mankad R & Herrmann J. Cardiac tumors: echo assessment. *Echo Research and Practice* 2016 **3** R65–R77. (<https://doi.org/10.1530/ERP-16-0035>)
- 8 Jeudy J, Kirsch J, Tavora F, Burke AP, Franks TJ, Mohammed TL, Frazier AA & Galvin JR. Cardiac lymphoma: radiologic-pathologic correlation. *RadioGraphics* 2012 **32** 1369–1380. (<https://doi.org/10.1148/rg.325115126>)
- 9 Ragland MM, Tak DO & Tak T. The role of echocardiography in diagnosing space-occupying lesions of the heart. *Clinical Medicine and Research* 2006 **4** 22–32.
- 10 Tilly H, da Silva MG, Vitolo U, Jack A, Meignan M, Guillermo AL, Walewski J, André M, Johnson PW, Pfreundschuh M, et al. Diffuse large B-cell lymphoma (DLBCL): ESMO Clinical Practice Guidelines for diagnosis, treatment and follow-up. *Annals of Oncology* 2015 **26** (Supplement 5) v116–v125. (<https://doi.org/10.1093/annonc/mdv304>)

Received in final form 8 June 2018

Accepted 12 June 2018

Accepted Preprint published online 12 June 2018