

RESEARCH

Prevalence of moderate-to-severe TR suitable for percutaneous intervention in TTE patients

Z H Teoh, J Roy, J Reiken, M Papitsas, J Byrne and M J Monaghan

Department of Cardiology, King's College Hospital, London, UK

Correspondence should be addressed to Z H Teoh: zhi.teoh@nhs.net

Abstract

Moderate-to-severe tricuspid regurgitation is associated with higher mortality and morbidity yet remains significantly undertreated. The reasons for this are complex but include a higher operative mortality for patients undergoing isolated tricuspid valve surgery. This study sought to determine the prevalence of patients with moderate-to-severe tricuspid regurgitation and identify those who could be potentially suitable for percutaneous tricuspid valve intervention by screening patients referred for transthoracic echocardiography (ECHO) at a tertiary center. Our results showed that the prevalence of moderate-to-severe tricuspid regurgitation in our total ECHO patient population was 2.8%. Of these, approximately one in eight patients with moderate-to-severe tricuspid regurgitation would be potentially suitable for percutaneous intervention and suggests a large, unmet clinical need in this population.

Key Words

- ▶ tricuspid regurgitation
- ▶ echocardiography
- ▶ valve repair
- ▶ transcatheter

Introduction

It is estimated that tricuspid regurgitation occurs in 8–35% of patients (1) with several studies demonstrating that severe tricuspid regurgitation is associated with higher morbidity and mortality, independent of age or biventricular systolic function (2, 3).

Despite this, current American Heart Association (AHA) and American College of Cardiology (ACC) guideline recommendations give a class I indication for tricuspid valve (TV) repair only for patients undergoing concomitant left-sided valve surgery (4). The 2017 European Society of Cardiology (ESC) and European Association for Cardio-thoracic Surgery (EACTS) guidelines mirror this recommendation, but also support surgery in symptomatic patients with severe isolated primary tricuspid regurgitation without right ventricular dysfunction (5). One of the major reasons for the limited recommendation is the elevated surgical mortality rate

associated with isolated TV surgery, which may be as high as 9.8% (6, 7).

However, percutaneous interventions targeting tricuspid regurgitation have recently begun to emerge. These can broadly be categorized into several categories, namely edge-to-edge coaptation devices, annuloplasty devices, space occupying devices and caval valve implantation devices (8, 9). These have been shown to be safe, to reduce tricuspid regurgitation (TR) and to improve quality of life outcomes. Nonetheless, these have been limited to trials involving a relatively small number of patients (10, 11). Larger scale trials are expected to follow this.

Our team therefore sought to determine the prevalence of patients with moderate-to-severe TR and identify those who could be potentially suitable for percutaneous TV intervention.

Methods

Retrospective cross-sectional study of all patients at King's College Hospital, London referred for TTE between January 1, 2016, and December 31, 2016. Clinical information about the severity of TR was obtained retrospectively from formalized transthoracic ECHO reports of patients. Other ECHO parameters assessed included left ventricular ejection fraction (LVEF), right ventricular systolic pressure (RVSP), presence of aortic valve stenosis or regurgitation, presence of mitral valve stenosis or regurgitation, presence of previous aortic or mitral valve interventions and previous TV replacement or repair.

All ECHO assessments and reports were done independently by British Society of Echocardiography-accredited echocardiographers who were not aware of the study at the time and were performed as part of a routine clinical service. The severity of TR was graded using standard quantitative criteria as specified by European Association of Cardiovascular Imaging (EACVI) and American Society of Echocardiography (ASE) guidelines (12, 13).

A two-step screening process was adopted for this study, based on the ECHO inclusion criteria for percutaneous TV annuloplasty (Trialign) from the SCOUT trial as published by Hahn *et al.* (10). First, patients were screened based on their ECHO report for eligibility for percutaneous TV annuloplasty. This was defined using all of the following criteria: LVEF >35%, RVSPs ≤60 mmHg and the absence of significant aortic or mitral valve regurgitation or stenosis. Significant valve pathology was defined as the presence of ≥moderate valvular regurgitation or stenosis based on EACVI/ASE guidelines.

As tricuspid annular plane systolic excursion (TAPSE) was not specifically reported in a significant number of the ECHO reports, ECHO images for patients who fulfilled all the above criteria were re-assessed retrospectively by an experienced echocardiographer who was blinded to the age, gender and TR severity with the ECHO images fully anonymized for patient identifiable data. ECHO parameters re-assessed included TAPSE, presence of pacemaker leads, etiology of TR, vena contracta, tricuspid annulus dimensions, right ventricular dimensions, distance of TV annulus plane to right ventricular apex and right ventricular fractional area change (RVFAC). It was not possible to re-assess the effective regurgitant orifice area (EROA) in a significant number of patients due to insufficient image quality. As per the SCOUT trial ECHO exclusion criteria, the study excluded patients with previous tricuspid replacement or repair, pacemaker leads

or primary TR. Only patients over the age of 18 years were included in the study.

The initial retrospective analysis and screening for patients with moderate-to-severe TR was registered and approved by the King's College Hospital quality improvement and audit committee. Subsequently, analysis and reassessment of the ECHO images were performed with the data fully anonymized and therefore did not require further ethical committee approval and was discussed with the audit.

Results

Overall, 12 000 patients were referred for Transthoracic Echo between January 1, 2016, and December 31, 2016, at King's College Hospital, London. Three hundred thirty-eight patients were reported as having at least moderate TR.

Their baseline demographics are shown in Table 1. The mean age was 74±14.4 years and 60.4% were women. Thirty-two (9.5%) patients had previous mitral valve intervention, 33 (9.8%) had previous aortic valve intervention and 6 (1.8%) had both previous aortic and mitral valve intervention.

Therefore, the prevalence of moderate-to-severe TR within the Echo referral patient population at King's College Hospital, London was 2.8%.

As illustrated in Fig. 1, based on their ECHO report, 126 (37.3%) patients with moderate-to-severe TR had

Table 1 Baseline demographics of the 338 patients with moderate-to-severe tricuspid regurgitation.

Age (years)	74 (±14.4)
Female (%)	204/338 (60.4)
Prior myocardial infarction (%)	66/338 (19.5)
Prior PCI (%)	52/338 (15.4)
Prior CABG (%)	45/338 (13.3)
Hypertension (%)	231/338 (68.3)
Hyperlipidemia (%)	194/338 (57.4)
History of pulmonary hypertension (%)	49/338 (14.5)
Diabetes (%)	87/338 (25.7)
Chronic renal disease* (%)	146/319 (45.8)
Peripheral vascular disease (%)	31/338 (9.2)
Cerebrovascular disease (%)	54/338 (16.0)
Atrial fibrillation (%)	221/338 (65.4)
Prior valve intervention (%)	
Mitral valve only	32/338 (9.5)
Aortic valve only	33/338 (9.8)
Mitral and aortic valve	6/338 (1.8)

Values are mean ± s.d.

*Renal function n/a for 19 patients.

CABG, coronary artery bypass graft; PCI, percutaneous coronary intervention.

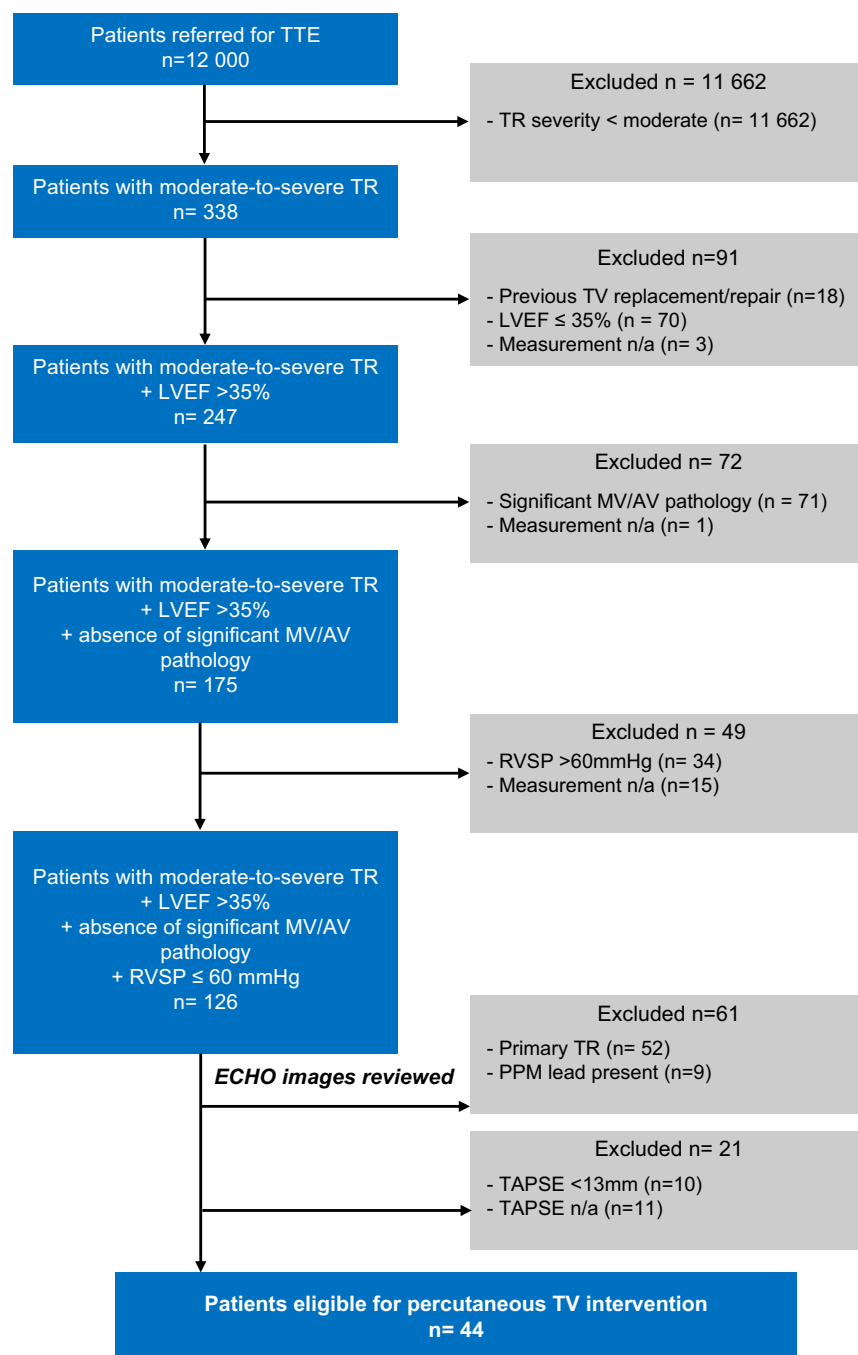


Figure 1
Flow chart of patients with moderate-to-severe
TR suitable for percutaneous TV intervention.

LVEF >35%, absence of previous significant mitral or aortic valve pathology and RVSP ≤60 mmHg.

Subsequent further reassessment of their ECHO images revealed that 44/338 (13%) or approximately one in eight patients would be potentially eligible for percutaneous TV intervention based on their ECHO parameters. Other ECHO parameters are presented in Table 2.

Discussion

Severe TR is independently associated with worsening morbidity and mortality outcomes (2, 3). Despite this, the indications for isolated TV surgery are limited to those patients undergoing concomitant left-sided valve surgery or those with isolated TR with right ventricular

Table 2 Echocardiographic parameters of the 44 patients suitable for percutaneous tricuspid valve intervention.

Tricuspid annular plane systolic excursion (TAPSE) (cm)	1.88±0.47
TR vena contracta (cm)	0.69±0.17
TV annular diameter (cm)	3.87±0.71
RV diameter (cm)	3.33±0.63
Distance from TV annulus plan to RV apex (cm)	7.03±0.94
RVFAC (%)	37.05±10.95

Values are mean±s.d.

LVEF, left ventricular ejection fraction; RV, right ventricle; RVFAC, right ventricular fractional area change; RVSP, right ventricular systolic pressure; TR, tricuspid regurgitation; TV, tricuspid valve.

dysfunction. With these conservative guidelines, only a proportion of this subgroup of patients will undergo TV surgery, principally because of the increased mortality rates in this cohort. As a result, TR remains significantly undertreated; estimated to be <0.5% of patient population in the United States (14).

The advent of less-invasive percutaneous interventions targeting the TV could potentially address this – a large, currently unmet clinical need. Many of these techniques are based upon proven surgical techniques, but to date have only been studied in small feasibility trials (9, 10, 11, 15, 16, 17, 18).

The number of patients who would be potentially eligible or benefit from these percutaneous interventions is still unknown. Based upon the ECHO eligibility criteria for percutaneous TV annuloplasty, as described by Hahn *et al.* (10), this study aimed to quantify the prevalence of this particular group within our TTE referral patient population; recognizing that this will underestimate the prevalence of this pathology in the general population.

Approximately one in eight patients with moderate-to-severe TR would be potentially eligible for percutaneous TV annuloplasty based on their echocardiographic parameters.

Study limitations

However, there remain certain limitations to this retrospective study. The echocardiographers were not aware that patients were being screened for potential percutaneous intervention and did not perform tricuspid-specific ECHO views. Therefore, in a few cases, certain ECHO parameters crucial for determining eligibility were missing from their reports.

More importantly, the reports did not differentiate between primary or secondary TR. Currently, percutaneous tricuspid intervention is only available to patients with secondary TR.

In order to mitigate against this, a two-step analysis process was designed for this study. In the first step, patients were identified based on ECHO parameters (LVEF, mitral/aortic pathology and RVSP) already reported on their ECHO. In the second step, patients still deemed eligible had their ECHO images re-analyzed for further ECHO parameters including etiology of TR, TAPSE and so on as outlined in the ‘Methods’ section.

However, the lack of dedicated tricuspid-specific ECHO views meant that certain ECHO criteria still could not be measured due to image quality. This included tricuspid EROA, which would require 3D ECHO for precise analysis.

Furthermore, RVSP was assessed by measuring the TR jet maximum velocity and right atrial pressure via the collapsibility index. In patients with severe TR, this could theoretically underestimate the RVSP. However, the use of more accurate measurement techniques, for example right heart catheterization to screen patients would not be possible, be it for practical or ethical reasons in this cohort; neither was it utilized in the initial percutaneous TV annuloplasty feasibility study as described by Hahn *et al.* (10), which this study was based upon.

Conclusion

In summary, moderate-to-severe TR is associated with significant poor outcomes, but remains undertreated for complex reasons, including concerns around increased operative risk. Percutaneous interventions which target the TV have the potential to address this large, unmet clinical need. Our study demonstrates that approximately one in eight patients with moderate-to-severe TR would potentially be eligible for percutaneous intervention.

Declaration of interest

The authors declare that there is no conflict of interest that could be perceived as prejudicing the impartiality of the research reported.

Funding

This research did not receive any specific grant from any funding agency in the public, commercial or not-for-profit sector.

References

- Antunes MJ & Barlow JB. Management of tricuspid valve regurgitation. *Heart* 2007 **93** 271–276. (<https://doi.org/10.1136/hrt.2006.095281>)
- Nath J, Foster E & Heidenreich PA. Impact of tricuspid regurgitation on long-term survival. *Journal of the American College of Cardiology* 2004 **43** 405–409. (<https://doi.org/10.1016/j.jacc.2003.09.036>)
- Topilsky Y, Nkomo VT, Vatury O, Michelena HI, Letourneau T, Suri RM, Pislaru S, Park S, Mahoney DW & Biner S. Clinical outcome of isolated tricuspid regurgitation. *JACC: Cardiovascular Imaging* 2014 **7** 1185–1194. (<https://doi.org/10.1016/j.jcmg.2014.07.018>)
- Nishimura RA, Otto CM, Bonow RO, Carabello BA, Erwin JP 3rd, Guyton RA, O'Gara PT, Ruiz CE, Skubas NJ & Sorajja P. 2014 AHA/ACC guideline for the management of patients with valvular heart disease: executive summary: a report of the American College of Cardiology/American Heart Association Task Force on Practice Guidelines. *Journal of the American College of Cardiology* 2014 **63** 2438–2488. (<https://doi.org/10.1016/j.jacc.2014.02.537>)
- Falk V, Baumgartner H, Bax JJ, De Bonis M, Hamm C, Holm PJ, Iung B, Lancellotti P, Lansac E & Muñoz DR. 2017 ESC/EACTS guidelines for the management of valvular heart disease. *European Journal of Cardio-Thoracic Surgery* 2017 **52** 616–664. (<https://doi.org/10.1093/ejcts/ezx324>)
- Kim YJ, Kwon DA, Kim HK, Park JS, Hahn S, Kim KH, Kim KB, Sohn DW, Ahn H, Oh BH, *et al.* Determinants of surgical outcome in patients with isolated tricuspid regurgitation. *Circulation* 2009 **120** 1672–1678. (<https://doi.org/10.1161/CIRCULATIONAHA.109.849448>)
- Vassileva CM, Shabosky J, Boley T, Markwell S & Hazelrigg S. Tricuspid valve surgery: the past 10 years from the Nationwide Inpatient Sample (NIS) database. *Journal of Thoracic and Cardiovascular Surgery* 2012 **143** 1043–1049. (<https://doi.org/10.1016/j.jtcvs.2011.07.004>)
- Rodés-Cabau J, Hahn RT, Latib A, Laule M, Lauten A, Maisano F, Schofer J, Campelo-Parada F, Puri R & Vahanian A. Transcatheter therapies for treating tricuspid regurgitation. *Journal of the American College of Cardiology* 2016 **67** 1829–1845. (<https://doi.org/10.1016/j.jacc.2016.01.063>)
- Nickenig G, Kowalski M, Hausleiter J, Braun D, Schofer J, Yzeiraj E, Rudolph V, Friedrichs K, Maisano F, Taramasso M, *et al.* Transcatheter treatment of severe tricuspid regurgitation with the edge-to-edge mitraclip technique *Circulation* 2017 **135** 1802–1814. (<https://doi.org/10.1161/CIRCULATIONAHA.116.024848>)
- Hahn RT, Meduri CU, Davidson CJ, Lim S, Nazif TM, Ricciardi MJ, Rajagopal V, Ailawadi G, Vannan MA & Thomas JD. Early feasibility study of a transcatheter tricuspid valve annuloplasty: SCOUT trial 30-day results. *Journal of the American College of Cardiology* 2017 **69** 1795–1806. (<https://doi.org/10.1016/j.jacc.2017.01.054>)
- Taramasso M, Pozzoli A, Guidotti A, Nietlispach F, Inderbitzin DT, Benussi S, Alfieri O & Maisano F. Percutaneous tricuspid valve therapies: the new frontier. *European Heart Journal* **38** 2017 639–647. (<https://doi.org/10.1093/eurheartj/ehv766>)
- Lancellotti P, Tribouilloy C, Hagendorff A, Popescu BA, Edvardsen T, Pierard LA, Badano L, Zamorano JL & Scientific Document Committee of the European Association of Cardiovascular Imaging. Recommendations for the echocardiographic assessment of native valvular regurgitation: an executive summary from the European Association of Cardiovascular Imaging. *European Heart Journal: Cardiovascular Imaging* 2013 **14** 611–644. (<https://doi.org/10.1093/ehjci/jet105>)
- Zoghbi WA, Enriquez-Sarano M, Foster E, Grayburn PA, Kraft CD, Levine RA, Nihoyannopoulos P, Otto CM, Quinones MA, Rakowski H, *et al.* American Society of Echocardiography Recommendations for evaluation of the severity of native valvular regurgitation with two-dimensional and Doppler echocardiography. *Journal of the American Society of Echocardiography* 2003 **16** 777–802. ([https://doi.org/10.1016/S0894-7317\(03\)00335-3](https://doi.org/10.1016/S0894-7317(03)00335-3))
- Stuge O & Liddicoat J. Emerging opportunities for cardiac surgeons within structural heart disease. *Journal of Thoracic and Cardiovascular Surgery* 2006 **132** 1258–1261. (<https://doi.org/10.1016/j.jtcvs.2006.08.049>)
- Campelo-Parada F, Perlman G, Philippon F, Ye J, Thompson C, Bédard E, Abdul-Jawad Altisent O, Del Trigo M, Leipsic J, Blanke P, *et al.* First-in-man experience of a novel transcatheter repair system for treating severe tricuspid regurgitation. *Journal of the American College of Cardiology* 2015 **66** 2475–2483. (<https://doi.org/10.1016/j.jacc.2015.09.068>)
- Schofer J, Bijuklic K, Tiburtius C, Hansen L, Groothuis A & Hahn RT. First-in-human transcatheter tricuspid valve repair in a patient with severely regurgitant tricuspid valve. *Journal of the American College of Cardiology* 2015 **65** 1190–1195. (<https://doi.org/10.1016/j.jacc.2015.01.025>)
- Latib A, Agricola E, Pozzoli A, Denti P, Taramasso M, Spagnolo P, Juliard JM, Brochet E, Ou P, Enriquez-Sarano M, *et al.* First-in-man implantation of a tricuspid annular remodeling device for functional tricuspid regurgitation. *JACC: Cardiovascular Interventions* 2015 **8** e211–e214. (<https://doi.org/10.1016/j.jacc.2015.08.534>)
- Laule M, Stangl V, Sanad W, Lembcke A, Baumann G & Stangl K. Percutaneous transfemoral management of severe secondary tricuspid regurgitation with Edwards Sapien XT bioprosthesis: first-in-man experience. *Journal of the American College of Cardiology* 2013 **61** 1929–1931. (<https://doi.org/10.1016/j.jacc.2013.01.070>)

Received in final form 8 October 2018

Accepted 29 October 2018

Accepted Preprint published online 1 November 2018