



# Technology-based assessment in patients with disorders of consciousness

Carol Di Perri<sup>(a)</sup>, Lizette Heine<sup>(b)</sup>, Enrico Amico<sup>(b)</sup>, Andrea Soddu<sup>(c)</sup>, Steven Laureys<sup>(b)</sup>  
and Athena Demertzi<sup>(b)</sup>

<sup>(a)</sup> Istituto Neurologico Nazionale C. Mondino, Neuroradiologia, Pavia, Italy

<sup>(b)</sup> Coma Science Group, Cyclotron Research Center & Neurology Department, University of Liège, Belgium

<sup>(c)</sup> Brain and Mind Institute, Physics and Astronomy Department, Western University, London Ontario, Canada

## Abstract

**Introduction.** A number of studies highlight the difficulty in forming a diagnosis for patients with disorders of consciousness when this is established merely on behavioral assessments.

**Background.** Positron emission tomography (PET), functional magnetic resonance imaging (fMRI), diffusion tensor imaging (DTI), and electroencephalography combined with transcranial magnetic stimulation (TMS-EEG) techniques are promoting the clinical characterization of this challenging population. With such technology-based “objective” tools, patients are also differentially able to follow simple commands and in some cases even communicate through modified brain activity. Consequently, the vegetative state and minimally conscious state have been revised and new nosologies have been proposed, namely the unresponsive wakefulness syndrome, the minimally conscious state plus and minus, and the functional locked-in syndrome.

**Aim.** To our mind, an integration of different technical modalities is important to gain a holistic vision of the underlying pathophysiology of disorders of consciousness in general and to promote single-patient medical management in particular.

## Key words

- disorders of consciousness
- functional neuroimaging
- electroencephalography
- vegetative state/unresponsive wakefulness syndrome
- minimally conscious state

## INTRODUCTION

Disorders of consciousness (DOC) are among the most challenging and poorly understood conditions of modern medical care. These clinical conditions have increasingly appeared in the clinical setting since emergency medicine and lifesaving technologies had been introduced back in the 1950s [1]. Ever since, the advance of such tools contributed to the raising number of patients who survived after sustaining extreme brain damage. At the same time, the introduction of medical imaging in the 1970s, and its rapid development ever since, boosted a deeper understanding of brain function in states of unconsciousness [1, 2]. Here we aim at providing an updated overview of the application and contribution of neuroimaging and electrophysiological techniques for the assessment of patients with DOC. Such technology-based approach seems to be imperative for diagnosing these patients, especially when one considers that standard neurological and behavioral assessment is not always accurate [3]. We will discuss the information we obtain about the brain's metabolic capacities (with positron emission tomography – PET), its hemodynamic function (with functional magnetic resonance imaging – fMRI), the metabolic and biochemical activity (with MRI spectroscopy), its structural properties (with diffusion weighted MRI), and the dynamics

of cortical excitability (with electroencephalography recordings of transcranial magnetic stimulation evoked pulses – EEG/TMS). To our mind, by combining the temporal and spatial properties which characterize these different techniques, one gains a holistic vision of the underlying pathophysiology of patients with DOCs in general and of the single patient under care in particular.

## THE CLINICAL ENTITIES OF CONSCIOUSNESS

What differentiates DOC from other states of unconsciousness, such as due to pharmacological anesthesia, sleep and epileptic seizures, is the prolonged impaired awareness following severe brain damage. After an acute brain insult, a patient may spend some time in coma. Patients in coma are not awake, as evinced by eye closure even when intensively stimulated [4] and presumably they are not aware of themselves and their environment. Coma may arise after structural or metabolic lesions of the brainstem reticular system or after widespread bilateral cerebral damage [4]. The condition of coma usually does not last longer than 4 weeks, after which patients either evolve to brain death (*i.e.*, permanent loss of brainstem functions) or may completely recover consciousness or evolve to a vegetative state (VS) [5].

The VS, recently termed as “unresponsive wakefulness syndrome” (UWS; [6]), is a condition of wakefulness without awareness [7]. This means that patients in VS/UWS open their eyes but they exhibit only reflex behaviors [8]. Therefore, they are considered unaware of themselves and their surroundings. Neuropathological findings seem to associate this condition to profound damage to the subcortical white matter and the major relay nuclei of the thalamus [9]. It has been further shown, in a large post-mortem series of patients who sustained a blunt traumatic brain injury, that clinical prognosis seems to be related to the location and extent of brainstem damage. Patients with lesions in central parts of the rostral brainstem, frequently associated with extensive diffusion axonal injury (DAI), showed no recovery from coma or VS/UWS, which occurred only in the patients with damage to the dorso-lateral brainstem tegmentum or pontine basis [10]. It has been proposed that the VS/UWS is permanent after 12 months following traumatic brain injury and 3 months following non-traumatic insults, and therefore chances for recovery are slim [11]. However, patients with late spontaneous recoveries challenge these proposed time boundaries and as such the futile connotation of the vegetative state has been revisited [6]. Patients from VS/UWS may die or evolve into a minimally conscious state (MCS), which may be the endpoint of their improvement or a temporary stage on the way to further recovery of consciousness [12].

Patients in MCS exhibit signs of discernible non-reflex behaviors which occur reproducibly (yet inconsistently) as a response to visual, auditory, tactile, or noxious stimuli [12]. However, patients in MCS are not able to communicate accurately with their environment although some may show intentional signs of communication [13]. The heterogeneity of MCS has been recognized and recently it has been proposed to subcategorize this entity into MCS PLUS and MINUS [14]. The differentiation was based on the level of complexity of the observed behavioral responses, such as the ability to follow simple commands [15]. Patients from MCS may die, regress back to VS/UWS, or emerge out of EMCS once they regain the ability to reliably communicate and/or use objects in a functional manner [12]. The temporal limits of irreversibility have not been proposed yet for MCS. Although there is some evidence suggesting that patients in a MCS have better chances of recovery than patients in VS/UWS, at present we are not in a position to refer to possibly chronic MCS [16].

Some patients, most frequently after a focal brainstem lesion, may evolve from a coma to a locked-in syndrome (LIS). This is not classically a DOC, but it is worth to be mentioned here as it often can be misdiagnosed as a DOC. In classic cases, patients in LIS have a fully recovered consciousness but have lost voluntary motor control, except for small eye movements making it possible for them to answer yes-no questions. More rarely they lose the control of all their voluntary muscles, including extrinsic eye muscles (complete LIS), making more challenging or impossible to communicate with them [17]. In these patients, the only evidence for preserved consciousness may be their ability to communicate via

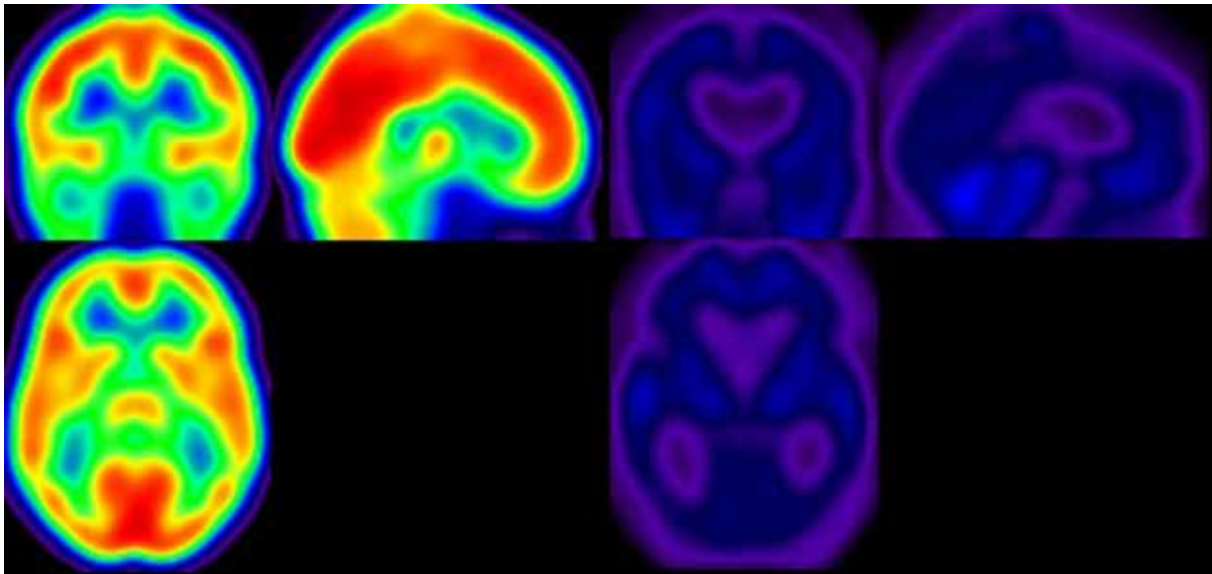
assisting technologies (*i.e.*, fMRI, EEG or evoked potentials). As such, the term “functional LIS” has been recently proposed to describe those patients with a dissociation between extreme behavioral motor impairment and the identified preserved higher cognitive abilities only detectable by functional imaging techniques [14].

Differential diagnosis of the above mentioned clinical DOC entities raises important ethical and medical issues, including end-of-life decision and pain treatment [18]. Nowadays, the gold standard to assess the level of consciousness is the clinical assessment, based on patients’ behavioral responsiveness. Because responsiveness represents only an indirect evidence of consciousness (*i.e.* the lack of responsiveness does not necessarily imply lack of consciousness) reliance on these behavioral markers presents significant challenges and may lead to misdiagnoses. Clinical studies have shown that up to 40% of patients with a diagnosis of VS/UWS may in fact retain some level of awareness [3, 19, 20], and the main causes of misdiagnosis are associated with patient’s disabilities, such as paralysis and aphasia, fluctuation in arousal level, difficulty differentiating between reflexive and voluntary movements, the presence of drugs’ side effects and the non-use of standardized and sensitive clinical scales such as the Coma Recovery Scale-Revised (CRS-R) [13]. Furthermore, conventional brain structural imaging studies have shown highly variable and heterogeneous results in patients with DOC, suggesting that a specific brain region cannot be unequivocally related to awareness [21]. This knowledge has led to the search for other non-clinical assessment techniques in order to better understand brain function in these patients and to overcome the limits of behavioral assessment in the detection of possible retained consciousness in unresponsive patients.

### **Positron emission tomography (PET)**

Positron emission tomography (PET) is a nuclear medical imaging technique for assessing brain activity and function by recording the emission of positrons from radioactively labeled molecules. If the chosen molecule is fludeoxyglucose (FDG), an analogue of glucose, the concentrations of tracer imaged will indicate tissue metabolic activity by virtue of the regional glucose uptake and hence neural activity whereas the O labelled water PET, due to the short half-life of this molecule, is usually used to detect activation during active and passive paradigms [22].

When PET is used to investigate brain death, the so-called “hollow skull sign” is present, accounting for the absence of glucose uptake in the brain and therefore metabolic activity. In these cases the only region showing an uptake of glucose is the skin surrounding the skull [4]. In comatose patients, PET studies showed on average a reduced grey-matter metabolism up to 50-70% of normal range in patients of traumatic or hypoxic origin [4]. After recovery from post-anoxic coma, cerebral metabolic rates for glucose show no drastic increase, exhibiting glucose rates only up to 75% of the normal values [23]. Global cerebral metabolism was shown to correlate poorly with the level of conscious-



**Figure 1**

Global brain metabolism detected by FDG-PET in a healthy control (left) and in a patient in an unresponsive wakefulness syndrome (right). Red colorscale indicates regions with high consumption of glucose; blue colorscale indicates regions with low consumption of glucose.

ness, as measured by the Glasgow Coma Scale, in patients studied within the first month after head trauma [24]. Furthermore, no established relation between cerebral metabolic rates of glucose or oxygen as measured by PET and patient outcome has been found. A global decrease in cerebral metabolism, in fact, is not unique to coma, as it can be associated to several different situations with temporary loss of consciousness, such as deep sleep [25], general anesthesia [26] and Cotard's syndrome [27].

In VS/UWS, where awareness is impaired whilst wakefulness is spared, PET studies showed that unresponsive patients are characterized by reduced global metabolism compared with healthy subjects (*Figure 1*). Interestingly, recovery of consciousness from VS/UWS does not necessarily coincide with resumption of global metabolic activity [17]. PET voxel-based studies have indicated that impairment of awareness is related to impairments in specific brain areas, consisting of a large-scale fronto-parietal network encompassing the polymodal associative cortices [28]. The higher-order associative fronto-parietal network mentioned above has been recently functionally subdivided into two different networks: extrinsic awareness network and intrinsic awareness network [29]. The extrinsic awareness network (also known as executive control network – ECN) encompasses the lateral fronto-parietal brain regions and it is related to the sensory awareness or awareness of the environment. The intrinsic awareness network (most widely known as the default mode network – DMN), encompasses mainly the medial prefrontal cortex, the precuneus and the bilateral posterior parietal cortex, and it is related to awareness of self and self-related processes, such as mind-wandering and autobiographical thinking [30]. Patients in VS/UWS have shown metabolic impairment of both the internal and external awareness networks [31], and to their connec-

tions with thalamic nuclei. This latter evidence stems from the recovery of this thalamo-cortical activity in a VS/UWS patient who had subsequently recovered consciousness [32]. PET studies using passive auditory and noxious stimulation [33, 34] have furthermore demonstrated a peculiar disconnection in VS/UWS patients between the primary sensory areas and these large-scale associative fronto-parietal cortices, which are thought to be required for conscious perception [7]. In contrast, function in known arousal structures including the reticular formation in the brainstem, the hypothalamus, and the basal forebrain appeared to remain relatively intact [4]. In line with their clinical condition, patients in MCS show a partial preservation of this large-scale associative fronto-parietal network [35]. In particular, it has been demonstrated recently that MCS patients show a better preservation of the external awareness network rather than internal awareness network, which could suggest an impairment of self-awareness otherwise difficult to detect at the bedside [31]. In contrast to VS/UWS, PET studies employing passive stimulations have further confirmed a partial preservation of the associative fronto-parietal cortices thought to be required for conscious perception. More interestingly, PET studies employing passive noxious stimuli, have elicited the activation of association areas related to pain processing in MCS patients in a similar network as in normal controls, suggesting therefore a potential pain perception capacity in this patient category [22]. This information supported the idea that MCS patients might need analgesic treatment and has further led to the validation of the Nociception Coma Scale, which assesses behavioral responses to nocistimulation in patients surviving coma [36].

In terms of diagnostic accuracy, cerebral metabolic information obtained by PET has shown to be able to specifically and reliably differentiate VS/UWS from LIS

patients and healthy controls [37]. It was based on PET investigation of brain function in MCS that the subcategorization into MCS PLUS and MCS MINUS was suggested. In particular, patients in MCS PLUS exhibited preserved metabolism in language comprehension related area, which is in accordance with their capacities to follow simple commands and/or communicate intentionally [15].

### **Functional magnetic resonance imaging (fMRI)**

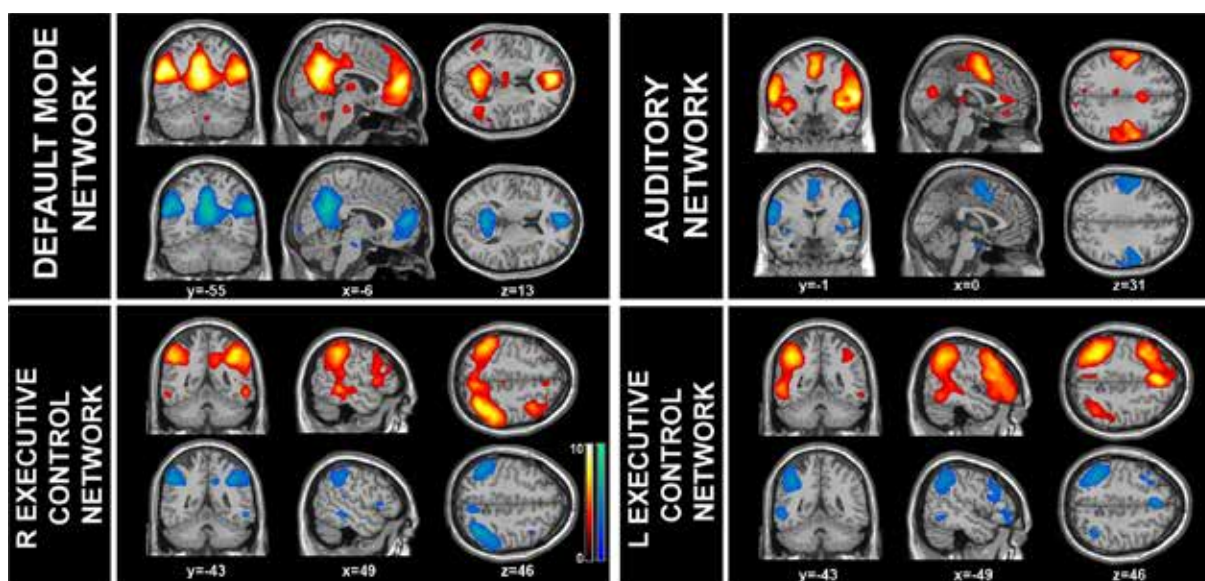
Functional magnetic resonance imaging (fMRI) relies on the natural diamagnetic properties of oxygenated hemoglobin and paramagnetic properties of desoxygenated hemoglobin to analyze changes of blood oxygenation in the brain associated with neural activity (blood oxygenation level dependent –BOLD– signal). As it does not require the use of X-rays and radiotracers injection, and for its superior spatial and temporal resolution in comparison to PET, it has been increasingly used for detecting brain activity changes. In the last decade, fMRI has been largely used in patients with DOC in order to detect brain activity related to residual cognition and awareness, and in some cases even established two-way communication, without requiring any behavioral output from patients [38]. For instance, a recent fMRI study using mental imagery tasks (imagining playing tennis vs. spatial navigation around one's house) showed that in a large cohort of 54 patients with DOC, five (3 patients in VS/UWS and 2 patients in MCS– two of them who did not show any signs of consciousness at behavioral assessment) were able to willfully modulate their brain activity; furthermore, one behaviorally patient in VS/UWS was able to use this technique to correctly respond with yes (by imagining playing tennis) or no (by imagining visiting the rooms of his house) to autobiographical questions during the fMRI scanning. This study showed that 17% of patients diagnosed as in VS/UWS after behavioral assessment can follow commands when such commands need a change in blood oxygenation level dependent response, rather than overt motoric behavior. Similarly, a further study using selective auditory attention showed that 3 behaviorally unresponsive patients out of 3 (2 in MCS and 1 in VS/UWS) were able to convey their ability to follow commands, and 1 of them in VS/UWS was even able to use attention to correctly communicate answers to several binary questions [39]. This evidence shows how different tasks, which allow to overcome the motor unresponsiveness of brain injured patients by tackling different cognitive aspects, might detect residual covert awareness in this patient category.

It is worth to stress that absent command-related brain activation does not allow to infer that awareness is not present [40]. Indeed, out of 31 patients in MCS described in the study by Monti *et al.* [38], only one was able to willfully modulate his brain activity. This could be related to several reasons. For example, a patient may not have understood the task instructions because of deafness or aphasia, or because of its fluctuating level of consciousness, or simply because he was not willing to perform the task, leading to possible false negatives

results [41]. In this context, resting-state fMRI is a non invasive technique used to investigate the spontaneous temporal coherence in BOLD fluctuations related to the amount of synchronized neural activity (*i.e.*, functional connectivity) existing between distinct brain locations, even in the absence of input or output tasks [42]. This technique has been increasingly used in the analysis of patients with DOC, mainly because it is non invasive and does not require any effort or feedback from the patient. Among the several functional networks that have been detected so far [43], the DMN has attracted most attention. As stated above, the DMN is defined as a set of areas, encompassing posterior-cingulate/precuneus, anterior cingulate/mesiofrontal cortex, temporo-parietal junctions and hippocampi [5], that show more activity at rest than during attention-demanding tasks. Because of its link to internally-oriented cognitive content, DMN has been thought to be implicated in consciousness processes [30, 44, 45]. Across the groups of patients in coma, VS/UWS, MCS, it was shown that DMN areas exhibited reduced functional connectivity which was correlated to the degree of consciousness [46]. Recently, more networks at resting state have been investigated in DOC, such as the bilateral fronto-parietal or executive control networks, salience, sensorimotor, auditory, visual systems, and the cerebellar network. It was found that the DMN, the bilateral executive control networks and the auditory system were significantly less identifiable (in terms of spatial and neural properties) in patients with DOC compared to healthy controls and showed consciousness-level dependent decreases in functional connectivity across the spectrum of DOC (*Figure 2*). Eventually, with machine learning classification trained on the identification of these ten networks as neuronal or not, it was able to accurately separate healthy controls from patients in DOC with 85% accuracy [47]. The potential prognostic value of DMN connectivity was shown in a cohort of patients in the acute stage of coma for whom the presence of DMN functional connectivity was paralleled to subsequent reversibility of coma [48].

Decreased DMN connectivity, however, is not unique to DOC, as it can be associated to several different conditions such as other physiological and pharmacological loss of consciousness (sleep and general anesthesia [49]) and pathological conditions such as Alzheimer Disease [50] and drug related states such as alcohol [51] and amphetamine [52]. Nevertheless, the persistence of coherent DMN connectivity in some patients in VS/UWS as well as in a known case of anesthetized monkey [53], in contrast with its complete absence in case of brain death [54], suggests that further phenomena may modulate the interplay between consciousness and the DMN. Concurrently with decreased DMN connectivity, we recently reported paradoxical hyperconnectivity in limbic structures in DOC patients (11 VS/UWS and 7 MCS patients) compared to healthy controls, and more strongly in VS/UWS than in MCS patients [55]. This hyperconnectivity may represent an epiphenomenon of global decrease in neural projections in patients, indicating more resistant connection between DMN and limbic structures. Alternatively, it



**Figure 2**

fMRI resting state connectivity in long-range (*i.e.*, default mode network, right and left executive control) and sensory cortical networks (*i.e.*, auditory) is disrupted in patients with disorders of consciousness (blue areas) compared to healthy controls (in red). Images are shown on triplanar anatomical slices.

may reflect the persistent engagement of residual neural activity in self-reinforcing neural loops which may disrupt normal patterns of connectivity [55]. This complex picture is in line with previous theories explaining diffuse (extralimbic) connectivity reduction in patients with DOC, and might delineate a condition in which dysfunctional hyperconnectivity may impair awareness by permanently engaging critical neural resources. This scenario would suggest a much more complex and multifaceted brain connectivity architecture in DOC patients than previously thought. This being also recently supported by the detection of hyperconnectivity patterns also in states of pharmacological coma, such as general anesthesia [56].

Along with intra- and inter-network connectivity, the importance of anti-correlation among different networks has further attracted scientific attention. There is now increasing evidence that the DMN network, or internal awareness network, and the executive control network, or external awareness network, show routinely an anti-correlation, *i.e.* when one is active the other is not and vice-versa. [30]. A decreased anti-correlation of these two networks is shown in unconscious states, such as anesthesia [57], deep sleep [58] and VS/UWS patients [54]. These findings highlight, at least partially, that the anti-correlated pattern between DMN and the executive control network may be of functional significance to conscious cognition of subjectivity [59].

However, the study of resting state activity in DOC can be challenging to both clinical and methodological issues. For example, patients that show pre-scan motion activity might need to be anesthetized during the scan in order to reduce the motion artifacts. In this case, the effect of anesthesia will need to be accounted during the processing of the acquired data. An example of a methodological problem is the spatial normalization of these often severely deformed brains.

This issue has been partially tackled in previous studies, where a mid-template [55] or study-template [37] was generated by taking into account the mean size of the group of patients and healthy controls, in order to use the same level of deformation in both patients and controls' groups. Finally, identified resting state connectivity patterns need to be interpreted according to the studied population. The future challenges will be to interpret resting-state patterns according to studied population, for example, in order to unravel the relationship (correlation and anti-correlation) between the resting state networks in different level of consciousness, and to better comprehend its functional and clinical meaning in general and at single subject level. A further challenge will be to move from static functional connectivity measurements to the assessment of temporal dynamics of connectivity, namely looking at the changes of correlation and anti-correlation among networks across time. This becomes imperative when considering the dynamic nature of intrinsic connectivity, which characterizes most areas of the brain beyond the DMN [49].

However, in practice fMRI is not suitable for all patients because it requires placing the subject into an MRI scanner. Therefore, its use is virtually impossible for those patients carrying non-compatible MRI devices (pace-makers, metallic implants etc), often present in an intensive care setting. Similarly, fMRI is not suited for patients at home as a "communication device". In such cases, the use of electrophysiological recordings is more practical and appropriate.

### ***Electroencephalography and transcranial magnetic stimulation (combined with electroencephalography)***

Like fMRI, electroencephalography (EEG) recordings in patients with DOC can evaluate different aspects of cognitive residual function and provide means

to communicate with the outside world without motor output. Standard recordings in the neurological department offer a first global view of the electrogenesis of a patient and can detect abnormal activity and therefore guide treatment [60]. In resting conditions, various EEG paradigms have made an effort to differentiate between the clinical entities of patients with DOC. EEG is routinely used to confirm the diagnosis of brain death and can be of diagnostic importance in some cases of complete LIS patients [61]. Generally speaking, following a severe brain injury, whether it is of traumatic or anoxic origin, the EEG can be altered and display abnormalities. A visible main effect is a slowing of the brain activity proportional to the severity of the injury. Therefore, the predominant rhythm is no longer posterior alpha (related to the awake stages in adult healthy adult individuals) but diffuse theta or delta (normally present in the slow stages of sleep in healthy adult individuals). In some cases alpha or theta activity can be observed, but its activity differs from a normal adult alpha activity [61].

Regarding DOC patients, measures of signal complexity such as the bi-spectral index (a measure of the depth of anesthesia) were shown to discriminate between patients in VS/UWS and patients in MCS, at the group level [62]. The bi-spectral index was also positively correlated with behavioral scores of awareness at the time of testing and was associated with outcome at 1-year post-trauma.

However, at the single-subject level, establishing a diagnosis solely based on a single standard EEG is difficult since the patterns are not specific of the etiology and the same subject can have varying patterns in short intervals. A study based on patients in persistent VS/UWS concluded that there was no possible diagnostic use of EEG due to its heterogeneous and varying aspects [63]. Despite the limited diagnostic role of standard EEG recordings, prognostic statements are possible but challenging as the same pattern can be found in encephalopathy of different origins. Furthermore, the outcome does not depend uniquely on the brain affection itself but on the overall condition of the patient. EEG information needs, therefore, to be backed-up by etiology in order to have insights on the prognosis [60].

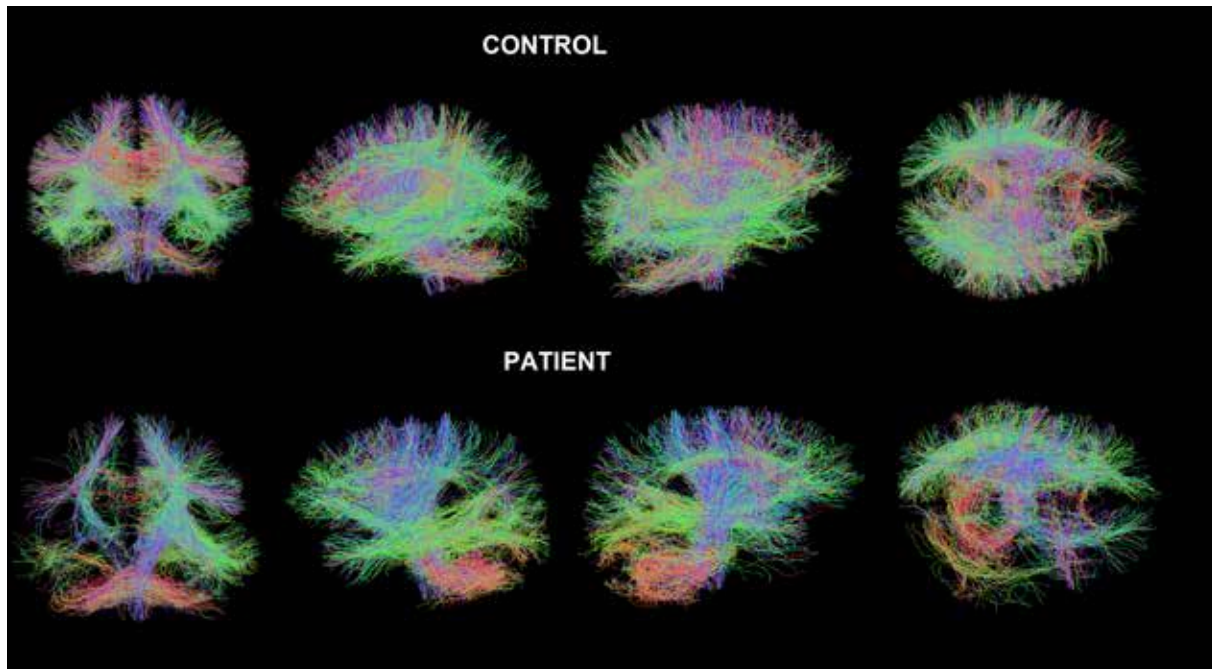
In this context, active command mental paradigms combined with EEG [64-66] or electromyography [67] appear to be more convenient in the diagnosis of DOC. They have, in fact, allowed both detection of voluntary brain function in VS/UWS and functional communication in patients with complete LIS. A recent study showed that out of 16 studied patients, 3 of them who seemed to be entirely in VS/UWS on the basis of repeated specialist behavioral assessment, were found to be aware and capable of substantially and consistently modulating their EEG responses upon command [66]. However, as pointed out above, we cannot infer any diagnostic information from a negative result, as it does not necessarily imply the lack of consciousness. In fact, as mentioned earlier, patients with minimal consciousness might still not be able to understand and follow instructions. In this context, EEG combined with TMS (TMS-EEG) may be especially useful to assess the level

of consciousness in DOC patients, because it does not rely on a subject's ability to process sensory stimuli, to understand and follow instructions, or to communicate. TMS-EEG allows to non-invasively stimulate a subset of cortical neurons, and to measure the effects produced by this perturbation in the rest of the brain [68, 69]. For patients in VS/UWS, when stimulating a superficial region of the cerebral cortex, TMS either induced no response or triggered a simple, local EEG response, indicating a breakdown of effective connectivity (*i.e.*, the influence that one brain region exerts on another [70, 71]) similar to the one observed in deep sleep and anesthesia [69, 72]. In contrast, for patients in MCS, TMS triggered complex EEG activations that sequentially involved distant cortical areas, similar to activations recorded in patients in LIS and healthy awake subjects. Interestingly, a patient in MCS assessed during a period of no responsiveness still showed complex and widespread brain responses to TMS, even though no conscious behavior could be observed at the bedside [71]. Furthermore, an empirical measure of brain complexity, the perturbational complexity index (PCI), which gauges the amount of information contained in the integrated response of the thalamocortical system to a direct TMS perturbation, has recently been introduced [68]. The PCI was tested on a large data set of TMS-evoked potentials recorded from healthy subjects during wakefulness, dreaming, non-rapid eye movement (NREM) sleep, and different levels of sedation induced by different anesthetic agents (midazolam, xenon, and propofol) as well as from brain-injured patients who had emerged from coma (overall, 208 sessions in 52 subjects). Empirically, PCI showed to provide a data-driven metric that can discriminate level of consciousness in single subjects under different conditions: wakefulness; dreaming; the LIS; the MCS; the EMCS; intermediate levels of sedation; NREM sleep; midazolam-, xenon-, and propofol-induced loss of consciousness; and the VS/UWS [68]. Because this technique is handy, not invasive, does not require patients' cooperation and works at the single-subject level, it appears to be a promising tool for the diagnosis of patients with DOC [68].

## STRUCTURAL MRI

### Diffusion tensor imaging

Diffusion tensor imaging (DTI) is an extension of diffusion weighted imaging which is based on the principle that water molecule movement is restricted by barriers to diffusion in the brain depending on tissue organization. The diffusion of water protons is higher along fiber tracts than across them in the white matter, which allows for directional measurement of diffusion and, hence, measurement of structural integrity. DTI differs from diffusion weighted imaging for the higher number of directions taken into considerations when studying the water flow (> 6). DTI data can be used to compute the fractional anisotropy as well as to track fibers (Figure 3). The fractional anisotropy quantifies anisotropic diffusion in the brain, which is related to the density, integrity, directionality and crossings of white matter tracts [73, 74]. DTI evaluates the architectural organization of white matter fibers and is a powerful



**Figure 3**

Neural tracks obtained with DTI in a healthy control (top) and a patient in MCS (bottom) confirms the structural damage which is evident in the temporo-parietal regions of the right hemisphere (bottom right - T1 MRI structural image). Colors indicate directionality of water diffusion: red = left-right; green = anterior-posterior; blue = superior-inferior.

technique for *in vivo* detection of diffuse axonal injury after brain trauma [75].

One of the advantages of DTI is the possibility to evaluate brain trauma even in sedated patients, as its values are theoretically not influenced by sedatives or hypnotics, such as during clinical exams or fMRI studies. So far, DTI has been mostly used in the attempt to assess the prognosis in traumatic brain injured (TBI) patients.

In TBI patients a significant negative correlation has been reported between fractional anisotropy in the splenium of the corpus callosum and in the internal capsule and Glasgow Coma Scale (GCS [76]) score at discharge [77]. A first study evaluating the combination of DTI and magnetic resonance spectroscopy (MRS) as a tool for predicting long-term outcome of traumatic patients, [78] showed that fractional anisotropy was significantly lower in patients who did not recover at all measurement sites, except in the posterior pons. The prediction of non-recovery after 1 year could be calculated with up to 86% sensitivity and 97% specificity when taking into account both DTI and MRS values. Non-recovery of traumatic patients was also shown to be correlated with decreased fractional anisotropy in cerebral peduncle, posterior limb of the internal capsule, posterior corpus callosum, and inferior longitudinal fasciculus [79].

Recent multicentric studies have further shown that white matter assessment with quantitative DTI increases the accuracy of long-term outcome prediction compared with the available clinical/radiographic prognostic score both in TBI and anoxic patients following cardiac arrest [80, 81]. As regards diagnostic accuracy, a recent study used DTI to assess the neuropathology of

25 patients in VS/UWS and MCS *in vivo* and to identify measures that could potentially distinguish the patients in these two groups [82]. The MCS and unresponsive patients differed significantly in subcortical white matter and thalamic regions, as measured by means of diffusivity (MD) maps, but appeared not to differ in the brainstem. DTI results predicted scores on the CSG and successfully classified the patients in to their appropriate diagnostic categories with an accuracy of 95% [82]. Furthermore, DTI showed to be helpful for characterizing etiologic differences in patients in VS/UWS. While there was evidence of marked, broadly similar abnormalities in the supratentorial grey and white matter in a group of both traumatic and anoxic patients, discordant findings were found in the infratentorial compartment, with DTI abnormalities in the brainstem confined to the TBI group [83].

These studies confirm the relevance of using DTI as biomarker for consciousness recovery after a traumatic brain injury. The available data support the possible benefit of this biomarker for early classification of patients and suggest the possibility to provide objective method for classifying these patient populations and therefore to complement the behavioral assessment.

### **Magnetic resonance spectroscopy (MRS)**

Magnetic resonance spectroscopy (MRS) is a non-invasive method that is able to measure resonances of different metabolic compounds in the brain. Thereby, it can potentially provide useful metabolic information on brain damage that may not be visible on structural MR images [84]. Most often, proton MRS (1H-MRS) is used because of the abundance of protons in the human



body and its central nervous system. However, phosphorus MRS (31P-MR) is on the increase and may provide specific information on the energy metabolism, in particular. 1H-MRS at intermediate or long echo time (135-288 ms) yields excellent signal-to-noise ratio for the main metabolites choline (Cho), creatine (Cr), N-acetylaspartate (NAA), and lactate (La). Cho is a metabolic marker of membrane synthesis and catabolism, in particular. Its concentration is higher in white than in gray matter and increases when there is an increased membrane turnover or breakdown due to cell proliferation or inflammatory processes. Cr is considered as a marker of the aerobic energy metabolism. Under the assumption that it remains fairly constant across different pathological conditions, it is widely used for calculating metabolite ratios such as NAA/Cr and Cho/Cr ratios. However, this assumption must clearly be challenged. Alternatively, the water resonance peak can be used for referencing. However, in TBI with brain atrophy cerebrospinal fluid contamination of the spectroscopically measured volume of interest will be increased and partial volume needs to be corrected for. This pertains to any of the metabolites measured in DOC. NAA is found in both gray and white matter in approximately equal quantities as a marker of neuronal density and viability produced in the mitochondria of the neurons and transported into the neuronal cytoplasm and the axons [21]. It is, on the other hand, also found in glial components of the central nervous system. La is a marker of anaerobic glycolysis. Normally, La remains below or just around the reliable limits of detectability in the normal brain, which are commonly determined by the Cramer-Rao lower bounds of the metabolite quantification. La may increase in the course of hypoxic, ischemic or severe post-traumatic brain injuries. Most often, these increases will be transient but detecting them at the right time may be of prognostic value. These issues have not yet been investigated systematically.

In order to assess brain metabolism in coma survivors, it is suggested that a comprehensive MRS protocol should include an axial chemical shift imaging (CSI) multivoxel spectroscopy at the level of the basal ganglia covering the thalamus, insula, and periventricular white matter for the supratentorial assessment and a single-voxel point-resolved 1H spectroscopy (PRESS) placed on the posterior two-thirds of the pons for the infratentorial assessment [21]. Previous investigations have indicated that 1H-MRS may be a valuable tool to predict patient outcome. In particular, NAA/Cr ratios seem to be correlated with recovery of TBI patients while no clear link with other metabolite ratios such as Cho/Cr has been observed [85]. Other studies demonstrated that metabolic changes in TBI patients are detectable by MRS even in the immediate days early after the trauma [86]. Here, NAA was found to be decreased. Its level was correlated with the initial GCS and the outcome at 3 months. Notably, NAA/Cho ratios were not suited to disentangle patients who regained consciousness from those who did not recover [87]. Other investigations have pointed to a significant correlation between NAA/Cr ratio and outcome of TBI patients in the gray and white matter of occipito-parietal [88,

89], frontalbrain areas [90], the splenium of corpus callosum [91], and thalamic brain regions [92]. In addition, pontine MRS recorded in the acute phase after a trauma may allow to separate patients who recover from patients left with severe neurological impairments, in VS/UWS or those that actually die [93]. Three distinguishable pontine MRS profiles have been proposed after head trauma: 1) a normal profile (with higher peak of NAA than Cho and Cr); 2) the neuronal-loss profile with decreased NAA peaks (going down nearly to the level of the Cr peak); and 3) the gliosis profile with an increased Cho peak, no change in the Cr or NAA peak and the associated metabolite ratios. Overall, NAA/Cr ratios seem to be of a better predictive value than NAA/Cho ratios in evaluating traumatic patients and its decrease appears to be a quite reliable index of unfavorable outcome [84]. NAA does indeed decrease immediately after a severe brain trauma. Subsequently, it seems to decline to a minimum within 48 h. After that, NAA levels remain stable within the first month after the injury. Therefore, MRS assessments during the second or third week after TBI can be considered valid markers of the degree of the traumatic impact on the brain [94, 95]. Between 6 weeks and 1 year after the insult, the evolution of the NAA/Cr ratio is much more heterogeneous. Here, NAA levels have been shown to decrease or increase but partial volume corrections have not been consistently carried out which may be important to improve the sensitivity and specificity of the findings in this period following a TBI.

As indicated above, the use of metabolite ratios may be problematic insofar that their common denominator Cr is very likely not to be unaffected by TBI. Cr resonances may be reduced in hypermetabolic and raised in hypometabolic states [96, 97] and this may well bias recordings obtained in mild-traumatic-injured patients [98]. Therefore, accurate MRS quantification and repeated longitudinal measurements will be the clue to improve MRS performance and our insights, which we can gain from this technology. Extension to 31P-MRS may be supplement further investigations as a biomarker of the altered energy metabolism associated with DOC.

## CONCLUSIONS

In the last decade, we have witnessed the development and the validation of standardized behavioral scales and neuroimaging/EEG techniques to better understand the variable conditions of patients with DOC. The need to objectively measure phenomena associated with DOC has, in fact, boosted an increased use of the neuroimaging/EEG techniques. Here we have reviewed the basic principles of how each of the different techniques (PET, fMRI, EEG, TMS-EEG) provides us with unique information about brain function in DOC patients. We have alerted the reader to the possible drawbacks of the single techniques. For example, PET, which investigates brain metabolism based on radiotracer uptake, is not suitable as a functional communication device. fMRI, giving indirect measure of neural activity by BOLD measure, requires patients to be placed in an MR scanner, making it also not easily suited or impractical.





cal as a communication devices, at least in broader application. Furthermore, activation tasks can easily lead to false negative results (*i.e.* if we get positive results we can infer about the presence of brain activity in patients but we can not infer much from a negative result). DTI and MRS provide indirect measures, respectively, of the structural integrity of WM tracts and of brain metabolism. EEG is a direct recording of neural activity, but establishing a diagnosis solely based on a single standard EEG is difficult since the patterns are not specific of the etiology. Finally, the statistical analysis of such data may require substantial training. Data analysis is further challenged by the specific brain injuries and their sequelae in these particular type of patients which often suffer from profound atrophy, focal brain lesions etc. Similarly, inferring from group-level analysis results to a single given patient is not yet possible but would be what matters in the clinical context. As one single technique can give partial information on the patient's diagnosis and prognosis, we believe in the need of combining structural/functional neuroimaging and neurophysiological techniques in order to obtain a more holistic vision of the disease per se and of the single subject. We believe that in a far reach perspective a wide integration of the neurophysiological and neuroimaging available technique may drastically improve our diagnosis and subcategorization of DOC even at single patient level. Eventually, this may allow us to translate the results

of such studies into clinical decisions relevant to the individual patient under our care.

### Conflict of interest statement

There are no potential conflicts of interest or any financial or personal relationships with other people or organizations that could inappropriately bias conduct and findings of this study.

### Acknowledgments

LH is a research fellow at the Belgian National Funds for Scientific Research (FNRS), SL is FNRS research director and AD FNRS postdoctoral researcher.

This work was also supported by the European Commission, the James McDonnell Foundation, the European Space Agency, Mind Science Foundation, the French Speaking Community Concerted Research Action, the Belgian interuniversity attraction pole, the Public Utility Foundation "Université Européenne du Travail", "Fondazione Europea di Ricerca Biomedica" and the University and University Hospital of Liège.

### Conflict of interest statement

The authors have no conflicts of interest and no disclosures of financial interest to report.

Submitted on invitation.

Accepted on 27 June 2014.

## REFERENCES

- Laureys S. Science and society: death, unconsciousness and the brain. *Nat Rev Neurosci* 2005 Nov;6(11):899-909. DOI: 10.1038/nrn1789
- Gantner IS, Bodart O, Laureys S, Demertzi A. Our rapidly changing understanding of acute and chronic disorders of consciousness: challenges for neurologists. *Future Neurol* 2012 2013/01/01;8(1):43-54. DOI: 10.2217/fnl.12.77
- Schnakers C, Vanhaudenhuyse A, Giacino J, Ventura M, Boly M, Majerus S, *et al.* Diagnostic accuracy of the vegetative and minimally conscious state: clinical consensus versus standardized neurobehavioral assessment. *BMC Neurol* 2009;9:35. DOI: 10.1186/1471-2377-9-35
- Laureys S, Owen AM, Schiff ND. Brain function in coma, vegetative state, and related disorders. *Lancet Neurol* 2004;3(9):537-46. DOI: 10.1016/S1474-4422(04)00852-X
- Greicius MD, Krasnow B, Reiss AL, Menon V. Functional connectivity in the resting brain: a network analysis of the default mode hypothesis. *Proc Natl Acad Sci USA* 2003;100(1):253-8. DOI: 10.1073/pnas.0135058100
- Laureys S, Celesia GG, Cohadon F, Lavrijsen J, Leon-Carrion J, Sannita WG, *et al.* Unresponsive wakefulness syndrome: a new name for the vegetative state or apallic syndrome. *BMC Med* 2010;8:68. DOI: 10.1186/1741-7015-8-68
- Laureys S. The neural correlate of (un)awareness: lessons from the vegetative state. *Trends Cogn Sci* 2005;9(12):556-9. DOI: 10.1016/j.tics.2005.10.010
- The vegetative state: guidance on diagnosis and management. *Clin Med* 2003;3(3):249-54.
- Adams JH, Graham DI, Jennett B. The neuropathology of the vegetative state after an acute brain insult. *Brain*. 2000 Jul;123(Pt 7):1327-38. DOI: 10.1093/brain/123.7.1327
- Jellinger KA. Neuropathology of prolonged unresponsive wakefulness syndrome after blunt head injury: review of 100 post-mortem cases. *Brain Inj* 2013;27(7-8):917-23. DOI: 10.3109/02699052.2013.793395
- Medical aspects of the persistent vegetative state (1). The Multi-Society Task Force on PVS. *N Engl J Med* 1994;330(21):1499-508.
- Giacino JT, Ashwal S, Childs N, Cranford R, Jennett B, Katz DI, *et al.* The minimally conscious state: definition and diagnostic criteria. *Neurology* 2002;58(3):349-53. DOI: 10.1212/WNL.58.3.349
- Giacino JT, Kalmar K, Whyte J. The JFK Coma Recovery Scale-Revised: measurement characteristics and diagnostic utility. *Arch Phys Med Rehabil* 2004;85(12):2020-9. DOI: 10.1016/j.apmr.2004.02.033
- Bruno MA, Vanhaudenhuyse A, Thibaut A, Moonen G, Laureys S. From unresponsive wakefulness to minimally conscious PLUS and functional locked-in syndromes: recent advances in our understanding of disorders of consciousness. *J Neurol* 2011;258(7):1373-84. DOI: 10.1007/s00415-011-6114-x
- Bruno MA, Majerus S, Boly M, Vanhaudenhuyse A, Schnakers C, Gosseries O, *et al.* Functional neuroanatomy underlying the clinical subcategorization of minimally conscious state patients. *J Neurol* 2012;259(6):1087-98. DOI: 10.1007/s00415-011-6303-7
- Laureys S, Boly M. The changing spectrum of coma. *Nat Clin Pract Neurol* 2008;4(10):544-6. PubMed PMID: 18762800. Epub 2008/09/03. eng. DOI: 10.1038/ncp-neuro0887
- Patterson JR, Grabis M. Locked-in syndrome: a review of 139 cases. *Stroke* 1986;17(4):758-64. DOI: 10.1161/01.STR.17.4.758

18. Boly M, Massimini M, Garrido MI, Gosseries O, Noirhomme Q, Laureys S, et al. Brain connectivity in disorders of consciousness. *Brain Connect* 2012;2(1):1-10. DOI: 10.1089/brain.2011.0049
19. Andrews K, Murphy L, Munday R, Littlewood C. Misdiagnosis of the vegetative state: retrospective study in a rehabilitation unit. *BMJ* 1996;313(7048):13-6. DOI: 10.1136/bmj.313.7048.13
20. Childs NL, Mercer WN, Childs HW. Accuracy of diagnosis of persistent vegetative state. *Neurology* 1993;43(8):1465-7. DOI: 10.1212/WNL.43.8.1465
21. Tshibanda L, Vanhaudenhuyse A, Boly M, Soddu A, Bruno MA, Moonen G, et al. Neuroimaging after coma. *Neuroradiology* 2010;52(1):15-24. DOI: 10.1007/s00234-009-0614-8
22. Boly M, Faymonville ME, Schnakers C, Peigneux P, Lambermont B, Phillips C, et al. Perception of pain in the minimally conscious state with PET activation: an observational study. *Lancet Neurol* 2008;7(11):1013-20. DOI: 10.1016/S1474-4422(08)70219-9
23. DeVolder AG, Goffinet AM, Bol A, Michel C, de Barse T, Laterre C. Brain glucose metabolism in post-anoxic syndrome. Positron emission tomographic study. *Arch Neurol* 1990;47(2):197-204. DOI: 10.1001/archneur.1990.00530020103022
24. Bergsneider M, Hovda DA, Lee SM, Kelly DF, McArthur DL, Vespa PM, et al. Dissociation of cerebral glucose metabolism and level of consciousness during the period of metabolic depression following human traumatic brain injury. *J Neurotrauma* 2000;17(5):389-401. DOI: 10.1089/neu.2000.17.389
25. Maquet P, Degueldre C, Delfiore G, Aerts J, Peters JM, Luxen A, et al. Functional neuroanatomy of human slow wave sleep. *J Neurosci* 1997;17(8):2807-12.
26. Alkire MT, Haier RJ, Barker SJ, Shah NK, Wu JC, Kao YJ. Cerebral metabolism during propofol anesthesia in humans studied with positron emission tomography. *Anesthesiology* 1995;82(2):393-403; discussion 27A. DOI: 10.1097/0000542-199502000-00010
27. Charland-Verville V, Bruno MA, Bahri MA, Demertzi A, Desseilles M, Chatelle C, et al. Brain dead yet mind alive: a positron emission tomography case study of brain metabolism in Cotard's syndrome. *Cortex* 2013;49(7):1997-9. DOI: 10.1016/j.cortex.2013.03.003
28. Laureys S, Goldman S, Phillips C, Van Bogaert P, Aerts J, Luxen A, et al. Impaired effective cortical connectivity in vegetative state: preliminary investigation using PET. *Neuroimage* 1999;9(4):377-82. DOI: 10.1006/nimg.1998.0414
29. Demertzi A, Soddu A, Laureys S. Consciousness supporting networks. *Curr Opin Neurobiol* 2013;23(2):239-44. DOI: 10.1016/j.conb.2012.12.003
30. Vanhaudenhuyse A, Demertzi A, Schabus M, Noirhomme Q, Bredart S, Boly M, et al. Two distinct neuronal networks mediate the awareness of environment and of self. *J Cogn Neurosci* 2011;23(3):570-8. DOI: 10.1162/jocn.2010.21488
31. Thibaut A, Bruno MA, Chatelle C, Gosseries O, Vanhaudenhuyse A, Demertzi A, et al. Metabolic activity in external and internal awareness networks in severely brain-damaged patients. *J Rehabil Med* 2012;44(6):487-94. DOI: 10.2340/16501977-0940
32. Laureys S, Lemaire C, Maquet P, Phillips C, Franck G. Cerebral metabolism during vegetative state and after recovery to consciousness. *J Neurol Neurosurg Psychiatry* 1999;67(1):121. DOI: 10.1136/jnnp.67.1.121
33. Laureys S, Faymonville ME, Peigneux P, Damas P, Lambermont B, Del Fiore G, et al. Cortical processing of noxious somatosensory stimuli in the persistent vegetative state. *Neuroimage* 2002;17(2):732-41. DOI: 10.1006/nimg.2002.1236
34. Laureys S, Faymonville ME, Degueldre C, Fiore GD, Damas P, Lambermont B, et al. Auditory processing in the vegetative state. *Brain* 2000;123 (Pt 8):1589-601. DOI: 10.1093/brain/123.8.1589
35. Laureys S, Perrin F, Faymonville ME, Schnakers C, Boly M, Bartsch V, et al. Cerebral processing in the minimally conscious state. *Neurology* 2004;63(5):916-8. DOI: 10.1212/01.WNL.0000137421.30792.9B
36. Schnakers C, Chatelle C, Vanhaudenhuyse A, Majerus S, Ledoux D, Boly M, et al. The Nociception Coma Scale: a new tool to assess nociception in disorders of consciousness. *Pain* 2010;148(2):215-9. DOI: 10.1016/j.pain.2009.09.028
37. Phillips CL, Bruno MA, Maquet P, Boly M, Noirhomme Q, Schnakers C, et al. "Relevance vector machine" consciousness classifier applied to cerebral metabolism of vegetative and locked-in patients. *Neuroimage* 2011;56(2):797-808. DOI: 10.1016/j.neuroimage.2010.05.083
38. Monti MM, Vanhaudenhuyse A, Coleman MR, Boly M, Pickard JD, Tshibanda L, et al. Willful modulation of brain activity in disorders of consciousness. *N Engl J Med* 2010;362(7):579-89. DOI: 10.1056/NEJMoa0905370
39. Naci L, Owen AM. Making every word count for nonresponsive patients. *JAMA Neurol* 2013 Aug 12. PubMed PMID: 23939634. Epub 2013/08/14. Eng. DOI: 10.1001/jamaneurol.2013.3686
40. Bardin JC, Fins JJ, Katz DI, Hersch J, Heier LA, Tabet K, et al. Dissociations between behavioural and functional magnetic resonance imaging-based evaluations of cognitive function after brain injury. *Brain* 2011;134(Pt 3):769-82. DOI: 10.1093/brain/awr005
41. Monti MM, Laureys S, Owen AM. The vegetative state. *BMJ* 2010;341:c3765. PubMed PMID: 20679291. Epub 2010/08/04. eng. DOI: 10.1136/bmj.c3765
42. Biswal BB, Van Klyen J, Hyde JS. Simultaneous assessment of flow and BOLD signals in resting-state functional connectivity maps. *NMR Biomed* 1997;10(4-5):165-70. DOI: 10.1002/(SICI)1099-1492(199706/08)10:4/5%3C165::AID-NBM454%3E3.0.CO;2-7
43. Beckmann CF, DeLuca M, Devlin JT, Smith SM. Investigations into resting-state connectivity using independent component analysis. *Philos Trans R Soc Lond B Biol Sci* 2005;360(1457):1001-13. PubMed PMID: 16087444. DOI: 10.1098/rstb.2005.1634
44. Raichle ME, MacLeod AM, Snyder AZ, Powers WJ, Gusnard DA, Shulman GL. A default mode of brain function. *Proc Natl Acad Sci USA* 2001;98(2):676-82. PubMed PMID: 11209064. DOI: 10.1073/pnas.98.2.676
45. Schilbach L, Eickhoff SB, Rotarska-Jagiela A, Fink GR, Vogeley K. Minds at rest? Social cognition as the default mode of cognizing and its putative relationship to the "default system" of the brain. *Conscious Cogn* 2008;17(2):457-67. DOI: 10.1016/j.concog.2008.03.013
46. Vanhaudenhuyse A, Noirhomme Q, Tshibanda LJ, Bruno MA, Boveroux P, Schnakers C, et al. Default network connectivity reflects the level of consciousness in non-communicative brain-damaged patients. *Brain* 2010;133(Pt 1):161-71. DOI: 10.1093/brain/awp313
47. Demertzi A, Gómez F, Crone JS, Vanhaudenhuyse A, Tshibanda L, Noirhomme Q, et al. Multiple fMRI system-level baseline connectivity is disrupted in patients with consciousness. DOI: 10.1016/j.cortex.2013.11.005
48. Norton L, Hutchison RM, Young GB, Lee DH, Sharpe MD, Mirsattari SM. Disruptions of functional con-

- nectivity in the default mode network of comatose patients. *Neurology* 2012;78(3):175-81. DOI: 10.1212/WNL.0b013e31823fcd61
49. Heine L, Soddu A, Gomez F, Vanhaudenhuyse A, Tshibanda L, Thonnard M, *et al.* Resting state networks and consciousness: alterations of multiple resting state network connectivity in physiological, pharmacological, and pathological consciousness States. *Front Psychol* 2012;3:295. DOI: 10.3389/fpsyg.2012.00295
  50. Greicius MD, Srivastava G, Reiss AL, Menon V. Default-mode network activity distinguishes Alzheimer's disease from healthy aging: evidence from functional MRI. *Proc Natl Acad Sci USA* 2004;101(13):4637-42. DOI: 10.1073/pnas.0308627101
  51. Esposito F, Pignataro G, Di Renzo G, Spinali A, Paccone A, Tedeschi G, *et al.* Alcohol increases spontaneous BOLD signal fluctuations in the visual network. *Neuroimage* 2010;53(2):534-43. DOI: 10.1016/j.neuroimage.2010.06.061
  52. Roberts GM, Garavan H. Evidence of increased activation underlying cognitive control in ecstasy and cannabis users. *Neuroimage* 2010;52(2):429-35. DOI: 10.1016/j.neuroimage.2010.04.192
  53. Vincent JL, Patel GH, Fox MD, Snyder AZ, Baker JT, Van Essen DC, *et al.* Intrinsic functional architecture in the anesthetized monkey brain. *Nature* 2007;447(7140):83-6. DOI: 10.1038/nature05758
  54. Boly M, Tshibanda L, Vanhaudenhuyse A, Noirhomme Q, Schnakers C, Ledoux D, *et al.* Functional connectivity in the default network during resting state is preserved in a vegetative but not in a brain dead patient. *Hum Brain Mapp* 2009;30(8):2393-400. DOI: 10.1002/hbm.20672
  55. Di Perri C, Bastianello S, Bartsch AJ, Pistarini C, Maggioni G, Magrassi L, *et al.* Limbic hyperconnectivity in the vegetative state. *Neurology* 2013;81(16):1417-24. DOI: 10.1212/WNL.0b013e3182a43b78
  56. Guldenmund P, Demertzi A, Boveroux P, Boly M, Vanhaudenhuyse A, Bruno MA, *et al.* Thalamus, brainstem and salience network connectivity changes during propofol-induced sedation and unconsciousness. *Brain Connect* 2013;3(3):273-85. DOI: 10.1089/brain.2012.0117
  57. Boveroux P, Vanhaudenhuyse A, Bruno MA, Noirhomme Q, Lauwick S, Luxen A, *et al.* Breakdown of within- and between-network resting state functional magnetic resonance imaging connectivity during propofol-induced loss of consciousness. *Anesthesiology* 2010;113(5):1038-53. DOI: 10.1097/ALN.0b013e3181f697f5
  58. Samann PG, Wehrle R, Hoehn D, Spoormaker VI, Peters H, Tully C, *et al.* Development of the brain's default mode network from wakefulness to slow wave sleep. *Cereb Cortex* 2011;21(9):2082-93. DOI: 10.1093/cercor/bhq295
  59. Demertzi A, Vanhaudenhuyse A, Bredart S, Heine L, di Perri C, Laureys S. Looking for the self in pathological unconsciousness. *Front Hum Neurosci* 2013;7:538. PubMed PMID: 24027519. DOI: 10.3389/fnhum.2013.00538
  60. Lehenbre R, Marie-Aurelie B, Vanhaudenhuyse A, Chatelle C, Cologan V, Leclercq Y, *et al.* Resting-state EEG study of comatose patients: a connectivity and frequency analysis to find differences between vegetative and minimally conscious states. *Funct Neurol* 2012;27(1):41-7.
  61. Lehenbre R, Gosseries O, Lugo Z, Jedidi Z, Chatelle C, Sadzot B, *et al.* Electrophysiological investigations of brain function in coma, vegetative and minimally conscious patients. *Arch Ital Biol* 2012;150(2-3):122-39. DOI: 10.4449/aib.v150i2.1374
  62. Schnakers C, Ledoux D, Majerus S, Damas P, Damas F, Lambermont B, *et al.* Diagnostic and prognostic use of bispectral index in coma, vegetative state and related disorders. *Brain Inj* 2008;22(12):926-31. DOI: 10.1080/02699050802530565
  63. Kulkarni VP, Lin K, Benbadis SR. EEG findings in the persistent vegetative state. *J Clin Neurophysiol* 2007;24(6):433-7. DOI: 10.1097/WNP.0b013e31815c2810
  64. Schnakers C, Perrin F, Schabus M, Hustinx R, Majerus S, Moonen G, *et al.* Detecting consciousness in a total locked-in syndrome: an active event-related paradigm. *Neurocase* 2009;15(4):271-7. DOI: 10.1080/13554790902724904
  65. Lule D, Noirhomme Q, Kleih SC, Chatelle C, Halder S, Demertzi A, *et al.* Probing command following in patients with disorders of consciousness using a brain-computer interface. *Clin Neurophysiol* 2013;124(1):101-6. DOI: 10.1016/j.clinph.2012.04.030
  66. Cruse D, Chennu S, Chatelle C, Bekinschtein TA, Fernandez-Espejo D, Pickard JD, *et al.* Bedside detection of awareness in the vegetative state: a cohort study. *Lancet* 2011;378(9809):2088-94. DOI: 10.1016/S0140-6736(11)61224-5
  67. Bekinschtein TA, Coleman MR, Niklison J, 3<sup>rd</sup>, Pickard JD, Manes FF. Can electromyography objectively detect voluntary movement in disorders of consciousness? *J Neurol Neurosurg Psychiatry* 2008;79(7):826-8. DOI: 10.1136/jnnp.2007.132738
  68. Casali AG, Gosseries O, Rosanova M, Boly M, Sarasso S, Casali KR, *et al.* A theoretically based index of consciousness independent of sensory processing and behavior. *Sci Transl Med* 2013;5(198):198ra05. DOI: 10.1126/scitranslmed.3006294
  69. Massimini M, Ferrarelli F, Huber R, Esser SK, Singh H, Tononi G. Breakdown of cortical effective connectivity during sleep. *Science* 2005;309(5744):2228-32. DOI: 10.1126/science.1117256
  70. Ragazzoni A, Pirulli C, Veniero D, Feurra M, Cincotta M, Giovannelli F, *et al.* Vegetative versus minimally conscious states: a study using TMS-EEG, sensory and event-related potentials. *PLoS One* 2013;8(2):e57069. DOI: 10.1371/journal.pone.0057069
  71. Rosanova M, Gosseries O, Casarotto S, Boly M, Casali AG, Bruno MA, *et al.* Recovery of cortical effective connectivity and recovery of consciousness in vegetative patients. *Brain* 2012;135(Pt 4):1308-20. DOI: 10.1093/brain/awr340
  72. Ferrarelli F, Massimini M, Sarasso S, Casali A, Riedner BA, Angelini G, *et al.* Breakdown in cortical effective connectivity during midazolam-induced loss of consciousness. *Proc Natl Acad Sci USA* 2010;107(6):2681-6. DOI: 10.1073/pnas.0913008107
  73. Huisman TA, Loenneker T, Barta G, Bellemann ME, Hennig J, Fischer JE, *et al.* Quantitative diffusion tensor MR imaging of the brain: field strength related variance of apparent diffusion coefficient (ADC) and fractional anisotropy (FA) scalars. *Eur Radiol* 2006;16(8):1651-8. DOI: 10.1007/s00330-006-0175-8
  74. Jones DK, Dardis R, Ervine M, Horsfield MA, Jeffree M, Simmons A, *et al.* Cluster analysis of diffusion tensor magnetic resonance images in human head injury. *Neurosurgery* 2000;47(2):306-13; discussion 13-4. DOI: 10.1097/00006123-200008000-00008
  75. Huisman TA, Sorensen AG, Hergan K, Gonzalez RG, Schaefer PW. Diffusion-weighted imaging for the evaluation of diffuse axonal injury in closed head injury. *J Comput Assist Tomogr* 2003;27(1):5-11. DOI: 10.1097/00004728-200301000-00002
  76. Teasdale G, Jennett B. Assessment of coma and impaired consciousness. A practical scale. *Lancet* 1974;2(7872):81-4. DOI: 10.1016/S0140-6736(74)91639-0
  77. Huisman TA, Schwamm LH, Schaefer PW, Koroshetz WJ,



- Shetty-Alva N, Ozsunar Y, et al. Diffusion tensor imaging as potential biomarker of white matter injury in diffuse axonal injury. *AJNR Am J Neuroradiol* 2004;25(3):370-6.
78. Tollard E, Galanaud D, Perlberg V, Sanchez-Pena P, Le Fur Y, Abdennour L, et al. Experience of diffusion tensor imaging and 1H spectroscopy for outcome prediction in severe traumatic brain injury: Preliminary results. *Crit Care Med* 2009;37(4):1448-55. DOI: 10.1097/CCM.0b013e31819cf050
  79. Perlberg V, Puybasset L, Tollard E, Lehericy S, Benali H, Galanaud D. Relation between brain lesion location and clinical outcome in patients with severe traumatic brain injury: a diffusion tensor imaging study using voxel-based approaches. *Hum Brain Mapp* 2009;30(12):3924-33. DOI: 10.1002/hbm.20817
  80. Galanaud D, Perlberg V, Gupta R, Stevens RD, Sanchez P, Tollard E, et al. Assessment of white matter injury and outcome in severe brain trauma: a prospective multi-center cohort. *Anesthesiology* 2012;117(6):1300-10. DOI: 10.1097/ALN.0b013e3182755558
  81. Luyt CE, Galanaud D, Perlberg V, Vanhaudenhuyse A, Stevens RD, Gupta R, et al. Diffusion tensor imaging to predict long-term outcome after cardiac arrest: a bi-centric pilot study. *Anesthesiology* 2012;117(6):1311-21. DOI: 10.1097/ALN.0b013e318275148c
  82. Fernandez-Espejo D, Bekinschtein T, Monti MM, Pickard JD, Junque C, Coleman MR, et al. Diffusion weighted imaging distinguishes the vegetative state from the minimally conscious state. *Neuroimage* 2011;54(1):103-12. DOI: 10.1016/j.neuroimage.2010.08.035
  83. Newcombe VF, Williams GB, Scoffings D, Cross J, Carpenter TA, Pickard JD, et al. Aetiological differences in neuroanatomy of the vegetative state: insights from diffusion tensor imaging and functional implications. *J Neurol Neurosurg Psychiatry* 2010 May;81(5):552-61. DOI: 10.1136/jnnp.2009.196246
  84. Cecil KM, Hills EC, Sandel ME, Smith DH, McIntosh TK, Mannon LJ, et al. Proton magnetic resonance spectroscopy for detection of axonal injury in the splenium of the corpus callosum of brain-injured patients. *J Neurosurg* 1998;88(5):795-801. DOI: 10.3171/jns.1998.88.5.0795
  85. Choe BY, Suh TS, Choi KH, Shinn KS, Park CK, Kang JK. Neuronal dysfunction in patients with closed head injury evaluated by *in vivo* 1H magnetic resonance spectroscopy. *Invest Radiol* 1995;30(8):502-6. DOI: 10.1097/00004424-199508000-00008
  86. Marino S, Zei E, Battaglini M, Vittori C, Buscalferri A, Bramanti P, et al. Acute metabolic brain changes following traumatic brain injury and their relevance to clinical severity and outcome. *J Neurol Neurosurg Psychiatry* 2007;78(5):501-7. DOI: 10.1136/jnnp.2006.099796
  87. Ricci R, Barbarella G, Musi P, Boldrini P, Trevisan C, Basaglia N. Localised proton MR spectroscopy of brain metabolism changes in vegetative patients. *Neuroradiology* 1997;39(5):313-9. DOI: 10.1007/s002340050415
  88. Ross BD, Ernst T, Kreis R, Haseler LJ, Bayer S, Danielsen E, et al. 1H MRS in acute traumatic brain injury. *J Magn Reson Imaging* 1998;8(4):829-40. DOI: 10.1002/jmri.1880080412
  89. Friedman SD, Brooks WM, Jung RE, Chiulli SJ, Sloan JH, Montoya BT, et al. Quantitative proton MRS predicts outcome after traumatic brain injury. *Neurology* 1999;52(7):1384-91. DOI: 10.1212/WNL.52.7.1384
  90. Garnett MR, Blamire AM, Corkill RG, Cadoux-Hudson TA, Rajagopalan B, Styles P. Early proton magnetic resonance spectroscopy in normal-appearing brain correlates with outcome in patients following traumatic brain injury. *Brain* 2000;123 (Pt 10):2046-54. DOI: 10.1093/brain/123.10.2046
  91. Sinson G, Bagley LJ, Cecil KM, Torchia M, McGowan JC, Lenkinski RE, et al. Magnetization transfer imaging and proton MR spectroscopy in the evaluation of axonal injury: correlation with clinical outcome after traumatic brain injury. *AJNR Am J Neuroradiol* 2001;22(1):143-51.
  92. Uzan M, Albayram S, Dashti SG, Aydin S, Hanci M, Kuday C. Thalamic proton magnetic resonance spectroscopy in vegetative state induced by traumatic brain injury. *J Neurol Neurosurg Psychiatry* 2003;74(1):33-8. DOI: 10.1136/jnnp.74.1.33
  93. Carpentier A, Galanaud D, Puybasset L, Muller JC, Lescot T, Boch AL, et al. Early morphologic and spectroscopic magnetic resonance in severe traumatic brain injuries can detect "invisible brain stem damage" and predict "vegetative states". *J Neurotrauma* 2006;23(5):674-85. DOI: 10.1089/neu.2006.23.674
  94. Holshouser BA, Tong KA, Ashwal S, Oyoyo U, Ghamsary M, Saunders D, et al. Prospective longitudinal proton magnetic resonance spectroscopic imaging in adult traumatic brain injury. *J Magn Reson Imaging* 2006;24(1):33-40. PubMed PMID: 16755529. Epub 2006/06/07. eng. DOI: 10.1002/jmri.20607
  95. Signoretti S, Marmarou A, Fatouros P, Hoyle R, Beaumont A, Sawauchi S, et al. Application of chemical shift imaging for measurement of NAA in head injured patients. *Acta Neurochir Suppl* 2002;81:373-5. DOI: 10.1007/978-3-7091-6738-0\_94
  96. Castillo M, Kwock L, Mukherji SK. Clinical applications of proton MR spectroscopy. *AJNR Am J Neuroradiol* 1996;17(1):1-15.
  97. Wood SJ, Berger G, Velakoulis D, Phillips LJ, McGorry PD, Yung AR, et al. Proton magnetic resonance spectroscopy in first episode psychosis and ultra high-risk individuals. *Schizophr Bull* 2003;29(4):831-43. DOI: 10.1093/oxfordjournals.schbul.a007049
  98. Lewine JD, Davis JT, Sloan JH, Kodituwakku PW, Orrison WW, Jr. Neuromagnetic assessment of pathophysiologic brain activity induced by minor head trauma. *AJNR Am J Neuroradiol* 1999;20(5):857-66.