

REVIEW

Transoesophageal echocardiography (TOE): contra-indications, complications and safety of perioperative TOE

**Neil David Hauser MBChB DA(SA) MMed(Anaes) FCA(SA) FANZCA and
Justiaan Swanevelder MBChB MMed(Anes) FCA(SA) FRCA**

Department of Anaesthesia & Perioperative Medicine Groote Schuur & Red Cross Children's Hospitals, University of Cape Town, Cape Town, South Africa

Correspondence should be addressed to N D Hauser: ndhauser@gmail.com

Abstract

Transoesophageal echocardiography (TOE) has, in certain clinical situations, become an almost universal monitor and diagnostic tool. In the perioperative environment, TOE is frequently used to guide anaesthetic management and assist with surgical decision making for, but not limited to, cardiothoracic, major vascular and transplant operations. The use of TOE is not limited to the theatre environment being frequently used in outpatient clinics, emergency departments and intensive care settings. Two case reports, one of oesophageal perforation and another of TOE utilization in a patient having previously undergone an oesophagectomy, introduce the need for care while using TOE and highlight the need for vigilance. The safe use of TOE, the potential complications and the suggested contra-indications are then considered together with suggestions for improving the safety of TOE in adult and paediatric patients.

Key Words

- ▶ echocardiography
- ▶ transoesophageal echocardiography
- ▶ transoesophageal echocardiography contra-indications
- ▶ oesophagectomy
- ▶ TOE safety

Introduction

Transoesophageal echocardiography (TOE) has become an integral tool in both diagnostic and therapeutic procedures, providing real-time images of the heart via the oesophagus (1, 2, 3, 4). TOE provides unobstructed views of both cardiac structures and the great vessels. Improvements in both transducer technology and software has allowed for better image quality and greater computing power.

The use of TOE as an intraoperative monitor and diagnostic tool has become routine in most cardiac, aortic, major vascular and transplant operations, being used to aid anaesthetic management as well as assist surgical decision making (5). In addition to the perioperative environment, it is increasingly being used in the Outpatient Department, Emergency Department and Intensive Care settings

(5, 6, 7, 8, 9). TOE as a tool is proven in the diagnostic management of infective endocarditis, atrial thrombi, aortic dissection and assessment of valvular dysfunction (10, 11, 12, 13, 14).

The majority of safety recommendations and warnings surrounding the use of TOE are derived from observational studies and case reports with a limited number of randomized control trials. We present two case reports and a discussion on the utility, safety and potential complications of TOE use. The first case is that of oesophageal perforation from the TOE probe in a patient with an undiagnosed hiatus hernia and the second involves the use of TOE in a patient with an oesophagectomy presenting for mitral valve surgery.

Case 1: TOE causing oesophageal perforation

A 65-year-old male, presented with crescendo angina on minimal exertion and was diagnosed with a non-ST elevation myocardial infarction. He had a background history of type 2 diabetes mellitus (T2DM), ischaemic heart disease with a previous myocardial infarction 11 years prior, hypercholesterolaemia, hypertension and a long-standing history of smoking.

A preoperative transthoracic echo (TTE) revealed left ventricular hypertrophy with an ejection fraction of 75%, no mitral or aortic valve abnormalities and trivial tricuspid regurgitation. He was scheduled for a coronary artery bypass graft (CABG) procedure 5 days after his initial presentation. TOE is used routinely at our institution for all cardiac procedures as part of routine monitoring and patients are consented for its use.

The procedure was complicated surgically by poor targets for revascularization leading to a longer-than-expected case. Following an apparently easy and what was described as an atraumatic placement of the TOE probe, the anaesthetist had difficulty obtaining clear TOE images. The transgastric views in particular were noted as being unusual and a second cardiac anaesthetist was called on for assistance. The TOE probe was removed and reinserted presumably in an attempt to improve image quality and exclude any previously undetected damage on the TOE probe transducer that could explain the poor image quality. On removal of the probe, it was noted that there was fresh blood on the probe and further blood was suctioned from the pharynx. On reinsertion, it was still not possible to obtain good-quality views and the transgastric views in particular were still noted to be abnormal.

After the initial attempt post revascularization to separate from cardiopulmonary bypass failed, the decision was made to go back on to bypass to initiate further cardiac support. The patient stabilized after insertion of an intra-aortic balloon pump (IABP) and initiation of 0.1 µg/kg/min of adrenaline for transfer to the intensive care unit (ICU) post-operatively. Total theatre time was more than 9 h. On arrival in ICU, the attending anaesthetist noted their concerns regarding the problems with obtaining TOE images and the possibility of oesophageal injury.

The patient was taken back to theatre later that night for a re-exploration and a clot was discovered and removed from the chest. He required further blood and products post-operatively with an increased adrenaline requirement on return to ICU. The diagnosis of oesophageal perforation was made the next morning following a failed attempt at

nasogastric tube (NGT) placement and after appropriate further investigation. A gastroscopy performed in the ICU revealed an undiagnosed hiatus hernia and an oesophagogastric perforation.

The oesophagogastric perforation was initially managed conservatively with the placement of a covered gastric stent. Unfortunately, the patient became septic after a few days and developed a ventilator-acquired pneumonia, most likely due to the ongoing free reflux post stent placement. A follow-up chest CT scan revealed that a collection had developed around the perforation. Thirteen days post CABG, he returned to theatre for a thoracotomy and drainage of the peri-oesophageal collection.

The patient's time in ICU continued to be complicated as he developed a right hemiparesis, required ongoing inotropic support, failed attempts at extubation and remained dependent on the IABP support. His pneumonia continued to worsen with ongoing subclinical aspirations. Despite drainage of the peri-oesophageal collection, he developed worsening sepsis and passed away in ICU on day 25 post surgery.

This case highlights the potentially devastating consequences of an oesophageal perforation following the use of TOE. The inability to obtain clear TOE images (transgastric in particular), and the presence of fresh blood on removal of the TOE probe, should alert the clinician to a potential oesophageal perforation as part of their differential diagnosis. In this case, the undiagnosed hernia may have further contributed to the difficulty obtaining good TOE images. In addition to pre-existing patient risk factors, as discussed below, excessive TOE probe manipulation and the need for a prolonged period of cardiopulmonary bypass (CPB) are further risk factors for TOE-associated oesophageal perforation. Despite the prompt diagnosis of oesophageal perforation and the institution of appropriate management, the associated risks of oesophageal perforation are brought to the attention of the reader. In this case, despite the early diagnosis, the patient unfortunately did not recover after surgery.

Case 2: TOE in a patient with previous oesophagectomy

An active 67-year-old male presented with recent onset of impaired effort tolerance, dyspnoea, orthopnea and paroxysmal nocturnal dyspnoea. His previous medical history included an oesophagectomy and left upper

lobectomy via left thoracotomy for oesophageal cancer 6 years prior to this presentation. Post oesophagectomy, a surveillance gastroscopy was done with successful dilation of a stricture. There was no history of severe reflux or excessive symptoms of gastrointestinal inflammation. The patient was a retired cardiologist from the same institution, and he gave full consent for his case to be reported.

Cardiac examination and transthoracic echocardiography diagnosed severe mitral valve regurgitation (MR) because of prolapse of his posterior mitral valve leaflet. A mutual cardiology and surgical decision was made to proceed with a minimally invasive mitral valve repair procedure via right-side minithoracotomy, performed by a surgeon experienced in this technique.

There was a strong team feeling that the patient would benefit from an intraoperative TOE to guide surgical management and intraoperatively confirm a successful procedure. Careful and critical consideration was given to the risks and benefits of TOE probe placement and manipulation in this patient in light of his previous surgical history. All surgical discussions included the thoracic surgeon who performed this patient's lobectomy and oesophagectomy procedures. Opinion was that because the oesophagus was removed and part of the stomach, with its larger lumen, was in the patient's thorax this would simplify TOE probe placement and make it atraumatic. A gastroscopy was not performed prior to surgery although it is acknowledged that this may have guided the risk of TOE placement. The patient and his close relatives were well informed of all risks and were included in discussions throughout the surgical planning stages. Informed written consent for surgery, anaesthesia and TOE was obtained. While epicardial echocardiography may have been helpful with the intraoperative management, the surgical and anaesthetic teams both felt that the images from epicardial echocardiography would not have been able to provide the same degree of continuous detail that was obtainable through the use of TOE.

After induction of anaesthesia, the patient remained hemodynamically stable. The 3D TOE transducer (Vivid E9) was placed carefully without any difficulty. There was no resistance to either its placement or manipulation. Interesting and unfamiliar TOE views were observed, with no clear mid-oesophageal views obtainable. The usual upper oesophageal short- and long-axis views of the big vessels were observed. When the transducer was advanced from there, it would go straight into hybrid transgastric short- and long-axis views (Figs 1, 2, 3, 4 and 5).

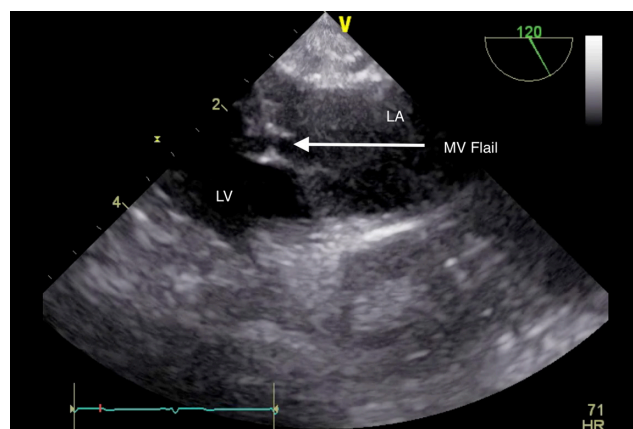


Figure 1

A hybrid mid-oesophageal long-axis view of the LVOT demonstrating the flail P2 scallop of the posterior mitral valve leaflet, due to the ruptured chordae tendineae. Arrow pointing at regurgitant orifice due to poor coaptation. LA, left atrium; LV, left ventricle.

These views were noted to be at unusual angles due to the displaced cardiac anatomy from previous thoracic surgeries.

The mitral valve was carefully assessed before and after CPB. The preoperative examination confirmed severe MR because of prolapse of the posterior mitral valve leaflet. A flail posterior leaflet P2 scallop (Figs 1 and 2), due to chorda tendineae rupture (Figs 3 and 4), was clearly demonstrated. There was a severe eccentric regurgitant jet present, going into an anterior direction (Fig. 6). Severity was confirmed by demonstrating systolic flow reversal in the pulmonary veins (Fig. 5), and a vena contracta of more than 7 mm diameter. Ventricular systolic function was

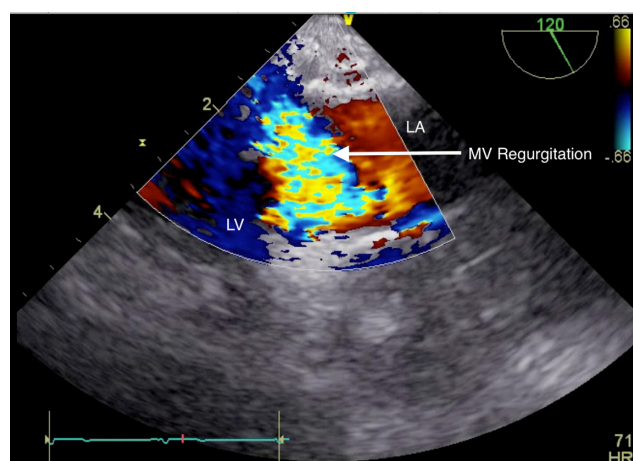


Figure 2

A hybrid mid-oesophageal long-axis view of the LVOT demonstrating the flail P2 scallop of the posterior mitral valve leaflet, due to the ruptured chordae tendineae. Arrow pointing at regurgitant jet identified with colour Doppler. LA, left atrium; LV, left ventricle; MV, mitral valve.

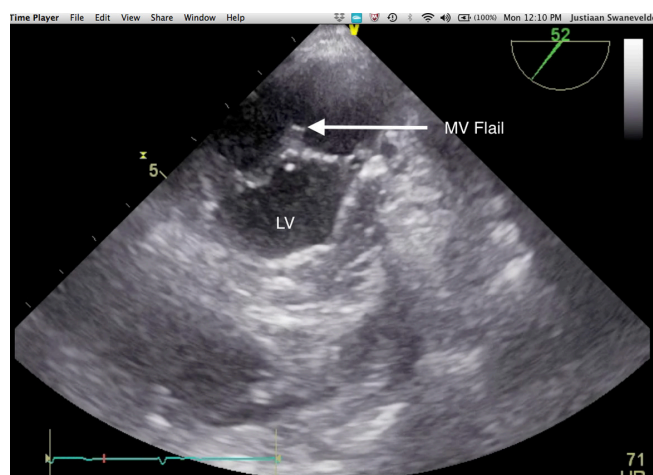


Figure 3

A hybrid mid-oesophageal commissural view of the mitral valve with arrow pointing at the prolapsing mitral valve P2 scallop with flailing chordae tendineae. LV, left ventricle; MV, mitral valve.

preserved with only moderate pulmonary regurgitation present (Fig. 7). A small left atrium indicated fairly acute/recent chordal rupture and MR.

The mitral valve procedure was uneventful and completed in a minimally invasive videoscope-assisted fashion via a right-side minithoracotomy. The mitral valve was repaired with two artificial Goretex chordae and a size 32 annuloplasty ring. The patient was separated from CPB without problems, on minimal inotropic support, and after heparin reversal, the minithoracotomy incisions were closed. TOE confirmed a successful repair with no residual regurgitation under normal loading conditions.

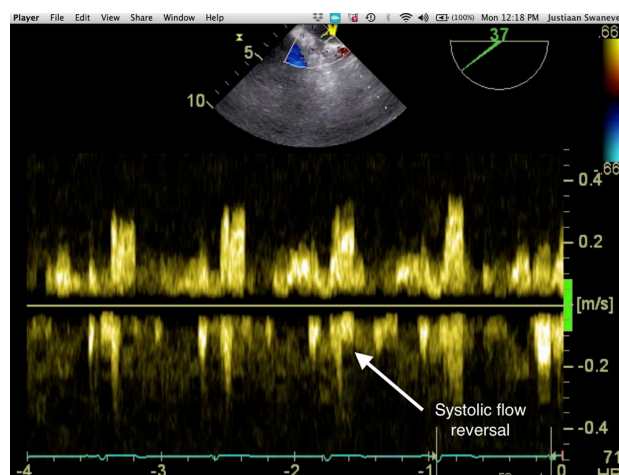


Figure 5

Systolic flow reversal in the left upper pulmonary vein, indicating severe mitral regurgitation.

The valve was competent with no pathological pressure gradient/drop across it. The annuloplasty ring was well seated. The TOE transducer was removed in the operating theatre and inspected for blood or signs of bleeding, neither of which was observed.

After the patient woke up in ICU a few hours post surgery, and his airway was extubated, a careful history and communication showed no evidence of injury to the patient's neo-oesophagus/upper gastrointestinal system. The patient started to take small sips of clear fluids a few hours post surgery and soon after that soft food, without any complications. The patient was discharged from hospital after 5 days and intermittently followed up

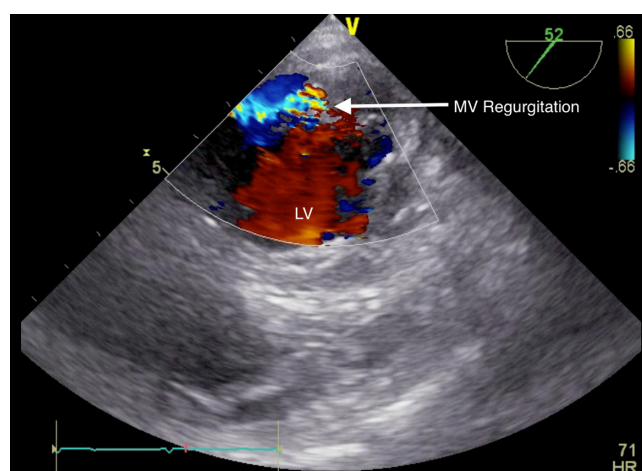


Figure 4

A hybrid mid-oesophageal commissural view of the mitral valve with arrow pointing at the regurgitant colour Doppler jet of the prolapsing mitral valve P2 scallop with flailing chordae tendineae. LV, left ventricle; MV, mitral valve.

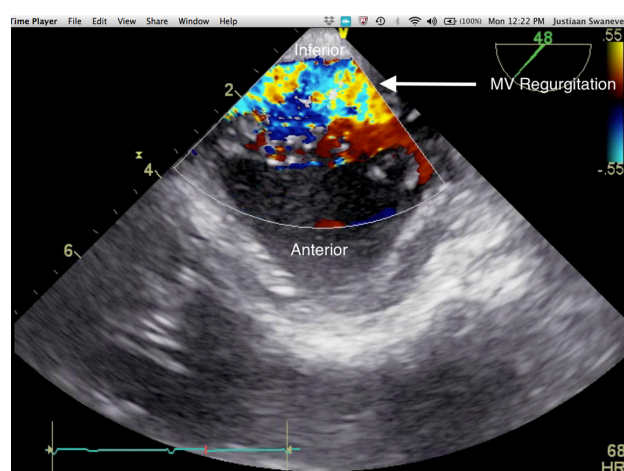


Figure 6

A hybrid mid-oesophageal short-axis view of the left ventricle, at 40°, with colour Doppler demonstrating mitral valve regurgitant jet, en face. MV, mitral valve.

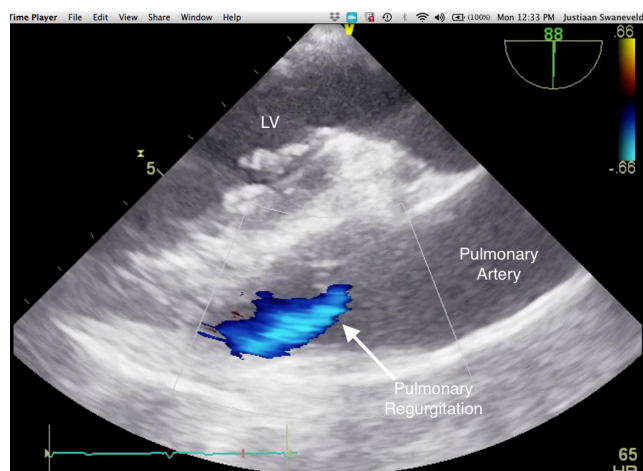


Figure 7

A hybrid mid-oesophageal 2-chamber view with colour Doppler demonstrating moderate pulmonary regurgitation subsequent to pulmonary hypertension caused by acute severe mitral regurgitation. LV, left ventricle.

over the next month, with no indication of any further cardiac, thoracic or upper gastrointestinal complications.

This case highlights the importance that when indicated, a TOE examination is possible in a patient with a previous oesophagectomy or oesophago-gastrectomy. It is important to always consider the risk-benefit ratio of TOE in this subgroup of patients. This is particularly relevant when TOE is crucial to a successful outcome, such as in this case of surgical mitral valve repair. Similarly in any other situation where TOE may be lifesaving, its use should be critically considered where potential contra-indications exist. To the best of our knowledge, this is the first report in which TOE has been done in a patient after a previous oesophagectomy. See accompanying figures (Figs 1, 2, 3, 4, 5, 6 and 7) and video clips (Videos 1, 2, 3, 4, 5 and 6).

Video 1

A hybrid mid-oesophageal long-axis view of the LVOT demonstrating the flail P2 scallop of the posterior mitral valve leaflet, due to the ruptured chordae tendineae. View Video 1 at <http://movie-usa.glencoesoftware.com/video/10.1530/ERP-18-0047/video-1>.

Video 2

A hybrid mid-oesophageal long-axis view of the LVOT demonstrating the flail P2 scallop of the posterior mitral valve leaflet, due to the ruptured chordae tendineae. View Video 2 at <http://movie-usa.glencoesoftware.com/video/10.1530/ERP-18-0047/video-2>.

Video 3

A hybrid mid-oesophageal commissural view of the mitral valve with arrow pointing at the prolapsing mitral valve P2 scallop with flailing chordate tendineae. View Video 3 at <http://movie-usa.glencoesoftware.com/video/10.1530/ERP-18-0047/video-3>.

Video 4

A hybrid mid-oesophageal commissural view of the mitral valve with arrow pointing at the regurgitant colour Doppler jet of the prolapsing mitral valve P2 scallop with flailing chordae tendineae. View Video 4 at <http://movie-usa.glencoesoftware.com/video/10.1530/ERP-18-0047/video-4>.

Video 5

A hybrid mid-oesophageal short-axis view of the left ventricle, at 40 degrees, with colour Doppler demonstrating mitral valve regurgitant jet, en face. View Video 5 at <http://movie-usa.glencoesoftware.com/video/10.1530/ERP-18-0047/video-5>.

Video 6

A hybrid mid-oesophageal 2-chamber view with colour Doppler demonstrating moderate pulmonary regurgitation subsequent to pulmonary hypertension caused by acute severe mitral regurgitation. View Video 6 at <http://movie-usa.glencoesoftware.com/video/10.1530/ERP-18-0047/video-6>.

Contra-indications to TOE

According to the 'Practice Guidelines for Perioperative Transesophageal Echocardiography' published by the American Society of Anesthesiologists (ASA), there is insufficient literature evidence to determine whether there should be prescribed absolute contra-indications to the use of TOE (15). It is however suggested and widely held by consultants and members of the ASA that the following four conditions may be regarded as potential contra-indications to the use of TOE: (1) Pre-existing gastro-oesophageal pathology e.g. stricture, trauma, diverticulum, tumour, (2) tracheo-oesophageal fistula, (3) recent upper gastrointestinal surgery and (4) oesophagectomy or oesophagogastrectomy (5). A greater number of relative contra-indications exist (Table 1), and there appears to be agreement upon these in the literature (5, 15, 16). The authors suggest that due to a

Table 1 Potential absolute and relative contra-indications to TOE.

Absolute contra-indications	Relative contra-indications
Oesophageal stricture	Oesophageal/gastric varices
Trachea-oesophageal fistula	Barrets oesophagus
Oesophageal trauma	Zencker's diverticulum
Oesophageal surgery/esophagectomy	Oesophageal carcinoma
Perforated viscus	Previous thoracic radiotherapy
	Mallory-Weiss tear
	Colonic interposition
	Previous bariatric surgery
	Dysphagia
	Coagulopathy/bleeding disorder
	Atlanto-axial joint disease limiting cervical mobility
	Severe cervical osteoarthritis
	Thoracic aortic aneurysm

lack of consensus in the published literature, together with disagreement between experts and opinion leaders as to what constitutes an absolute contra-indication to TOE, that all contra-indications should rather be viewed as relative and evaluated on a case-by-case basis. Where concern exists regarding the presence of a potential risk factor when using TOE, we suggest that a discussion is held between all parties involved. This discussion should include the patient and/or family where possible, prior to undertaking the TOE examination.

Complications associated with TOE

The use of TOE is generally considered to be safe, with the benefits and information derived outweighing the risks associated with this tool. TOE is however not without potential complications. The most devastating complication is undoubtedly oesophageal perforation, suggested to occur in 0.01–0.09% of cases dependent on the underlying patient risk factors present (17, 18). A task force created to investigate complications associated with perioperative TOE, suggest an incidence of <3% dependent on the specific complication (15). It is suggested that TOE is comparable to routine upper gastrointestinal (UGI) endoscopy in terms of safety profile, with UGI Endoscopy shown to have a complication rate of 0.08–0.13% and mortality rate of 0.004% (16, 17, 19, 20, 21).

Complications related to the use of TOE can be broadly divided into minor traumatic injuries, often related to the insertion of the TOE probe, and broader more complex injuries with considerably greater morbidity. Minor traumatic injuries that may occur from the use of TOE are listed in Table 2.

The risk of dental trauma is a concern for practitioners when performing TOE with an incidence of 0.03–0.1%

reported in the literature (15, 16). This risk is logically increased in patients with poor dentition and those with identifiably loose teeth. Documentation of loose teeth, caps or crowns and a discussion of the risk of dental damage with patients prior to the procedure is always important. The use of a disposable single use 'gum-guard' and/or mouthpiece may decrease the risk of dental damage in these patients. These protective devices should be placed before any sedation is administered for the procedure, adding to patient comfort and decreasing both the risk of damaging teeth and the TOE probe. Documentation of any dental injury should be made at the end of the procedure. Equally important is the documentation of no visible identifiable injury and confirmation that any tooth identified as being loose pre-procedure has remained in place.

Gastro-oesophageal perforation

Gastro-oesophageal perforation is the complication most likely associated with the greatest degree of morbidity and mortality from the use of TOE (5, 17, 22). It appears from the literature that the exact incidence of gastro-oesophageal perforation is unknown and can vary from as low as 0.01% up to as high as 2.2% (16, 18, 23, 24). Fortunately from larger series studies, it appears that this complication is rare, with as stated above an incidence of 0.01–0.09% (17, 18, 23). This translates to 1–9 perforations per 10,000 TOE studies.

Pre-existing gastro-oesophageal pathology, abnormal anatomy and multiple attempts at probe insertion all appear to increase the risk of perforation (25, 26, 27). Other possible, but as of yet unproven, risk factors for perforation are listed in Table 3.

Although the presence of a pre-existing symptomatic hiatal hernia or pharyngeal pouch are both recognised as potential risk factors for oesophageal perforation,

Table 2 Minor injuries associated with TOE.

Site of injury	Injury
Oral	Lip bruising and laceration Tongue laceration and minor swelling Dental chipping Dental loosening Denture displacement Hoarseness
Oesophagus	Minor laceration Odynophagia Mallory-Weiss with limited gastrointestinal bleeding only
Gastric	Minor laceration with limited gastrointestinal bleeding only
Cardiovascular	Self-limiting arrhythmia without haemodynamic compromise

the practice guidelines for TOE utilisation indicate that there is disagreement amongst members and consultants as to whether these conditions should be viewed as an absolute contra-indication to TOE use (15). Upper gastrointestinal endoscopy may be considered for patients with known risk factors (like previous oesophageal surgery) to identify features that may preclude a subsequent TOE examination, for example the presence of a residual stricture/narrowing as these may alter management (28).

Anatomy of oesophageal perforation

The area of the oesophagus most frequently perforated depends largely on whether the TOE is performed in an operative or non-operative setting. The majority of operative TOE associated oesophageal perforations occur in the thoraco-abdominal oesophagus (27). Non-operative TOE perforation is more likely to occur in the cervico-pharyngeal segments of the oesophagus and is related to the insertion of the TOE probe in a patient with largely intact gag reflexes and essentially normal muscle tone (24).

Mechanism of perforation

The most likely reason for a gastro-oesophageal perforation is due to direct mechanical trauma related to probe size selection, insertion and/or manipulation once inserted (16). Indirect mechanical trauma has also been described in a case report, as a reason for oesophageal perforation (22). Presumably compression of susceptible tissues at the probe-mucosal interface results in pressure necrosis and resultant perforation (29, 30).

Thermal injury has been suggested as another mechanism for gastro-oesophageal perforation. Thermal energy generated by the piezo-electric crystal at the probe tip is transferred to susceptible, presumably

severely atherosclerotic tissue within a compromised circulation. The resultant tissue heating ultimately leads to perforation (22). It must however be noted that this model of perforation has never been demonstrated in animal studies (31), and it is thought that the presence of severe atherosclerosis is a prerequisite for this thermal effect to occur.

The suggested mechanisms of operative perforation include prolonged probe tip contact with the oesophageal mucosa and probe manipulation through maximal antegrade flexion of the probe tip to obtain a short-axis (SAX) view through the left and right ventricles (32). With respect to the mechanism of prolonged contact, the low perfusion states of tissues during CPB in particular predisposes to ischaemia and subsequent tissue necrosis (27). Antegrade probe flexion results in a very localized pressure point in the oesophagus, or at the gastro-oesophageal junction, increasing the risk of hypoperfusion and subsequent tissue disruption. Intraoperatively, when the probe is not being used to obtain views, it is recommended that the user pull it back into the cervical oesophagus. Furthermore, limiting the number of attempts at obtaining SAX views decreases the risk of antegrade flexion perforation (27). Depth manipulation in the oesophagus, as well as rotational manipulation of the transducer should be minimized and

Table 3 Factors contributing to the risk of oesophageal perforation (18, 28, 29).

Risk factor for TOE perforation
Short stature
Chronic steroid usage
Longer operative time
Longer bypass time
Congestive cardiac failure
Low cardiac output states pre- and post-cardiopulmonary bypass, hypothermia and hypothermic bypass
Older age

kept as gentle as possible. This should be considered by TOE users when obtaining additional right heart views (33) as further probe manipulation may further increase risk. This may be particularly important in the presence of a hiatus hernia, as mentioned earlier and illustrated in case 1, as these additional views are obtained from transgastric and deep transgastric positions. It is potentially less damaging to the oesophageal and gastric mucosa if angle rotation is only performed after correct positioning of the transducer, in relation to the cardiac structure about to be examined.

Detection of oesophageal perforation

In patients with known risk factors, a high index of suspicion must be maintained post procedure in both the operative and non-operative setting. Importantly, the absence of risk factors does not preclude the risk of oesophageal perforation; as shown in one systematic review on TOE-induced oesophageal perforation, 60% of patients had no risk factors present (27). Any patient presenting immediately after a TOE examination with tachypnea, a pneumothorax, a pleural effusion, subcutaneous emphysema or excessive orogastric haemorrhage should have the diagnosis of oesophageal perforation as part of their differential (5). Further as highlighted by Case 1 the unexpected inability to obtain clear TOE images should also prompt the clinician to the potential of an oesophageal perforation.

It is more likely that there will be a delay in detection in patients undergoing an operative TOE examination, as the above-described findings may either be masked or attributed to another reason in the post-operative period. Multiple modalities can be used to confirm the diagnosis of perforation and may include a chest radiograph, CT, gastrografin swallow and/or fluoroscopic examination.

Treatment of a TOE-induced oesophageal perforation

A number of studies recommend that a primary surgical repair and drainage be undertaken for TOE-induced oesophageal perforation, and this recommendation remains even if the diagnosis is made beyond 24h (27). It is believed that TOE-induced perforations are more amenable to primary repair due to the fact that these oesophageal perforations are small, less contaminated and have relatively preserved surrounding tissue (34, 35, 36, 37).

Gastro-oesophageal haemorrhage

The majority of cases of gastrointestinal bleeding following the use of TOE are minor and self-limiting. These cases typically result from direct orogastric mucosal damage or damage to associated friable tissue (5). Very rarely, bleeding is serious, resulting in major blood loss and haemodynamic compromise. Serious bleeding attributable to TOE is estimated to occur in 0.03% of cases (16). The presence of oesophageal varices increases the risk of major haemorrhage and for this reason it is suggested that varices are a relative contra-indication to TOE examination. This is despite there being no reports of procedure-related complications in patients with known varices (5) and provided that adequate surveillance and prior gastroscopy is undertaken before the TOE examination (38).

Bleeding may be further exacerbated by the anticoagulants employed to facilitate CPB. This is supported by a number of case reports describing an exacerbation of mucosal bleeding following heparinization for CPB (16, 39). Despite the theoretical increased bleeding risk associated with anticoagulation, studies have failed to demonstrate an increased risk for gastrointestinal bleeding post TOE examination in the setting of anticoagulation (5). In addition to the limited literature supporting the increased risk of TOE and anticoagulants, cardiac surgery itself is associated with an increased risk of gastrointestinal bleeding making it difficult to separate the exact contribution made by TOE to post-procedural bleeding. This is supported by studies comparing patients followed prospectively after undergoing cardiac surgery with TOE against controls retrospectively having undergone cardiac surgery without TOE (40, 41). Both studies failed to show that TOE increased the risk of bleeding or was an independent predictor of major gastrointestinal morbidity.

Swallowing dysfunction and TOE

Swallowing difficulty post cardiac surgery has been noted in previous studies (19, 29, 30, 42). The consequences of swallowing difficulty may significantly impact on a patient's recovery from cardiac surgery, increasing the need for additional procedures, hospital length of stay and respiratory complication post cardiac surgery (42). Hogue *et al.*, in a series of 869 patients, demonstrated that intraoperative TOE utilisation was an independent predictor of swallowing difficulty post cardiac surgery

(42). Similarly Rousou *et al.* demonstrated in their series of 868 consecutive cardiac surgeries that the use of TOE was independently associated with an increased risk of dysphagia and swallowing difficulties (43). This series demonstrated that the use of TOE was a stronger predictor of dysphagia than duration of intubation. The combination of reduced pharyngeal patency, hypothermia, poor perfusion on CPB, tissue compression between the ETT and the TOE probe, trauma on insertion and the presence of the rigid TOE probe left in the oesophagus during surgery were suggested as potential aetiologies for injury (44, 45).

It should be noted that in both of the above studies, the use of TOE was more prevalent in patients that were assessed as being sicker and having a lower left ventricular ejection fraction and were thus more likely to also exhibit two other independent predictors of dysphagia, namely an increase in age and a longer period of tracheal intubation. Indeed dysphagia following cardiac surgery may be due to a number of other factors. After cardiac surgery neurological dysfunction in particular is almost three times more likely to result in dysphagia than the use of TOE (43). In addition to this, not all studies have shown a correlation between the use of TOE and the development of dysphagia with a number of negative studies having been published in this regard (40, 46).

Safety of TOE

As mentioned above, the complication rate and safety associated with the use of TOE is comparable to that of routine gastroscopy (20, 21). Complication rates appear to be similar whether TOE is performed in the operative or non-operative setting, although as highlighted previously, the anatomical areas of injury appear to differ in the two settings (16, 40, 42, 47).

The risk of minor injury varies between 0.1 and 13% depending on the complication under investigation (15, 16), with the majority of studies investigating minor complications being limited by their low numbers. Reporting bias is inevitable in procedure-related complications, with surviving patients being more frequently reported in the literature. This may lead to under-estimation of the true incidence or over-estimation of rare complications.

In order to increase the safety of perioperative TOE, the British Society of Echocardiography (BSE) together with the Association of Cardiothoracic Anaesthetists have endorsed a safety checklist intended specifically for use

with TOE, particularly when TOE is performed outside of the surgical theatre where there is almost universal use of the World Health Organisation (WHO) Surgical Safety Checklist (47).

The BSE-endorsed TOE safety checklist is divided into five sections and the resemblance to the WHO checklist can be clearly seen:

1. *Sign-in and patient checks:* The completion of this subsection occurs with an awake patient and its content includes but is not limited to the patient's details, their consent, presence of risk factors, presence of potential contra-indications and functioning monitoring.
2. *Time out – immediately pre-procedure:* Team members confirm their name and role, patients name and the procedure to be performed as well as any anticipated problems with sedation or equipment issues.
3. *Sign-out – post procedure:* Confirmation of the procedure performed as well as collection of the necessary images. The specific sedative drugs that have been used are noted as well as their dose and the name of the person administering the medication.
4. *Team member signatures:* The names and signatures of all involved are then recorded at the end.
5. *General anaesthesia appendix:* A brief record of airway, aspiration and other anaesthesia concerns may be recorded in the appendix together with monitoring employed, ASA grade and resuscitation equipment.

This checklist can be adapted and modified to suit the needs of any unit and serves as a template to ensure that important information is documented and concerns are noted by all involved in the procedure. Application of a checklist for TOE examinations may decrease associated complications.

Certain basic steps can be taken to decrease the risk of complications associated with TOE examination thereby increasing the safety of TOE:

- Reviewing of patient's existing medical records will identify any existing pathology, which may increase risk of pharyngeal or oesophageal damage. This should be done both in the theatre and outpatient settings. Again, the absence of risk factors does not eliminate the risk of TOE-associated injury.
- Continuous monitoring of oxygen saturation, ECG and blood pressure should take place throughout TOE procedures. This is standard in theatre and should be applied to any sedated patient undergoing TOE examination in any environment outside of theatre.

- Adhering to local fasting guidelines before TOE procedures will decrease the risk of aspiration.
- Oral local anaesthetic spray, particularly in the outpatient setting, together with adequate lubrication of the transducer will facilitate placement and comfort of the patient.
- Transducer must at all times be introduced in the unlocked position and carefully guided during placement in oesophagus. The use of a laryngoscope may aid TOE probe placement in the oesophagus.
- Avoid forceful insertion and manipulation against resistance.
- Use direct visualization of the oesophagus with a laryngoscope or video-laryngoscope when meeting resistance during probe placement. This is more easily achieved in anaesthetized patients but with adequate topicalization and sedation, this may be safely achieved in the outpatient setting.
- In a patient with a tracheostomy, deflate tracheostomy cuff during transducer placement.
- Endotracheal tube (ETT) or double lumen tube (DLT) cuff pressures should be carefully and frequently monitored when a TOE probe is in the oesophagus. Limiting excessive cuff pressure will ensure oesophageal mucosal perfusion is preserved, potentially decreasing a mucosal-probe interface pressure point. The ETT or DLT cuff may also be deflated on insertion of the probe provided there is no risk of aspiration or lung contamination respectively. During periods of low tissue perfusion, as seen with CPB, excessive ETT/DLT cuff pressure may decrease oesophageal mucosal perfusion increasing the potential risk of oesophageal perforation. In one study investigating changes in cuff pressure on CPB in congenital heart surgery, it was shown that cuff pressures decreased on hypothermic CPB (48). Similar results have been noted in adult patients (49, 50) and although this may be protective against poor oesophageal mucosal perfusion, the risk of silent aspiration or lung contamination exists. These findings may suggest a measure of safety with insufflated cuffs on CPB and a decision must be made on a case-by-case basis as to whether or not the cuff should be deflated. In light of the above studies, we do not suggest deflating the cuff.
- Remove nasogastric tube when placing transducer.
- During CPB – freeze image or turn off echo machine to prevent thermal damage, keep probe in neutral position and unlocked.
- When not in use, withdraw transducer into the midoesophagus.

Use of TOE where the benefits may outweigh potential risks perioperatively

The use of TOE in cardiac surgery is almost universal. It has become an integral monitoring and diagnostic tool for both the surgeon and the anaesthetist. Transesophageal echo is able to guide the surgeon, influence the anaesthetist's decision making, as well as assess the effectiveness of the cardiovascular surgical correction against the patient's preoperative pathology. This allows the surgeon to revise repairs, change approach and potentially improve patient outcome. Routine TOE is considered to be a cost-effective and clinically beneficial tool in cardiac surgery (1, 4, 51, 52).

In the presence of a potential contra-indication transthoracic echocardiography (TTE) may provide vital information and due to its non-invasive nature, it would be suggested as the first approach. Alternatively, intraoperative epicardial echocardiography may also be used. There are however times when TTE will not provide adequate information or may not be feasible. In a patient with potential TOE contra-indications, but where the benefits outweigh the risks, we suggest that the patient is fully informed about the risk, and the appropriate consent is recorded as with all TOE procedures.

TOE assessment of valvular and ventricular function pre and post valvular repair or replacement surgery can alter surgical decision making. Similarly, assessment of global cardiac function and regional wall motion abnormalities during coronary artery bypass surgery can demonstrate the effectiveness of the graft, as TOE is twice as sensitive as ECG in detecting left ventricular ischaemia (53). Impact studies have shown a benefit in the use of TOE in life-threatening unexplained hypoxemia and hypotension as well as assisting in determining the cause of unexplained cardiac arrest (54, 55).

In non-cardiac surgery, TOE usage has also become more common. Vascular and neuroanaesthetists, trauma and intensive care physicians are either beginning to or have incorporated TOE in their practice. During vascular surgery, TOE can be used to aid selection of the landing site for endovascular aneurysm repair (EVAR) grafts. TOE has been shown in one series to influence the landing site in up to 33% of patients (56). Real-time tracking of guidewires eliminates placement in false lumens, minimizing morbidity and increasing the safety profile of vascular surgery.

As skill with TOE continues to improve in a number of areas of clinical practice, its perioperative use will increase. Increasingly, as more anaesthetists incorporate TOE in their practice, more patients with potential

contra-indications to its use will present for procedures. Careful assessment is necessary and full discussion with the patient is mandatory, but many of these contra-indications should really be viewed as relative in light of potential management changing information that can be obtained with this equipment.

Use of TOE in paediatric populations

It is perhaps less likely that paediatric patients have contra-indications to TOE, but their presence should be considered at all times. A similar risk-benefit strategy should be employed and discussed with the parents, and where appropriate, the patient pre-operatively. With the development of technology and the miniaturization of ultrasound probes, TOE use has also become more routine practice in paediatric cardiothoracic surgery, particularly as more complex congenital cardiac corrections are attempted.

TOE provides valuable real-time information to both the surgical and anaesthesia teams during these procedures, where assessment of the surgical correction is seen as mandatory (5). Catheter laboratory analysis of congenital abnormalities can be compared directly to corrective surgical procedures via TOE assessment in theatre. Gradients can be measured when shunts are placed and real-time haemodynamic effects can be seen.

Most interventional procedures in the paediatric population are performed under general anaesthesia. As illustrated above, this may result in a specific injury pattern in terms of insertion and risk of oesophageal perforation (24) and the same considerations should be remembered after any TOE examination in a child.

Despite the decrease in size and diameter of paediatric TOE probes, due to anatomical development or rather lack thereof, paediatric patients are more susceptible to the compressive effects of a hard ultrasound probe on mediastinal and vascular structures, as well as upper airways during probe insertion (57, 58, 59). Cardiovascular collapse, complete airway occlusion, endotracheal tube dislodgement or disturbance of its position, may all occur. The anaesthetist needs to be aware of these potential complications related to TOE use. Anecdotally and understandably, it appears that mediastinal compression tends to occur more commonly in smaller patients, and those with abnormal vascular anatomy (5).

In order to limit complications associated with TOE usage in children, it is recommended that specific paediatric probes be used in children weighing less than 20 kg. When care is taken, the complication rate for TOE

utilization in children is not significantly different in terms of oesophageal perforation or haemorrhage (60, 61).

Conclusion

The utility of TOE continues to expand as more disciplines include it in their practice. Real-time information provides anaesthetists and surgeons with valuable information intraoperatively. In the outpatient environment, TOE continues to aid clinicians diagnostically and therapeutically. Awareness of the potential complications and the risks associated with the use of TOE is important in terms of providing a safe procedure for patients. Taking steps to limit the complications and recognizing them early if they do occur may help improve patient outcomes. Recognizing potential contra-indications and approaching them with a risk-benefit type strategy with appropriate caution can similarly result in successful outcomes.

Declaration of interest

The authors declare that there is no conflict of interest that could be perceived as prejudicing the impartiality of this review.

Funding

This work did not receive any specific grant from any funding agency in the public, commercial, or not-for-profit sector.

References

- 1 Click RL, Abel MD & Schaff HV. Intraoperative transesophageal echocardiography: 5-year prospective review of impact on surgical management. *Mayo Clinic Proceedings* 2000 **75** 241–247. ([https://doi.org/10.1016/S0025-6196\(11\)65027-1](https://doi.org/10.1016/S0025-6196(11)65027-1))
- 2 Mishra M, Chauhan R, Sharma KK, Dhar A, Bhise M, Dhole S, Omar A, Kasliwal RR & Trehan N. Real-time intraoperative transesophageal echocardiography – how useful? Experience of 5016 cases. *Journal of Cardiothoracic and Vascular Anesthesia* 1998 **12** 625–632. ([https://doi.org/10.1016/S1053-0770\(98\)90232-4](https://doi.org/10.1016/S1053-0770(98)90232-4))
- 3 Eltzschig HK, Shernan SK & Rosenberger P. Ischemic mitral regurgitation during temporary coronary artery ligation. *New England Journal of Medicine* 2004 **350** 2424–2425. (<https://doi.org/10.1056/NEJM200406033502323>)
- 4 Eltzschig HK, Rosenberger P, Löffler M, Fox JA, Aranki SF & Shernan SK. Impact of intraoperative transesophageal echocardiography on surgical decisions in 12,566 patients undergoing cardiac surgery. *Annals of Thoracic Surgery* 2008 **85** 845–852. (<https://doi.org/10.1016/j.athoracsur.2007.11.015>)
- 5 Hilberath JN, Oakes DA, Shernan SK, Bulwer BE, D'Ambra MN & Eltzschig HK. Safety of transesophageal echocardiography. *Journal of the American Society of Echocardiography* 2010 **23** 1115–1127. (<https://doi.org/10.1016/j.echo.2010.08.013>)
- 6 Heidenreich PA. Transesophageal echocardiography (TEE) in the critical care patient. *Clinical Cardiology* 2000 **18** 789–805. ([https://doi.org/10.1016/S0733-8651\(05\)70180-6](https://doi.org/10.1016/S0733-8651(05)70180-6))

- 7 Yong Y, Wu D, Fernandes V, Kopelen HA, Shimoni S, Nagueh SF, Callahan JD, Bruns DE, Shaw LJ, Quinones MA, et al. Diagnostic accuracy and cost-effectiveness of contrast echocardiography on evaluation of cardiac function in technically very difficult patients in the intensive care unit. *American Journal of Cardiology* 2002 **89** 711–718. ([https://doi.org/10.1016/S0002-9149\(01\)02344-X](https://doi.org/10.1016/S0002-9149(01)02344-X))
- 8 Schmidlin D, Schuepbach R, Bernard E, Ecknauer E, Jenni R & Schmid ER. Indications and impact of postoperative transesophageal echocardiography in cardiac surgical patients. *Critical Care Medicine* 2001 **29** 2143–2148. (<https://doi.org/10.1097/00003246-200111000-00016>)
- 9 Tousignant CP, Walsh F & Mazer CD. The use of transesophageal echocardiography for preload assessment in critically ill patients. *Anesthesia and Analgesia* 2000 **90** 351–355.
- 10 Yvorchuk KJ & Chan KL. Application of transthoracic and transesophageal echocardiography in the diagnosis and management of infective endocarditis. *Journal of the American Society of Echocardiography* 1994 **7** 294–298. ([https://doi.org/10.1016/S0894-7317\(14\)80400-8](https://doi.org/10.1016/S0894-7317(14)80400-8))
- 11 Michelena HI, Abel MD, Suri RM, Freeman WK, Click RL, Sundt TM, Schaff HV & Enriquez-Sarano M: Intraoperative echocardiography in valvular heart disease: an evidence-based appraisal. *Mayo Clinic Proceedings* 2010 **85** 646–655. (<https://doi.org/10.4065/mcp.2009.0629>)
- 12 Klein AL, Obarski TP, Stewart WJ, Casale PN, Pearce GL, Husbands K, Cosgrove DM & Salcedo EE. Transesophageal Doppler echocardiography of pulmonary venous flow: a new marker of mitral regurgitation severity. *Journal of the American College of Cardiology* 1991 **18** 518–526. ([https://doi.org/10.1016/0735-1097\(91\)90609-D](https://doi.org/10.1016/0735-1097(91)90609-D))
- 13 Yalcin F, Thomas JD, Homa D & Flachskampf FA. Transesophageal echocardiography: first-line imaging for aortic diseases. *Cleveland Clinic Journal of Medicine* 2000 **67** 417–418, 421–428. (<https://doi.org/10.3949/ccjm.67.6.417>)
- 14 Manning WJ, Weintraub RM, Waksmonski CA, Haering JM, Rooney PS, Maslow AD, Johnson RG & Douglas PS. Accuracy of transesophageal echocardiography for identifying left atrial thrombi. A prospective, intraoperative study. *American College of Physicians* 1995 **123** 817–822. (<https://doi.org/10.7326/0003-4819-123-11-199512010-00001>)
- 15 Practice Guidelines for Perioperative Transesophageal Echocardiography. An updated report by the American Society of Anesthesiologists and the Society of Cardiovascular Anesthesiologists Task Force on Transesophageal Echocardiography. *Anesthesiology* 2010 **112** 1084–1096.
- 16 Kallmeyer IJ, Collard CD, Fox JA, Body SC & Sherman SK. The safety of transesophageal echocardiography: a case series of 7200 cardiac surgical patients. *Anesthesia and Analgesia* 2001 **92** 1126–1130. (<https://doi.org/10.1097/00000539-200105000-00009>)
- 17 Bavalia N, Anis A, Benz M, Maldjian P, Bolanowski PJ & Saric M. Esophageal perforation, the most feared complication of TEE: early recognition by multimodality imaging. *Echocardiography* 2011 **28** E56–E59. (<https://doi.org/10.1111/j.1540-8175.2010.01291.x>)
- 18 Min JK, Spencer KT, Furlong KT, DeCara JM, Sugeng L, Ward RP & Lang RM. Clinical features of complications from transesophageal echocardiography: a single-center case series of 10,000 consecutive examinations. *Journal of the American Society of Echocardiography* 2005 **18** 925–929. (<https://doi.org/10.1016/j.echo.2005.01.034>)
- 19 Daniel WG, Erbel R, Kasper W, Visser CA, Engberding R, Sutherland GR, Grube E, Hanrath P, Maisch B, Dennig K, et al. Safety of transesophageal echocardiography. A multicenter survey of 10,419 examinations. *Circulation* 1991 **83** 817–821. (<https://doi.org/10.1161/01.CIR.83.3.817>)
- 20 Silvius SE, Nebel O, Rogers G, Sugawa C & Mandelstam P. Endoscopic complications. Results of the 1974 American Society for Gastrointestinal Endoscopy survey. *JAMA* 1976 **235** 928–930. (<https://doi.org/10.1001/jama.1976.03260350032023>)
- 21 Miller G. Complications of endoscopy of the upper gastrointestinal tract [article in German]. *Leber, Magen, Darm* 1987 **17** 299–304.
- 22 Kharasch ED & Sivarajan M. Gastroesophageal perforation after intraoperative transesophageal echocardiography. *Anesthesiology* 1996 **85** 426–428. (<https://doi.org/10.1097/00000542-199608000-00027>)
- 23 Piercy M, McNicol L, Dinh DT, Story DA & Smith JA. Major complications related to the use of transesophageal echocardiography in cardiac surgery. *Journal of Cardiothoracic and Vascular Anesthesia* 2009 **23** 62–65. (<https://doi.org/10.1053/j.jvca.2008.09.014>)
- 24 Jougon JB, Gallon P, MacBride T, Dubrez J & Velly JF. Esophageal perforation after transesophageal echocardiography. *European Journal of Cardio-Thoracic Surgery* 1999 **16** 686–687. ([https://doi.org/10.1016/S1010-7940\(99\)00322-X](https://doi.org/10.1016/S1010-7940(99)00322-X))
- 25 Spahn DR, Schmid S, Carrel T, Pasch T & Schmid ER. Hypopharynx perforation by a transesophageal echocardiography probe. *Anesthesiology* 1995 **82** 581–583. (<https://doi.org/10.1097/00000542-199502000-00029>)
- 26 Massey SR, Pitsis A, Mehta D & Callaway M. Oesophageal perforation following perioperative transoesophageal echocardiography. *British Journal of Anaesthesia* 2000 **84** 643–646. (<https://doi.org/10.1093/bja/84.5.643>)
- 27 Sainathan S & Andaz S. A systemic review of transesophageal echocardiography-induced esophageal perforation. *Echocardiography* 2013 **30** 977–983. (<https://doi.org/10.1111/echo.12290>)
- 28 Zuchelli T, Alsheik E, Chu C & Bhandari B. Does an upper endoscopy before transesophageal echocardiography change management? *Journal of Clinical Gastroenterology* 2015 **49** 848–852. (<https://doi.org/10.1097/MCG.0000000000000332>)
- 29 Savino JS, Hanson CW III, Bigelow DC, Cheung AT & Weiss SJ. Oropharyngeal injury after transesophageal echocardiography. *Journal of Cardiothoracic and Vascular Anesthesia* 1994 **8** 76–78. ([https://doi.org/10.1016/1053-0770\(94\)90017-5](https://doi.org/10.1016/1053-0770(94)90017-5))
- 30 Urbanowicz JH, Kernoff RS, Oppenheim G, Parnagian E, Billingham ME & Popp RL. Transesophageal echocardiography and its potential for esophageal damage. *Anesthesiology* 1990 **72** 40–43. (<https://doi.org/10.1097/00000542-199001000-00008>)
- 31 O'Shea JP, Southern JE, D'Ambra MN, Magro C, Geurrero JL, Marshall JE, Vlahakes GV, Levine RA & Weyman AE. Effects of prolonged transesophageal echocardiographic imaging and probe manipulation on the esophagus—an echocardiographic-pathologic study. *Journal of the American College of Cardiology* 1991 **17** 1426–1429.
- 32 Lennon MJ, Gibbs NM, Weightman WM, Leber J, Ee HC, Yusoff IF. Transesophageal echocardiography-related gastrointestinal complications in cardiac surgical patients. *Journal of Cardiothoracic and Vascular Anesthesia* 2005 **19** 141–145. (<https://doi.org/10.1053/j.jvca.2005.01.020>)
- 33 Kasper J, Bolliger D, Skarvan K, Buser P, Filipovic M & Seiberger MD. Additional cross sectional transesophageal echocardiography views improve perioperative right heart assessment. *Anesthesiology* 2012 **117** 726–734. (<https://doi.org/10.1097/ALN.0b013e318269054b>)
- 34 Bufkin BL, Miller JI & Mansour KA. Esophageal perforation: emphasis on management. *Annals of Thoracic Surgery* 1996 **61** 1447–1451; discussion 1451–1442. ([https://doi.org/10.1016/0003-4975\(96\)00053-7](https://doi.org/10.1016/0003-4975(96)00053-7))
- 35 Ohri SK, Liakakos TA, Pathi V, Townsend ER & Fountain SW. Primary repair of iatrogenic thoracic esophageal perforation and Boerhaave's syndrome. *Annals of Thoracic Surgery* 1993 **55** 603–606. ([https://doi.org/10.1016/0003-4975\(93\)90261-F](https://doi.org/10.1016/0003-4975(93)90261-F))
- 36 Nesbitt JC & Sawyers JL. Surgical management of esophageal perforation. *American Surgeon* 1987 **53** 183–191.
- 37 Whyte RJ, Iannettoni MD & Orringer MB. Intrathoracic esophageal perforation. The merit of primary repair. *Journal of Thoracic and Cardiovascular Surgery* 1995 **109** 140–144; discussion 144–146. ([https://doi.org/10.1016/S0022-5223\(95\)70429-9](https://doi.org/10.1016/S0022-5223(95)70429-9))

- 38 Spier BJ, Larue SJ, Teelin TC, Leff JA, Swize LR, Borkan SH, Satyapriya A, Rhako PS & Pfau PR. Review of complications in a series of patients with known gastroesophageal varices undergoing transesophageal echocardiography. *Journal of the American Society of Echocardiography* 2009 **22** 396–400. (<https://doi.org/10.1016/j.echo.2009.01.002>)
- 39 St-Pierre J, Fortier LP, Couture P & Hebert Y. Massive gastrointestinal hemorrhage after transoesophageal echocardiography probe insertion. *Canadian Journal of Anesthesia* 1998 **45** 1196–1199. (<https://doi.org/10.1007/BF03012463>)
- 40 Hulyalkar AR & Ayd JD. Low risk of gastroesophageal injury associated with transesophageal echocardiography during cardiac surgery. *Journal of Cardiothoracic and Vascular Anesthesia* 1993 **7** 175–177. ([https://doi.org/10.1016/1053-0770\(93\)90212-4](https://doi.org/10.1016/1053-0770(93)90212-4))
- 41 McSweeney ME, Garwood S, Levin J, Marino MR, Wang SX, Kardatzke D, Mangano DT & Wolman RL. Adverse gastrointestinal complications after cardiopulmonary bypass: can outcome be predicted from preoperative risk factors? *Anesthesia and Analgesia* 2004 **98** 1610–1617. (<https://doi.org/10.1213/01.ANE.0000113556.40345.2E>)
- 42 Hogue CW, Lappas GD, Creswell LL, Ferguson TB Jr, Sample M, Pugh D, Balfe D, Cox JL & Lappas DG. Swallowing dysfunction after cardiac operations. Associated adverse outcomes and risk factors including intraoperative transesophageal echocardiography. *Journal of Thoracic and Cardiovascular Surgery* 1995 **110** 517–522. ([https://doi.org/10.1016/S0022-5223\(95\)70249-0](https://doi.org/10.1016/S0022-5223(95)70249-0))
- 43 Rousou JA, Tighe DA, Garb JL, Krasner K, Engelman RM, Flack JE & Deaton DW. Risk of dysphagia after transesophageal echocardiography during cardiac operations. *Annals of Thoracic Surgery* 2000 **69** 486–490.
- 44 Messina AG, Parancas M, Fiamengo S, Yao F-S, Krieger K, Isom OW & Devereux RB. Risk of dysphagia after transesophageal echocardiography. *American Journal of Cardiology* 1991 **67** 313–314. ([https://doi.org/10.1016/0002-9149\(91\)90567-5](https://doi.org/10.1016/0002-9149(91)90567-5))
- 45 Khandheria BK & Oh J. Transesophageal echocardiography: state-of-the-art and future directions. *American Journal of Cardiology* 1992 **69** (Supplement 1) 61H–75H. ([https://doi.org/10.1016/0002-9149\(92\)90648-1](https://doi.org/10.1016/0002-9149(92)90648-1))
- 46 Kallmeyer I, Morse DS, Body SC & Collard CD. Case 2-2000. Transesophageal echocardiography-associated gastrointestinal trauma. *Journal of Cardiothoracic and Vascular Anesthesia* 2000 **14** 212–216. ([https://doi.org/10.1016/S1053-0770\(00\)90022-3](https://doi.org/10.1016/S1053-0770(00)90022-3))
- 47 Sharma V, Alderton S, McNamara H, Steeds R, Bradlow W, Chenzbraun A, Oxborough D, Mathew T, Jones R, Wheeler R, et al. A safety checklist for transesophageal echocardiography from the British Society of Echocardiography and the Association of Cardiothoracic Anaesthetists. *Echo Research and Practice* 2015 **2** G25–G27. (<https://doi.org/10.1530/ERP-15-0035>)
- 48 Kako H, Alkhatib O, Krishna SG, Khan S, Naguib A & Tobias JD. Changes in intracuff pressure of a cuffed endotracheal tube during surgery for congenital heart disease using cardiopulmonary bypass. *Pediatric Anaesthesia* 2015 **25** 705–710. (<https://doi.org/10.1111/pan.12631>)
- 49 Inada T, Kawachi S & Kuroda M. Tracheal tube cuff pressure during cardiac surgery using cardiopulmonary bypass. *British Journal of Anaesthesia* 1995 **74** 283–286. (<https://doi.org/10.1093/bja/74.3.283>)
- 50 Souza Neto EP, Piriou V, Durand PG, George M, Evans R, Obadia JF & Lehot JJ. Influence of temperature on tracheal tube cuff pressure during cardiac surgery. *Acta Anaesthesiologica Scandinavica* 1999 **43** 333–337. (<https://doi.org/10.1034/j.1399-6576.1999.430315.x>)
- 51 Mishra M, Chauhan R, Sharma KK, Dhar A, Bhise M, Dhole S, Omar A, Kasliwal RR & Trehan N. Real-time intraoperative transesophageal echocardiography – how useful? Experience of 5016 cases. *Journal of Cardiothoracic and Vascular Anesthesia* 1998 **12** 625–632. ([https://doi.org/10.1016/S1053-0770\(98\)90232-4](https://doi.org/10.1016/S1053-0770(98)90232-4))
- 52 Couture P, Denault AY, McKenty S, Boudreault D, Plante F, Perron R, Babin D, Normandin L & Poirier N. Impact of routine use of intraoperative transesophageal echocardiography during cardiac surgery. *Canadian Journal of Anesthesia* 2000 **47** 20–26. (<https://doi.org/10.1007/BF03020726>)
- 53 Comunale ME, Body SC, Ley C, Koch C, Roach G, Mathew J, Herskowitz A & Mangano T. The concordance of intraoperative left ventricular wall-motion abnormalities and electrocardiographic S-T segment changes: association with outcome after coronary revascularization. *Anesthesiology* 1998 **88** 945–954. (<https://doi.org/10.1097/0000542-199804000-00014>)
- 54 Denault AY, Couture P, McKenty S, Boudreault D, Plante F, Perron R, Babin D & Buithieu J. Perioperative use of transesophageal echocardiography by anesthesiologists: impact in noncardiac surgery and in the intensive care unit. *Canadian Journal of Anesthesia* 2002 **49** 287–293. (<https://doi.org/10.1007/BF03020529>)
- 55 Memtsoudis SG, Rosenberger P, Löffler M, Eltzschig HK, Mizuguchi A, Shernan SK & Fox JA. The usefulness of transesophageal echocardiography during intraoperative cardiac arrest in noncardiac surgery. *Anesthesia and Analgesia* 2006 **102** 1653–1657. (<https://doi.org/10.1213/01.ane.0000216412.83790.29>)
- 56 Rapezzi C, Rocchi G, Fattori R, Calderera I, Ferlito M, Napoli G, Pierangeli A & Branzi A. Usefulness of transesophageal echocardiographic monitoring to improve the outcome of stent-graft treatment of thoracic aortic aneurysms. *American Journal of Cardiology* 2001 **87** 315–319. ([https://doi.org/10.1016/S0002-9149\(00\)01365-5](https://doi.org/10.1016/S0002-9149(00)01365-5))
- 57 Greene MA, Alexander JA, Knauf DG, Talbert J, Langham M, Kays D & Ledbetter D. Endoscopic evaluation of the esophagus in infants and children immediately following intraoperative use of transesophageal echocardiography. *Chest* 1999 **116** 1247–1250. (<https://doi.org/10.1378/chest.116.5.1247>)
- 58 Tsai SK, Chang CI, Wang MJ, Chen SJ, Chiu IS, Chen YS & Lue HC. The assessment of the proximal left pulmonary artery by transesophageal echocardiography and computed tomography in neonates and infants: a case series. *Anesthesia and Analgesia* 2001 **93** 594–597. (<https://doi.org/10.1097/0000539-200109000-00013>)
- 59 Andropoulos DB, Ayres NA, Stayer SA, Bent ST, Campos CJ & Fraser CD. The effect of transesophageal echocardiography on ventilation in small infants undergoing cardiac surgery. *Anesthesia and Analgesia* 2000 **90** 47–49. (<https://doi.org/10.1097/0000539-200001000-00011>)
- 60 Laporta D, Kleiman S, Begin L, De Marchie M & Spanier AH. Traumatic perforation of the cervical esophagus: a complication of endotracheal intubation. *Intensive Care Medicine* 1993 **19** 59–60. (<https://doi.org/10.1007/BF01709282>)
- 61 Stevenson JG. Incidence of complications in pediatric transesophageal echocardiography: experience in 1650 cases. *Journal of the American Society of Echocardiography* 1999 **12** 527–532. ([https://doi.org/10.1016/S0894-7317\(99\)70090-8](https://doi.org/10.1016/S0894-7317(99)70090-8))

Received in final form 26 July 2018

Accepted 2 August 2018

Accepted Preprint published online 2 August 2018