

Case Report

Meningitis and pneumococcal pyomyositis in a child with intramuscular hemangiomas: an autopsy case report

Cristiano Claudino Oliveira, Mariângela Esther Alencar Marques

Department of Pathology, São Paulo State University, Botucatu School of Medicine, Botucatu, São Paulo, Brazil

Received May 1, 2014; Accepted June 24, 2014; Epub June 15, 2014; Published July 1, 2014

Abstract: Pyomyositis is the bacterial infection of skeletal muscle, usually accompanied by abscesses. The main etiologic agent is *Staphylococcus aureus*. There are rare cases attributed to *Streptococcus pneumoniae*. This paper presents an autopsy of a four year old child with multiple congenital intramuscular hemangiomas that developed pneumococcal pyomyositis associated with meningitis. The authors propose the hypothesis that patients with hemangiomas, mainly the intramuscular type, may also represent a risk group for pyomyositis. The possibility of respiratory/meningeal co-infection, might also be considered even if the clinical picture is restricted to the muscular system.

Keywords: Pyomyositis, pneumococcal meningitis, hemangioma

Introduction

Hemangiomas are the most common benign vascular tumors of childhood [1]. Among soft tissue tumors, hemangiomas represent 7-10% of cases, with 0.8% classified as intramuscular hemangioma [2]. Pyomyositis are bacterial infections of skeletal muscle usually accompanied by abscess. The main etiologic agent reported is *Staphylococcus aureus* [3]. Pyomyositis by *Streptococcus pneumoniae* is rare and there have been 32 reported cases since 1972, as described by Zadroga et al [3]. This paper presents an autopsy case of a child with multiple intramuscular hemangiomas with pyomyositis and simultaneous development of meningitis caused by *Streptococcus pneumoniae* isolated from blood cultures.

Case report

A four year old female child was admitted to the pediatric emergency hospital presenting intense pain in the right lower limb followed by fever. The patient was otherwise in good health and was kept under observation with therapeutic

measures for pain. The child had previously been diagnosed with multiple intramuscular congenital hemangiomas in the right thigh and left leg, confirmed by computed tomography, magnetic resonance imaging and venous duplex without arteriovenous fistulas or thrombi.

The initial blood count showed normal values of platelets, mild anemia (hemoglobin = 11.5 g/dL, hematocrit = 34.1%) and leukocytosis (absolute value of 15.900/mm³ with a predominance of neutrophils). A blood culture was performed.

Throughout the two days following admission, the patient's hemoglobin and hematocrit drastically decreased to 8.0 g/dL and 23.4%, respectively, with 52.000/mm³ platelets and the continued presence of neutrophilic leukocytosis.

Computed tomography showed a solid mass in the soft tissue of the anterior medial region of the right thigh associated with a tumor in the pelvis. The diagnostic possibilities were hemangiomas.

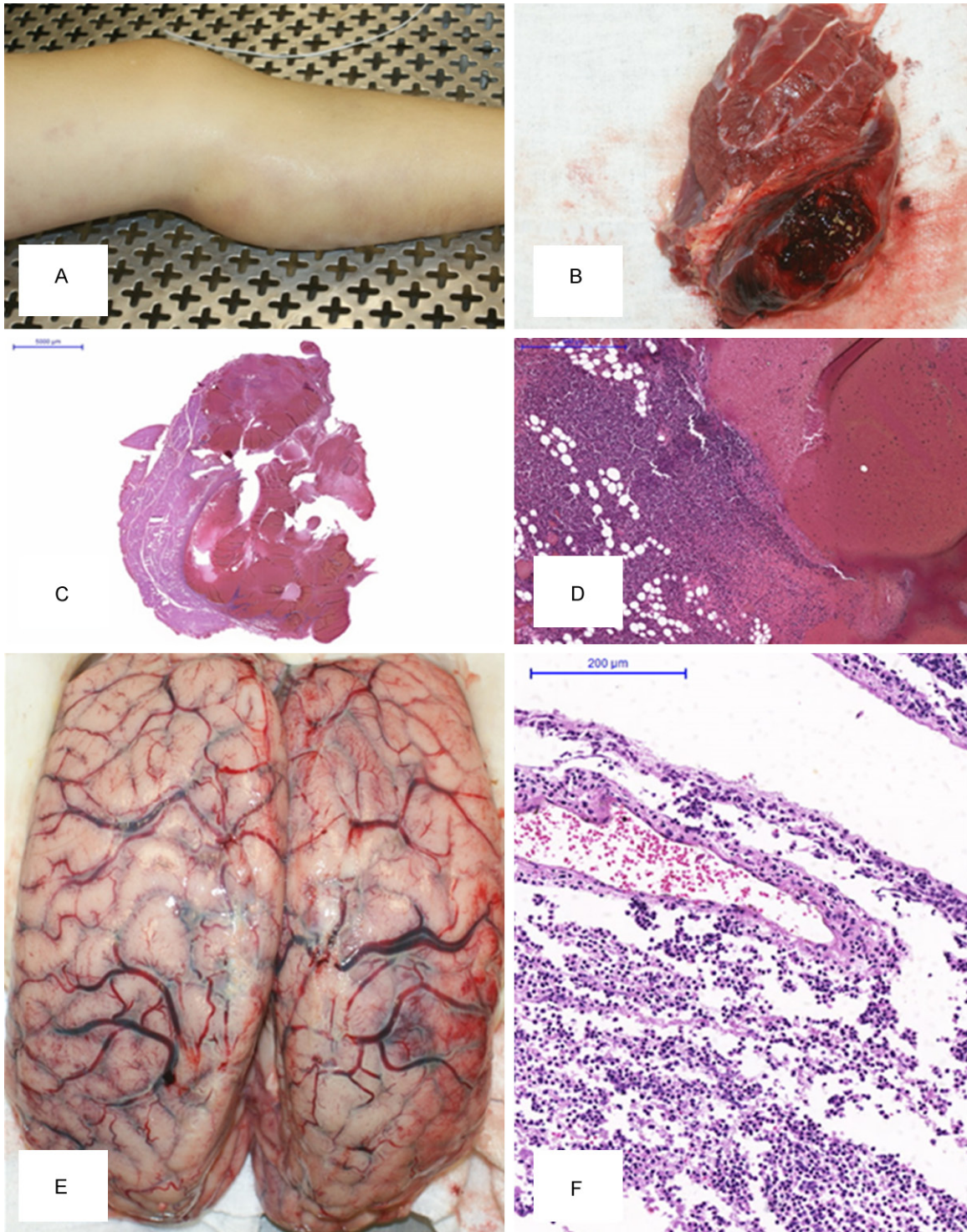


Figure 1. Intramuscular hemangioma: lesion in the left lower limb (A), macroscopic lesion (B), microscopy demonstrating the relationship with the adjacent musculature (C) and histological pattern of pyomyositis (D). Meningitis: macroscopic thickening of meninge (E) and microscopic pattern with intense neutrophilic inflammation (F).

The clinical condition of the child worsened in the following hours, and the pain became refractory to analgesics. The patient had

decreased levels of consciousness, intracranial hypertension, requiring intubation. Significant alterations in coagulation and a computed

tomography scan confirmed diffuse cerebral edema. After two days of hospitalization, the child developed cardiopulmonary arrest refractory to cardiopulmonary resuscitation measures resulting in her death.

The autopsy showed four wine-homogeneously, intramuscular lesions located in the left calf, the anterior medial region of the right thigh, the base of the right thigh and the pelvis, ranging from 3.0 to 4.5 cm in size. Histological examination revealed that all the lesions were hemangiomas, with lobular architecture, dilated vessels, with irregular walls, filled with blood or fibrin thrombi. There was a dense neutrophilic infiltrate involving the hemangioma, muscle fibers and adjacent adipose tissue. The histopathological features were consistent with pyomyositis (**Figure 1**).

The brain had an increased weight (1410 g) and macroscopic signs of diffused edema. The meninges were thickened with mild pallor, and (**Figure 1**) histological evaluation showed meningitis with exuberant exudate of neutrophils. Other findings included multiple hyaline thrombi detected in peripheral blood vessels of adrenal and hepatosplenomegaly.

The result of the blood culture performed on the first day of hospitalization and released after the death, was positive for *Streptococcus pneumoniae*.

The morphological and laboratory data indicate the diagnosis of pneumococcal pyomyositis associated with pneumococcal meningitis in a context of sepsis, disseminated intravascular coagulation and cerebral edema resulting in death.

Discussion

Hemangiomas are benign vascular neoplasms responsible for 7-10% of soft tissue tumors, common in childhood, with a predominance in females [1, 2]. The congenital origin is documented in 30-50% of cases, generally manifesting, by the end of the first year of life, predominantly in the head and neck. A family history of hemangiomas is found in 10% of cases. Multiple lesions are seen in approximately 20% of patients [1]. The most accepted classification is based on the histologic appearance of the vessels and includes the following

subtypes: capillary, cavernous, venous, arteriovenous and mixed [4, 5].

Intramuscular hemangiomas represent 0.8% of these tumors with a predominance in women [2]. The most common locations for this type of tumor are: extremities (40%, predominantly the lower limbs), head and neck (40%) and trunk (20%) [1, 6]. Kiran et al report the difficulty in the clinical diagnosis of these lesions because of their depth and size variation [2]. The clinical presentation includes: localized pain, swelling and nerve compression due to the constriction caused by tumor growth [6]. Some patients may develop consumption coagulopathies represented by thrombocytopenia, microangiopathic anemia, hypofibrinogenemia, an increase of products of fibrin degradation increasing the vascular tumors. This clinical laboratory frame is called Phenomenon Kassabach-Merritt, commonly described in children with large tumors with skin involvement such as Hemangioendothelioma kaposiform [6, 7]. Kiran et al also state that the intramuscular hemangiomas may occur in adolescents and young adults and is associated in 17% of cases with trauma to the area [2].

Imaging tests are important for the diagnosis of hemangiomas, especially magnetic resonance which provides details of the lesion such as location, size and extension [2, 6]. Biopsy is not indicated for routine diagnosis, except when there are clinical and radiological suspicions of malignancy [6]. The patient in this case study had multiple intramuscular hemangiomas on her lower limbs, one of them with pelvic extension. Russell et al reported a similar case of hemangioma on the thigh of a five-year old child who developed pyomyositis caused by *Streptococcus pyogenes* [6].

Pyomyosites are bacterial infections that affect the skeletal muscles, with abscess formation, first reported in the nineteenth century (France, 1858; Brazil, 1866). After the 1980s, the higher frequency of pyomyositis was due to prevalence of diabetes mellitus, related to immunosuppression as Acquired Immunodeficiency Syndrome (AIDS), autoimmune diseases, patients who had received a transplant, malignancy and drug abuse [3]. The main etiological agent is the *Staphylococcus aureus*. *Streptococcus pyogenes* are uncommon, and *Escherichia coli*, *Streptococcus pneumoniae* and

Haemophilus influenza are seldom reported [3, 8-11]. Zadroga et al, in a literature review, found 32 cases of pyomyositis caused by *Streptococcus pneumoniae* reported since 1972 [3]. Mackay et al mentioned that they have made inferences that pyomyositis were severe infections which were difficult to diagnose and might be related not only to bacteremia, but also to co-factors such as local trauma, immune system diseases and, in rare cases, with involvement of *Streptococcus pneumoniae*, and to respiratory/meninges infections [11].

Zadroga et al studied 31 cases of pyomyositis caused by *Streptococcus pneumoniae* confirmed by blood cultures, of which 21 patients had shown respiratory infections or meningitis before clinical muscle symptoms. These patients had mild respiratory/neurological clinical manifestations. In that study there were no patients with hemangioma [3]. Thus, this group of authors argues that the primary focus of pneumococcal infection is pulmonary or meninges, leading to bacteremia. And that by risk factors, would lead to an exaggerated inflammatory response to muscle involvement, featuring areas of pyomyositis [3]. Collazos et al, in a review of 11 cases of pneumococcal pyomyositis, found three cases of meningitis concomitant with the same etiologic agent and reported a higher inflammatory response in pneumococcal pyomyositis than those caused by other bacteria [10]. Despite the aggressiveness of infection, morbidity and mortality from pneumococcal pyomyositis is not as high when it is diagnosed early, and antimicrobial and invasive therapies (such as drainage of abscesses) are performed [3, 9, 10, 12].

Literature does not consider the hemangiomas as risk factors for pyomyositis. Russell et al highlighted that patients with clinical symptoms of muscle pain and swelling should be carefully evaluated due to the possibility of intramuscular hemangiomas complicated with bleeding and/or infections, with emphasis on pyomyositis [5, 12]. The child in this case study was previously diagnosed with intramuscular hemangiomas and was admitted to hospital with symptoms compatible with pyomyositis. The autopsy confirmed the pyomyositis associated with meningitis, and blood cultures were positive for *Streptococcus pneumoniae*. Thus, it is hereby proposed, the hypothesis that patients with hemangiomas, mainly intramus-

cular type, may also represent a risk group for pyomyositis. The possibility of respiratory/meningeal co-infections might also be considered even if the clinical picture is restricted to the muscular system.

Disclosure of conflict of interest

None.

Address correspondence to: Dr. Cristiano Claudino Oliveira, Department of Pathology, São Paulo State University, Botucatu School of Medicine, Botucatu, São Paulo, Brazil. CEP: 18618-970. E-mail: Cristiano_c_oliveira@hotmail.com

References

- [1] Ranero-Juaréz AG, Rosales-Galindo VM, Takahashi AML, Arenas-Guzmán R, García C. Intramuscular hemangiomas of the extremities: report of six cases. *Int J Dermatol* 2009; 48: 875-8.
- [2] Kiran KR, Babu TV, Babu SS, Deepti K. Skeletal Muscle Haemangioma: A Cause for Chronic Pain about the Knee: A Case Report. *Case Rep Orthop* 2012; 2012: 452651..
- [3] Zadroga RJ, Zylla D, Cawcutt K, Musher DM, Gupta P, Kuskowski M, Dincer A, Kaka AS. Pneumococcal Pyomyositis: Report of 2 Cases and Review of the Literature. *Clin Infect Dis* 2012; 55: e12-7.
- [4] Desai SC, Gopal M, Narayan A. A rare intramuscular hemangioma - case report. *Indian J Surg* 2008; 70: 250-251.
- [5] Maki DD, Craig-Mueller J, Griffiths HJ. Radiologic case study. Intramuscular Hemangioma. *Orthopedics* 1996; 19: 907-909.
- [6] Russel S, Watts RG, Royal SA, Barnhart DC. Group A Streptococcal Infection of an Intramuscular Venous Malformation. A Case Report and Review of the Literature. *Pediatr Emerg Care* 2008; 24: 839-41.
- [7] Kelly M. Kasabach-Merritt Phenomenon. *Pediatr Clin North Am* 2010; 57: 1085-9.
- [8] Bretón JR, Pi G, Lacruz L, Calvo I, Rodríguez I, Sánchez A, Camarena JJ, Hernández R. Pneumococcal pyomyositis. *Pediatr Infect Dis J* 2001; 20: 85-7.
- [9] Collazos J, Fernández A, Martínez E, Mayo J, de la Viuda JM. Pneumococcal pyomyositis. Case report, review of the literature, and comparison with classic pyomyositis caused by other bacteria. *Arch Intern Med* 1996; 156: 1470-4.
- [10] Wong SL, Anthony EY, Shetty AK. Pyomyositis due to *Streptococcus pneumoniae*. *Am J Emerg Med* 2009; 27: 633-5.
- [11] Robertson-Mackay F, Al-Hillawi AH. Pyomyositis complicating pneumococcal meningitis. *Postgrad Med J* 1993; 69: 64-5.

Meningitis and pneumococcal pyomyositis

- [12] Berg RP, Smets AM, Bosman DK, Besselaar PP. Pyomyositis of the M. quadriceps femoris in an 8-month-old boy following pneumococcal meningitis. *Ned Tijdschr Geneeskd* 2005; 149: 2228-31.