

## Review Article

# Therapy of adrenocortical cancer: present and future

Daniela F. Maluf<sup>1</sup>, Brás H. de Oliveira<sup>2</sup>, Enzo Lalli<sup>3,4</sup>

<sup>1</sup>Department of Pharmacy, Federal University of Paraná, 80210-170, Curitiba PR, Brazil; <sup>2</sup>Department of Chemistry, Federal University of Paraná, 81531-990, Curitiba PR, Brazil; <sup>3</sup>Institut de Pharmacologie Moléculaire et Cellulaire, CNRS UMR 6097, 06560 Valbonne, France; <sup>4</sup>Université de Nice - Sophia Antipolis, Valbonne, France.

Received November 30, 2010; accepted December 6, 2010; Epub December 7, 2010; Published January 1, 2011

**Abstract:** Adrenocortical carcinoma is a rare endocrine malignancy with an estimated worldwide incidence of 0.5 - 2 per million/year. This neoplasm is characterized by a high risk of recurrence and a dismal prognosis owing to unsatisfactory overall survival. Surgery represents the cornerstone of adrenocortical carcinoma therapy, which can be associated to radiotherapy and adjuvant mitotane administration. In advanced cases, different chemotherapy regimens are used, but their relative efficacy is still unknown until the results of clinical trials under way will be published. Novel drugs have been recently developed based on the discovery of molecular pathways that trigger development and evolution of these tumors. More efficient treatments are widely expected in the future from these new targeted therapies as a hope of cure for patients affected with this aggressive malignancy.

**Keywords:** Adrenocortical carcinoma, targeted therapy, review, mitotane, radiotherapy, chemotherapy,  $\beta$ -catenin, Steroidogenic factor 1 (SF-1) inverse, mTOR, antagonists

## Introduction

Adrenocortical carcinoma (ACC) is a rare endocrine malignancy with an estimated worldwide incidence of 0.5 - 2 per million/year. Even though adrenocortical tumors are rare in children, there is a considerable incidence in southern Brazil with 3.4-4.2 cases per million children under 15 years, a rate 12-18 times higher than worldwide incidence [1, 2]. This neoplasm is characterized by a high risk of recurrence and a dismal prognosis owing to unsatisfactory overall 5-year survival that ranges between 23% and 60% [1, 3-5]. A bimodal age distribution has been observed in ACC patients with higher incidence occurring before the age of 5 years and in the fourth to fifth decade of life. Moreover, there is a slightly female predominance [1, 6]. Early diagnosis in adults is particularly difficult since often no signs of hormone excess are present. Conversely, approximately 90% of pediatric patients can be recognized by hormone excess causing virilization and androgen hypersecretion (mainly cortisol hypersecretion), and for this reason they have a better prognosis [1].

The tumor stage at diagnosis is the strongest prognostic factor. Three parameters have been identified strongly correlated to a shorter survival: older age at diagnosis, stages III (involvement of local lymph nodes) to IV (local organ invasion or distant metastases) disease, and cortisol hypersecretion [7]. Complete operative resection is the only hope for cure of ACC. However, because of the frequency that the disease is at an advanced stage at the moment of diagnosis, surgery often fails to remove total tumor burden. Furthermore, recurrence occurs in approximately 70% to 80% of patients after resection. The majority of patients treated with radical resection undergoes relapse and 5-year survival can be as low as 5% [8]. Chemotherapy is the first-line nonoperative therapy, used as adjuvant treatment and in cases where resection is incomplete or contraindicated. Nevertheless, lack of efficacy of the available chemotherapy for this deadly disease constitutes a matter of debate for clinical management [9].

Currently, two important international clinical studies are in development and they may soon

bring clinical benefits. The first one is a Phase III, randomized clinical trial on locally advanced and metastatic ACC treatment (<http://www.firmact.org>) comparing etoposide, doxorubicin, cisplatin plus mitotane (EDP/M) with streptozotocin plus mitotane (Sz/M) in 300 patients during 5 years. The results of this study are anticipated to be available in 2011 [9, 10]. The second study is a prospective randomized trial intended to evaluate the efficacy of adjuvant mitotane therapy versus follow-up only (<http://www.adiuvo-trial.org>) in patients with low/moderate risk of relapse. In agreement with the consensus of an international expert panel, the treatment for adrenocortical carcinoma depends on the individual risk status. The classification is based on tumor stage, resection status and expression of the proliferation marker Ki67. Patients with high risk, who are likely to develop distant metastases, may receive a more aggressive adjuvant treatment (e.g. mitotane plus streptozotocin) for at least 2 years. In R<sub>1</sub> resection patients, radiotherapy of the tumor bed is also recommended [8-10].

### Surgery

There is a common agreement that open adrenalectomy (OA) is the most important approach in the treatment of ACC. It is the only curative option when a margin-free complete resection (R<sub>0</sub> resection) is achieved. A recent retrospective study aimed to compare the outcome of patients who underwent open resection (OR) to those treated by laparoscopic adrenalectomy (LA) [11]. In a mean follow-up of 36.5 months ( $\pm 43.6$ ), a total of 88 patients were analyzed, among which 17 were treated by LA. Tumor size ranged 4-14 cm for LA versus 5-27 cm to OR patients. This retrospective evaluation showed that recurrence occurred in 63% of cases at a mean time of 9.6 months ( $\pm 14$ ) in LA compared with 65% at 19.2 months ( $\pm 37.5$ ) in the OR group. Likewise, local recurrence was found in 25% of patients in the LA group and 20% of the OR group. The authors concluded that laparoscopic adrenalectomy is not suitable for patients with ACC. Higher complexity is attributed to LA since it is not possible to identify how to penetrate the capsule of the adrenal gland without spreading the tumor and shedding malignant cells [12]. Obviously, this trial presents limitations because of its small sample size, retrospective nature and selection bias. Although the role of LA is controversial, taking

into account its superiority over OA in terms of postoperative recovery, duration of hospitalization and overall costs, some studies have recommended LA in localized non-invasive tumors (diameter < 10 cm) and for selected cases of stage I and II ACC, when performed by an experienced endocrine surgeon [13, 14]. Interestingly, a recent study demonstrated a direct relationship between the type of surgical approach and occurrence of peritoneal carcinomatosis (PC) [15]. In this study, 18 PC diagnosed patients were evaluated. Investigation of several factors (type of surgery, size, stage, complete surgery, and hormone secretion) showed that only the type of surgery was significantly associated with PC occurrence (4/6 patients treated with LA and 11/55 patients treated with OA). The authors also attested a higher risk of local recurrence after LA compared with OA (4-year rate of PC of 67% for LA compared to 27% for OA), since LA can generate tumor spillage and consequently fast carcinomatosis development. Although this study is in accordance with Gonzalez *et al.* who reported a 15% risk of PC in OA and 89% in LA [16], there is an intrinsic limitation due to the low number of patients who undergo LA since this procedure is not generally recommended.

### Mitotane

The first description of the use of mitotane (*o,p'*-DDD), an analogue of the insecticide DDT, was made in 1948 when it was shown to produce adrenal atrophy in dogs [17]. Twelve years later, mitotane was introduced as an adrenocorticolytic agent for the treatment of adrenocortical carcinoma [18]. This drug acts by inhibiting 11 $\beta$ -hydroxylation and cholesterol chain cleavage in the mitochondria of steroidogenic cells, therefore blocking cortisol synthesis [19]. Up to date, ACC patients make use of adjuvant mitotane treatment despite its considerable toxicity and relatively low response rate, and mitotane therapy still remains the cornerstone, mainly in metastatic stage [20, 21].

Mitotane is poorly absorbed (60%) and, because of its lipophilicity, a significant amount (40%) is stored mainly in adipose tissue and also in liver, brain and adrenal tissues. This is the major factor responsible for the need of mitotane high dose administration (up to 4-6 g/day) and the toxicity events related to the treatment [22, 23]. A number of studies have de-

scribed the impact of mitotane adjuvant treatment. An important retrospective multicenter study, published in 2007 by Terzolo *et al.*, evaluated the importance of mitotane as an adjuvant treatment after radical resection of ACC in a wide cohort covering 8 Italian and 47 German centers with a 10-year follow-up [24]. Recurrence was reported in 48.9% of patients in the mitotane group, compared to 90.9% and 73.3% of the patients in the two control groups, respectively. Median recurrence-free survival in the mitotane treatment group was 42 months, compared with 10 and 25 months in the control groups ( $p < 0.01$ ). This study also showed that death from adrenocortical cancer was reduced in the mitotane group (25.5% vs. 54.5% and 41.3% in the control groups). The authors concluded that in the group of adjuvant treatment with mitotane not only the risk for recurrence and death was significantly diminished but also a longer recurrence-free survival was achieved. Even though an inherent bias is related to retrospective studies, the importance of this study is related to the large number of studied patients recruited in international centers with methodical follow-up, well-suited control groups, and efficient statistical analysis. The results of Terzolo *et al.* are in agreement with the previous study by Kasperlik-Zaluska *et al.*, which reported increased survival in mitotane group in which administration was started immediately after surgery [25]. In a critical analysis, Schteingart attested that the favorable results for adjuvant mitotane of Terzolo *et al.* may be explained by the fact that mitotane adjuvant therapy was most likely selected to patients whose surgical resection was outwardly complete [26]. A more recent study by Fassnacht *et al.* [27] concluded that a better five-year survival [87 vs. 53%, HR for death 0.35 (95% CI 0.13–0.97);  $P = 0.04$ ] and disease-free survival exist for patients who received adjuvant mitotane compared to those who did not. In addition, a risk reduction of 62% was associated to adjuvant mitotane. Furthermore, a long-term follow-up study analyzed 25 patients treated by surgery plus monitored mitotane, independently of tumor stage and total resection [28]. Around 87% of patients were treated with mitotane over more than 2 years. Overall survival was found to be 52% regardless of the prevalence of high-stage tumors. All together, these findings are supportive for therapeutic benefit of adjuvant mitotane treatment.

On the other hand, Vassilopoulou-Selin *et al.* in

a small, prospective, randomized study, found no difference in recurrence-free survival among patients who received mitotane and those who did not [29]. Additionally, Bertherat *et al.*, concluded that there is no significant advantage with adjuvant mitotane after complete removal of ACC [30]. According to these authors, it is reasonable to think that the mitotane-treated group could be selected for unfavorable prognostic factors and selection bias might be able to influence results of mitotane inefficacy. Grubbs *et al.*, in a recent publication reported a study of the largest series of ACC patients treated at a single institution [31]. Throughout an 88-month follow-up, the overall survival observed was 47 months. Comparing the outcome of patients treated with adjuvant mitotane to those treated with an alternative strategy of withholding mitotane, the authors found no significant difference in overall survival. The authors justify their results at variance with the ones obtained by Terzolo *et al.* raising questions about possible incomplete surgery in control groups in that study, which could explain a high recurrence rate.

Some hypotheses have been proposed to explain why the results of those studies are conflicting. First, it is possible that drug metabolism be variable among apparently comparable tumors. This is explained by the need of mitotane to be converted *in vivo* to an active metabolite, an acyl chloride reactive molecule, to develop the adrenolytic effect [26]. Consequently, a therapeutic response to mitotane may be present only in tumors which are able to metabolize it. In contrast, a negative response may be found in those tumors which do not have this capability. Second, the rareness of ACC with a restricted statistical possibility to carry out a trustworthy assessment of treatment effectiveness and the need for a control group of patients with analogous baseline characteristics is an inherent bias that challenges future research. Finally, retrospective analysis using different formulations with a large range of doses (3 to 20 g daily) given for variable time periods [32], may contribute to the discordant results described in the literature [33].

### Radiotherapy regimens

Radiotherapy is a worthwhile adjuvant therapy and should be considered in all patients undergoing surgical resection, in consideration of the

high rates of failure associated to surgery. It is also highly desirable in patients with locally advanced stage, large tumors, or after metastasectomy. An international, prospective, randomized study is needed to evaluate the benefit of radiotherapy to the treatment of unresectable disease [34].

In a preclinical study, Cerquetti *et al.* sought to evaluate the antineoplastic effects of radiotherapy and *o,p'*-DDD used alone or in combination on H295R and SW13 adrenocortical cancer cell lines [35]. These authors found a lasting growth arrest of 70% in H295R cells and of 55% in SW13 cells after radiation treatment. They concluded that radiotherapy in combination with *o,p'*-DDD has an important antiproliferative effect on adrenocortical human cell lines, characterized by cell cycle arrest in G2 with overexpression of cyclin B<sub>1</sub> and a high Cdc2 kinase activity in H295R cells [36].

In a recent paper, Sabolch *et al.* described the efficacy of radiotherapy in unresectable disease and identified potential associations of patient, tumor, and treatment characteristics with local recurrence and overall survival [37]. Their most important finding is that lack of radiotherapy adjuvant treatment presented a 4.7 fold higher risk of local failure than regimens which used radiotherapy. Importantly, they showed that patients treated with mitotane obtained similar results either in the surgery group or surgery and radiotherapy group (25% and 20%, respectively), hence they found no mitotane effect in local relapse reduction.

### Chemotherapy regimens

Up to date, the recommended first line treatment regimens in ACC are mitotane monotherapy, etoposide, doxorubicin, cisplatin plus mitotane, or streptozotocin plus mitotane [10]. Fareau *et al.* evaluated the efficacy of the most commonly described systemic agents for ACC: 1) platinum/etoposide; 2) platinum/etoposide/mitotane; 3) platinum/etoposide/other cytotoxic agents (adriamycin); 4) other miscellaneous cytotoxic agents (gemcitabine; paclitaxel; cisplatin/adriamycin/cyclophosphamide; cisplatin/adriamycin/iphosphamide) [38]. They found no difference in overall survival between the treatment groups of mitotane/platinum/etoposide and platinum/etoposide without mitotane. However, time to progression was observed to be

significantly better in patients treated with mitotane. A single institution experience, the heterogeneity of treatment groups and the low number of patients treated with certain agents and combinations may represent an important bias in this work. Therapy employing mebendazole has been proved to be effective in a variety of cancers, e.g. peritoneum, lung, liver, and bone, producing significant results. For this reason, Martarelli *et al.* recently evaluated the role of mebendazole on human adrenocortical carcinoma cells *in vitro* and after implantation in nude mice [39]. They found that mebendazole treatment significantly reduced invasion and migration of cancer cells (*in vitro*), metastases formation (*in vivo*) and cancer cells growth (both *in vitro* and *in vivo*). The therapeutic effects obtained on H295R and SW-13 human adrenocortical carcinoma cells were attributed to induction of apoptosis. A recent phase II trial searched to test the activity of gemcitabine administered in association with continuous 5-fluoracil infusion or metronomic capecitabine, as a second/third line approach in advanced ACC patients [40]. The patients received a combination of *i.v.* gemtacinibine (800 mg/m<sup>2</sup>, on days 1 and 8, every 21 days) and *i.v.* 5-fluorouracil protracted infusion (200 mg/m<sup>2</sup>/daily without interruption until progression) in the first six patients, or oral capecitabine (1500 mg/daily) in the subsequent patients. Mitotane administration was maintained in all cases. Response according to RECIST criteria was observed in 7.2% of cases and 46.4% obtained a clinical stabilization.

### New targeted therapies

New avenues for ACC therapy have been opened by studies investigating the biological and molecular bases of this disease. Here, we present a short overview of recent advances in the field.

#### IGF-I receptor antagonists

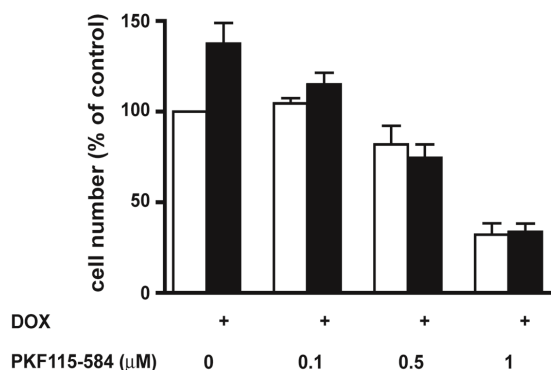
The Insulin-like Growth Factor system involves IGF-I, IGF-II and their respective tyrosine kinase receptors (IGF-IR, IGF-IIR). The *IGF2* gene, highly expressed in the human adrenal gland only during the fetal life, is located at 11p15 and its expression is regulated by a mechanism of parental imprinting. Genetic mutations involving the 11p15 region can induce development of adrenocortical tumors as part of a spectrum of

disease involving macroglossia, abdominal wall defects, hypoglycemia, organ enlargement, tumor predisposition and other symptoms (Beckwith-Wiedemann syndrome) [41]. The interaction between IGF-II and IGF-I receptor triggers several intracellular phosphorylation steps that activate mainly PI3K/Akt and MAPK pathways involved in cell proliferation, differentiation, and survival [42]. IGF signalling is implicated not only in the development and differentiation of the normal adrenal gland but also in tumorigenic adrenocortical growth. Overexpression of IGF-II and/or IGF-IR is possibly the most frequent genetic alteration in ACC and is associated to malignancy in adult, but not childhood, adrenocortical tumors [43-48]. Based on reported data of IGF-IR inhibition as a new treatment target tool in multiple myeloma and hematologic malignancies, Garcia-Echeverria *et al.* introduced a highly selective IGF-IR antagonist (NVP-AEW541, a pyrrolo[2,3-d]pyrimidine derivative) as a drug endowed with powerful antitumor activity [49]. Consistently with the pivotal role of IGF-II in regulating adrenocortical tumor cell proliferation [50], NVP-AEW541 showed antiproliferative/proapoptotic effects and inhibition of cell cycle progression, leading to specific G1 arrest, on both H295R and another cell line derived from a pediatric adrenocortical tumor [51]. Another study by Barlasakar *et al.* [52] identified increased IGF signaling in a large panel of benign and malignant human adrenal tumors and tested inhibition of adrenocortical tumor cell proliferation by IGF-IR antagonists NVP-AEW541 and IMC-A12. Both drugs were evaluated both *in vitro* and *in vivo*. The authors established that IMC-A12 attenuated phospho-Akt<sup>Ser473</sup> expression in a dose-dependent manner, while NVP-AEW541 treatment produced no detectable levels of IGF-IR tyrosine phosphorylation and phospho-Akt<sup>Ser473</sup>. Tumor growth measured in athymic nude mice xenograft (H295R) was significantly reduced by treatment with IGF-IR antagonists. In parallel, the authors evaluated a synergic effect of mitotane plus IGF antagonists in culture and in xenografts. Statistical analysis indicated that, as a single therapy, IGF-IR antagonists were more potent than mitotane to reduce tumor growth. Furthermore, association of mitotane and IGF-IR antagonist produced significant synergy. In order to assess safety, tolerability, and pharmacokinetics of the anti-IGF-IR figitumumab (CP-751,871), a phase I study was conducted at three large referral centers in metastatic, refractory patients with advanced solid tumors [53, 54]. Patients received

figitumumab by intravenous infusion at a maximal dose of 20 mg/kg every 21 days and serum glucose, insulin, and growth hormone were measured. Figitumumab toxicity was usually mild (hyperglycemia, nausea, fatigue and anorexia), but treatment increased serum insulin and growth hormone levels. Increase in insulin is explained by a compensatory secretion effect in most of the patients and showed that the insulin receptor (IR) is active in patients treated with figitumumab, even if IR and IGF-IR are highly homologous. Considering that all 14 patients were at metastatic stage and 57% experienced stability of disease, it would be interesting to evaluate combination of this agent with mitotane and/or cytotoxic chemotherapy, since blocking of AKT activation by IGF-II stimulation of IGF-IR is known to improve the anti-tumor activity of cytotoxic chemotherapy.

## *β-catenin antagonists*

The  $\beta$ -catenin gene (*CTNNB1*) is an important element of signal transduction in canonical Wnt signaling, which is involved in cell-cell adhesion, cell renewal, maintenance and commitment of progenitor cells in numerous tissues and cytoskeleton dynamics regulation [55]. Wnt stimulation produces inactivation of GSK3- $\beta$  and stabilization of  $\beta$ -catenin in the cytoplasm.  $\beta$ -catenin induces target gene expression by a sequence of events that includes  $\beta$ -catenin nuclear translocation after release from phosphorylation by casein dependent kinase-1 and glycogen synthase kinase-3 and interaction with T-cell factor/lymphoid enhancer factor (TCF/LEF) transcription factor. Deficiency in Wnt extra-cellular ligands leads to  $\beta$ -catenin phosphorylation on N-terminal serine/threonine residues, which is bound to a multi-protein scaffolding complex composed of Casein Kinase I (CKI), GSK3 $\beta$ , AXIN and APC and is further degraded by the proteasome [56]. *CTNNB1* mutation is a frequent event found in adrenocortical tumors, both benign and malignant, and may be associated with a more aggressive phenotype in ACC [57-60]. The oncogenic role of  $\beta$ -catenin in adrenal tumorigenesis was investigated by Berthoin *et al.* in a mouse model. In this work, Cre-mediated  $\beta$ -catenin activation in the adrenal cortex was produced [61]. This caused marked adrenocortical zonation defects leading to primary hyperaldosteronism and further malignant characteristics, coupled to uncontrolled neovascularization in aged mice. The authors concluded that activation of  $\beta$ -catenin in the mouse



**Figure 1.** PKF115-584 inhibits Tcf/ $\beta$ -catenin-dependent transcription and proliferation of adrenocortical tumor H295R TR/SF-1 cells [63] in a dose-dependent fashion. Doxycycline (1  $\mu$ g/mL) was added where indicated (black histograms) to increase SF-1 expression. SEM is indicated. Reproduced with permission from [62] (Copyright 2008, The Endocrine Society).

adrenal cortex produces aldosterone-secreting tumors that can later become malignant. Since clinical data evidenced  $\beta$ -catenin involvement in ACC pathogenesis, Doghman *et al.* evaluated the effect of PKF115-584, an inhibitor of TCF/ $\beta$ -catenin complex formation, on proliferation of the human ACC cell line H295R, which harbors a constitutively active  $\beta$ -catenin due to the CTNNB1 S45P mutation [62]. This compound not only inhibited cell proliferation but also overruled the effect of enhanced Steroidogenic Factor-1 (SF-1) levels on H295R proliferation [63] (Figure 1). Complementarily, no effect was observed on HeLa cell proliferation, in which the  $\beta$ -catenin pathway is not activated. PKF115-584 inhibited entry of H295R cells into S phase and induced their apoptosis. Although these results are promising, possible side effects of *in vivo* use of Wnt pathway inhibitors need to be taken into account for further evaluation of  $\beta$ -catenin antagonists.

#### Steroidogenic factor 1 (SF-1) inverse agonists

Steroidogenic Factor-1 (SF-1/Ad4BP; NR5A1) is a nuclear receptor transcription factor that was primarily identified to act in the regulation of promoter activity of cytochrome P450 steroid hydroxylases genes in steroidogenic cell lines [64, 65]. Today it is known that SF-1 plays a decisive role on the regulation of adrenal and gonadal development and in the regulation of

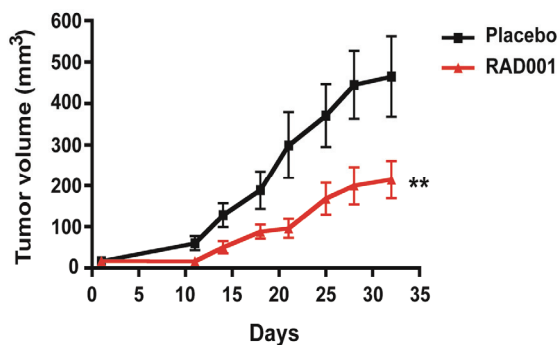
steroidogenic enzymes expression [reviewed in 66, 67]. SF-1 amplification and overexpression is frequently found in pediatric ACC and is also found in adults, where it is correlated to more severe prognosis [68-71]. Studies performed in human adrenocortical cells and in a mouse model of *Sf-1* overexpression demonstrated that an increased SF-1 dosage is a critical factor in triggering adrenocortical tumorigenesis [63]. For this reason, Doghman *et al.* investigated the effect of SF-1 inverse agonists, identified through high-throughput screening (HTS) campaigns [72, 73], on adrenocortical tumor cell proliferation [74]. SF-1 inverse agonists of the isoquinolinone class selectively downregulated H295R proliferation induced by an increased SF-1 dosage, while they had no effect on proliferation of the SW-13 cell line, which does not express SF-1. SF-1 inverse agonists also suppressed steroid hormone production by adrenocortical tumor cells, which may be beneficial to reduce symptoms due to hormone excess in the clinical setting. While these results are encouraging and SF-1 constitutes an appealing therapeutic target because of its restricted expression in steroidogenic tissues, further studies are required to assess the effects of SF-1 inverse agonists in *in vivo* models of adrenocortical tumors.

#### mTOR antagonists

Phosphatidylinositol 3-kinase (PI3K)/Akt/mammalian target of rapamycin inhibitor (mTOR) deregulation is commonly associated to human cancer pathogenesis. Several new drugs have been developed to inhibit activation of PI3K/Akt signaling in cancer [75, 76]. Recently, IGF-IR/mTOR signaling was demonstrated to be activated in childhood ACT at multiple levels by the effect of reduced expression of miR-99a and miR-100 miRNAs in the tumors [77]. Doghman *et al.* showed that a specific mTOR inhibitor (RAD001; everolimus) potently suppresses adrenocortical tumor cell proliferation *in vitro* and when grown as xenografts in immunodeficient mice (Figure 2). These results reveal a novel important mechanism of IGF-IR/mTOR signaling regulation and suggest that mTOR antagonists can represent a new potential therapeutic approach in ACC.

#### Conclusion

Adrenocortical carcinoma is a deadly disease



**Figure 2.** The rapamycin analogue RAD001 (everolimus) inhibits adrenocortical tumor cell growth *in vitro* and *in vivo*. H295R xenograft growth in NOD/SCID/yc<sup>null</sup> mice treated with placebo (black squares) or with RAD001 (10/mg/kg/day; red triangles). SEM is indicated. Tumor growth was significantly different (\*\* $p < 0.01$ , paired t-test) in animals treated with the drug. Reproduced with permission from [77] (Copyright 2010, AACR).

with poor prognosis and lack of efficient treatment options. Poor therapeutic results led to the need of collaborative international trials with the intention to establish a common protocol for treatment to produce more comparable results and improve the clinical outcome of patients with ACC. Indeed, there is a common understanding that the available drugs are not suited for a satisfactory treatment. Novel drugs have been recently developed based on the discovery of molecular pathways that trigger development and evolution of these tumors. An improved understanding of the molecular pathogenesis of ACC has conducted to the first phase III study of an IGF-I receptor antagonist. More efficient treatments are widely expected from these new targeted therapies as a hope of cure for patients affected with this aggressive malignancy.

#### Acknowledgements

D. M. is supported by a CAPES doctoral fellowship. Research in E.L. laboratory is supported by Institut National du Cancer, FP7 ENS@T CANCER and CNRS (LIA NEOGENEX).

**Please address correspondence to:** Dr. Enzo Lalli, Institut de Pharmacologie Moléculaire et Cellulaire, 660 route des Lucioles, 06560 Valbonne, France. Phone: +33 4 93 95 77 55; fax: +33 4 93 95 77 08; E-mail: [ninino@ipmc.cnrs.fr](mailto:ninino@ipmc.cnrs.fr)

#### References

- [1] Michalkiewicz E, Sandrini R, Figueiredo B, Miranda EC, Caran E, Oliveira-Filho AG, Marques R, Pianovski MA, Lacerda L, Cristofani LM, Jenkins J, Rodriguez-Galindo C, Ribeiro RC. Clinical and outcome characteristics of children with adrenocortical tumors. An analysis of 254 cases from the International Pediatric Adrenocortical Tumor Registry. *J Clin Oncol* 2004; 22: 838-845.
- [2] Pianovski MA, Maluf EM, de Carvalho DS, Ribeiro RC, Rodriguez-Galindo C, Boffetta P, Zancanella P, Figueiredo BC. Mortality rate of adrenocortical tumors in children under 15 years of age in Curitiba, Brazil. *Pediatr Blood Cancer* 2006; 47: 56-60.
- [3] Wajchenberg BL, Albergaria Pereira MA, Medonca BB, Latronico AC, Campos Carneiro P, Alves VA, Zerbini MC, Liberman B, Carlos Gomes G, Kirschner MA. Adrenocortical carcinoma: clinical and laboratory observations. *Cancer* 2000; 88: 711-736.
- [4] Bilimoria KY, Shen WT, Elaraj D, Bentrem DJ, Winchester DJ, Kebebew E, Sturgeon C. Adrenocortical carcinoma in the United States: treatment utilization and prognostic factors. *Cancer* 2008; 113: 3130-3136.
- [5] Icard P, Goudet P, Charpenay C, Andreassian B, Carnaille B, Chapuis Y, Cougard P, Henry JF, Proye C. Adrenocortical carcinomas: surgical trends and results of a 253-patient series from the French Association of Endocrine Surgeons study group. *World J Surg* 2001; 25: 891-897.
- [6] Fassnacht M, Allolio B. What is the best approach to an apparently nonmetastatic adrenocortical carcinoma? *Clin Endocrinol* 2010; 73: 561-565.
- [7] Veytsman I, Nieman L, Fojo T. Management of endocrine manifestations and the use of mitotane as a chemotherapeutic agent for adrenocortical carcinoma. *J Clin Oncol* 2009; 27: 4619-4629.
- [8] Berruti A, Fassnacht M, Baudin E, Hammer G, Haak H, Leboulleux S, Skogseid B, Allolio B, Terzolo M. Adjuvant therapy in patients with adrenocortical carcinoma: a position of an international panel. *J Clin Oncol* 2010; 28: e401-402.
- [9] Berruti A, Ferrero A, Sperone P, Daffara F, Reimondo G, Papotti M, Dogliotti L, Angeli A, Terzolo M. Emerging drugs for adrenocortical carcinoma. *Expert Opin Emerg Drugs* 2008; 13: 497-509.
- [10] Berruti A, Terzolo M, Sperone P, Pia A, Casa SD, Gross DJ, Carnaghi C, Casali P, Porpiglia F, Mantero F, Reimondo G, Angeli A, Dogliotti L. Etoposide, doxorubicin and cisplatin plus mitotane in the treatment of advanced adrenocortical carcinoma: a large prospective phase II trial. *Endocr Relat Cancer* 2005; 12: 657-666.



- [11] Miller BS, Ammori JB, Gauger PG, Broome JT, Hammer GD, Doherty GM. Laparoscopic resection is inappropriate in patients with known or suspected adrenocortical carcinoma. *World J Surg* 2010; 34: 1380-1385.
- [12] Gumbs AA, Gagner M. Laparoscopic adrenalectomy. *Best Pract Res Clin Endocrinol Metab* 2006; 20: 483-499.
- [13] Brix D, Allolio B, Fenske W, Agha A, Dralle H, Jurowich C, Langer P, Mussack T, Nies C, Riedmiller H, Spahn M, Weismann D, Hahner S, Fassnacht M. Laparoscopic versus open adrenalectomy for adrenocortical carcinoma: surgical and oncologic outcome in 152 patients. *Eur Urol* 2010; 58: 609-615.
- [14] Porpiglia F, Fiori C, Daffara F, Zaggia B, Bollito E, Volante M, Berruti A, Terzolo M. Retrospective evaluation of the outcome of open versus laparoscopic adrenalectomy for stage I and II adrenocortical cancer. *Eur Urol* 2010; 57: 873-878.
- [15] Leboulleux S, Deandreis D, Al Ghuzlan A, Auperin A, Goere D, Dromain C, Elias D, Caillou B, Travagli JP, De Baere T, Lumbroso J, Young J, Schlumberger M, Baudin E. Adrenocortical carcinoma: is the surgical approach a risk factor of peritoneal carcinomatosis? *Eur J Endocrinol* 2010; 162: 1147-1153.
- [16] Gonzalez RJ, Tamm EP, Ng C, Phan AT, Vassilopoulou-Sellin R, Perrier ND, Evans DB, Lee JE. Response to mitotane predicts outcome in patients with recurrent adrenal cortical carcinoma. *Surgery* 2007; 142: 867-875.
- [17] Nelson AA, Woodard G. Adrenal cortical atrophy and liver damage produced in dogs by feeding 2,2-bis-(parachloro-phenyl)-1,1-dichloroethane. *Fed Proc* 1948; 7: 277.
- [18] Bergenstal DM, Hertz R, Lipsett MB, Moy RH. Chemotherapy of adrenocortical cancer with *o,p'*-DDD. *Ann Int Med* 1960; 53: 672-682.
- [19] Touitou Y, Bogdan A, Luton JP. Changes in corticosteroid synthesis of the human adrenal cortex in vitro, induced by treatment with *o,p'*-DDD for Cushing's syndrome: evidence for the sites of action of the drug. *J Steroid Biochem* 1978; 9: 1217-1224.
- [20] Wandoloski M, Bussey KJ, Demeure MJ. Adrenocortical cancer. *Surg Clin North Am* 2009; 89: 1255-1267.
- [21] Lacroix A. Approach to the patient with adrenocortical carcinoma. *J Clin Endocrinol Metab* 2010; 95: 4812-4822.
- [22] Heilmann P, Wagner P, Nawroth PP, Ziegler R. [Therapy of the adrenocortical carcinoma with Lysodren (*o,p'*-DDD). Therapeutic management by monitoring *o,p'*-DDD blood levels]. *Med Klin* 2001; 96: 371-377.
- [23] Phan AT. Adrenal cortical carcinoma—review of current knowledge and treatment practices. *Hematol Oncol Clin North Am* 2007; 21: 489-507.
- [24] Terzolo M, Angeli A, Fassnacht M, Daffara F, Tauchmanova L, Conton PA, Rossetto R, Buci L, Sperone P, Grossrubatscher E, Reimondo G, Bollito E, Papotti M, Saeger W, Hahner S, Koschker AC, Arvat E, Ambrosi B, Loli P, Lombardi G, Mannelli M, Bruzzi P, Mantero F, Allolio B, Dogliotti L, Berruti A. Adjuvant mitotane treatment for adrenocortical carcinoma. *N Engl J Med* 2007; 356: 2372-2380.
- [25] Kasperlik-Zaluska AA, Migdalska BM, Zgliczynski S, Makowska AM. Adrenocortical carcinoma. A clinical study and treatment results of 52 patients. *Cancer* 1995; 75: 2587-2591.
- [26] Schteingart DE. Adjuvant mitotane therapy of adrenal cancer - use and controversy. *N Engl J Med* 2007; 356: 2415-2418.
- [27] Fassnacht M, Johanssen S, Fenske W, Weismann D, Agha A, Beuschlein F, Fuhrer D, Jurowich C, Quinkler M, Petersenn S, Spahn M, Hahner S, Allolio B. Improved survival in patients with stage II adrenocortical carcinoma followed up prospectively by specialized centers. *J Clin Endocrinol Metab* 2010; 95: 4925-4932.
- [28] Wangberg B, Khorram-Manesh A, Jansson S, Nilsson B, Nilsson O, Jakobsson CE, Lindstedt S, Oden A, Ahlman H. The long-term survival in adrenocortical carcinoma with active surgical management and use of monitored mitotane. *Endocr Relat Cancer* 2010; 17: 265-272.
- [29] Vassilopoulou-Sellin R, Guinee VF, Klein MJ, Taylor SH, Hess KR, Schultz PN, Samaan NA. Impact of adjuvant mitotane on the clinical course of patients with adrenocortical cancer. *Cancer* 1993; 71: 3119-3123.
- [30] Bertherat J, Coste J, Bertagna X. Adjuvant mitotane in adrenocortical carcinoma. *N Engl J Med* 2007; 357: 1256-1257.
- [31] Grubbs EG, Callender GG, Xing Y, Perrier ND, Evans DB, Phan AT, Lee JE. Recurrence of adrenal cortical carcinoma following resection: surgery alone can achieve results equal to surgery plus mitotane. *Ann Surg Oncol* 2010; 17: 263-270.
- [32] Terzolo M, Berruti A. Adjunctive treatment of adrenocortical carcinoma. *Curr Opin Endocrinol Diabetes Obes* 2008; 15: 221-226.
- [33] Allolio B, Fassnacht M. Clinical review: Adrenocortical carcinoma: clinical update. *J Clin Endocrinol Metab* 2006; 91: 2027-2037.
- [34] Hermsen IG, Groenen YE, Dercksen MW, Theuvs J, Haak HR. Response to radiation therapy in adrenocortical carcinoma. *J Endocrinol Invest.* 2010; Mar 10 [Epub ahead of print].
- [35] Cerquetti L, Bucci B, Marchese R, Misiti S, De Paula U, Miceli R, Muleti A, Amendola D, Piergrossi P, Brunetti E, Toscano V, Stigliano A. Mitotane increases the radiotherapy inhibitory effect and induces G2-arrest in combined treatment on both H295R and SW13 adrenocortical cell lines. *Endocr Relat Cancer* 2008; 15: 623-634.
- [36] Cerquetti L, Sampaoli C, Amendola D, Bucci B,



- Misiti S, Raza G, De Paula U, Marchese R, Brunetti E, Toscano V, Stigliano A. Mitotane sensitizes adrenocortical cancer cells to ionizing radiations by involvement of the cyclin B1/CDK complex in G2 arrest and mismatch repair enzymes modulation. *Int J Oncol* 2010; 37: 493-501.
- [37] Sabolch A, Feng M, Griffith K, Hammer G, Doherty G and Ben-Josef E. Adjuvant and definitive radiotherapy for adrenocortical carcinoma. *Int J Radiat Oncol Biol Phys* 2010; [Epub ahead of print].
- [38] Fareau GG, Lopez A, Stava C, Vassilopoulou-Sellin R. Systemic chemotherapy for adrenocortical carcinoma: comparative responses to conventional first-line therapies. *Anticancer Drugs* 2008; 19: 637-644.
- [39] Martarelli D, Pompei P, Baldi C, Mazzoni G. Mebendazole inhibits growth of human adrenocortical carcinoma cell lines implanted in nude mice. *Cancer Chemother Pharmacol* 2008; 61: 809-817.
- [40] Sperone P, Ferrero A, Daffara F, Priola A, Zaggia B, Volante M, Santini D, Vincenzi B, Badalamenti G, Intrivici C, Del Buono S, De Francia S, Kalomirakis E, Ratti R, Angeli A, Dogliotti L, Papotti M, Terzolo M, Berruti A. Gemcitabine plus metronomic 5-fluorouracil or capecitabine as a second-/third-line chemotherapy in advanced adrenocortical carcinoma: a multicenter phase II study. *Endocr Relat Cancer* 2010; 17: 445-453.
- [41] Weksberg R, Smith AC, Squire J, Sadowski P. Beckwith-Wiedemann syndrome demonstrates a role for epigenetic control of normal development. *Hum Mol Genet* 2003; 12: R61-68.
- [42] Pollak M. Insulin and insulin-like growth factor signalling in neoplasia. *Nat Rev Cancer* 2008; 8: 915-928.
- [43] Ilvesmaki V, Kahri AI, Miettinen PJ, Voutilainen R. Insulin-like growth factors (IGFs) and their receptors in adrenal tumors: high IGF-II expression in functional adrenocortical carcinomas. *J Clin Endocrinol Metab* 1993; 77: 852-858.
- [44] Gicquel C, Raffin-Sanson ML, Gaston V, Bertagna X, Plouin PF, Schlumberger M, Louvel A, Luton JP, Le Bouc Y. Structural and functional abnormalities at 11p15 are associated with the malignant phenotype in sporadic adrenocortical tumors: study on a series of 82 tumors. *J Clin Endocrinol Metab* 1997; 82: 2559-2565.
- [45] Boule N, Logie A, Gicquel C, Perin L, Le Bouc Y. Increased levels of insulin-like growth factor II (IGF-II) and IGF-binding protein-2 are associated with malignancy in sporadic adrenocortical tumors. *J Clin Endocrinol Metab* 1998; 83: 1713-1720.
- [46] Gicquel C, Bertagna X, Gaston V, Coste J, Louvel A, Baudin E, Bertherat J, Chapuis Y, Duclos JM, Schlumberger M, Plouin PF, Luton JP, Le Bouc Y. Molecular markers and long-term recurrences in a large cohort of patients with sporadic adrenocortical tumors. *Cancer Res* 2001; 61: 6762-6767.
- [47] West AN, Neale GA, Pounds S, Figueredo BC, Rodriguez-Galindo C, Pianovski MA, Oliveira Filho AG, Malkin D, Lalli E, Ribeiro R, Zambetti GP. Gene expression profiling of childhood adrenocortical tumors. *Cancer Res* 2007; 67: 600-608.
- [48] Rosati R, Cerrato F, Doghman M, Pianovski MA, Parise GA, Custodio G, Zambetti GP, Ribeiro RC, Riccio A, Figueiredo BC, Lalli E. High frequency of loss of heterozygosity at 11p15 and IGF2 overexpression are not related to clinical outcome in childhood adrenocortical tumors positive for the R337H TP53 mutation. *Cancer Genet Cytogenet* 2008; 186: 19-24.
- [49] Garcia-Echeverria C, Pearson MA, Marti A, Meyer T, Mestan J, Zimmermann J, Gao J, Brueggen J, Capraro HG, Cozens R, Evans DB, Fabbro D, Furet P, Porta DG, Liebetanz J, Martiny-Baron G, Ruetz S, Hofmann F. In vivo anti-tumor activity of NVP-AEW541- A novel, potent, and selective inhibitor of the IGF-IR kinase. *Cancer Cell* 2004; 5: 231-239.
- [50] Logié A, Boule N, Gaston V, Perin L, Boudou P, Le Bouc Y, Gicquel C. Autocrine role of IGF-II in proliferation of human adrenocortical carcinoma NCI H295R cell line. *J Mol Endocrinol* 1999; 23: 23-32.
- [51] Almeida MQ, Fragoso MC, Lotfi CF, Santos MG, Nishi MY, Costa MH, Lerario AM, Maciel CC, Mattos GE, Jorge AA, Mendonca BB, Latronico AC. Expression of insulin-like growth factor-II and its receptor in pediatric and adult adrenocortical tumors. *J Clin Endocrinol Metab* 2008; 93: 3524-3531.
- [52] Barlasak FM, Spalding AC, Heaton JH, Kuick R, Kim AC, Thomas DG, Giordano TJ, Ben-Josef E, Hammer GD. Preclinical targeting of the type I insulin-like growth factor receptor in adrenocortical carcinoma. *J Clin Endocrinol Metab* 2009; 94: 204-212.
- [53] Karp DD, Paz-Ares LG, Novello S, Haluska P, Garland L, Cardenal F, Blakely LJ, Eisenberg PD, Langer CJ, Blumenschein G, Jr., Johnson FM, Green S, Gualberto A. Phase II study of the anti-insulin-like growth factor type 1 receptor antibody CP-751,871 in combination with paclitaxel and carboplatin in previously untreated, locally advanced, or metastatic non-small-cell lung cancer. *J Clin Oncol* 2009; 27: 2516-2522.
- [54] Haluska P, Worden F, Olmos D, Yin D, Schteingart D, Batzel GN, Paccagnella ML, de Bono JS, Gualberto A, Hammer GD. Safety, tolerability, and pharmacokinetics of the anti-IGF-1R monoclonal antibody figitumumab in patients with refractory adrenocortical carcinoma. *Cancer Chemother Pharmacol* 2010; 65: 765-773.
- [55] van Amerongen R, Nusse R. Towards an inte-

- grated view of Wnt signaling in development. *Development* 2009; 136: 3205-3214.
- [56] El Wakil A, Lalli E. The Wnt/beta-catenin pathway in adrenocortical development and cancer. *Mol Cell Endocrinol*. 2010; Nov 19 [Epub ahead of print].
- [57] Tissier F, Cavard C, Groussin L, Perlemoine K, Fumey G, Hagneré AM, René-Corail F, Jullian E, Gicquel C, Bertagna X, Vacher-Lavenu MC, Perret C, Bertherat J. Mutations of beta-catenin in adrenocortical tumors: activation of the Wnt signaling pathway is a frequent event in both benign and malignant adrenocortical tumors. *Cancer Res* 2005; 65: 7622-7627.
- [58] Tadjine M, Lampron A, Ouadi L, Bourdeau I. Frequent mutations of beta-catenin gene in sporadic secreting adrenocortical adenomas. *Clin. Endocrinol* 2008; 68: 264-270.
- [59] Gaujoux S, Tissier F, Groussin L, Libe R, Ragazzon B, Launay P, Audebourg A, Dousset B, Bertagna X, Bertherat J. Wnt/beta-catenin and 3',5'-cyclic adenosine 5'-monophosphate/protein kinase A signaling pathways alterations and somatic beta-catenin gene mutations in the progression of adrenocortical tumors. *J Clin Endocrinol Metab* 2008; 93: 4135-4140.
- [60] Ragazzon B, Libé R, Gaujoux S, Assié G, Fratticci A, Launay P, Clauser E, Bertagna X, Tissier F, de Reyniès A, Bertherat J. Transcriptome analysis reveals that p53 and {beta}-catenin alterations occur in a group of aggressive adrenocortical cancers. *Cancer Res* 2010; 70: 8276-8281.
- [61] Berthon A, Sahut-Barnola I, Lambert-Langlais S, de Joussineau C, Damon-Soubeyrand C, Louiset E, Taketo MM, Tissier F, Bertherat J, Lefrancois-Martinez AM, Martinez A, Val P. Constitutive beta-catenin activation induces adrenal hyperplasia and promotes adrenal cancer development. *Hum Mol Genet* 2010; 19: 1561-1576.
- [62] Doghman M, Cazareth J, Lalli E. The T cell factor/beta-catenin antagonist PKF115-584 inhibits proliferation of adrenocortical carcinoma cells. *J Clin Endocrinol Metab* 2008; 93: 3222-3225.
- [63] Doghman M, Karpova T, Rodrigues GA, Arhatte M, De Moura J, Cavalli LR, Virolle V, Barbry P, Zambetti GP, Figueiredo BC, Heckert LL, Lalli E. Increased Steroidogenic Factor-1 dosage triggers adrenocortical cell proliferation and cancer. *Mol Endocrinol* 2007; 21: 2968-2987.
- [64] Lala DS, Rice DA, Parker KL. Steroidogenic factor I, a key regulator of steroidogenic enzyme expression, is the mouse homolog of fushi tarazu-factor I. *Mol Endocrinol* 1992; 6: 1249-1258.
- [65] Morohashi K, Honda S, Inomata Y, Handa H, Omura T. A common trans-acting factor, Ad4-binding protein, to the promoters of steroidogenic P-450s. *J Biol Chem* 1992; 267: 17913-17919.
- [66] Schimmer BP, White PC. Minireview: Steroidogenic Factor 1: its roles in differentiation, development, and disease. *Mol Endocrinol*. 2010; 24: 1322-1337.
- [67] Lalli E. Adrenocortical development and cancer: focus on SF-1. *J Mol Endocrinol* 2010; 44: 301-307.
- [68] Figueiredo BC, Cavalli LR, Pianovski MA, Lalli E, Sandrini R, Ribeiro RC, Zambetti G, DeLacerda L, Rodrigues GA, Haddad BR. Amplification of the Steroidogenic Factor 1 gene in childhood adrenocortical tumours. *J Clin Endocrinol Metab* 2005; 90: 615-619.
- [69] Pianovski MA, Cavalli LR, Figueiredo BC, Santos SC, Doghman M, Ribeiro RC, Oliveira AG, Michalkiewicz E, Rodrigues GA, Zambetti G, Haddad BR, Lalli E. 2006 SF-1 overexpression in childhood adrenocortical tumours. *Eur J Cancer* 2006; 42: 1040-1043.
- [70] Almeida MQ, Soares IC, Ribeiro TC, Fragoso MC, Marins LV, Wakamatsu A, Ressio RA, Nishi M, Jorge AA, Lerario AM, Alves VA, Mendonca BB, Latronico AC. Steroidogenic Factor 1 overexpression and gene amplification are more frequent in adrenocortical tumors from children than from adults. *J Clin Endocrinol Metab* 2010; 95: 1458-1462.
- [71] Sbiera S, Schmul S, Assie G, Voelker HU, Kraus L, Beyer M, Ragazzon B, Beuschlein F, Willenberg HS, Hahner S, Saeger W, Bertherat J, Alolio B, Fassnacht M. High diagnostic and prognostic value of Steroidogenic Factor-1 expression in adrenal tumors. *J Clin Endocrinol Metab* 2010; 95: E161-E171.
- [72] Del Tredici AL, Andersen CB, Currier EA, Ohrmund SR, Fairbain LC, Lund BW, Nash N, Olsson R, Piu F. Identification of the first synthetic steroidogenic factor 1 inverse agonists: pharmacological modulation of steroidogenic enzymes. *Mol Pharmacol* 2008; 73: 900-908.
- [73] Madoux F, Li X, Chase P, Zastrow G, Cameron MD, Konkright JJ, Griffin PR, Thacher S and Hodder P. Potent, selective and cell penetrant inhibitors of SF-1 by functional ultra-high-throughput screening. *Mol Pharmacol* 2008; 73: 1776-1784.
- [74] Doghman M, Cazareth J, Douguet D, Madoux F, Hodder P and Lalli E. Inhibition of adrenocortical carcinoma cell proliferation by steroidogenic factor-1 inverse agonists. *J Clin Endocrinol Metab* 2009; 94: 2178-2183.
- [75] Engelman JA, Luo J, Cantley LC. The evolution of phosphatidylinositol 3-kinases as regulators of growth and metabolism. *Nat Rev Genet* 2006; 7: 606-619.
- [76] Maira SM, Stauffer F, Brueggen J, Furet P, Schnell C, Fritsch C, Brachmann S, Chene P, De Pover A, Schoemaker K, Fabbro D, Gabriel D, Simonen M, Murphy L, Finan P, Sellers W, Garcia-Echeverria C. Identification and characterization of NVP-BEZ235, a new orally available dual phosphatidylinositol 3-kinase/mammalian target of rapamycin inhibitor with potent in vivo

- antitumor activity. *Mol Cancer Ther* 2008; 7: 1851-1863.
- [77] Doghman M, El Wakil A, Cardinaud B, Thomas E, Wang J, Zhao W, Peralta-Del Valle MH, Figueiredo BC, Zambetti GP, Lalli E. Regulation of insulin-like growth factor-mammalian target of rapamycin signaling by microRNA in childhood adrenocortical tumors. *Cancer Res* 2010; 70: 4666-4675.