

Case Report

HHV-6-associated acute lymphadenitis in immunocompetent patients: a case report and review of literature

Yanfeng Bai, Zhaoming Wang, Ke Sun, Hongtian Yao

Department of Pathology, The First Affiliated Hospital, College of Medicine, Zhejiang University, Hangzhou, Zhejiang Province, China

Received April 7, 2014; Accepted May 26, 2014; Epub May 15, 2014; Published June 1, 2014

Abstract: Human herpesvirus type 6 (HHV-6) has been well described as an agent in immunocompromised hosts, but is a rare cause of acute lymphadenitis in immunocompetent adults. We report an immunocompetent adult with HHV-6-associated acute lymphadenitis. The patient was an elderly man who presented with fever and generalized lymphadenopathy. Microscopically, the lymph node showed diffuse paracortical expansion and scattered large atypical lymphoid cells with large nucleus and eosinophilic nucleoli, resembled immunoblasts. Intranuclear eosinophilic viral inclusions can be found. Immunohistochemical study showed that the large atypical lymphoid cells were positive for CD3 and CD4, but negative for CD8, CD20, CD79a, CD30, ALK, CK, EBV-LMP, and CD56. The antibody against HHV-6 envelope glycoprotein highlighted the viral inclusions which were mostly cytoplasmic with a Golgi distribution. Literatures of HHV-6 associated acute lymphadenitis in immunocompetent patients were reviewed.

Keywords: HHV-6, lymphadenitis, immunocompetent patients, HL, ALCL

Introduction

Human herpesvirus type 6 (HHV-6) infects most individuals between 6 and 12 months of age. After primary infection, reactivation can lead to many diseases in immunocompromised hosts. HHV-6 has been implicated in several diseases in immunocompetent adults; while HHV6 associated acute lymphadenitis is rarely reported. We report a case of 60 year old man with fever and generalized lymphadenopathy who recovered well during the periods 24 months of follow-up.

Clinical history

A 60-year-old man with fever and generalized lymphadenopathy for approximately ten days, was admitted to our hospital in May 7th, 2009. He has no history of HIV and organ transplantation. He complained sore throat for one week. On examination he had enlarged cervical, axillary and inguinal lymph node. The body temperature reached up to 37.9°C. B ultrasound didn't reveal the enlargement of liver, spleen, and ret-

roperitoneal lymph node. The white blood cell (WBC) count was $7.7 \times 10^9/L$, neutrophils 0.77, lymphocytes 0.15, monocytes 0.06, hemoglobin 132 g/L, platelets $260 \times 10^9/L$, globulin 37.1 g/L, alkaline phosphatase 22 U/L, IgM 3840 mg/L, IgG 1660 mg/L, C3 1.53 g/L, ESR 60 mm/1 h and CRP 513 mg/L. Serologies were negative for HIV, hepatitis B and hepatitis C viruses, and cytomegalovirus (CMV). He received antibiotics and was carried on biopsy for his left cervical lymph node.

Pathological findings

Grossly, the lymph node with medium texture and gray-red cut surface was measured $1.1 \times 1.0 \times 0.5$ cm. Microscopically, the normal architecture of the lymph node was incomplete effacement with some patent sinuses and reactive lymphoid follicles. There were diffuse paracortical expansion with mixed cellular proliferation, consisting of eosinophils, plasmas and scattered immunoblasts and large atypical lymphoid cells. Many of the atypical cells, particu-

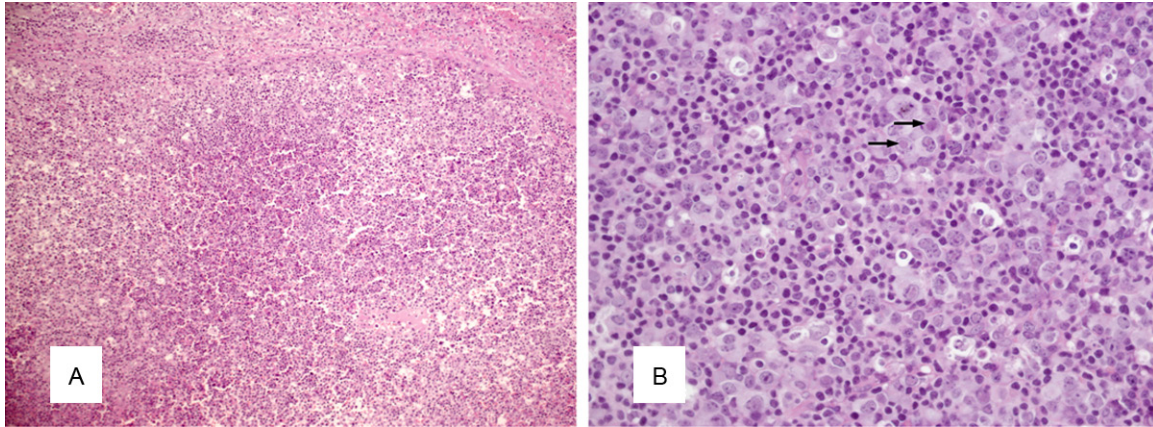


Figure 1. Histologic findings. A: The lymph node showed diffuse paracortical expansion with mixed cellular proliferation. (left, hematoxylin and eosin, $\times 100$). B: The atypical lymphoid cells contained large nucleus in which eosinophilic viral inclusions can be found and eosinophilic nucleoli. (right, hematoxylin and eosin, $\times 400$).

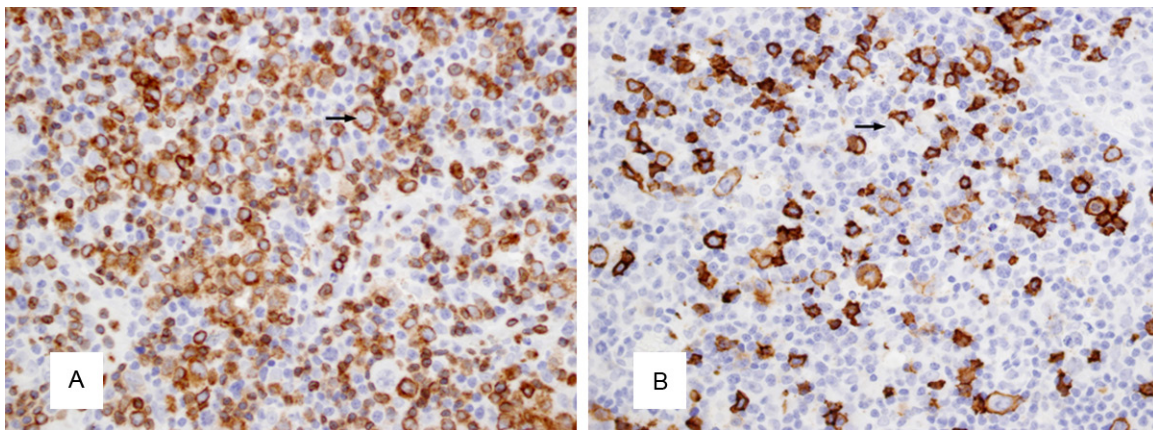


Figure 2. Immunohistochemical findings. The atypical cells with eosinophilic inclusion were positive for CD3 (A, Immunohistochemistry, $\times 400$), but negative for CD20 (B, Immunohistochemistry, $\times 400$).

lar in the subcapsular and paracortical areas, contained large nucleus and eosinophilic nucleoli; resembled immunoblasts (**Figure 1**). Intracellular eosinophilic viral inclusions can be found. The atypical cells can also be identified in the peripheric adipose tissue.

Immunohistochemical analysis

Some cells in residual follicles and rare scattered immunoblasts areas are positive for CD20, CD79a and CD30. The atypical cells with eosinophilic inclusion were positive for CD3 and CD4, but negative for CD8, CD20, CD79a, CD30, ALK, CK, EBV-LMP, and CD56 (**Figure 2**). The antibody against HHV-6 envelope glycoprotein highlighted the viral inclusions which were mostly cytoplasmic with a Golgi distribution (**Figure 3**).

Discussion

Based on the pathological and immunohistochemical findings, we diagnosed this case as HHV-6 associated acute lymphadenitis. HHV-6 was first isolated in 1986 from the peripheral blood of six patients with a variety of lymphoproliferative disorders and acquired immune deficiency syndrome (AIDS) [1]. The virus is highly prevalent world-wide and infection is acquired within the first years of life. Two variants of HHV-6 have been defined as A and B based on differences in genetic and biological properties. The virus shows a more distant relationship to the prototype β -herpes virus, human cytomegalovirus (CMV) [2]. The complete nucleotide sequences of HHV-6A and variant B have been reported. The genomes are 160-162 kb in

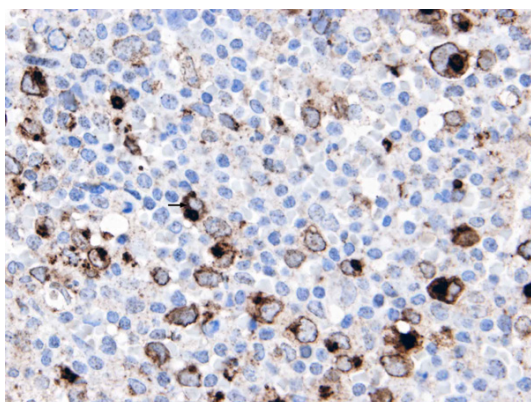


Figure 3. The antibody against HHV-6 envelope glycoprotein highlighted the viral inclusions (stained in Queen Elizabeth Hospital, Hong Kong, Courtesy of Dr. John K.C. Chan).

size, including a unique region of 143-144 kb bound by terminal direct repeats of 8-9 kb. HHV-6 encodes an envelope glycoprotein gp82-gp105 [3].

Primary infection with HHV-6 in infancy, almost exclusively variant B, is associated with febrile illness, including roseola infantum [4]. Primary infections in adults are exceedingly uncommon.

After primary infection, HHV-6 is characterized by life-long latency in peripheral blood mononuclear cells, salivary glands, and brain tissue [5]. During periods of immunosuppression, reactivation of latency or increased viral replication may occur and cause diseases including encephalitis, pneumonitis and marrow suppression [6]. HHV-6 reactivation in immunocompetent hosts is rarely documented. A study demonstrated that stress-related mechanisms, potentially involving cytokine or chemical mediators, result in the reactivation of HHV-6 [7]. HHV-6 has been linked to a variety of diseases, including hepatitis, myocarditis [8], meningitis/encephalitis [9], meningoencephalitis [5], encephalomyelitis [10, 11], chronic bone marrow suppression [12] and pneumonia [13]. It was believed HHV-6 may behave as an immunosuppressive pathogen to evade host immune responses in immunocompetent patients and also as an opportunistic pathogen in immunocompromised patients [5, 9-11]. HHV-6 associated acute lymphadenitis in immunocompetent patients is rare. Four case reports were found in English literature. William et al [14]

reported a 6 year old girl who presented with a morbilliform rash over her trunk and face lasting 48 hours. After this, she developed fever, sore throat and cervical lymphadenopathy over the subsequent three days and treated with ampicillin. All symptoms and signs resolved completely over the next four days. Akashi et al [15] reported a severe infectious mononucleosis-like syndrome in a 43 year old man presented with fever, bilateral cervical lymphadenopathy, mild splenomegaly and tonsillar pharyngitis who was infected with HHV-6 type B. Maric et al [16] reported two cases aged 28 and 56 of HHV-6 associated acute lymphadenitis in immunocompetent adults who presented with fever and generalized lymphadenopathy. They confirmed the presence of virus in CD4-positive T lymphocytes by immunohistochemistry, and electron microscopy and PCR identified distinctive features of HHV-6B.

The existence of atypical cells with large nucleus contained large, eosinophilic inclusion of HHV-6 associated acute lymphadenitis frequently result in a mistaken diagnosis of Hodgkin lymphoma (HL) and anaplastic large cell lymphoma (ALCL). The predominantly sinusal and paracortical distribution of the large lymphoid cells with eosinophilic inclusion, reactive lymphoid follicles should raise a serious concern for the possibility of HHV-6 associated lymphadenitis. In HHV-6 associated acute lymphadenitis, the large lymphoid cells with eosinophilic were negative for CD20, CD30, CD15, CD8, EBV-LMP, and were positive for CD3 and CD4 and the positivity of HHV-6 can confirm the diagnosis of HHV-6 associated acute lymphadenitis. The feature of HL is the presence of Reed-Sternberg cells and variants in the background of inflammatory cells. Classical diagnostic Reed-Sternberg cells are large, have abundant slightly basophilic cytoplasm and have at least two nuclear lobes or nuclei. The nuclei are large and often rounded in contour with a prominent nuclear membrane, pale chromatin and usually one prominent eosinophilic nucleolus. The Reed-Sternberg cells and variants are frequently positive for CD30 and CD15, and, the pattern of CD20 positivity is variable. The tumor cells of ALCL have abundant cytoplasm which may appear clear, basophilic or eosinophilic and eccentric, horse-shoe- or kidney-shaped nuclei often with an eosinophilic region near the nucleus. The nu-

clear chromatin is usually finely clumped or dispersed with multiple small, basophilic nucleoli. When the lymph node architecture is only partially effaced, the tumor characteristically grows within the sinuses and, thus, may resemble a metastatic tumor. Large T lymphocyte cell with abundant cytoplasm and deviated nucleus, which may positive for CD30, ALK, EMA, CD43, CD4, negative for CD20, is the characteristics of ALCL. CMV infection demonstrated partial effacement of the nodal architecture and numerous endothelial cells with typical CMV inclusions. In rare instances, infected T cells contain characteristic owl's eye inclusion bodies in expanded paracortical areas [16].

Prognosis of HHV6 associated acute lymphadenitis differs between cases. After received symptomatic treatment, most patients recovered well during the periods of follow-up. Only one case [16] expired with worsening liver failure and encephalopathy 17 day after admission. Our patient received antibiotics and was discharged from the hospital. He resolved well without fever and lymphadenopathy during 24 months of follow-up periods.

Acknowledgements

The authors are deeply grateful to Dr. John K.C. Chan of the Department of Pathology, Queen Elizabeth Hospital, Hong Kong for consultation of this case.

Disclosure of conflict of interest

None.

Address correspondence to: Dr. Zhaoming Wang, Department of Pathology, The First Affiliated Hospital, College of Medicine, Zhejiang University, 79 Qingchun Road, Hangzhou, Zhejiang 310003, PR China. Tel: +86-571-87236364; Fax: +86-571-87236570; E-mail: wangzhaoming1963@163.com

References

- [1] Salahuddin SZ, Ablashi DV, Markham PD, Josephs SF, Sturzenegger S, Kaplan M, Halligan G, Biberfeld P, Wong-Staal F, Kramarsky B. Isolation of a new virus, HBLV, in patients with lymphoproliferative disorders. *Science* 1986; 234: 596-601.
- [2] Human herpesvirus-6 strain groups: a nomenclature. *Arch Virol* 1993; 129: 363-366.
- [3] Dominguez G, Dambaugh TR, Stamey FR, Dewhurst S, Inoue N, Pellett PE. Human herpesvirus 6B genome sequence: coding content and comparison with human herpesvirus 6A. *J Virol* 1999; 73: 8040-8052.
- [4] Hall CB, Long CE, Schnabel KC, Caserta MT, McIntyre KM, Costanzo MA, Knott A, Dewhurst S, Insel RA, Epstein LG. Human herpesvirus-6 infection in children: A prospective study of complications and reactivation. *N Engl J Med* 1994; 331: 432-438.
- [5] Birnbaum T, Padovan CS, Sporer B, Rupprecht TA, Ausserer H, Jaeger G, Pfister HW. Severe meningoencephalitis caused by human herpesvirus 6 type B in an immunocompetent woman treated with ganciclovir. *Clin Infect Dis* 2005; 40: 887-889.
- [6] Clark DA, Griffiths PD. Human herpesvirus 6: relevance of infection in the immunocompromised host. *Br J Haematol* 2003; 120: 384-395.
- [7] Ihira M, Yoshikawa T, Ishii J, Nomura M, Hishida H, Ohashi M, Enomoto Y, Suga S, Iida K, Saito Y, Nishiyama Y, Asano Y. Serological examination of human herpesvirus 6 and 7 in patients with coronary artery disease. *J Med Virol* 2002; 67: 534-537.
- [8] Chang YL, Parker ME, Nuovo G, Miller JB. Human herpesvirus 6-related fulminant myocarditis and hepatitis in an immunocompetent adult with fatal outcome. *Hum Pathol* 2009; 40: 740-745.
- [9] Torre D, Mancuso R, Ferrante P. Pathogenic mechanisms of meningitis/encephalitis caused by human herpesvirus-6 in immunocompetent adult patients. *Clin Infect Dis* 2005; 41: 422-423.
- [10] Denes E, Magy L, Pradeau K, Alain S, Weinbreck P, Ranger-Rogez S. Successful treatment of human herpesvirus 6 encephalomyelitis in immunocompetent patient. *Emerg Infect Dis* 2004; 10: 729-731.
- [11] Novoa LJ, Nagra RM, Nakawatase T, Edwards-Lee T, Tourtellotte WW, Cornford ME. Fulminant demyelinating encephalomyelitis associated with productive HHV-6 infection in an immunocompetent adult. *J Med Virol* 1997; 52: 301-308.
- [12] Gompels UA, Luxton J, Knox KK, Carrigan DR. Chronic bone marrow suppression in immunocompetent adult by human herpesvirus 6. *Lancet* 1994; 343: 735-736.
- [13] Merk J, Schmid FX, Fleck M, Schwarz S, Lehane C, Boehm S, Salzberger B, Birnbaum DE. Fatal pulmonary failure attributable to viral pneumonia with human herpes virus 6 (HHV6) in a young immunocompetent woman. *J Intensive Care Med* 2005; 20: 302-306.
- [14] Irving WL, Cunningham AL. Serological diagnosis of infection with human herpesvirus type 6. *BMJ* 1990; 300:156-159

HHV-6 associated acute lymphadenitis in immunocompetent patients

- [15] Akashi K, Eizuru Y, Sumiyoshi Y, Minematsu T, Hara S, Harada M, Kikuchi M, Niho Y, Minamishima Y. Brief report: severe infectious mononucleosis-like syndrome and primary human herpesvirus 6 infection in an adult. *N Engl J Med* 1993; 329: 168-171.
- [16] Maric I, Bryant R, Abu-Asab M, Cohen JI, Vivero A, Jaffe ES, Raffeld M, Tsokos M, Banks PM, Pittaluga S. Human herpesvirus-6-associated acute lymphadenitis in immunocompetent adults. *Mod Pathol* 2004; 17: 1427-1433.