

## Case Report

# Myofibroblastic sarcoma in liver: a case report

Xiaoping Yi<sup>1</sup>, Desheng Xiao<sup>2</sup>, Xueying Long<sup>1</sup>

<sup>1</sup>Department of Radiology, Xiangya Hospital, Central South University, Changsha 410008, China; <sup>2</sup>Department of Pathology, Xiangya Hospital, Central South University, Changsha 410008, China

Received November 13, 2014; Accepted December 24, 2014; Epub January 1, 2015; Published January 15, 2015

**Abstract:** We recently encountered a giant Myofibroblastic sarcoma (MS) exceeding 23 cm in diameter which had developed in the liver in a 27-year-old female, and which was surgically resected with gratifying results. On surveillance imaging, a giant mass was detected in the right lobe of the liver. On the basis of morphology and immunohistochemistry features, the diagnosis of intermediate-grade myofibroblastic sarcoma (MS) was established. MS is extremely rarely found in the abdominal cavity. It is almost impossible to make a definite diagnosis before operation. However, the possibility of sarcoma should be taken into account for liver mass according to multimodal imaging features of the mass, especially when the diagnosis of common hepatic tumor was not supported by signs on imaging. Relative characteristic features on multimodal images maybe helpful to considerate the possibility of MS. This is the first reported case to date.

**Keywords:** Myofibroblastic sarcoma, liver, multimodal imaging, pathology

### Introduction

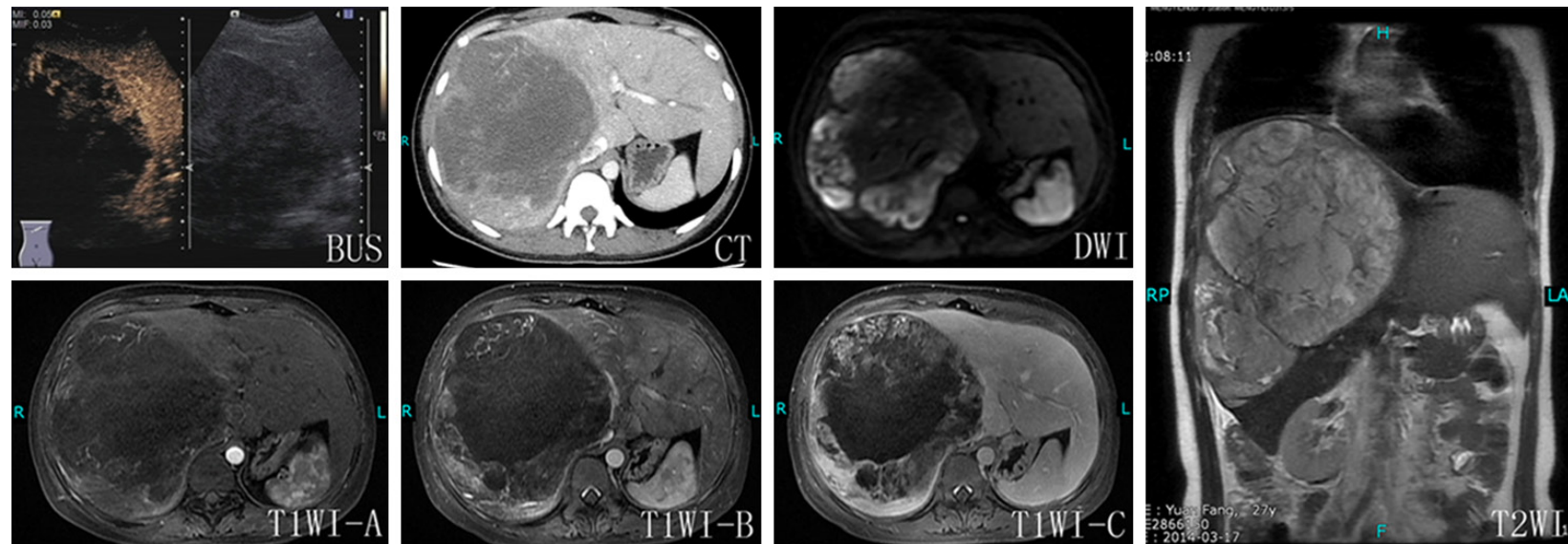
Cancers of the liver are an important cause of morbidity and mortality, and hepatocellular carcinoma represents the most common histological type. In contrast, primary liver sarcomas are exceedingly rare and represent only 1% to 2% of all primary liver tumors [1]. Myofibroblastic sarcoma (MS) is considered a distinct entity of soft tissue neoplasms, defined as an atypical myofibroblastic proliferation with fibromatosis-like features and a predilection for the head and neck. It is extremely rarely found in the abdominal cavity, and there have been only a few cases of GS reported worldwide [2-5]. This is the first description of MS in the liver to date. The report presents clinical, cross-sectional imaging (MRI and CT), histological, immunohistochemical, therapeutic findings of a young woman with MS in liver.

### Case report

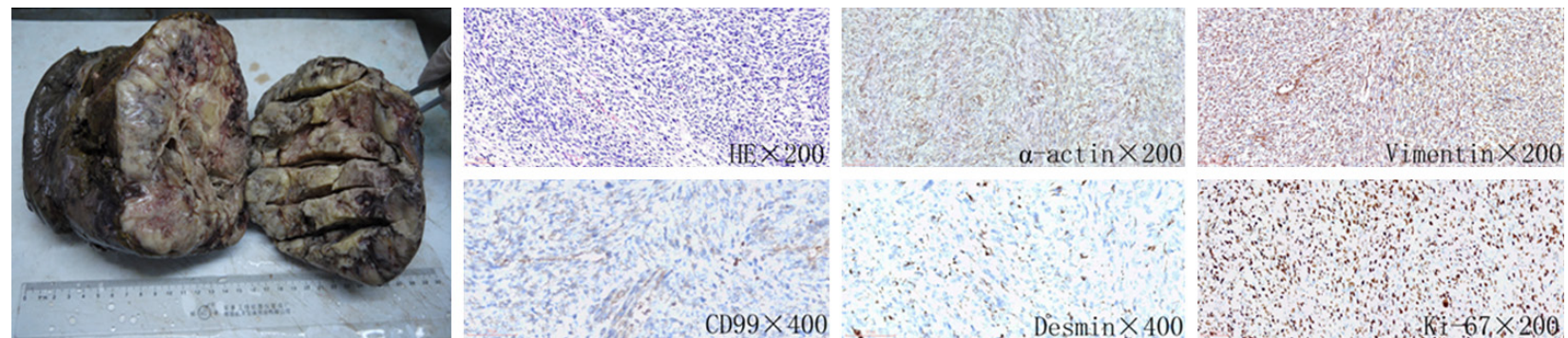
A 27-year-old woman, with a history of laparoscopic cholecystectomy due to gallstones, visited our hospital complaining of right-upper abdominal swelling pain for 2 months and lost approximately 4 Kg in weight. There was no history of hepatitis and cirrhosis. The general physical examination was unremarkable except for moderate hepatomegaly. Apart from elevated

LDH (>2 N), C-reactive protein (>5 N) and ESR (>3 N), other laboratory data, including tumor markers such as AFP, CEA and CA19-9, were within normal limits. Abdominal contrast-enhanced colored ultrasound (CEUS) revealed a huge heteroechoic mass in the right lobe of the liver with scatter peripheral blood signal and progressive concentric enhancement at delayed phases was detected. CT with dynamic contrast enhancement showed the lesion to be a round well-defined hypodense mass with mild to moderate inhomogeneous enhancement peripherally while the central portion remained unenhanced at the portal phase. Magnetic resonance imaging showed the tumor to be hyperintense with hypointense stripes throughout the tumor giving it a honeycomb appearance on the T2 weighted images, while on the precontrast enhanced T1 weighted imaging the tumor was homogeneously hypointense. Diffuse weighted imaging revealed the peripheral portion to be hyper-intense and the central portion to be hypo-intense. On the dynamic contrast enhanced images, the peripheral portion of the tumor has a patchy enhancement pattern at the early phase and the enhancement was prolonged with progressive centrally extension at the delayed phases, however large irregular non-enhanced area was observed at the central portion (**Figure 1**).

## Myofibroblastic sarcoma in liver



**Figure 1.** Abdominal imaging. BUS: contrast-enhanced colored ultrasound; CT: dynamic enhanced CT (port vein phase); DWI: diffuse weighted imaging; T1WI (dynamic contrast enhanced images of T1 weighted imaging)-A: early arterial phase, -B: late arterial phase, -C: port vein phases; T2WI: T2 weighted images.



**Figure 2.** Pathological finding of the tumor.

The patient subsequently underwent right hepatic trisegmentectomy; an enormous tumor, slightly adhered to nearby diaphragm with fibrous tissues, was almost occupying the entire right trisegment of the liver, and no tumors were detected in the peritoneal cavity. Histopathologically, the tumor composed of slender spindle shaped tumor cells arranged in interlacing fascicles or storiform pattern. The mitotic rate was moderate (6~8 per 10 high-power fields). Scattered necrosis and hemorrhage were seen. The tumor was positive for  $\alpha$ -SMA and vimentin, focally positive for desmin and CD99, and negative for ALK and h-caldesmon, with a high Ki-67 index (>60%) (**Figure 2**). On the basis of morphology and immunohistochemistry features, the diagnosis of intermediate-grade myofibroblastic sarcoma (MS) was established.

The patient was followed-up without postoperative radiation or adjuvant therapy. The patient was alive and well with no evidence of disease at 6 months after the surgery without any additional therapy.

### Discussion

Myofibroblasts are mesenchymal spindle cells that share ultrastructural features of both fibroblasts and smooth-muscle cells. Occasionally, myofibroblasts undergo tumorigenic transformation and become malignant tumor, which called MS. MS preferentially occurs at the extremity and the head and neck region. MS may occur in the patients of any age but usually develops during adulthood with a slight male predominance. It is considered to have a wide-ranging anatomic distribution but preferentially occurs at the extremity and the head and neck region. Although the tumor has a propensity to develop in the head and neck, MS has not been described in the liver. However, given the rare reports, the cytogenetic and molecular genetic alterations of the tumors are presently obscure and need to be investigated in further study.

The clinical course and symptoms of MS was usually non-specific such as slightly pain in the region involved. Even so, Symptoms do not show up until the tumor grows larger. Therefore, MS are generally indolent, especially when the tumor growth in the peritoneal cavity. According Miyazawa M et al. [2], the size of the tumors developing in the abdominal cavity and pelvis

are usually relatively larger than that of tumors originated in other regions such as head and neck region. This may be due to the fact that tumors developing in the abdominal cavity or pelvis are less palpable through the body surface as compared to those originated in other regions such as the oral cavity and the extremities. So, it is difficult to discover the tumor growing in abdominal region until the tumor grows large enough. The present patient had the lesion measured more than 23 cm. Thence, early detection sometimes becomes extremely difficult when tumors are in deep tissues especially in abdominal organs such as liver. In the present case, the tumor grew without pain and it was not until occupied the most of the right lobe of the liver became overt that the symptoms appeared.

The radiological features of MS have not been well-documented because of its rareness. FDG-PET maybe effective in detecting this occult tumor [6]. It is almost impossible to make a definite diagnosis before operation. However, the possibility of sarcoma should be taken into account for liver mass when the diagnosis of common hepatic tumor was not supported by signs on images. Multimodal imaging features of the tumor, such as described above, especially the characteristic honeycomb appearance on T2WI images and the progressive enhancement pattern just as appeared in the present case, maybe helpful to considerate the possibility of MS.

The exact diagnosis of MS relies on pathological and immunohistochemical findings. Histopathologically, MS is composed of slender spindle cells with eosinophilic cytoplasm, and fusiform, tapering, wavy, or plump ovoid; vesicular nuclei and small central eosinophilic nucleoli, which arranged in interlacing fascicles. Immunohistochemically,

MS is immunopositive for vimentin, SMA, muscle-specific actin, calponin and fibronectin, rarely immunopositive for desmin, and immunonegative for laminin and type IV collagen. On the basis of the morphological and immunohistochemical features the diagnosis of MS was rendered, and further evidence for the myofibroblastic derivation is highlighted by the presence of fibronexus, and an epithelial subepithelial anchoring structure by electron microscopy. In the present case, the tumor composed of



slender spindle shaped tumor cells arranged in interlacing fascicles or storiform pattern, which was positive for  $\alpha$ -SMA and vimentin, focally positive for desmin and CD99, and negative for ALK and h-caldesmon. Based on these findings, the patient was diagnosed with GS.

MS was graded according to the modified NCI system 6, in which the presence of necrosis (up to 15%) and six or more mitotic figures per 10 high power field (HPF) was considered to be grade 2. The present patient meets these criteria, and was defined as grade 2. LGMS has been reclassified as a distinct entity in the newly published World Health Organization classification of soft tissue tumors. High-grade (pleomorphic) myofibroblastic sarcomas were described as pleomorphic sarcomas composed of atypical spindle, polygonal and giant cells demonstrate marked hypercellularity, severe cytologic atypia, high mitotic rates, and necrosis [7]. According to Meng et al. [8] reports, MS of grade 1 are local aggressive lesions with frequent recurrence, so management by wide excision of the tumors with long-term follow-up is suggested. MS of grade 2 exhibit high recurrent rate and frequent metastasis, and should be managed by excision with a wide margin of normal tissue and adjuvant radiation therapy or systemic chemotherapy. However, Adjuvant chemotherapy or radiation therapy was conducted in some patients, but the therapeutic effect was unclear [9]. Surgical excision with negative margins has been the optimal therapy and a favorable prognosis maybe attained. The main clinical challenge has been the prevention of local recurrence, Therefore, any local recurrence should be detected as soon as possible by periodic imaging examinations. It has been also reported that the presence of increased proliferative activity and tumor necrosis was associated with more aggressive behavior [10]. In the present study, the patient was diagnosed as grade 2 MS with a high Ki-67 index (>60%). Based on this diagnosis, postoperative radiotherapy was recommended, but the patient refused. However, the good news is that there was no sign of recurrence and metastasis 6 months after surgery.

In summary, we described a MS that originated in the liver in the report herein. To the best of the authors' knowledge, this case is the first reported example of MS of the liver.

## Disclosure of conflict of interest

None.

**Address correspondence to:** Dr. Xueying Long, Department of Radiology, XiangYa Hospital, Central South University, 87 XiangYa Road, Changsha 410008, Hunan, China. Tel: +86-731-84327448; Fax: +86-731-84327448; E-mail: doctorlongxueying@126.com

## References

- [1] Stocker JT. Hepatic tumors in children. *Clin Liver Dis* 2001; 5: 259-81.
- [2] Miyazawa M, Naritaka Y, Miyaki A, Asaka S, Isohata N, Yamaguchi K, Murayama M, Shimakawa T, Katsube T, Ogawa K, Fujibayashi M. A low-grade myofibroblastic sarcoma in the abdominal cavity. *Anticancer Res* 2011; 31: 2989-94.
- [3] Mentzel T, Dry S, Katenkamp D, Fletcher CD. Low-grade myofibroblastic sarcoma: analysis of 18 cases in the spectrum of myofibroblastic tumors. *Am J Surg Pathol* 1998; 22: 1228-38.
- [4] Agaimy A, Wunsch PH, Schroeder J, Gaumann A, Dietmaier W, Hartmann A, Hofstaedter F, Mentzel T. Low-grade abdominopelvic sarcoma with myofibroblastic features (low-grade myofibroblastic sarcoma): clinicopathological, immunohistochemical, molecular genetic and ultrastructural study of two cases with literature review. *J Clin Pathol* 2008; 61: 301-6.
- [5] Montgomery E, Goldblum JR, Fisher C. Myofibrosarcoma: a clinicopathologic study. *Am J Surg Pathol* 2001; 25: 219-28.
- [6] Morii T, Mochizuki K, Sano H, Fujino T, Harasawa A, Satomi K. Occult myofibroblastic sarcoma detected on FDG-PET performed for cancer screening. *Ann Nucl Med* 2008; 22: 811-5.
- [7] Covello R, Licci S, Pichi B, Spriano G, Vidiri A, Morelli L, Rosenberg AE. Low-grade myofibroblastic sarcoma of the larynx. *Int J Surg Pathol* 2011; 19: 822-6.
- [8] Meng GZ, Zhang HY, Bu H, Zhang XL, Pang ZG, Ke Q, Liu X, Yang G. Myofibroblastic sarcomas: a clinicopathological study of 20 cases. *Chin Med J (Engl)* 2007; 120: 363-9.
- [9] Murakami Y, Tsubamoto H, Hao H, Nishimoto S, Shibahara H. Long-term disease-free survival after radical local excision of low-grade myofibroblastic sarcoma of the vulva. *Gynecol Oncol Case Rep* 2013; 5: 34-6.
- [10] Saito T, Mitomi H, Kurisaki A, Torigoe T, Takagi T, Suehara Y, Okubo T, Kaneko K, Yao T. Low-grade myofibroblastic sarcoma of the distal femur. *Int J Surg Case Rep* 2013; 4: 195-9.