

# Related factors of outcomes of pharyngeal foreign bodies in children

SAGE Open Medicine

Volume 5: 1–7

© The Author(s) 2017

Reprints and permissions:

[sagepub.co.uk/journalsPermissions.nav](http://sagepub.co.uk/journalsPermissions.nav)

DOI: 10.1177/2050312117724057

[journals.sagepub.com/home/smo](http://journals.sagepub.com/home/smo)

Zhenghua Huang<sup>1</sup>, Peng Li<sup>1</sup>, Lisheng Xie<sup>1</sup>, Jing Li<sup>2</sup>,  
Honggen Zhou<sup>1</sup> and Qi Li<sup>1</sup>

## Abstract

**Objective:** This study aimed to identify factors related to outcomes of the pharyngeal foreign bodies in children and to improve the management protocol of this disease.

**Methods:** The medical records of 131 children with pharyngeal foreign bodies hospitalized in the hospital were retrospectively reviewed.

**Results:** Significant differences were observed between the two groups (dislodgement and removal group) with respect to location of pharyngeal foreign bodies and age, while sex, time of pharyngeal foreign bodies, and nature of pharyngeal foreign bodies had no significant differences. Moreover, results suggested that location of pharyngeal foreign bodies and nature of pharyngeal foreign bodies were risk factors correlated with complications.

**Conclusion:** Pharyngeal foreign body in children has a high rate of dislodgement (>50%). Foreign bodies in the oropharynx were more likely to dislodge compared with the foreign bodies in the laryngopharynx. Younger children were more likely to dislodge compared with older children. Although the risk of complications was very low, attention needs to be paid to the potential risks: local infection, deep abscess, and migration of foreign bodies. Because the possibility of complications caused by bone fragments and foreign bodies in the laryngopharynx increase obviously, hence, it is suggested to remove these kinds of foreign bodies as soon as possible to prevent complications.

## Keywords

Abscess, children, dislodgement, foreign body, migration

Date received: 9 April 2017; accepted: 10 July 2017

## Introduction

Pharyngeal foreign body (PFB) is a common emergency in children. Fish bone was the commonest foreign body (FB) encountered in the pharynx.<sup>1–4</sup> The management of PFB in children is more difficult in children than in adults.<sup>5</sup> Most PFBs are removed in the outpatient department. Only a few children lack cooperation and need extracting FBs in the hospital under general anesthesia. In clinical practice, many PFBs in children are dislodged spontaneously before presentation. However, many reports have been associated with complications of PFBs, such as infections of the pharyngeal wall, retropharyngeal abscess, migration of FB, and even death.<sup>6–9</sup>

Spontaneous dislodgement and no complications of FBs are the results that doctors and parents expect. Factors inducing dislodgement and factors causing complications need to be explored. Some studies referred to the dislodgement of PFBs;<sup>4,5</sup> however, they did not investigate the related factors. Some studies analyzed the risk factors of

complications after FB ingestion, but the cases they choose were mostly adults. Moreover, they often discussed PFBs, esophageal FBs, and FBs in the gastrointestinal tract together.<sup>4,10</sup> At present, reports of complications caused by PFBs in children are limited. Therefore, this study aimed to identify the factors related to the outcomes of PFBs in children. The findings would help to relieve parental anxiety and reduce complications.

<sup>1</sup>Department of Otorhinolaryngology, Children's Hospital of Nanjing Medical University, Nanjing, P.R. China

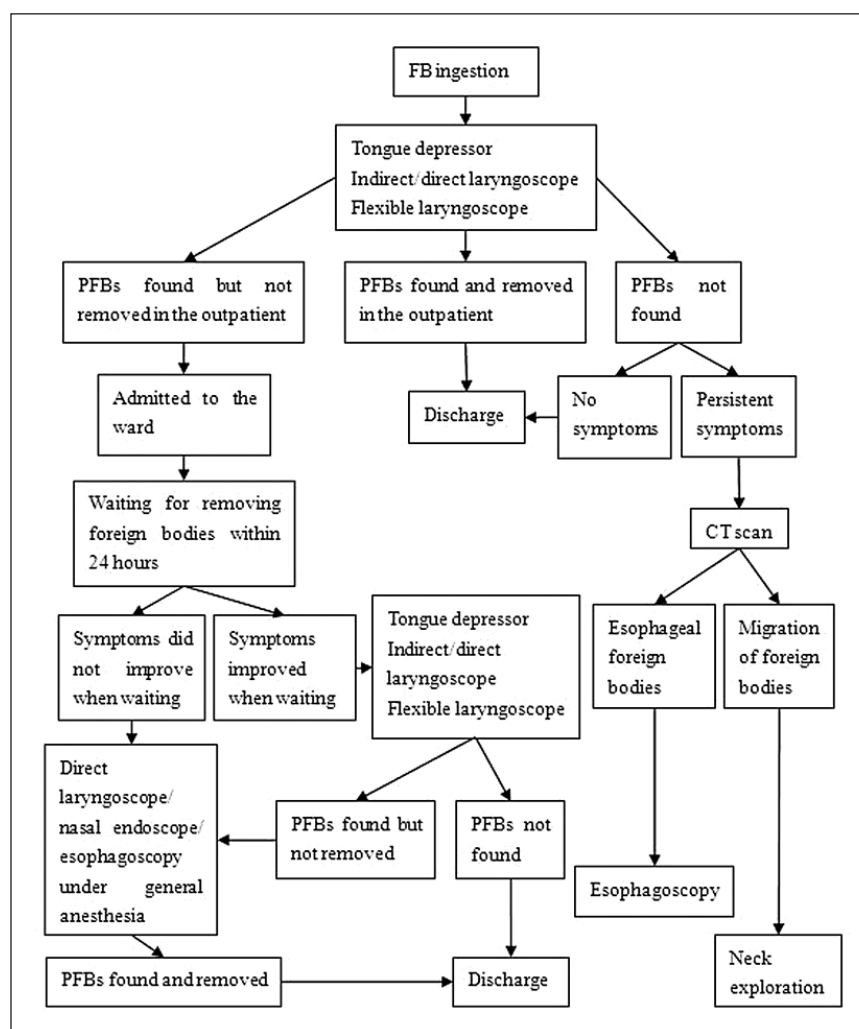
<sup>2</sup>Department of Gastroenterology, Jiaozuo Renmin Hospital, Jiaozuo, P.R. China

### Corresponding author:

Qi Li, Department of Otorhinolaryngology, Children's Hospital of Nanjing Medical University, 72 Guangzhou Road, Nanjing 210008, Jiangsu, P.R. China.

Email: [liqi71520@hotmail.com](mailto:liqi71520@hotmail.com)





**Figure 1.** Management protocol of PFBs in children in the ENT department.

## Materials and methods

### Clinical data

The medical records of 131 children with PFB hospitalized in the Children's Hospital of Nanjing Medical University (69 males and 62 females; age range: 3 months to 12 years) from January 2010 to April 2016 were reviewed in this study. Demographic data, duration of PFBs, nature of PFBs, location of PFBs, clinical presentation, radiological findings, endoscopic examination, outcome, and management of the PFBs were recorded and tabulated on database.

The exclusion criteria were as follows: PFBs caused by traumatism and FBs had completely entered into the esophageal or laryngeal cavity.

### Research methods

**Diagnosis and treatment.** The diagnostic techniques for PFBs in the hospital include tongue depressor, transnasal laryngoscope,

indirect laryngoscope, direct laryngoscope, x-ray, and computed tomography (CT) scan. All patients suspected of FB ingestion were treated followed by the management protocol of PFBs in our hospital (see Figure 1).

General anesthesia was induced with fentanyl 1.5 µg/kg and propofol 1.5 mg/kg. For FBs in the nasopharynx, Davis mouth gag was used to open the mouth, a sputum suction tube was used to hang up the soft palate, and the FBs were removed using the artery forceps guided by a rigid 70° video nasal endoscope into the mouth. The FBs in the oropharynx and laryngopharynx were removed under direct laryngoscope. Sometimes esophagoscopy was required when the FBs were buried in the mucosa of the postcricoid.

**Duration of the PFB.** Duration of FB taken out was calculated from the moment of ingestion until inpatient surgery, daily (less than 1 day was calculated as 1 day). Duration of FB dislodged was measured from the ingestion until finding dislodgement of the FB, with daily precision.

**Table 1.** Nature of foreign bodies and diagnostic tools before hospitalization.

Nature of foreign bodies	Diagnostic methods			
	Tongue depressor	X-ray	CT scan	Transnasal laryngoscope
Fish bone	1	0	1	109
Bone fragment	0	1	7	2
Other foreign bodies	2 <sup>a</sup>	0	0	8 <sup>b</sup>

CT: computed tomography.

<sup>a</sup>Other foreign bodies include one hair and one awn of wheat.

<sup>b</sup>Other foreign bodies include three broken melon seeds, one splinter, two steel wires, and two unknown foreign bodies.

**Classification of outcomes of the PFBs.** The children were divided into two groups: dislodgement group (DG) and removal group (RG). The DG includes three subgroups: FBs not found next morning verified by diagnostic methods, no FBs found via direct laryngoscope under general anesthesia, and symptoms disappear when waiting and discharge without complications. The complications include infections of the pharyngeal wall, abscess formation, perforation, and migration of FB.

### Statistical analysis

Data analysis was conducted using SPSS software (version 13.0). Measurement data were expressed as  $\bar{x} \pm s$ . The Student *t* test was used for statistical analysis. The  $\chi^2$  test or Fisher's exact test was used for enumeration data. A *p* value less than 0.05 was considered as statistically significant.

## Results

### Nature of FBs and diagnostic methods

The fish bone contributed to 84.7% of the cases. Flexible laryngoscope is the most useful diagnostic tool in detecting PFBs (Table 1).

### Locations of FBs and diagnostic methods

Maximum FBs were found in the oropharynx, about 83.2%. Flexible laryngoscope was useful tool in identifying PFBs lodged in different parts of the pharynx (Table 2).

### Outcomes and complications

Outcomes of PFBs were observed in this study. In the RG, most FBs were taken out via direct laryngoscope. In the DG, there were no complications (Table 3).

Of the 131 patients, 4 patients had complications, all in the RG. They were all caused by primary disease; no procedure-related complications were reported. The FBs in these four cases were all bone fragments. Two cases had wound

**Table 2.** Locations of foreign bodies and diagnostic methods before hospitalization.

Locations of foreign bodies	Diagnostic methods			
	Tongue depressor	X-ray	CT scan	Transnasal laryngoscope
Nasopharynx	0	0	1	5
Oropharynx	3	1	3	102
Uvula	2	0	0	0
Tonsil	1	0	0	45
Vallecula	0	0	0	40
Base of tongue	0	1	3	17
Laryngopharynx	0	0	4	12
Pyriform sinus	0	0	0	6
Postcricoid	0	0	2	2
Posterior wall of laryngopharynx	0	0	2	2
Lateral wall of laryngopharynx	0	0	0	2

CT: computed tomography.

**Table 3.** Outcomes of PFBs in children after hospitalization.

Group	Management	Total	CG
RG	Extraction via nasal endoscope under general anesthesia	4	0
	Extraction via direct laryngoscope under general anesthesia	59	3
	Removed by esophagoscopy under general anesthesia	1	1
DG	Foreign bodies not found next morning by diagnostic methods	45 <sup>a</sup>	0
	No foreign bodies found via direct laryngoscope under general anesthesia	14 <sup>b</sup>	0
	Symptoms disappear when waiting and discharge without complications	8	0

RG: removal group; DG: dislodgement group; CG: complication group; PFBs: pharyngeal foreign bodies.

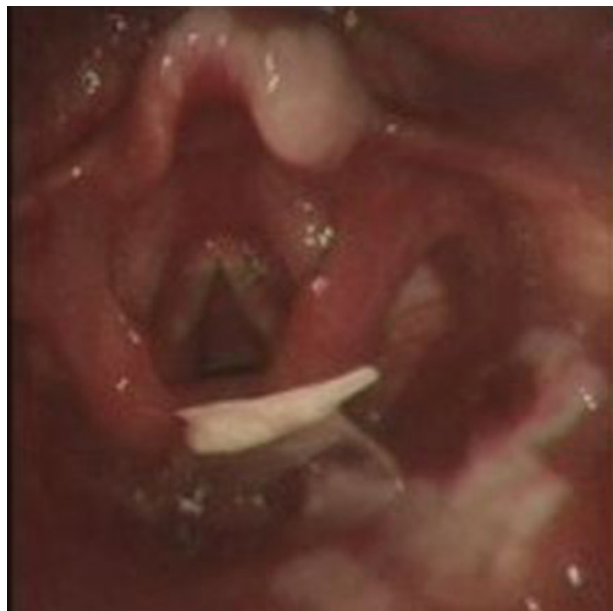<sup>a</sup>Of which 43 using transnasal laryngoscope, 1 with tongue depressor, and 1 with computed tomography (CT) scan.

<sup>b</sup>Of which 3 with additional esophagoscopy and 1 with additional gastroscopy because of parental anxiety.

infections of the pharynx (Figure 2). Two cases had a deep abscess (Figures 3 and 4), with FB migration locally in one of these cases. The clinical data of these four cases are shown in Table 4.

### Factors causing dislodgement of PFBs

Of the 131 cases in this study, the dislodgement incidence exceeded 50%. Univariate analysis showed significant differences between the two groups (DG and RG) with respect



**Figure 2.** Case 2: electronic laryngoscope showing irregular bone pieces as foreign bodies embedded in the laryngopharyngeal wall and a large piece of erosion near the foreign body.

to location of PFBs and age, while sex, time of PFBs, and nature of PFBs had no significant differences. The dislodgement incidence of FBs in the oropharynx was the highest (56.88%), while that of FBs in the laryngopharynx was the lowest (18.75%). Children less than 3 years old have a dislodgement incidence of up to 66.7% (Table 5).

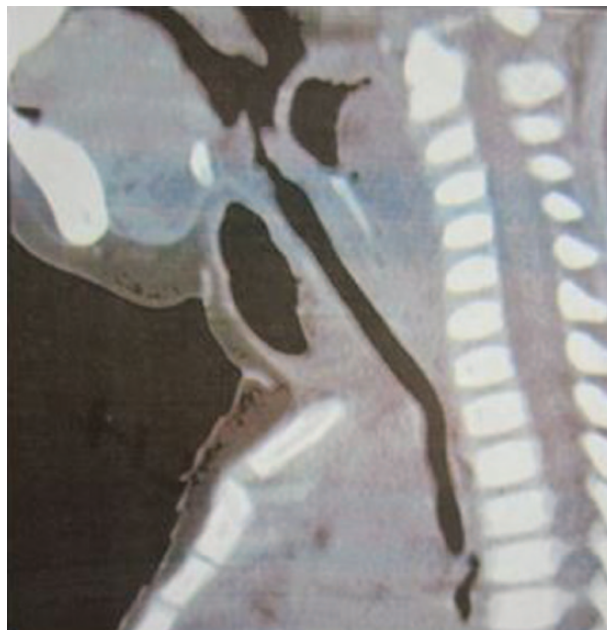### *Factors causing complications with PFBs*

Results suggested that location of PFBs and nature of PFBs were risk factors correlated with complications. The complication incidence of FBs in the laryngopharynx was high (25%), it was especially high in two parts of the laryngopharynx: postcricoid (50%) and posterior wall of the laryngopharynx (50%). Moreover, the complication incidence in patients with bone fracture reached 44.44% (Table 6).

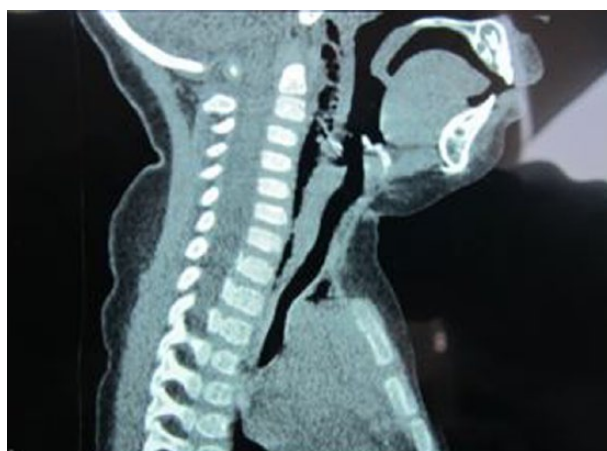
## **Discussion**

Ingested fish bones in the pharynx are common in East Asia, probably as a result of the custom of eating fish without prior removal of bones.<sup>2</sup> The hospital is a tertiary facility. At least 1000 cases of suspected PFB are admitted to the hospital every year. Most children are admitted to the hospital within 24 h. When the FBs cannot be removed in the outpatient clinics, the patients are admitted to the ward for observation and therapy because of potential risks.<sup>4</sup>

The flexible laryngoscope is a safe, effective, and well-tolerated diagnostic tool for PFBs, it is worldwide accepted and recommended. However, when endoscopy results are



**Figure 3.** Case 3: CT showing that the cone-shaped bone fragments migrated to the tissue of postcricoid, and air and abscess were found around the neck.



**Figure 4.** Case 4: CT showing an irregular bone as foreign body piercing into the tissue of postcricoid and causing emphysema of the pharyngeal wall.

negative and symptoms are persistent, CT scan is suggested. Table 2 shows that the doctors were more likely to choose CT for complaints of bone fragment ingestion because bone fragment could easily cause trauma and enter into the esophagus. CT is useful to determine the exact location of the FB and its relationship to the vital structures in the neck. It allows the surgeon to locate the FB during an exploration of the neck.<sup>6</sup> X-ray is useful in detecting bone chips and metal FBs. It should be considered when flexible laryngoscope and



**Table 4.** Details of four patients with complications caused by PFBs.

Case number	Age (years)	Sex	Time (days)	Nature of foreign body	Location of foreign body	Treatment and prognosis
1	4.9	Male	4	Bone fragment (chicken feet)	Posterior wall of laryngopharynx	The patient presented with fever and dysphagia; antibiotics alone were prescribed after taking out the foreign body, and the patient was discharged on the postoperative day 5
2	2	Male	2	Bone fragment (fish head)	Posterior wall of laryngopharynx	The foreign body was removed using direct laryngoscope; the patient received antibiotic treatment for 3 days and was discharged against medical advice
3	1.25	Male	9	Bone fragment (pig bone)	Postcricoid	The foreign body was extracted by direct laryngoscope combined with esophagoscopy. The wound and abscess were also drained during the operation, but the patient presented with breathing difficulties the next day. Due to obvious swelling of the neck, neck incision and tube drainage of pus were performed. After about a month of antibiotic treatment and drainage of the abscess, the patient was cured and discharged
4	1.25	Male	1	Bone fragment (fish head)	Postcricoid	The patient presented with fever when admitted to the hospital. After taking out the foreign bodies and giving intravenous antibiotics for 2 days, the patient was discharged against medical advice

PFBs: pharyngeal foreign bodies.

CT scan are not available.<sup>7</sup> Due to the specialty of PFBs in children, three cases of FBs were found using a tongue depressor but not removed in the outpatient clinic.

This study aimed to find the related factors affecting dislodgement and complications of PFBs in children. The findings would help in improving management protocol of this disease.

FBs in the oropharynx were more likely to dislodge compared with the FBs in the laryngopharynx, probably due to the powerful movement of the tongue and also due to the larger diameter of the oropharynx. The pharynx is considered as an inverted cone. The postcricoid and posterior wall of the laryngopharynx are at the tip of the cone. A narrow gap is present between the laryngopharynx and the esophagus. The FBs are easy to block in this gap and do not get easily dislodged. Younger children with PFB have a high rate of dislodgement, probably due to three reasons. First, younger children have weak muscles, and the swallowing function is not very strong; hence, the FBs pierce the tissue superficially. Second, infants with PFBs often refuse to eat,<sup>5</sup> which avoids extrusion of FBs into deep tissue. Third, infants are prone to crying, nausea, and vomiting, which increases the elimination of FBs.

The possibility of complications caused by bone fragments and FBs in the laryngopharynx increases obviously, consistent with other studies.<sup>4,6</sup> This might be because of the anatomical structure, the retropharyngeal and parapharyngeal spaces were around the laryngopharynx. The shape of fractured bones was irregular, and the surface was sharp and piercing. Hence, they could penetrate the mucosa, cause large wounds, and form deep cavities. Food residues and secretions accumulated in the wound could easily cause infection, abscess, and perforation. These factors contributed to the high risk of complications.

Some researchers believed that the retention time of FBs was related to the complications. Singh et al.<sup>10</sup> found that the retention of FBs for more than 24 h is a major risk factor causing complications in children less than 10 years old. The findings conflicted with the findings of this study. This study found no relationship between retention time and the complications of PFBs in children, probably because of the different choices of subjects. The complications in adults were reported in most published series, but the reports were fewer in children. Most common complications of PFBs were local infection and abscess formation.<sup>11,12</sup> Serious complications were perforation and migration of FBs.<sup>13,14</sup> The clinical data of current 6 years were analyzed. Only one case (case 3) was observed in which the bone fracture migrated into the posterior pharyngeal wall 9 days later. However small the risk of migration of PFBs is, awareness should be raised.

Some researchers reported that once the ingested FB progressed into the lower digestive tract, it could be discharged naturally.<sup>15–18</sup> Therefore, for the children with FB dislodgement in the hospital, a trial diet was usually suggested. If the patients had no complications, they would be discharged. However, Norberg and Reyes<sup>19</sup> reported a case of a 14-month-old boy who ingested an ornamental Christmas bulb causing repeated rectal bleeding, a large ischiorectal abscess, and perforation of the ileum. Burstein et al.<sup>20</sup> reported four cases of children with ingested FB causing bowel obstruction and perforation. Aduful<sup>21</sup> reported that ingested bone chips could cause perforation and obstruction of the anus. Therefore, a period of follow-up was necessary when the FB moved into the lower digestive tract. All patients in this study were followed up for 1 month after discharge, and no short-term complications were reported.

To avoid complications of PFBs, after FB removal, purulent secretions were drained and the wound was washed.

**Table 5.** Factors causing dislodgement of PFBs.

Variable	RG	DG	p value
N	64	67	
Age (years)			0.011*
≤3	16	30	
3–6	22	21	
≥6	26	16	
Sex			0.804
Male	33	36	
Female	31	31	
Duration of PFBs (h)			0.133
0–24	30	44	
25–48	21	17	
49–72	10	4	
>72	3	2	
Nature of PFBs			0.613
Fish bone	53	59	
Bone fragment	6	3	
Others <sup>a</sup>	5	5	
Location of PFBs			0.007*
Nasopharynx	4	2	
Oropharynx	47	62	
Uvula	0	2	
Tonsil	21	25	
Vallecula	18	22	
Base of tongue	8	13	
Laryngopharynx	13	3	
Pyriform sinus	3	3	
Postcricoids	4	0	
Posterior wall of laryngopharynx	4	0	
Lateral wall of laryngopharynx	2	0	

N: number of cases; RG: removal group; DG: dislodgement group; PFBs: pharyngeal foreign bodies.

<sup>a</sup>Other foreign bodies include three broken melon seeds, two steel wires, one splinter, one hair, one awn of wheat, and two unknown foreign bodies.

\* $p < 0.05$ , the difference was statistically significant.

Sometimes the abscesses may recur and cause severe upper airway obstruction, which may be life-threatening if not promptly treated. Fortunately, the four cases with complications were all cured and discharged without sequelae.

This study had certain limitations. First, the number of complications was low; hence, large-sample multicenter studies were required to verify the results. Second, PFBs treated in the outpatient clinic were excluded from this study due to incomplete information. Third, some studies reported that FBs could be easily removed by transnasal laryngoscopy with biopsy forceps in the outpatient clinic, even in children.<sup>5,22,23</sup> However, the transnasal laryngoscope used in this study was not equipped with biopsy forceps, which might have affected the results.

Ethical approval was sought for this study by independent ethics committee (IEC) of Children's Hospital

**Table 6.** Factors causing complications with PFBs.

Variable	Total	CG	p value
N	131	4	
Age (years)			0.099
≤3	46	3	
3–6	43	1	
≥6	42	0	
Sex			0.121
Male	69	4	
Female	62	0	
Duration of PFBs (h)			0.181
0–24	74	0	
25–48	38	1	
49–72	14	1	
>72	5	2	
Nature of PFBs			<0.001*
Fish bone	112	0	
Bone fragment	9	4	
Others <sup>a</sup>	10	0	
Location of PFBs			<0.001*
Nasopharynx	6	0	
Oropharynx	109	0	
Uvula	2	0	
Tonsil	46	0	
Vallecula	40	0	
Base of tongue	21	0	
Laryngopharynx	16	4	
Pyriform sinus	6	0	
Postcricoid	4	2	
Posterior wall of laryngopharynx	4	2	
Lateral wall of laryngopharynx	2	0	

N: number of cases; CG: complication group; PFBs: pharyngeal foreign bodies.

<sup>a</sup>Other foreign bodies include three broken melon seeds, two steel wires, one splinter, one hair, one awn of wheat, and two unknown foreign bodies.

\* $p < 0.05$ , the difference was statistically significant.

affiliated to Nanjing Medical University (approval number: 201701022).

## Conclusion

PFBs in children have a high rate of dislodgement. FBs in the nasopharynx and oropharynx are more likely to dislodge. Also, the risks of complications in these parts are rare. If the FB cannot be removed immediately, it can be closely observed for 24 h. If no dislodgement is observed the next day, the FB needs to be removed. The PFBs in the laryngopharynx, especially bone fractures, because of the high incidence of complications, should be removed immediately without waiting. When the FB is removed, the prognosis is mostly uneventful after timely treatment of complications.

## Acknowledgements

The authors would like to thank other doctors in the ENT department who were involved in the treatment and follow-up of the enrolled children. Z.H. and P.L. contributed equally to this work.

## Declaration of conflicting interests

The author(s) declared no potential conflicts of interest with respect to the research, authorship, and/or publication of this article.

## Ethical approval

Ethical approval for this study was obtained from IEC of Children's Hospital affiliated to Nanjing Medical University (approval number: 201701022)\*.

## Funding

The author(s) received no financial support for the research, authorship, and/or publication of this article.

## Informed consent

Informed consent was not sought for this study because it was a retrospective study and noninvasive.

## References

1. Watanabe K, Amano M, Nanome A, et al. The prolonged presence of a fish bone in the neck. *Tohoku J Exp Med* 2012; 227: 49–52.
2. Yang CY and Yang CC. Subjective neck pain or foreign body sensation and the true location of foreign bodies in the pharynx. *Acta Otolaryngol* 2015; 135: 177–180.
3. Endican S, Garap JP and Dubey SP. Ear, nose and throat foreign bodies in Melanesian children: an analysis of 1037 cases. *Int J Pediatr Otorhinolaryngol* 2006; 70: 1539–1545.
4. Lai ATY, Chow TL, Lee DTY, et al. Risk factors predicting the development of complications after foreign body ingestion. *Brit J Surg* 2003; 90: 1531–1535.
5. Pak MW, Lee WC, Fung HK, et al. A prospective study of foreign-body ingestion in 311 children. *Int J Pediatr Otorhinolaryngol* 2001; 58: 37–45.
6. Mamede RCM, Amaral F, Raimundo DG, et al. Do foreign bodies migrate through the body towards the heart? *Braz J Otorhinolaryngol* 2009; 75: 195–199.
7. Unadkat SN, Talwar R and Tolley N. The eye in the neck: removal of a sewing needle from the posterior pharyngeal wall. *Case Report Med* 2010; 8: 1–3.
8. Hartmann RW. Recognition of retropharyngeal abscess in children. *Am Fam Physician* 1992; 46: 193–196.
9. Costa L, Larangeiro J, Moura CP, et al. Foreign body ingestion: rare cause of cervical abscess. *Acta Med Port* 2014; 27: 743–748.
10. Singh B, Kantu M, Har-El G, et al. Complications associated with 327 foreign bodies of the pharynx, larynx, and esophagus. *Ann Otol Rhinol Laryngol* 1997; 106: 301–304.
11. Coulthard M and Isaacs D. Retropharyngeal abscess. *Arch Dis Child* 1991; 66: 1227–1230.
12. Sethi DS and Chew CT. Retropharyngeal abscess—the foreign body connection. *Ann Acad Med Singapore* 1991; 20: 581–588.
13. Yadav SP, Chanda R, Malik P, et al. Ingested nail penetrating the neck in an infant. *Int J Pediatr Otorhinolaryngol* 2002; 65: 159–162.
14. Landis BN and Giger R. An unusual foreign body migrating through time and tissues. *Head Face Med* 2006; 2: 1–3.
15. Webb WA. Management of foreign bodies of the upper gastrointestinal tract: update. *Gastrointest Endosc* 1995; 41: 39–51.
16. Macgregor D and Ferguson J. Foreign body ingestion in children: an audit of transit time. *J Accid Emerg Med* 1998; 15: 371–373.
17. A-Kader HH. Foreign body ingestion: children like to put objects in their mouth. *World J Pediatr* 2010; 6: 301–309.
18. Panieri E and Bass DH. The management of ingested foreign bodies in children—a review of 663 cases. *Eur J Emerg Med* 1995; 2: 83–87.
19. Norberg HP and Reyes HM. Complications of ornamental Christmas bulb ingestion, case report and review of the literature. *Arch Surg* 1975; 110: 1494–1497.
20. Burstein I, Steinberg R and Zer M. Small bowel obstruction and covered perforation in childhood caused by bizarre bezoars and foreign bodies. *Isr Med Assoc J* 2000; 2: 129–131.
21. Aduful HK. Anal pain secondary to swallowed bone. *Ghana Med J* 2006; 40: 31–32.
22. Sato K. Extraction of minute pharyngeal foreign bodies with the videoendoscope. *Ann Otol Rhinol Laryngol* 2003; 112: 693–696.
23. Tamura K, Kim M, Abe K, et al. A new video laryngo-pharyngoscope with shape-holding coiled tube and surgical forceps: a preliminary study. *Auris Nasus Larynx* 2009; 36: 677–681.