

Induction Chemotherapy for p16 Positive Oropharyngeal Squamous Cell Carcinoma

Yuki Saito, MD, PhD; Mizuo Ando, MD, PhD; Go Omura, MD; Kazuo Yasuhara, MD;
Masafumi Yoshida, MD, PhD; Wataru Takahashi, MD, PhD; Tatsuya Yamasoba, MD, PhD

Objectives/Hypothesis: We aimed to determine the effectiveness of induction chemotherapy for treating p16-positive oropharyngeal cancer in our department.

Study Design: This was a retrospective case series to assess treatment effectiveness.

Methods: We administered induction chemotherapy to patients with stage III to IV oropharyngeal p16-positive squamous cell carcinoma between 2008 and 2013. Induction chemotherapy was administered using combinations of docetaxel, cisplatin, and 5-fluorouracil. We measured the survival rates using the Kaplan-Meier method and log-rank test.

Results: We reviewed 23 patients (18 men and 5 women; age, 42–79 years). Induction chemotherapy resulted in partial or complete remission (20 patients) and in stable (2 patients) or progressive (1 patient) disease. In partial or complete remission, subsequent radiotherapy was performed in 16 patients, chemoradiotherapy in two, and transoral resection in two. In stable or progressive disease, subsequent open surgery was performed. Overall, one patient died of cervical lymph node metastasis, one died of kidney cancer, and one died of myocardial infarction. Event-free, distant-metastasis-free survival was present for 20 patients. The 3-year disease-specific survival was 95%; the overall survival was 87%. Two patients required gastrostomies during chemoradiotherapy and three required tracheotomies, but these were closed in all patients.

Conclusion: The therapeutic response to induction chemotherapy for p16-positive oropharyngeal cancer was good. Partial or complete remission was achieved in almost 90% patients, and control of local and distant metastases was possible when it was followed by radiotherapy alone or with transoral resection of the primary tumor. A multicenter study is required to confirm these findings.

Key Words: Oropharyngeal carcinoma, induction chemotherapy, p16, human papillomavirus.

Level of Evidence: 4.

INTRODUCTION

Traditional treatment for advanced oropharyngeal squamous cell carcinoma (OPSCC) has involved surgical removal through a transmandibular or lower cheek flap approach. However, poor functional outcomes have led clinicians to explore alternative options, including the use of concurrent chemoradiotherapy.¹ Although locoregional control is effective and not inferior to ablative surgery,² concurrent chemoradiotherapy can be associated with significantly delayed toxicity and adverse function.³

Human papillomavirus (HPV)-associated OPSCC is rapidly increasing in incidence and has unique epidemiologic, molecular, and biologic characteristics.^{4,5} Of note, these patients have a younger median age at disease onset,⁶ and therefore tend to live longer with the adverse effects of standard chemoradiotherapy. This has in turn prompted the development of treatment deintensification trials that try to decrease the incidence of treatment-related adverse effects. In other research, minimally invasive surgical techniques are being evaluated for transoral resection, such as transoral laser microsurgery⁷ and transoral robotic surgery⁸ in the United States and transoral videolaryngosurgery⁹ in Japan. However, these new surgical methods are not ideal; not only are they limited to localized tumor (T) classification disease, but they also are associated with the potential for catastrophic bleeding.

Data from clinical trials support the use of induction chemotherapy, followed by radiotherapy, for nonsurgical preservation of the larynx in patients with advanced laryngeal or hypopharyngeal carcinoma. The Department of Veterans Affairs trial established the feasibility of laryngeal preservation without reducing survival using induction with cisplatin and 5-fluorouracil (i.e., the *PF regimen*) followed by radiotherapy.¹⁰ The pattern of failure in this study revealed a significantly lower rate of metastases. A higher response rate was observed with the addition of docetaxel (i.e., the *TPF regimen*) than with the *PF*

This is an open access article under the terms of the Creative Commons Attribution-NonCommercial-NoDerivs License, which permits use and distribution in any medium, provided the original work is properly cited, the use is non-commercial and no modifications or adaptations are made.

From the Department of Otolaryngology and Head and Neck Surgery (Y.S., M.A., G.O., K.Y., M.Y., T.Y.); and the Department of Radiology (W.T.), University of Tokyo, Tokyo, Japan.

Editor's Note: This Manuscript was accepted for publication 20 February 2016.

Funding Information: This work was supported by JSPS KAKENHI Grant Number 25861531.

The authors have no other funding, financial relationships, or conflicts of interest to disclose.

Send correspondence to Yuki Saito, MD, PhD, Department of Otolaryngology, Head and Neck Surgery, University of Tokyo, 7-3-1, Hongo, Bunkyo-ku, Tokyo 113-8655, Japan. E-mail: saitou-ty@umin.ac.jp

DOI: 10.1002/liv.2.18

regimen, and it was postulated that induction TPF could improve the rates of laryngeal preservation and local control in mixed-site locally advanced head and neck squamous cell carcinoma (HNSCC).¹¹ Subset analysis also confirmed that the overall survival (OS) and progression-free survival (PFS) rates were better for HPV-positive OPSCC than for HPV-negative OPSCC.

Induction chemotherapy for locally advanced HNSCC has some important limitations. Of note, induction TPF therapy was frequently associated with adverse effects and had mortality rates of 2% and 3% in the TAX 324 and TAX 323 trials, respectively.¹² Furthermore, the TPF regimen followed by radiation plus high-dose cisplatin is not feasible for general use, and thus induction chemotherapy is not currently used as a standard treatment for locally advanced HNSCC.

When seeking to establish a deintensification therapy for HPV-positive OPSCC, the unique tumor biology factors need to be considered. HPV-positive OPSCCs have favorable local or locoregional control with standard treatment, but they also have equivalent risk for distant metastasis when compared with HPV-negative OPSCC.¹³ Reducing the dose of chemotherapy by 80% can reduce the adverse effect burden and increase the ease of clinical use. Therefore, we investigated the effects of reduced-dose induction TPF followed by radiation therapy or transoral resection on the outcomes of locally advanced HPV-positive OPSCC in a clinical setting.

MATERIALS AND METHODS

Study Design and Patient Selection

We reviewed patients with oropharyngeal carcinoma who were treated with curative intent at the Department of Otolaryngology and Head and Neck Surgery, Tokyo University, Tokyo, Japan, between January 2008 and December 2013. The institutional review board approved the study protocol, and written informed consent was obtained from all patients. Patients with untreated oropharyngeal cancer who met the following criteria were enrolled to induction chemotherapy: those with squamous cell carcinoma; those with stage III or IVA cancer without T1 disease, according to the 2012 tumor-node-metastasis (TNM) classification; those with a performance status between 0 and 1; those aged between 20 and 75 years; those with sufficient bone marrow function (white blood cell count $> 3,500/\text{mm}^3$ and platelet count $> 100,000/\text{mm}^3$); and those without any abnormalities of the liver, kidneys, heart, and lungs. Renal function was assessed as normal if the creatinine clearance was $\geq 60 \text{ mL/min}$. Formalin-fixed paraffin-embedded pretreatment biopsies were retrieved from the records of our pathology department, and p16 positivity was substituted for HPV positivity.¹⁴

Patients

We identified 119 patients with OPSCC during the study period but excluded 71 patients (60%) because they had p16-negative tumors. Of the remaining 48 patients, we excluded patients with stage I to II disease ($n = 4$), stage IVb disease ($n = 5$), and stage T1N1 to T1N2 disease ($n = 6$). Of the remaining 33 patients, seven were not suitable for induction chemotherapy because of age (> 75) or low performance status, and an additional three patients refused induction chemotherapy. Therefore, we included 23 patients (18 men, 5 women; age, 42–74 years; median

TABLE I.
Patients Demographics.

Characteristics	All Patients (n = 23)
Age, y	
Median	60
Range	42–74
Sex, n (%)	
Male	18 (78)
Female	5 (22)
Tobacco Smoking, n (%)	
Never	6 (26)
Current and ever	17 (74)
Alcohol Consumption, n (%)	
Never, chance	11 (48)
Habitual drinker	12 (52)
Tumor Classification, n (%)	
T2	12 (52)
T3	9 (39)
T4	2 (9)
Nodal Classification, n (%)	
N0	5 (22)
N1	3 (13)
N2	15 (65)
AJCC Stage, n (%)	
III	7 (30)
IV	16 (70)
Induction Chemotherapy	
TPF	20 (87)
TP	2 (9)
PF	1 (4)

AJCC = American Joint Committee on Cancer; TPF = Docetaxel, Cisplatin, and 5-fluorouracil; TP = Docetaxel and Cisplatin; PF = Cisplatin and 5-fluorouracil.

age, 60 years) who were treated with induction chemotherapy. The clinical charts were reviewed (Table I).

Treatment

Induction Chemotherapy. Induction chemotherapy included two cycles of TPF, consisting of 60 mg/m^2 cisplatin and 60 mg/m^2 docetaxel on day 1, with continuous infusion of 600 mg/m^2 5-fluorouracil for 5 days. Infusion of fluid replacement was established at 3 L/day during the administration of cisplatin, and a minimum urine volume of 2 L/day was maintained for 5 days after administration. Steroids, palonosetron, and aprepitant were used as antiemetics against cisplatin, as needed. Tumor extent and nodal disease were assessed 3 weeks after induction chemotherapy using panendoscopy and a computed tomography scan of the neck, if indicated. In patients with comorbidity or who were unable to tolerate TPF, we administered PF (70 mg/m^2 cisplatin and 700 mg/m^2 5-fluorouracil) or TP (60 mg/m^2 docetaxel and 60 mg/m^2 cisplatin) regimens. Patients were classified into those with complete response, partial response, stable disease, or progressive disease, according to the Response Evaluation Criteria in Solid Tumors (version 1.1) (http://ctep.cancer.gov/protocolDevelopment/docs/recist_guideline.pdf). Patients with complete or partial response were treated with (chemo)radiotherapy or transoral resection, whereas those with stable or progressive disease received open surgery.

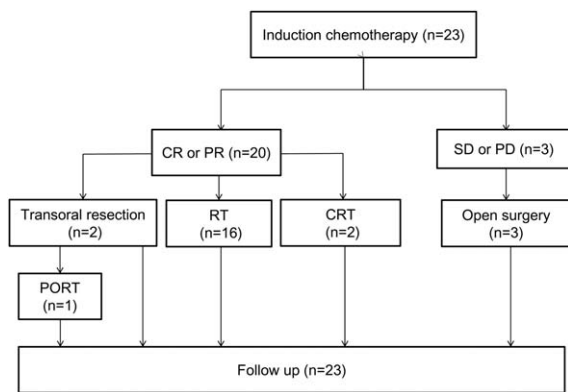


Fig. 1. Efficacy of induction chemotherapy and subsequent therapy. CR = complete response; CRT = chemoradiation therapy; PD = progressive disease; PORT = postoperative radiation therapy; PR = partial response; RT = radiation therapy; SD = stable disease.

Radiotherapy and Concurrent Chemotherapy. In radiotherapy cases ($n = 16$), with two-step radiation therapy using 6 and 10 MV photon beams, patients were prescribed a 70 Gy in 35 fractions with curative intent. The primary tumor and involved lymph nodes were contoured as gross tumor volume (GTV). Clinical target volume 1 (CTV1) included GTV with 3 mm to 5 mm margins in all directions. For prophylactic nodal irradiation, CTV2 included bilateral retropharyngeal lymph node and levels II to IV area (level IB was optional). Next, planning target volume (PTV) was defined as each CTV plus a 5-mm margin to account for setup error. Routinely, an additional dose was delivered to CTV1 up to a total dose, after the prophylactic dose (up to 40 Gy in conventional RT and 46 Gy in intensity-modulated radiation therapy) was delivered to CTV2.

In chemoradiotherapy cases ($n = 2$), we used concurrent TPF chemotherapy as follows: total dose of 60 mg/m² cisplatin, 50 mg/m² docetaxel on day 1 and 600 mg/m² 5-fluorouracil by continuous infusion for 5 days for 1 cycle.

Surgery. In patients with stable or progressive disease ($n = 3$) after two courses of induction chemotherapy, we performed open surgery with ipsilateral neck dissection and free flap reconstruction. No patient was administered subsequent postoperative radiation therapy. In patients with complete response after one course of induction chemotherapy ($n = 2$), we performed tonsillectomy in cases confined to a palatine tonsil after two courses of induction chemotherapy. After pathological evaluation, postoperative radiation therapy was administered in a case with positive surgical margins ($n = 1$).

Statistical Analysis

Analyses were performed using Microsoft Excel 2010 (Microsoft, Redmond, WA) and Stat Flex version 6.0 (Artech Co. Ltd, Osaka, Japan). All P values < 0.05 were considered statistically significant. The study endpoints were OS, disease-specific survival (DSS; defined as tumor-related death), and univariate PFS evaluated using the Kaplan–Meier method and log-rank test.

RESULTS

Efficacy and Outcomes

Induction chemotherapy resulted in partial or complete remission in 20 patients, stable disease in two patients, and progressive disease in one patient. Of the 20 patients with partial or complete remission, 16 received

radiotherapy only, two received chemoradiotherapy, and two underwent tonsillectomy. Of the two patients who underwent tonsillectomy, one patient showed pathological complete response and one patient had residual disease with a positive margin that necessitated postoperative radiotherapy delivered at a total dose of 60 Gy in 30 fractions. The three remaining patients with stable or progressive disease underwent open surgery with free flap reconstruction (Fig. 1).

Of the 23 patients, one patient with stable disease died of cervical lymph node metastasis from the original disease, one patient died of a myocardial infarction, and another died of kidney cancer. However, 20 patients had event-free, distant-metastasis-free survival over a mean follow-up period of 3.6 years (range, 0.6–5.8 years). The 3-year OS and DSS rates were 87.5% (95% confidence interval [CI], 74–100) and 95.5% (95% CI, 87–100), respectively (Fig. 2).

Adverse Events

Adverse events were evaluated by Common Terminology Criteria for Adverse Events, version 4.0 (National Cancer Institute, National Institutes of Health, Bethesda, MD). At least one treatment-related adverse event occurred in 20 of the 23 patients (87%) who received induction chemotherapy. Grade 3 or 4 neutropenia occurred in 18 patients (78%), and febrile neutropenia occurred in nine patients (39%). Grade 3 or 4 anemia developed in two patients, but there were no patients of grade 3 or 4 thrombocytopenia. All three patients undergoing open surgery also received a tracheostomy, and two patients undergoing chemoradiotherapy received a prophylactic percutaneous endoscopic gastrostomy. After treatment (> 6 months), the gastrostomies and tracheostomies were closed (Table II).

DISCUSSION

In this study, we demonstrated that induction chemotherapy for p16-positive OPSCC was considerably effective and associated with a favorable prognosis and good functional outcome. Of note, there were no subsequent metastases, no gastrostomy-dependent patients, and no treatment-related deaths, which we believe was facilitated by the 80%

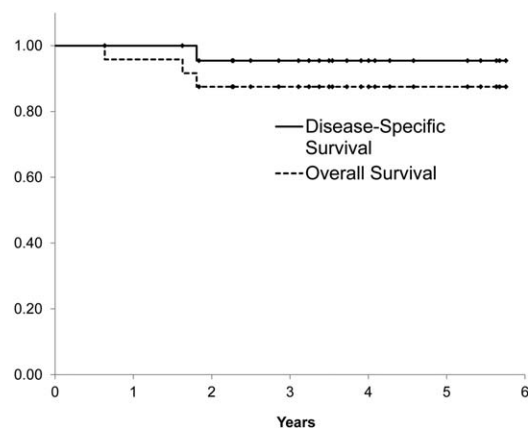


Fig. 2. Overall and disease-specific survival.

TABLE II.
Adverse Effects.

Variable	No. of Patients
Adverse Events During Treatment	
Hematologic	
Anemia grade 3 or 4	2
Thrombocytopenia grade 3 or 4	0
Neutropenia grade 3 or 4	18
Febrile neutropenia*	9
Nonhematologic grade 3 or 4	
Stomatitis (mucositis)	4
Nausea	1
Vomiting	0
Dysphagia	2
Diarrhea	2
Infection	3
Neurotoxicity	0
Anaphylaxis	1
Tracheostomy	3
PEG dependency	2
Adverse Events After (> 6-month) Treatment	
Nonhematologic grade 3 or 4	
Stomatitis (mucositis)	0
Dysphasia	0
Anorexia	0
Tracheostomy	0
PEG dependency	0

*Febrile neutropenia was defined as fever of grade 2 or more concomitant with grade 4 neutropenia requiring intravenous antibiotics, hospitalization, or both.

PEG = percutaneous endoscopic gastrostomy.

dose reduction in induction chemotherapy. In addition, because 17 patients (74%) were current or ever-smokers, most were categorized as intermediate by Ang et al.'s risk stratification,¹³ making the 3-year OS (87.5%) and DSS (95.5%) considerably outstanding. Overall, although this was only a retrospective, small-scale case series without the strength of a clinical trial, we showed that induction chemotherapy could be a good option for locally advanced p16-positive OPSCC. A multicenter prospective trial is justified to confirm our findings.

Several studies have identified several prognostic factors besides smoking status in HPV-positive OPSCC. For example, O'Sullivan et al.¹⁵ categorized T4 and N3 HPV-positive OPSCC into a distant metastasis high-risk group treated by radiotherapy or chemoradiotherapy. In addition, Vainshtein et al.¹⁶ demonstrated using multivariate analysis that T4 and N3 were the only significant predictors of locoregional failure. Furthermore, the significance of extracapsular spread in HPV-positive OPSCC is uncertain. In a retrospective study of 152 patients with p16-positive OPSCC who were treated with transoral laser microsurgery, Sinha et al.¹⁷ reported that extracapsular spread in lymph nodes had no prognostic significance on disease-free survival; equally, chemoradiotherapy had no prognostic benefit

over radiotherapy alone for extracapsular spread. Therefore, treatment deintensification should only be recommended for HPV-positive OPSCC in patients with favorable prognostic factors (i.e., non-T4, non-N3, and minimal smoking history). In our study, patients with N3 disease were excluded from induction chemotherapy because of their requirement for intensive local multimodality therapy (i.e., neck dissection plus postoperative chemoradiotherapy). In addition, we only included two patients with T4 disease, and cancers for both patients were located at the tongue base (considered T4a with invasion to the styloglossus muscles). Fortunately, these patients had a good response to induction chemotherapy, presumably because their disease was relatively confined. We recommend care when treating T4a HPV-positive OPSCC.

Several clinical trials of deintensified treatment for HPV-positive OPSCC are in progress. In a subgroup analysis by Bonner et al.,¹⁸ the outcome of p16-positive patients who received cetuximab concurrently with radiation was significantly better than those who received radiation alone. Replacing chemotherapy with cetuximab is also currently being investigated in large randomized trials (RTOG 1016). In other research, the relationship between HPV and epidermal growth factor receptor (EGFR) expression has been described to have an inverse correlation in OPSCC,¹⁹ with both p16 and EGFR expression being prognostic factors for outcomes. At present, the role of cetuximab in place of conventional chemotherapy is somewhat controversial.

Transoral robotic surgery can be used for the initial management of OPSCC, particularly in HPV-positive OPSCC, because most of these cancers have low-T high-N classifications and are present in younger patients. Leonhardt et al.²⁰ reported that transoral robotic surgery alone or that followed by radiation therapy resulted in excellent quality-of-life measures; however, they showed that patients who required adjuvant chemoradiotherapy had worse dysphagia at 6 months and 1 year. Using lower doses of radiation (50 Gy instead of 60 Gy), the ongoing ECOG 3311 trial therefore offers a promising approach for postoperative deintensification. Most patients with T2 HPV-positive OPSCC would be good candidates for transoral robotic surgery²¹ because negative margin of primary tumor would omit the adjuvant radiation.

As of 2015, the da Vinci (Intuitive Surgical Inc., Sunnyvale, CA) surgical robot has not been approved in Japan, and the transoral approach is restricted, particularly to the base of the tongue. Therefore, our strategy of induction chemotherapy provides a useful nonrobotic approach to the deintensification of treatment for patients with HPV-positive OPSCC. In addition, HPV-positive OPSCCs have low risk for second primary malignancies⁵; thus, it is possible that patients older than 60 years may also be good candidates for this nonsurgical approach.

CONCLUSION

We conclude that induction chemotherapy is considerably effective for non-N3 locally advanced p16-positive OPSCC. However, it is important to note that our study

is limited by the small sample size and the fact that it was conducted at a single center. Further multicenter prospective study is therefore required to confirm our findings.

BIBLIOGRAPHY

1. Calais G, Alfonsi M, Bardet E, et al. Randomized trial of radiation therapy versus concomitant chemotherapy and radiation therapy for advanced-stage oropharynx carcinoma. *J Natl Cancer Inst* 1999;91:2081–2086.
2. Parsons JT, Mendenhall WM, Stringer SP, et al. Squamous cell carcinoma of the oropharynx: surgery, radiation therapy, or both. *Cancer* 2002;94:2967–2980.
3. Forastiere AA, Zhang Q, Weber RS, et al. Long-term results of RTOG 91-11: a comparison of three nonsurgical treatment strategies to preserve the larynx in patients with locally advanced larynx cancer. *J Clin Oncol* 2013;31: 845–852.
4. Saito Y, Yoshida M, Ushiku T, et al. Prognostic value of p16 expression and alcohol consumption in Japanese patients with oropharyngeal squamous cell carcinoma. *Cancer* 2013;199:2005–2011.
5. Saito Y, Ebihara Y, Ushiku T, et al. Negative human papillomavirus status and excessive alcohol consumption are significant risk factors for second primary malignancies in Japanese patients with oropharyngeal carcinoma. *Jpn J Clin Oncol* 2014;44:564–569.
6. D'Souza G, Kreimer AR, Viscidi R, et al. Case-control study of human papillomavirus and oropharyngeal cancer. *N Engl J Med* 2007;356:1944–1956.
7. Patel SH, Hinni ML, Hayden RE, et al. Transoral laser microsurgery followed by radiation therapy for oropharyngeal tumors: the Mayo Clinic Arizona experience. *Head Neck* 2014;36:220–225.
8. Quon H, Cohen MA, Montone KT, et al. Transoral robotic surgery and adjuvant therapy for oropharyngeal carcinomas and the influence of p16 INK4a on treatment outcomes. *Laryngoscope* 2013;123:635–640.
9. Tomifuji M, Araki K, Yamashita T, Shiotani A. Transoral videolaryngoscopic surgery for oropharyngeal, hypopharyngeal, and supraglottic cancer. *Eur Arch Otorhinolaryngol* 2014;271:589–597.
10. Induction chemotherapy plus radiation compared with surgery plus radiation in patients with advanced laryngeal cancer. The Department of Veterans Affairs Laryngeal Cancer Study Group. *N Engl J Med* 1991;324: 1685–1690.
11. Lorch JH, Goloubeva O, Haddad RI, et al. Induction chemotherapy with cisplatin and fluorouracil alone or in combination with docetaxel in locally advanced squamous-cell cancer of the head and neck: long-term results of the TAX 324 randomised phase 3 trial. *Lancet Oncol* 2011;12: 153–159.
12. Vermorken JB, Remenar E, van Herpen C, et al. Cisplatin, fluorouracil, and docetaxel in unresectable head and neck cancer. *N Engl J Med* 2007;357:1695–1704.
13. Ang KK, Harris J, Wheeler R, et al. Human papillomavirus and survival of patients with oropharyngeal cancer. *N Engl J Med* 2010;363:24–35.
14. Saito Y, Yoshida M, Omura G, et al. Prognostic value of p16 expression irrespective of human papillomavirus status in patients with oropharyngeal carcinoma. *Jpn J Clin Oncol* 2015;45:828–836.
15. O'Sullivan B, Huang SH, Siu LL, et al. Deintensification candidate subgroups in human papillomavirus-related oropharyngeal cancer according to minimal risk of distant metastasis. *J Clin Oncol* 2013;31:543–550.
16. Vainshtein JM, Spector ME, McHugh JB, et al. Refining risk stratification for locoregional failure after chemoradiotherapy in human papillomavirus-associated oropharyngeal cancer. *Oral Oncol* 2014;50:513–519.
17. Sinha P, Lewis JS Jr, Piccirillo JF, Kallogjeri D, Haughey BH. Extracapsular spread and adjuvant therapy in human papillomavirus-related, p16-positive oropharyngeal carcinoma. *Cancer* 2012;118:3519–3530.
18. Bonner JA, Harari PM, Giralt J, et al. Radiotherapy plus cetuximab for squamous-cell carcinoma of the head and neck. *N Engl J Med* 2006;354: 567–578.
19. Reimers N, Kasper HU, Weissenborn SJ, et al. Combined analysis of HPV-DNA, p16 and EGFR expression to predict prognosis in oropharyngeal cancer. *Int J Cancer* 2007;120:1731–1738.
20. Leonhardt FD, Quon H, Abrahao M, O'Malley BW Jr, Weinstein GS. Transoral robotic surgery for oropharyngeal carcinoma and its impact on patient-reported quality of life and function. *Head Neck* 2012;34:146–154.
21. de Almeida JR, Li R, Magnuson JS, et al. Oncologic outcomes after transoral robotic surgery: a multi-institutional study. *JAMA Otolaryngol Head Neck Surg* 2015;141:1043–1051.