Check for updates

E-only Article

Journal of Evidence-Based Complementary & Alternative Medicine
2016, Vol. 21(4) NP77-NP84
© The Author(s) 2016
Reprints and permission:
sagepub.com/journalsPermissions.nav
DOI: 10.1177/2156587216637469
cam.sagepub.com
SAGE

Gastroprotective Effect of Combination of Hot Water Extracts of Licorice (*Glycyrrhiza glabra*), Pulasari Stem Bark (*Alyxia reinwardtii*), and Sembung Leaf (*Blumea balsamifera*) Against Aspirin-Induced Gastric Ulcer Model Rats

Agung Endro Nugroho, MSc, PhD[1], Agustin Wijayanti, MSc[1], Mutmainah Mutmainah, MSc[1], Rina Susilowati, MD, PhD[2], and Nuning Rahmawati, MSc[3]

Abstract

Licorice (*Glycyrrhiza glabra*), Pulasari stem bark (*Alyxia reinwardtii*) and Sembung leaf (*Blumea balsamifera*) are traditionally used to treat gastrointestinal disorders. The aim of the study was to investigate gastroprotective effect of hot water extracts combination of those herbal against aspirin-induced gastric ulcer model in rats. The combination consisted of fixed doses of Licorice 273 mg/kg BW and Sembung leaf 457.5 mg/kg BW, and also consisted of Pulasari stem in various doses i.e. 100 mg/kg BW (first group), 200 mg/kg BW (second and sixth group) and 300 mg/kg BW (third group). The fourth grup rats received sucralfate 360 mg/kg BW. Ten minute after seven consecutive days of drug administration, the rats were induced with aspirin 450 mg/kg BW except sixth group rats. The fifth group rats only received aspirin without any protective agents. The number and area of gastric ulcers were evaluated macroscopically. Whereas, histopatological observation was used for evaluation of mucosal damage score, and the number of eosinophils and mast cells. In the study, herbal extracts combination markedly exhibited protective effects indicated by less number and smaller area of gastric ulcers in comparison to those of aspirin group ($P < 0.05$). The score of mucosal damages were also decreased in herbal extracts combination groups. The number of eosinophils and mast cells of herbal combination groups were observed to be smaller than those of aspirin group ($P < 0.05$). In conclusion, herbal combination of Licorice (Glycyrrhiza glabra), Pulasari stem bark (Alyxia reinwardtii) and Sembung leaf (Blumea balsamifera) is potential to develop as a gastroprotective agent.

Keywords

gastric ulcer, protective effect, *Glycyrrhiza glabra*, *Alyxia reinwardtii*, *Blumea balsamifera*

Received August 6, 2015. Received revised January 19, 2016. Accepted for publication February 5, 2016.

Peptic ulcer is a gastrointestinal disorder that affects many people worldwide. This disease is caused by an imbalance of aggressive factors (gastric acid and pepsin) and defensive factors (mucous secretion, bicarbonate secretion, mucosal blood flow, and regeneration of the mucosal epithelium). This imbalance is influenced by several causes, that is, drugs (nonsteroidal anti-inflammatory drugs, aspirin), infection (*Helicobacter pylori*), food, psychological stress, cigarette smoking, and alcohol consumption. These ulcerogenic factors can cause the aggressive factors to become more dominant and can regulate the inflammatory processes involving the roles of neutrophils, eosinophils, and mast cells.[1-3] One of antiulcer agents recommended to heal nonsteroidal anti-inflammatory drug–induced peptic ulcers is sucralfate. Its mechanism is to increase the

[1] Department of Pharmacology and Clinical Pharmacy, Faculty of Pharmacy, Universitas Gadjah Mada, Jogjakarta, Indonesia
[2] Department of Histology and Cell Biology, Faculty of Medicine, Universitas Gadjah Mada, Yogyakarta, Indonesia
[3] Medicinal Plant and Traditional Medicine Research and Development Center, Tawangmangu, Karanganyar, Central Java, Indonesia

Corresponding Author:
Agung Endro Nugroho, MSc, PhD, Department of Pharmacology & Clinical Pharmacy, Faculty of Pharmacy, Universitas Gadjah Mada, Sekip Utara Jogjakarta, Indonesia 55281.
Email: agungendronugroho@gmail.com

mucosal defense for the acid and pepsin. Some cases of the use of sucralfate cause side effects such as constipation and hypophosphatemia.[4]

In Indonesia, the use of traditional medicine in the community has been increasing every year. Some of them are already used in the formal health system including for the treatment of peptic ulcer. Some traditional medicine widely used for treating gastric ulcer are licorice (*Glycyrrhiza glabra*), Pulasari stem bark (*Alyxia reinwardtii*), and Sembung leaf (*Blumea balsamifera*). These plants grow widely in some areas of Southeast Asia countries including Indonesia. Reportedly, licorice exhibited antiulcerogenic effect by increasing mucin secretion and prostaglandin E2 release and decreasing leukotrienes.[5] This plant also exhibited antioxidative and anti-inflammatory activities, which also play roles in its antiulcerogenic effect. These activities are closely related to its flavonoid contents.[6,7] Due to its potent gastroprotective activity, the plant is used as the basis of antiulcer agents for treating peptic ulcer.[8] This medicinal plant is often combined with other plants for this purpose.[9]

Pulasari stem bark has been reported to contain high content of coumarin compounds such as 3-hydroxycoumarin derivatives. These compounds exhibit antioxidative activities by scavenging several free radicals and inhibiting human low-density lipoprotein peroxidation.[10,11] Sembung leaf is empirically reported in *Medicine Plant of Myanmar* for the treatment of gastric ulcer. Based on these facts, this study aimed to investigate the protective effect of hot water extracts combination of licorice (*Glycyrrhiza glabra*), Pulasari stem bark (*Alyxia reinwardtii*), and Sembung leaf (*Blumea balsamifera*) against aspirin-induced gastric ulcer model rats.

Materials and Methods

Materials

Licorice (*Glycyrrhiza glabra*), Pulasari (*Alyxia reinwardtii*), and Sembung (*Blumea balsamifera*) were collected from July to August 2012 from areas around Tawangmangu, Karanganyar, Central Java, Indonesia. The plants were identified by a botanist at the Medicinal Plant and Traditional Medicine Research and Development Center, Karanganyar, Central Java, Indonesia. The voucher specimens were stored in the herbarium of the department. Sucralfate was purchased from PT Kalbe Farma Tbk Indonesia, whereas aspirin (inducer for gastric ulcers), hematoxylin, eosin, lithium carbonate, Canadian balsam, and toluidine blue were obtained from Sigma Chemical (St Louis, MO).

Animals

Male Wistar rats (150-200 g) aged 2 to 3 months were used in the study. The rats were obtained from the Laboratory of Pharmacology and Toxicology, Department of Pharmacology and Clinical Pharmacy, Faculty of Pharmacy, Universitas Gadjah Mada, Indonesia. They were housed at constant temperature (22 $\pm$ 2°C) and constant relative humidity (55 $\pm$ 10%), automatically controlled in a 12:12 hour light-dark cycle (light on at 7:00 AM). The rats were fed with a standard laboratory food and water ad libitum. Ethical clearance for the animal study was obtained from the Research Ethics Committee, Agency for Health Research and Development, Ministry of Health, Indonesia (Ethical Clearance Certificate Number: ke.01.08/ec/584/2012).

Experimental Design

Thirty male Wistar rats were acclimatized and quarantined to the experimental laboratory for 8 days for acclimatization. They were randomly assigned into 6 groups as given below:

- Group 1: The rats received a combination of *G glabra* (273 mg/kg body weight [BW]), *A reinwardtii* (100 mg/kg BW), and *B balsamifera* (457.5 mg/kg BW) orally, once daily.
- Group 2: The rats received a combination of *G glabra* (273 mg/kg BW), *A reinwardtii* (200 mg/kg BW), and *B balsamifera* (457.5 mg/kg BW) orally, once daily.
- Group 3: The rats received a combination of *G glabra* (273 mg/kg BW), *A reinwardtii* (300 mg/kg BW), and *B balsamifera* (457.5 mg/kg BW) orally, once daily.
- Group 4: The rats received sucralfate 360 mg/kg BW orally, once daily.
- Group 5: The rats received oral saline 10 mL/kg BW (control group).
- Group 6: The rats received a combination of *G glabra* (273 mg/kg BW), *A reinwardtii* (200 mg/kg BW), and *B balsamifera* (457.5 mg/kg BW) orally, once daily.

All drug treatments were administered orally for 7 days. Ten minutes after the administration of these drugs, the rats were induced with aspirin 450 mg/kg BW, except for the rats in the sixth group. At the end of the experiments (day 8), after 10 hours of fasting, the rats were sacrificed for macroscopic and microscopic evaluations of the gastric mucosal lesions. The stomach was excised and opened along the greater curvature. The mucosa was then observed for possible damage. The number and area (mm^2) of the gastric ulcers were counted and measured macroscopically.

Histological Observation

The stomach tissues were fixed in 10% buffered formaldehyde. The fixed tissues were processed in a paraffin tissue–processing machine to provide pieces of desired size (4 μm). Subsequently, a section of the stomach tissue was deparaffinized in xylene and dehydrated with a series of alcohol concentrations. The paraffin sections were stained with hematoxylin and eosin or toluidine blue for histological evaluation under a light microscope (Olympus BX51, Tokyo, Japan) with a magnification of 100×. Hematoxylin and eosin staining was used for the evaluation of microscopic mucosal damage and the number of eosinophils, whereas toluidine blue staining was used for counting the number of mast cells. The mucosal damage was observed and scored based on a previous study.[12]

Statistical Analysis

All experimental data are shown as mean $\pm$ standard error of the mean. Statistical analysis of the data used one-way analysis of variance followed by the least significant difference test. P values of less than .05 were considered as significant.

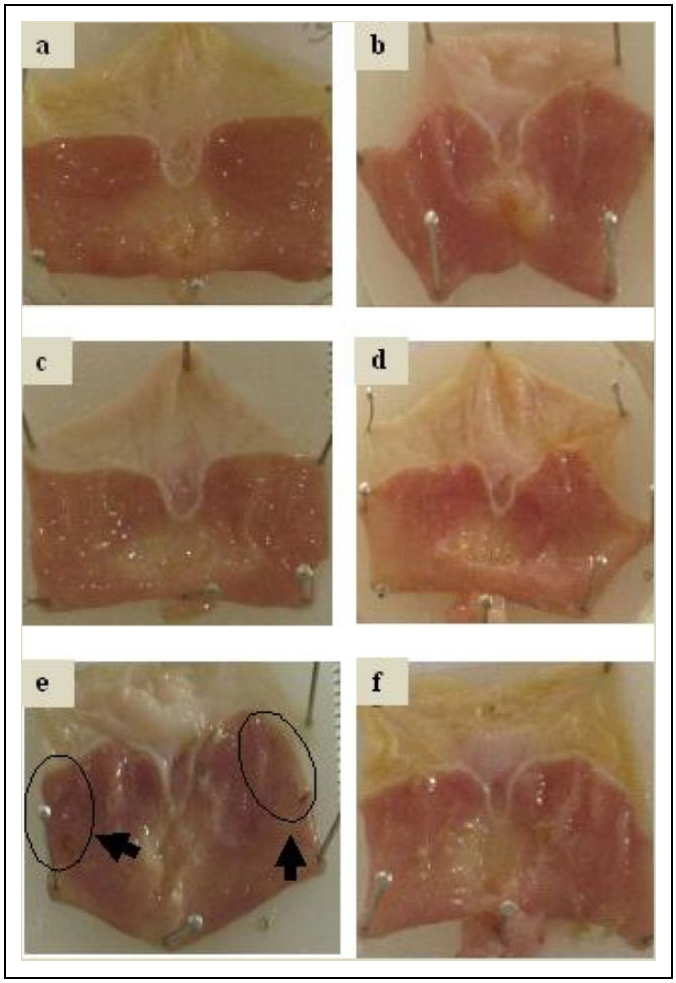

Figure 1. Macroscopic observation on gastric mucosa after aspirin induction. The drugs were administered for 7 days. Groups 1 to 3: Herbal combinations of low dose, medium dose, and high dose with aspirin induction (a-c); Group 4: Sucralfate 72 mg/200 g BW with aspirin induction (d); Group 5: Aspirin induction without any drug treatment (e); Group 6: Herbal combination without aspirin induction (f). Lesion areas were observed in group 5 (e). Black arrow indicates a lesion.

Results

Macroscopic Evaluation of Gastric Ulcers

In the study, macroscopic observation was used for determining the number and size of gastric lesions. Oral treatment of aspirin at a dose of 450 mg/kg BW markedly induced gastric ulcer on the mucosa (Figure 1). The group that received only aspirin without any protective agents was the negative control. Treatment of herbal extract combinations for 7 days succeeded in decreasing the aspirin-induced gastric lesions, as indicated by the smaller number and size of gastric lesions in comparison to the negative control (Figures 1 and 2). These gastroprotective effects were dose-dependent. Sucralfate, a cytoprotective agent for peptic ulcer, also decreased the mucosal damage due to aspirin induction. Comparison of the gastroprotective effects of all treatments regarding the number and size of gastric lesions is shown in Figure 2.

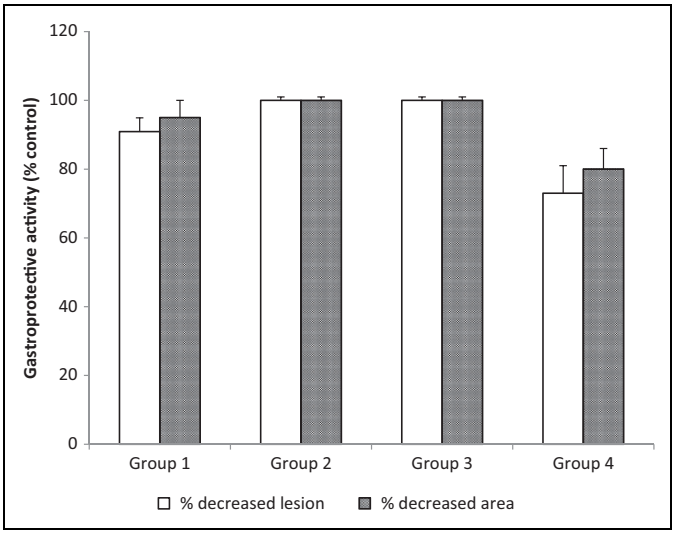

Figure 2. Gastroprotective activities of each group in aspirin-induced gastric ulcer model rats regarding the parameters of number and area of lesions.

Histological Observation of Mucosal Damage

In line with previous macroscopic observations, oral treatment of aspirin could initiate gastric ulcers indicated by erosion of gastric mucosa (Figure 3). However, treatment of herbal extract combinations avoided the mucosal erosions. Sucralfate also could reduce the evidence of gastric ulcer and mucosal erosions. The gastroprotective effect of the herbal extracts combination was higher than that of sucralfate (Figure 4).

Number of Mast Cells and Eosinophils in the Mucosa and Submucosa

Aspirin treatment could increase the number of mast cells in the submucosal layer (Table 1). Mast cells, multifunctional immune cells, are related to inflammatory processes. Mast cells can release some inflammatory mediators such as histamine, leukotrienes, serotonin, and proteases. Aspirin also stimulated the increase of eosinophil in submucosal and mucosal tissues. The higher number of eosinophil in these tissues was closely related to the evidence of inflammatory processes in gastric mucosa (Table 1). Treatment of herbal extracts combination or sucralfate could prevent the increase of the number of mast cells and eosinophil in comparison to that in the negative group (Figures 5 and 6).

Discussion

To date, attempts to develop traditional medicine is increasing every year, including extraction and isolation active compounds from herbs, herbal combinations, in vitro and in vivo bioassays for screening pharmacological effects and investigation of their mechanisms, toxicological study, and clinical trial. Indonesia has the second largest biodiversity in the world including medicinal plants. The medicinal plants are widely

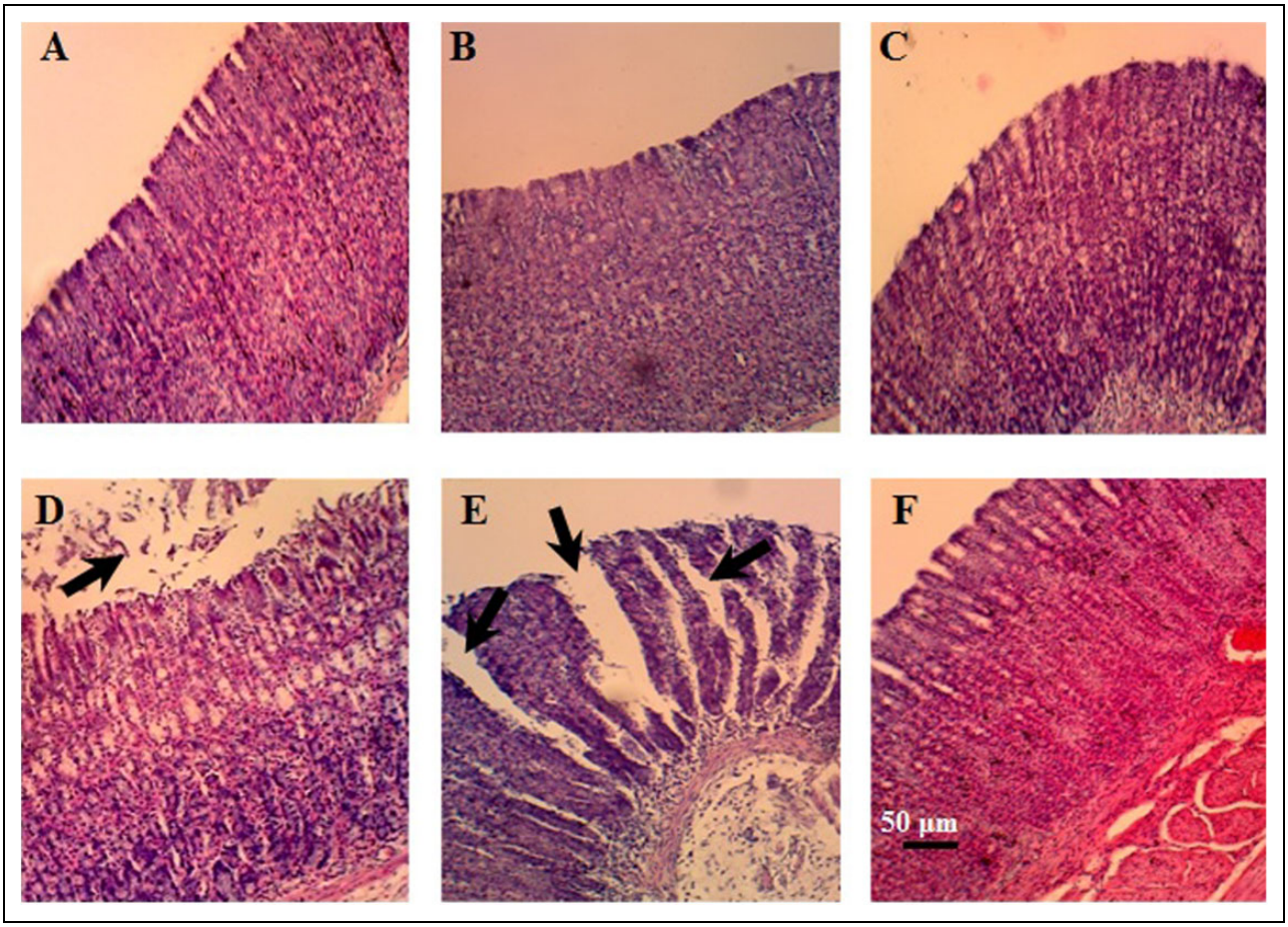

Figure 3. Hematoxylin and eosin (HE)–stained sections of gastric mucosal tissues for gastric ulcer and mucosal erosion observation. Groups 1 to 3: Herbal combinations of low dose, medium dose, and high dose with aspirin induction (a-c); Group 4: Sucralfate 72 mg/200 g BW with aspirin induction (d); Group 5: Aspirin induction without any drug treatment (e); Group 6: Herbal combination without aspirin induction (f). Magnification 100×. Mucosal damage is shown by the black arrows.

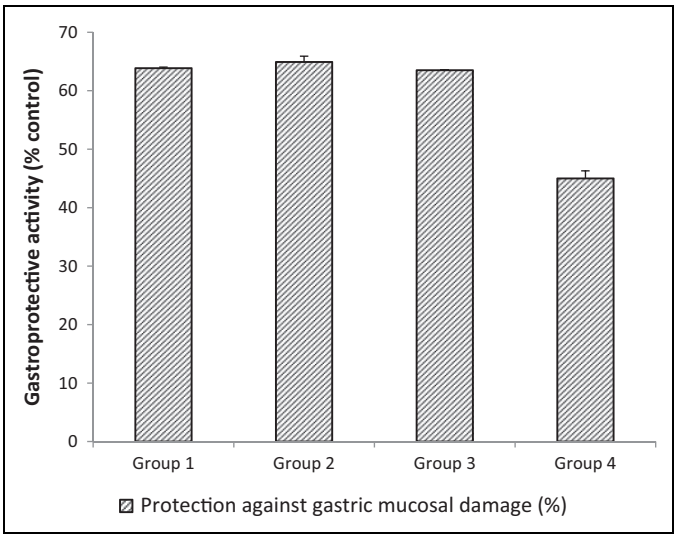

Figure 4. Gastroprotective activities of each group in aspirin-induced gastric ulcer model rats regarding the parameters of gastric mucosal damage.

Table 1. Number of Mast Cells and Eosinophils in the Gastric Mucosa and Submucosa of Each Treatment Group and the Control.

Group	Number of Submucosal Mast Cells ($/10^5$ µm^2)	Number of Eosinophils ($/10^5$ µm^2)	
		Submucosa	Mucosa
Group 1: Herbal combination dose 1 (+aspirin)	0.90 ± 0.05*	1.63 ± 0.91*	4.35 ± 1.47
Group 2: Herbal combination dose 2 (+aspirin)	0.88 ± 0.05*	1.52 ± 0.87*	4.15 ± 0.40*
Group 3: Herbal combination dose 3 (+aspirin)	0.60 ± 0.05*	1.44 ± 0.14*	4.19 ± 0.11*
Group 4: Sucralfate (+aspirin)	0.73 ± 0.28*	1.46 ± 0.88*	5.19 ± 0.44*
Group 5: Aspirin only (negative control)	2.21 ± 0.44	3.19 ± 1.23	7.35 ± 0.89
Group 6: Herbal combination only	0.58 ± 0.06*	1.38 ± 0.56*	3.58 ± 0.28*

*$P < .05$ compared with the control value.

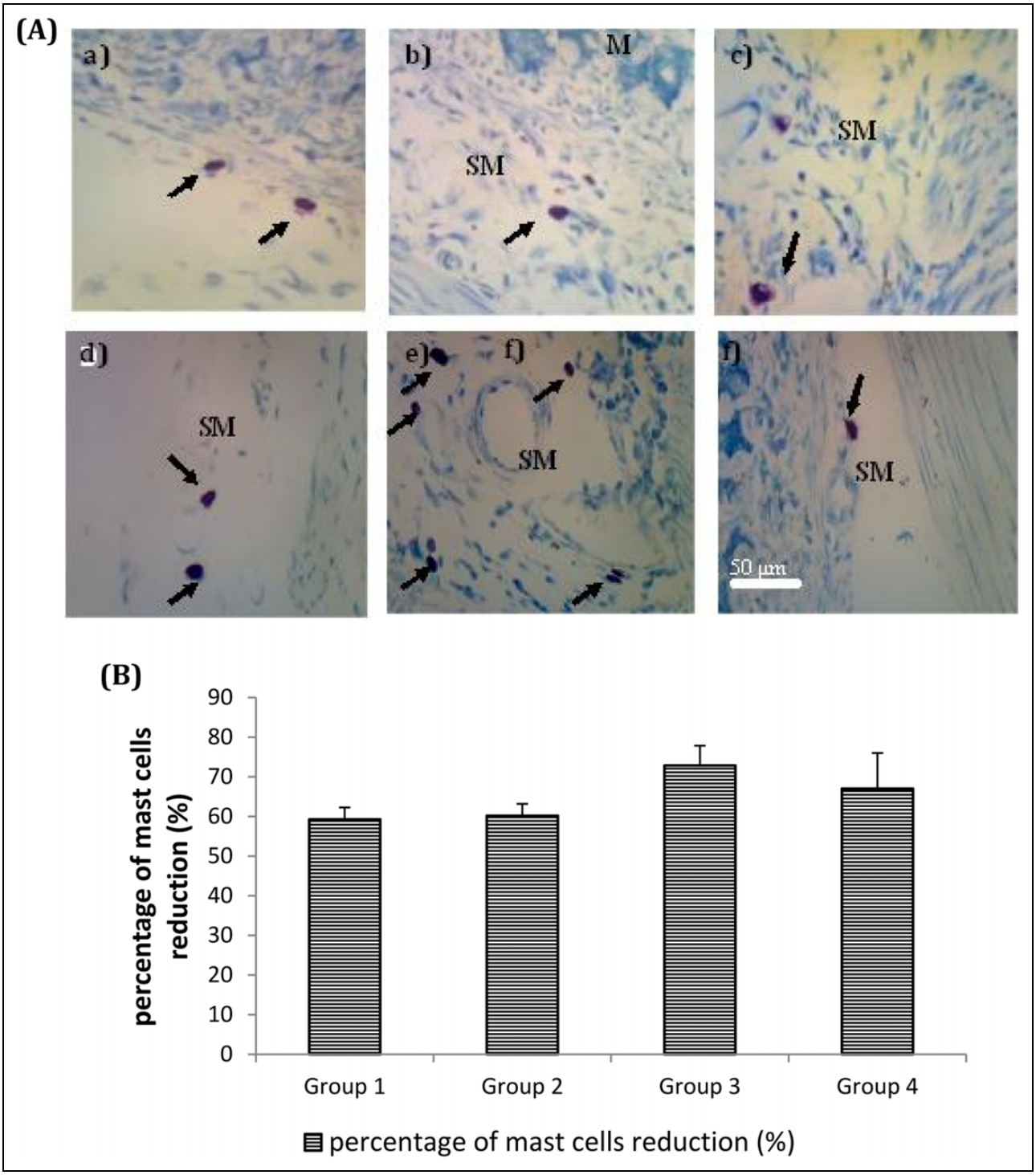

Figure 5. Toluidine blue–stained sections of gastric mucosal tissues for gastric ulcer and mucosal erosion observation (A). The drugs were administered for 7 days. Groups 1 to 3: Herbal combinations of low dose, medium dose, and high dose with aspirin induction (a-c); Group 4: Sucralfate 72 mg/200 g BW with aspirin induction (d); Group 5: Aspirin induction without any drug treatment (e); Group 6: Herbal combination without aspirin induction (f). Magnification 100×. Mast cell is showed by black arrow. Gastroprotective activities of each group in aspirin-induced gastric ulcer model rats regarding the parameters of mast cells reduction number (B). M = mucosa, SM = submucosa.

used by many people for the treatment of several diseases including gastric ulcer either in single form or in combination form. In Indonesia, herbs used for traditional medicine are known as *Jamu*. Some traditional medicinal plants that have been used empirically for the treatment of gastric ulcer are licorice (*Glycyrrhiza glabra*), Pulasari stem bark (*Alyxia reinwardtii*), and Sembung leaf (*Blumea balsamifera*). In this study, these plants were combined and evaluated for their

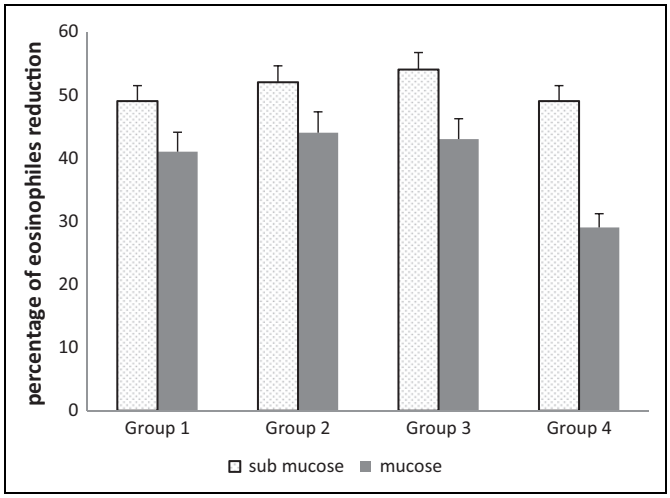

Figure 6. Percentage of eosinophil reduction of each group in aspirin-induced gastric ulcer model rats.

potency of gastrointestinal effect against aspirin-induced gastric ulcer model rats.

In this study, a gastric ulcer model was initiated in rats by using aspirin. The long-term use of aspirin even at low doses is related to some clinical features of gastroduodenal injury. Aspirin decreases the level of gastric mucosal prostaglandin and causes gastric mucosal damage in long-term therapy. Reportedly, the incidence of gastrointestinal injury and bleeding is increasing. The mechanisms of action of nonsteroidal anti-inflammatory drugs and aspirin are related to the inhibition of cyclooxygenase (COX)-1 and cyclooxygenase (COX)-2. Inhibition of COX-1 is related to the pathogenesis of mucosal damage including reduction of mucosal flow, decrease of mucus and bicarbonate secretion, and impaired platelet aggregation. Pathogenesis related to the inhibition of COX-2 is reduction of angiogenesis and increase of leukocytes adherence. Epithelial damage is directly related to acid back diffusion and impaired platelet aggregation. Aspirin inhibits more potently on COX-1 than on COX-2.[13,14]

The pathogenesis of gastric ulcer involves the role of inflammatory mediators. Mucosal cells produce pro-inflammatory chemotactic as inflammatory mediators that can attract more leukocytes such as eosinophil. Nonsteroidal anti-inflammatory drugs stimulate granulocytes infiltration into the mucosa by inducing some inflammatory processes such as expression of cytokines (tumor necrosis factor-α and interleukins) and adhesion molecules on leukocytes and endothelial cells.[1,15] Indeed, infiltration and activation of eosinophils occur at the margin of newly formed ulcers.[16]

Mast cells are multifunctional immune cells related to expression of high-affinity immunoglobulin E receptors and are responsible to release potent inflammatory mediators such as histamine, serotonin, leukotrienes, and proteases (tryptase).[17] Mast cells are an important substance contributing to the pathogenesis of many gastrointestinal diseases including peptic ulcer. Mast cells play an important role in the development and healing of gastric ulcers. The number of mucosal and connective tissue–type mast cells in the stomach increased in acetic acid–induced ulcer in rats.[18,19]

In this study, the herbal extracts combination was treated in rats in the absence and presence of aspirin. Administration of herbal extracts combination in the absence of an ulcer inducer aimed to evaluate the direct effect of the combination on gastric mucosa. Based on the results, there is no evidence of gastric mucosal damage or irritation due to the herbal extracts combination. The herbal extracts combination prevented mucosal injury in the presence of aspirin. Reportedly, *Glycyrrhiza glabra* exhibited a potential gastroprotective effect in preclinical and clinical studies. The mechanisms related to its antiulcerogenic effect were increase of mucin secretion, increase of prostaglandin E2 release, and decrease of leukotrienes.[5,20] Its gastroprotective effect is closely related to its antioxidative and anti-inflammatory activities. The flavonoids content in *Glycyrrhiza glabra* is thought to play a role in these activities.[6,7] *Glycyrrhiza glabra* is often used as the basis of antiulcer agents, especially in combination form for treating peptic ulcer.[8,9] *Alyxia reinwardtii* stem bark and *Blumea balsamifera* leaf consist of flavonoids. Empirically, the herbs have been used for gastric ulcer therapy. The flavonoids exhibited gastroprotective effect in their antioxidative activity, especially through scavenging of hydroxyl radicals.[21] Besides, flavonoids also contribute to increase the amount of gastric mucus glycoprotein and inhibition of prostaglandin production.[22] The action of aspirin and nonsteroidal anti-inflammatory drugs is related to enhancement of reactive oxygen species in the gastric mucosa.[23] Increased free radical production contributes in inflammatory progression during gastric ulcer injury.[24]

Alyxia reinwardtii stem bark also contains high amounts of coumarins such as 3-hydroxycoumarin derivatives. These compounds exhibit antioxidative activities by scavenging several free radicals and inhibiting human low-density lipoprotein peroxidation.[10,11] Based on these data, the herbal extract combination succeeded to protect mucosal damage, avoid the increase in the number of mast cells, and eosinophil mobilization.

In this study, the gastroprotective effect of the herbal combination was compared to sucralfate, a cytoprotective agent indicated for peptic ulcers therapy.[4] Based on the results, the effect of the herbal combination tends to be better than that of sucralfate. The binding of sucralfate to aspirin is not considered to be a factor regarding its protective effect against aspirin-induced gastric ulcer. Its mechanism is related to stimulation of an increase of mucosal prostaglandin E2 synthesis, secretion of bicarbonate, and mucus secretion.[25]

In conclusion, combination of hot water extracts of licorice (*Glycyrrhiza glabra*), Pulasari stem bark (*Alyxia reinwardtii*), and Sembung leaf (*Blumea balsamifera*) exhibited potential activities to protect mucosal damage, avoid the increase of the number of mast cells, and eosinophil mobilization in aspirin-induced gastric ulcer model rats. The present findings provide information on the pharmacological effects of plants originating from Southeast Asia, especially Indonesia. The main sources of new drugs are mainly from medicinal plants and

synthesis processes.[26-29] The Southeast Asia countries have the biggest biodiversity in the world including medicinal plants and intensive studies are being carried out on some medicinal plants.[30-35]

Acknowledgments

We gratefully thank the Medicinal Plant and Traditional Medicine Research and Development Center Indonesia for the collaboration and Faculty of Pharmacy for the financial support. We also thank Mr. Y. Suhardi for excellent technical assistance.

Author Contributions

AEN, NR, AW, and MM contributed in plant collection, experimental work and statistical analysis. RS, AW and MM were involved in the histological observation. AEN, MM, and AW drafted the article. All authors read and approved the final version of the article.

Declaration of Conflicting Interests

The authors declared no potential conflicts of interest with respect to the research, authorship, and publication of the article.

Funding

The authors disclosed receipt of the following financial support for the research, authorship, and/or publication of this article: Financial support was received from the Faculty of Pharmacy, Universitas Gadjah Mada, and Medicinal Plant and Traditional Medicine Research and Development Center Indonesia.

Ethical Approval

Ethical clearance for the animal study was approved by the Research Ethics Committee, Agency for Health Research and Development, Ministry of Health, Indonesia (Ethical Clearance Certificate Number ke.01.08/ec/584/2012).

References

1. Watanabe T, Higuchi K, Tanigawa T, Tominaga K, Fujiwara Y, Arakawa T. Mechanism of peptic ulcer recurrence: role of inflammation. *Inflammopharmacology*. 2002;10:291-302.
2. Lockrey G, Lim L. Peptic ulcer disease in older people. *J Pharm Pract Res*. 2011;41:58-61.
3. Wallace JL. Mechanisms, prevention and clinical implications of nonsteroidal anti-inflammatory drug-enteropathy. *World J Gastroenterol*. 2013;19:1861-1876.
4. Berardi RR, Welage L. Peptic ulcer disease. In: DiPiro JT, Talbert RL, Yee GC, Matzke GR, Wells BG, Posey LM, eds. *Pharmacotherapy: A Pathological Approach*. 6th ed. New York, NY: McGraw-Hill; 2008.
5. Khayyal MT, el-Ghazaly MA, Kenawy SA, et al. Antiulcerogenic effect of some gastrointestinally acting plant extracts and their combination. *Arzneimittelforschung*. 2001;51:545-553.
6. Herold A, Cremer L, Calugaru A, Tamaş V, Ionescu F, Manea S, Szegli G. Hydroalcoholic plant extracts with anti-inflammatory activity. *Roum Arch Microbiol Immunol*. 2003;62:117-129.
7. Mukherjee M, Bhaskaran N, Srinath R, et al. Anti-ulcer and antioxidant activity of GutGard. *Indian J Exp Biol*. 2010;48:269-274.
8. Fukai T, Marumo A, Kaitou K, Kanda T, Terada S, Nomura T. Anti-*Helicobacter pylori* flavonoids from licorice extract. *Life Sci*. 2002;71:1449-1463.
9. Bafna PA, Balaraman R. Anti-ulcer and anti-oxidant activity of pepticare, a herbomineral formulation. *Phytomedicine*. 2005;12:264-270.
10. Lin LJ, Lin LZ, Ruangrungsi N, Cordell GA. 3-Hydroxycoumarin glycosides from *Alyxia reinwardti* var. Lucida. *Phytochemistry*. 1993;34:825-830.
11. Bailly F, Maurin C, Teissier E, Vezin H, Cotelle P. Antioxidant properties of 3-hydroxycoumarin derivatives. *Bioorg Med Chem*. 2004;12:5611-5618.
12. Mutmainah, Susilowati R, Rahmawati N, Nugroho AE. Gastroprotective effects of combination of hot water extracts of turmeric (*Curcuma domestica* L.), cardamom pods (*Ammomum compactum* S.) and sembung leaf (*Blumea balsamifera* DC.) against aspirin-induced gastric ulcer model in rats. *Asian Pac J Trop Biomed*. 2014;4(suppl 1):S500-S504.
13. Iwamoto J, Saito Y, Honda A, Matsuzaki Y. Clinical features of gastroduodenal injury associated with long-term low-dose aspirin therapy. *World J Gastroenterol*. 2013;19:1673-1682.
14. Yuan Y, Padol IT, Hunt RH. Pepic ulcer disease today. *Nat Clin Pract Gastroenterol Hepatol*. 2006;3:80-89.
15. Dunlop RH, Malbert CH. *Veterinary Pathophysiology*. Hoboken, NJ: Wiley; 2004.
16. Mei Q, Korsgren M, Erjefält JS, Sundler F. Eosinophil infiltration and activation at the gastric ulcer margin in rats. *Eur J Gastroenterol Hepatol*. 2002;14:503-511.
17. Done JD, Rudick CN, Quick ML, Schaeffer AJ, Thumbikat P. Role of mast cells in male chronic pelvic pain. *J Urol*. 2012;187:1473-1482.
18. Barczyk M, Debek W, Chyczewski L. Mast cells in the gastrointestinal tract. *Rocz Akad Med Bialymst*. 1995;40:36-57.
19. Nakajima S, Krishnan B, Ota H, et al. Mast cell involvement in gastritis with or without *Helicobacter pylori* infection. *Gastroenterology*. 1997;113:746-754.
20. Puram S, Suh HC, Kim SU, et al. Effect of GutGard in the management of *Helicobacter pylori*: a randomized double blind placebo controlled study. *Evid Based Complement Alternat Med*. 2013;2013:263805.
21. Biswas K, Bandyopadhyay U, Chattopadhyay I, Varadaraj A, Ali E, Banerjee RK. A novel antioxidant and antiapoptotic role of omeprazole to block gastric ulcer through scavenging of hydroxyl radical. *Biol Chem*. 2003;278:10993-11001.
22. Nartey ET, Ofosuhene M, Kudzi W, Agbale CM. Antioxidant and gastric cytoprotective prostaglandins properties of *Cassia sieberiana* roots bark extract as an anti-ulcerogenic agent. *BMC Complement Altern Med*. 2012;12:65.
23. Mitobe Y, Hiraishi H, Sasai T, Shimada T, Terano A. The effects of aspirin on antioxidant defences of cultured rat gastric mucosal cells. *Aliment Pharmacol Ther*. 2000;14(suppl 1):10-17.
24. Farinati F, Della Libera G, Cardin R, et al. Gastric antioxidant, nitrites, and mucosal lipoperoxidation in chronic gastritis and *Helicobacter pylori* infection. *J Clin Gastroenterol*. 1996;22:275-281.

25. Danesh BJZ, Duncan A, Russell RI, Mitchell G. Effect of intragastric pH on mucosal protective action of sucralfate. *Gut*. 1988; 29:1379-1385.
26. Nugroho AE, Ikawati Z, Sardjiman, Maeyama K. Effects of benzylidenecyclopentanone analogues of curcumin on histamine release from mast cells. *Biol Pharm Bull*. 2009;32:842-849.
27. Nugroho AE, Riyanto S, Sukari MA, Maeyama K. Anti-allergic effects of marmin, a coumarine isolated from *Aegle marmelos* Correa: in vitro study. *Int J Phytomed*. 2011;3:84-97.
28. Harwoko A, Pramono S, Nugroho AE. Triterpenoid-rich fraction of *Centella asiatica* leaves and in vivo antihypertensive activity. *Int Food Res J*. 2014;21:149-154.
29. Nugroho AE, Hermawan A, Putri DDP, Novika A, Meiyanto E. Combinational effects of hexane insoluble fraction of *Ficus septica* Burm. F. and doxorubicin chemotherapy on T47D breast cancer cells. *Asian Pac J Trop Biomed*. 2013;3:297-302.
30. Nugroho AE, Anas Y, Arsito PN, Wibowo JT, Riyanto S, Sukari MA. Effects of marmin: a compound isolated from *Aegle marmelos* correa, on contraction of the guinea pig-isolated trachea. *Pak J Pharm Sci*. 2011;24:427-433.
31. Nugroho AE, Ikawati M, Hermawan A, Putri DDP, Meiyanto E. Cytotoxic effect of ethanolic extract fractions of Indonesian plant *Ficus septica* Burm. f. on human breast cancer T47D cell lines. *Int J Phytomed*. 2011;3:216-226.
32. Nugroho AE, Andrie M, Warditiani NK, Siswanto E, Pramono S, Lukitaningsih E. Antidiabetic and antihiperlipidemic effect of *Andrographis paniculata* (Burm. f.) Nees and andrographolide in high-fructose-fat-fed rats. *Indian J Pharmacol*. 2012;44: 377-381.
33. Nugroho AE, Rais IR, Setiawan I, et al. Pancreatic effect of andrographolide isolated from *Andrographis paniculata* (Burm. f.) Nees. *Pak J Biol Sci*. 2014;17:22-31. doi:10.3923/pjbs.2014.22.31.
34. Nugroho AE, Lindawati NY, Herlyanti K, Widyastuti L, Pramono S. Anti-diabetic effect of a combination of andrographolide-enriched extract of *Andrographis paniculata* (Burm f.) Nees and asiaticoside-enriched extract of *Centella asiatica* L. in high fructose-fat fed rats. *Indian J Exp Biol*. 2013;51:1101-1108.
35. Nugroho AE, Kusumaramdani G, Widyaningar A, Anggoro DP, Pramono S. Antidiabetic effect of combinations of n-hexane insoluble fraction of ethanolic extract of *Andrographis paniculata* with other traditional medicines. *Int Food Res J*. 2014;21: 785-789.