

Odontogenic Sinusitis: A Review of the Current Literature

Ryan E. Little, MD ; Christopher M. Long, MD; Todd A. Loehrl, MD; David M. Poetker, MD

Objectives: To present current literature on the topic of odontogenic sinusitis.

Data Source: PubMed literature search for odontogenic sinusitis.

Results: Odontogenic sinusitis is an inflammatory condition of the paranasal sinuses that is the result of dental pathology, most often resulting from prior dentoalveolar procedures, infections of maxillary dentition, or maxillary dental trauma. Infections are often polymicrobial with an anaerobe-predominant microbiome requiring special considerations for antimicrobial therapy. Medical management and treatment of the underlying dental pathology remains a critical initial step in the treatment of odontogenic sinusitis, however recent literature suggests that a significant portion of patients may require endoscopic sinus surgery for successful disease resolution.

Conclusions: This review describes the essential epidemiological and etiological factors, relevant clinical findings and diagnostic modalities, microbiologic and antimicrobial considerations, as well as the medical and surgical treatment approaches commonly utilized for the management of odontogenic sinusitis.

Key Words: Odontogenic sinusitis, rhinosinusitis of dental etiology, dental infection, periapical abscess, maxillary sinusitis.

Level of Evidence: NA.

INTRODUCTION

Over 30 million Americans suffer from rhinosinusitis, accounting for approximately 20 million office visits and 1.2 million hospital visits each year.¹ Odontogenic sinusitis describes the presence of sinonasal disease where radiographic, microbiologic, and/or clinical evidence indicates it is of a dental origin. Approximately 10% of all sinusitis cases are the result of an odontogenic process, with several reports in the literature citing that up to 40% of all sinusitis cases may have an underlying dental pathology.^{2,3} Furthermore, as many as half a million Americans have dental implant surgery every year.⁴ Recent literature suggests that rising rates of dental surgery over the last several years may be associated with an increased incidence of iatrogenic causes for sinusitis.^{5–7}

The paranasal sinuses are air-filled cavities that develop from the facial bones of the skull. These sinuses are named for the bones in which they originate. This

includes four paired sinuses: maxillary, ethmoid, sphenoid, and frontal. The paranasal sinuses are immature at birth and mature with age. Both nasal cavities have a total surface area of about 150 cm².⁸ The resting rate of mucus production is about 0.5 to 1 ml of mucus per cm² over a 24-hour period.⁹ As a result, the paranasal sinuses produce 75 to 150 ml of mucus per day, which helps to humidify inspired air and facilitate alveolar gas exchange. In addition, mucus traps particulate matter and the mucociliary clearance of the respiratory epithelium removes mucus from the sinuses. Patency of sinus ostia and normal mucociliary function are required for normal function of the paranasal sinuses. The maxillary sinus is the first sinus to develop in utero via evagination of the nasal mucosa into the lateral cartilaginous environment from the primitive ethmoid infundibulum. This sinus is present at birth and demonstrates growth periods from birth to 3 years of age and further maturation from 7 to 12 years of age. The natural ostium is located in the superior aspect of the medial wall of the sinus. The ostiomeatal unit is a functional unit involved in the drainage pathway for and ventilation of the maxillary, anterior ethmoid and frontal sinuses.¹⁰ Processes which impact the patency of the ostiomeatal unit may have an impact on the adjacent sinuses and have a significant impact on sinonasal disease.¹¹

Epidemiology

The etiology of acute sinonasal inflammation or sinusitis may be the result of environmental allergens, irritants, bacterial infections, fungus, or dental issues including inflammation, infection, or foreign bodies. Odontogenic sinusitis is most common among 40–60 year olds with a slight female predominance.^{7,12,13} Approximately 50% of patients will report previous dental surgery or

This is an open access article under the terms of the Creative Commons Attribution-NonCommercial-NoDerivs License, which permits use and distribution in any medium, provided the original work is properly cited, the use is non-commercial and no modifications or adaptations are made.

From the Department of Otolaryngology & Communication Sciences (R.E.L., C.M.L., T.A.L., D.M.P.), Medical College of Wisconsin, Milwaukee, Wisconsin, U.S.A.; and the Milwaukee VA Medical Center (ZABLOCKI) (R.E.L., C.M.L., T.A.L., D.M.P.), Milwaukee, Wisconsin, U.S.A.

Editor's Note: This Manuscript was accepted for publication 15 February 2018.

Conflict of Interest: The authors have no conflicts of interest

Funding: None

Send correspondence to David M. Poetker, MD, Department of Otolaryngology and Communication Sciences, Medical College of Wisconsin, 9200 W. Wisconsin Ave., Milwaukee, WI 53226. Email: dpoetker@mcw.edu

DOI: 10.1002/liv.147

infection, however only one-third will report associated dental pain.¹⁴ It is estimated that 10% of cases of chronic maxillary sinusitis are odontogenic in origin, though this has been reported to be as high as 75% among patients with unilateral maxillary disease.^{5,15} Although the overall incidence of odontogenic sinusitis remains relatively low, several studies have demonstrated that the incidence of odontogenic sinusitis appears to be increasing over the last decade.¹⁶

Etiology

Odontogenic sinusitis is most commonly the result of iatrogenic injury of the mucoperiosteum, or Schneiderian membrane, of the maxillary sinus.¹³ Dental procedures such as dental extractions, maxillary dental implant placement, sinus augmentation grafts ("sinus lift"), misplaced foreign bodies as well as orthognathic and cleft surgery procedures have all been associated with odontogenic sinusitis.¹⁵ Other potential etiologies include periodontal and periapical disease. Endodontic infections are typically the result of extension of dental caries into the dental pulp resulting in pulpitis and apical infection. Alternatively, chronic periodontitis may occur in the setting of chronic infection of a tooth socket. The resultant inflammation and/or disruption of the Schneiderian membrane leads to mucosal inflammation and altered mucociliary function within the maxillary sinus.¹² Impaired mucociliary function results in altered mucus transport, impaired mucosal defenses, blockage of sinus ostia and resultant bacterial infection and inflammation. Other less common etiologies of odontogenic sinusitis include maxillary bone trauma, odontogenic cysts, neoplasms or other inflammatory processes.¹⁷

A recent systematic review examining the etiology of odontogenic sinusitis among 674 patients demonstrated that an iatrogenic etiology accounted for 65.7% of cases, apical periodontal pathology accounted for 25.1% of cases, and marginal periodontitis accounted for 8.3%.¹² This study further demonstrated that the most commonly affected maxillary teeth, in order of frequency, were the first molar (35.6%), second molar (22%), third molar (17.4%), and second premolar (14.4%).

Improvement in oral hygiene through various public health campaigns and enhanced national awareness have reduced the frequency of periodontal disease; however, recent increases in the rates of invasive dental surgery, including dental implant treatment, have been associated with rising rates of iatrogenic causes for sinusitis.^{5,6,17} In addition, rates of surgical intervention to address iatrogenic cases of odontogenic sinusitis may be as high as 80%.¹¹ Damage to the Schneiderian membrane of the sinus floor can occur with dental implants or foreign bodies, and this finding has also been associated with the need for surgical intervention.¹¹

Clinical Evaluation and Diagnosis

The clinical presentation of odontogenic sinusitis varies, but most commonly includes symptoms of facial pain or pressure, postnasal drip, nasal congestion,

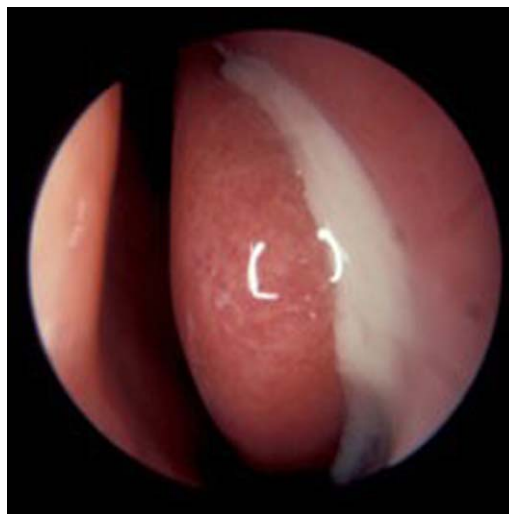

Fig. 1. Endoscopic examination of the left nasal cavity and left middle turbinate demonstrating purulent fluid in the middle meatus.

purulent anterior rhinorrhea that may be unilateral, foul smell or taste, and fatigue. Obtaining a thorough history particularly as it relates to dentoalveolar surgery is critical. Of particular note is the finding that dental pain is often absent in odontogenic sinusitis, and when dental pain is present in the absence of other nasal symptoms, it is not specific for sinusitis.¹⁸ Of additional note, less than half of patients report a recent dental procedure. This is likely due to the latency period of up to a year for augmentative dental surgery-associated maxillary sinusitis and a latency of almost four years in implant-associated maxillary sinusitis.¹⁵ Careful evaluation of dentition for root fractures, status of the dental pulp, periodontal tissues, presence of an oral-antral fistula and condition of existing dental restorations are important components of the initial physical examination. Additionally, intranasal examination with anterior rhinoscopy or nasal endoscopy may demonstrate findings of unilateral purulent rhinorrhea or edema but remains less sensitive in the detection of odontogenic sinusitis as compared to imaging modalities (Fig. 1).

Radiographic imaging is an essential diagnostic tool in the diagnosis and management of odontogenic sinusitis. Standard dental radiographs include periapical radiography and panoramic radiography. Periapical radiography is rendered in two dimensions with high resolution allowing for the detection of dental caries and periapical radiolucency. However, it should be noted that this modality is limited in the evaluation of multi-rooted teeth which are most commonly the source for odontogenic sinusitis.¹⁹ Furthermore, previous studies have demonstrated that a periapical radiolucency must be very large or perforate the cortical bone in order to be observed radiographically. Panoramic radiography produces a two-dimensional representation of the curved surfaces of the maxilla. This imaging modality allows for determination of the size of periapical lesions, visualization of cystic lesions of the maxilla, as well as mucosal

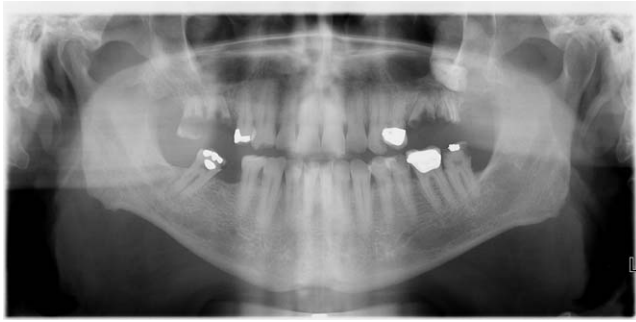


Fig. 2. Panoramic radiography showing a two-dimensional representation of the curved surfaces of the maxilla and evidence of dental restorations in a patient with odontogenic sinusitis (see Fig. 3).

thickening along the floor of the maxillary sinus (Fig. 2). However, the sensitivity of panoramic radiography in detecting periapical pathology is lower than periapical radiography due to the two-dimensional nature and resultant anatomic superimposition.¹⁹ The overall sensitivity of dental radiographs in the detection of carious dental lesions and periodontal disease are 60% and 85%, respectively.²⁰ As a result, high rates of false negatives have been reported with both modalities with one study demonstrating that periapical radiography missed more than 60% of periodontal pathology when compared to cone beam computerized tomography (CT) imaging.²¹

CT scans produce a three-dimensional rendering of pertinent anatomical structures in axial, sagittal and coronal planes. This modality offers high resolution images in multiple planes and eliminates superimposition of maxillary molars allowing for clinicians to distinguish between tissues of differing physical density. Maxillofacial CT scans allow for a detailed examination of the patient's paranasal sinus anatomy and detection of sinonasal inflammation (Fig. 3). As a result, this imaging modality is the gold standard for radiographic evaluation of the paranasal sinuses in patients with chronic and recurrent acute sinonasal disease.²² Major disadvantages of this modality include radiation exposure, limited detection of dental pathology and susceptibility to metal artifacts from prior dental restorations and craniofacial hardware.²¹

Radiographic examination of patients with odontogenic sinusitis most commonly demonstrates unilateral maxillary sinusitis. More than 70% of maxillofacial CT scans showing unilateral maxillary sinusitis may be attributable to an odontogenic infection.^{23,24} However, several studies have documented that dental disease may be frequently overlooked on CT by radiologists leading to misdiagnosis.^{25,26} As a result, clinicians should carefully analyze maxillary dentition when interpreting maxillofacial CT scans, particularly in the setting of unilateral maxillary sinusitis.²⁷ Furthermore, involvement of the ostiomeatal unit may result in extension to adjacent paranasal sinuses with reported rates of extramaxillary extension ranging from 27% to 60% among patients with odontogenic sinusitis.²⁸ In addition, as many as 20% of patients with odontogenic sinusitis may

have bilateral involvement.²⁹ Therefore, clinicians should maintain a high degree of suspicion for an odontogenic etiology.

Several studies have examined the association between specific tooth roots of maxillary dentition as it relates to the development of chronic maxillary sinusitis. Maillet et al.¹⁴ retrospectively reviewed 871 cone-beam CT scans for the presence of sinusitis in one or both maxillary sinuses. Eighty-two imaging studies demonstrated "maxillary sinusitis." One hundred teeth were shown to be associated with a change in the integrity of the maxillary sinus floor. In this study, the maxillary first molar was most commonly associated with these findings (55%), followed by the maxillary second molar (34%), second premolar (8%) and first premolar (3%). Though the mesiobuccal root of the maxillary second molar is well documented to be closest to the floor of the maxillary sinus, theoretically increasing the risk of Schneiderian membrane disruption; the palatal root of the maxillary first molar was most commonly associated with perforation of the sinus floor. This may be due to the fact that the maxillary first molar erupts earlier than the second molar, resulting in greater susceptibility to carious dental lesions over time.^{14,21}

Microbiology

The bacteriology of odontogenic sinusitis is distinctly different from cases of non-odontogenic sinusitis.²⁹ Odontogenic sinus infections are generally polymicrobial with predominantly anaerobic organisms present in cultures, commonly including *Peptostreptococcus*, *Prevotella*, and *Fusobacterium*.^{3,30} These higher rates of mixed aerobic and anaerobic infections among patients with odontogenic sinusitis have been well documented in the literature.^{3,29,30} Zirk et al.¹³ reviewed 121 cases of odontogenic sinusitis and noted that 70% demonstrated anaerobes and

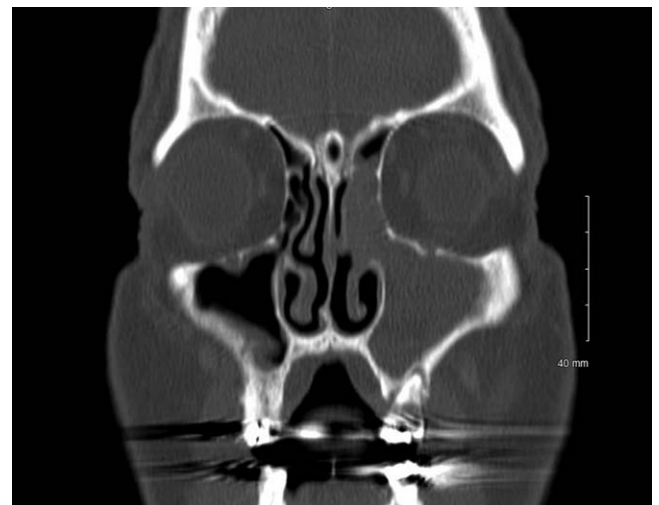

Fig. 3. Computerized tomography (CT) in a coronal plane of a patient with odontogenic sinusitis demonstrating complete opacification of the left maxillary and anterior ethmoid sinuses with associated involvement of the ostiomeatal unit. There is a periapical radiolucency of the left maxillary first molar. Please note, this is the same patient as in Figure 2, taken a week apart.

30% demonstrates aerobes. The highest susceptibility rates were observed with piperacillin (93.9%) and ampicillin (80%) combined with a β -lactamase inhibitor, followed by cefotaxime (78%), cefuroxime (69%), and clindamycin (50%). Fluoroquinolones, specifically moxifloxacin (86%) and ciprofloxacin (62%), and tetracyclines (63%) were alternative treatment options in penicillin allergic patients.

Surgical Management

Odontogenic sinus disease refractory to medical management traditionally involves definitive treatment of the underlying dental pathology. This may involve further endodontic treatment with root canal, apicoectomy, or dental extraction. Endoscopic sinus surgery may be required for patients who fail initial medical management and dental treatment.^{31–33} A recent retrospective review of 43 patients with odontogenic sinusitis demonstrated that 52% of patients improved with medical and dental treatment, while 48% ultimately required functional endoscopic sinus surgery. Among this cohort of patients, 14% patients required both dental intervention and endoscopic sinus surgery. Mattos et al.³² further identified factors predictive of the need for endoscopic sinus surgery. These predictive factors included the presence of ostiomeatal unit involvement and prior dental procedures (odds ratio 37.3 and 7.4, respectively). Additionally, all patients with oral-antral fistula or retained dental foreign bodies ultimately required functional endoscopic sinus surgery. Kim et al.¹¹ reviewed 19 patients treated for odontogenic sinusitis specifically as the result of a dental implant. Only 21% of patients in this cohort were successfully managed medically, while 79% required endoscopic sinus surgery. The maxillary second molar was the most commonly implanted tooth, with a mean symptom duration of 4.31 months. There were significantly higher rates of ostiomeatal unit involvement among patients in this study undergoing endoscopic sinus surgery, further supporting the conclusion that ostiomeatal unit involvement may change the clinical course of the disease and its potential for response to conservative treatment.

Successful management of odontogenic sinusitis involves a combination of medical treatment, dental surgery and/or endoscopic sinus surgery. Although several studies have emphasized dental surgery as the primary treatment modality for odontogenic sinusitis, there is recent evidence to suggest that endoscopic sinus surgery alone may be an effective treatment approach.^{26,34} A recent study examining odontogenic sinusitis in patients with dental implants who had undergone prior “sinus lift” procedures demonstrated that endoscopic sinus surgery with culture directed antibiotic therapy can be an effective treatment strategy for achieving disease resolution.³⁴ Among this small cohort of patients with intact dental implants, all were able to be successfully managed without removal of the involved implant at an average of 18 months follow-up. Wang et al.²⁶ described a cohort of patients undergoing treatment for odontogenic sinusitis. Among the patients with complete disease resolution, 33% required sinus surgery alone and

33% required concurrent sinus surgery and dental surgery. Although a large portion of patients were successfully managed with endoscopic sinus surgery alone, the authors acknowledged that dental surgery should remain the first-line surgical treatment as it appropriately targets the source of infection.

CONCLUSION

Odontogenic sinusitis is an important and relatively common disease process that is often underrecognized and frequently not identified by radiologists. This disease process is often refractory to conventional management for rhinosinusitis due to the polymicrobial, anaerobe-predominant nature of these infections as well as ongoing dental pathology. As a result, the clinicians evaluating patients with rhinosinusitis should maintain a high degree of suspicion for an odontogenic etiology, particularly for cases of chronic maxillary sinusitis, cases recalcitrant to conservative treatment, and patients with a history of prior dentoalveolar surgery. An individualized, multifaceted, and multidisciplinary approach to the treatment of odontogenic sinusitis is critical to successful disease resolution.

BIBLIOGRAPHY

1. National Health Interview Survey. Summary Health Statistics for U.S. Adults: National Health Interview Survey 2012. https://www.cdc.gov/nchs/data/series/sr_10/sr10_260.pdf. Accessed October 15, 2017.
2. Melen I, Lindahl L, Andreasson L, Rundcrantz H. Chronic maxillary sinusitis: Definition, diagnosis and relation to dental infections and nasal polyposis. *Acta otolaryngol (Stockh)* 1986;101:320–327.
3. Puglisi S, Privitera S, Maiolino L, et al. Bacteriological findings and antimicrobial resistance in odontogenic and non-odontogenic chronic maxillary sinusitis. *J Medical Microbiology* 2011;60:1353–1359.
4. American Academy of Implant Dentistry. Dental Implants Facts and Figures 2017. https://www.aaid.com/about/Press_Room/Dental_Implants_FAQ.html. Access October 15, 2017.
5. Mehra P, Jeong D. Maxillary sinusitis of odontogenic origin. *Curr Infect Dis Rep* 2008;10(3):205–210.
6. Lopatin AS, Sysolyatin SP, Sysolyatin PG, Melnikov MN. Chronic maxillary sinusitis of dental origin: Is external surgical approach mandatory? *Laryngoscope* 2002;112:1056–1059.
7. Arias-Irimia O, Barona-Dorado C, Santos-Marino JA, Martinez-Rodriguez N, Martinez-Gonzalez JM. Meta-analysis of the etiology of odontogenic maxillary sinusitis. *Med Oral Patol Oral Cir Bucal* 2010;15:70–73.
8. Mygind N, Dahl R. Anatomy, physiology and function of the nasal cavities in health and disease. *Adv Drug Deliv Rev* 1998;29:3–12.
9. Quraishi MS, Jones NS, Mason J. The rheology of nasal mucus: a review. *Clin Otolaryngol* 1998;23:403–413.
10. Kennedy DW. Functional endoscopic sinus surgery. *Arch Otolaryngology* 1985;111:643–649.
11. Kim SJ, Park JS, Kim HT, Lee CH, Park YH, Bae JH. Clinical features and treatment outcomes of dental implant-related paranasal sinusitis: A 2-year prospective observational study. *Clin Oral Implants Research* 2016;27:100–104.
12. Lechien JR, Filleul O, de Araujo PC, Hsieh JW, Chantrain G, Saussez S. Chronic maxillary rhinosinusitis of dental origin: a systematic review of 674 patient cases. *Int J Otolaryng* 2014;1–9.
13. Zirk M, Dreiseidler T, Pohl M, et al. Odontogenic sinusitis maxillaris: A retrospective study of 121 cases with surgical intervention. *J Craniomaxillofac Surg* 2017;45:520–525.
14. Maillet M, Bowles WR, McClanahan SL, John MT, Ahmad M. Cone-beam computed tomography evaluation of maxillary sinusitis. *J Endodontics* 2011;37:753–757.
15. Troeltzsch M, Pache C, Troeltzsch M, et al. Etiology and clinical characteristics of symptomatic unilateral maxillary sinusitis: A review of 174 cases. *J Craniomaxillofac Surg* 2015;43:1522–1529.
16. Hoskison E, Daniel M, Rowson JE, Jones NS. Evidence of an increase in the incidence of odontogenic sinusitis over the last decade in the UK. *J Laryngology & Otology* 2012;126:43–46.
17. Gamba P. Odontogenic maxillary cysts post-dental implant: Proposal of new radiological/clinical classification. *Int J Innovative Research in Med Sci* 2016;10:431–438.
18. Brook I. Sinusitis of odontogenic origin. *Otolaryngol Head Neck Surg* 2006;135:349–355.

19. Shahbazian M, Jacobs R. Diagnostic value of 2D and 3D imaging in odontogenic maxillary sinusitis: a review of literature. *J Oral Rehab* 2012; 39:294–300.
20. Douglass CW, Valachovic RW, Wijesinha A, et al. Clinical efficacy of dental radiography in the detection of dental caries and periodontal diseases. *Oral Surg Oral Med Oral Pathol* 1986;62:330–339.
21. Shahbazian M, Vandewoude C, Wyatt J, Jacobs R. Comparative assessment of periapical radiography and CBCT imaging for radiodiagnostics in posterior maxilla. *Odontology* 2015;103:97–104.
22. Rosenfeld RM, Andes D, Bhattacharyya N, et al. Clinical practice guideline: Adult sinusitis. *Otolaryngol Head Neck Surg* 2007;137(3):S1–S31.
23. Matsumoto Y, Ikeda T, Yokoi H, Kohno N. Association between odontogenic infections and unilateral sinus opacification. *Auris Nasus Larynx* 2015;42:288–293.
24. Bomeli SR, Branstetter BF, Ferguson BJ. Frequency of a dental source for acute maxillary sinusitis. *Laryngoscope* 2009;119(3):580–584.
25. Pokorny A, Tataryn R. Clinical and radiographic findings in a case series of maxillary sinusitis of dental origin. *Int Forum Allergy Rhinol* 2013;3: 973–979.
26. Wang KL, Nichols BG, Poetker DM, Loehrl TA. Odontogenic sinusitis: a case series studying diagnosis and management. *Int Forum Allergy Rhinol* 2015;5:597–601.
27. Longhini AB, Branstetter BF, Ferguson BJ. Otolaryngologists' perception of odontogenic maxillary sinusitis. *Laryngoscope* 2012;122:1910–1914.
28. Saibene AM, Pipolo GC, Lozza P, et al. Redefining boundaries in odontogenic sinusitis: a retrospective evaluation of extramaxillary involvement in 315 patients. *Int Forum Allergy Rhinol* 2014;4:1020–1023.
29. Saibene AM, Vassena C, Pipolo C, et al. Odontogenic and rhinogenic chronic sinusitis: A modern microbiological comparison. *Int Forum Allergy Rhinol* 2015;6:41–45.
30. Kuan EC, Suh JD. Systemic and odontogenic etiologies of chronic rhinosinusitis. *Otolaryngol Clin N Am* 2017;50:95–111.
31. Fadda GL, Berrone M, Crosetti E, Succo G. Monolateral sinonasal complications of dental disease or treatment: When does endoscopic endonasal surgery require an intraoral approach? *Acta Otorhino Italica* 2016;36: 300–309.
32. Mattos JL, Ferguson BJ, Lee S. Predictive factors in patients undergoing endoscopic sinus surgery for odontogenic sinusitis. *Int Forum Allergy Rhinol* 2016;6:697–700.
33. Lee CL, Lee SJ. Clinical features and treatments of odontogenic sinusitis. *Yonsei Med J* 2010;51:932–937.
34. Jiam NT, Goldberg AN, Murr AH, Pletcher SD. Surgical treatment of chronic rhinosinusitis after sinus lift. *Am J Rhinol Allergy* 2017;31:271–275.