

# Isolated large vessel pulmonary vasculitis leading to pulmonary artery aneurysm formation: a case report and literature review

Nima Moghaddam<sup>1</sup>, Bahar Moghaddam<sup>1</sup>, Natasha Dehghan<sup>1,2</sup> and Nathan W. Brunner<sup>1,3</sup>

<sup>1</sup>Department of Medicine, University of British Columbia, Vancouver, BC, Canada; <sup>2</sup>Division of Rheumatology, University of British Columbia, Vancouver, BC, Canada; <sup>3</sup>Division of Cardiology, University of British Columbia, Vancouver, BC, Canada

## Abstract

Pulmonary artery (PA) vasculitis occurs in association with primary vasculitides—in particular, giant cell arteritis, Takayasu's arteritis, or Behçet's disease—or secondary vasculitis as a result of infections or malignancy. However, PA vasculitis in isolation and with concomitant aneurysmal dilation is an unusual finding. We present a rare case of PA aneurysm secondary to isolated PA vasculitis in an asymptomatic patient with no features of systemic vasculitis. This case highlights one of the first cases of PA vasculitis managed with surgical resection alone.

## Keywords

pulmonary artery aneurysm, large vessel vasculitis, isolated pulmonary vasculitis

Date received: 26 December 2017; accepted: 24 February 2018

Pulmonary Circulation 2018; 8(2) 1–4

DOI: 10.1177/2045894018765346

## Introduction

Pulmonary artery (PA) aneurysms (PAA) are infrequently encountered in clinical practice.<sup>1</sup> While there are various proposed etiologies for PAAs, PA vasculitis is an uncommon cause for PAA formation.<sup>2</sup> PA vasculitis often occurs in the context of an underlying systemic vasculitis. Isolated PA vasculitis is a rare entity with only a few reports of this presentation leading to aneurysm of the pulmonary vasculature. Herein, we describe a patient presenting with an incidental finding of large aneurysmal dilatation of the main pulmonary trunk with histopathologic features of localized pulmonary vasculitis. A literature review of isolated pulmonary vasculitis and its association with PAAs was conducted.

## Case report

A 74-year-old woman was assessed in the outpatient cardiology clinic for an incidental finding of PAA on computed tomography (CT) of the chest. Past medical history was only significant for minimal past smoking and mild chronic obstructive pulmonary disease (COPD) with FEV<sub>1</sub> of 87% predicted. Four months before her presentation, she had

received antibiotics for a presumed respiratory tract infection with productive cough and an episode of scant hemoptysis. A chest X-ray done as part of an infectious work-up incidentally showed abnormal contour of the pulmonary artery. This was further characterized on a chest CT where an aneurysmal dilatation of the main pulmonary artery up to 5.7 cm was identified (Fig. 1).

Clinically, she was asymptomatic with no chest pain or dyspnea. She had intermittent productive cough but no history of hemoptysis except the streaks of blood-tinged sputum during her recent respiratory infection. She had no systemic symptoms including fever, weight loss, or any clinical features of vasculitis. Her physical exam was unremarkable. Blood pressure was within normal range with no differential in extremities. There were no vascular bruits or pulse differential.

Corresponding author:

Nathan W. Brunner, Gordon and Leslie Diamond Health Care Center, Pulmonary Hypertension Clinic, 7th floor, 2775 Laurel Street, Vancouver, BC, Canada V5Z 1M9.

Email: nathan.brunner@vch.ca

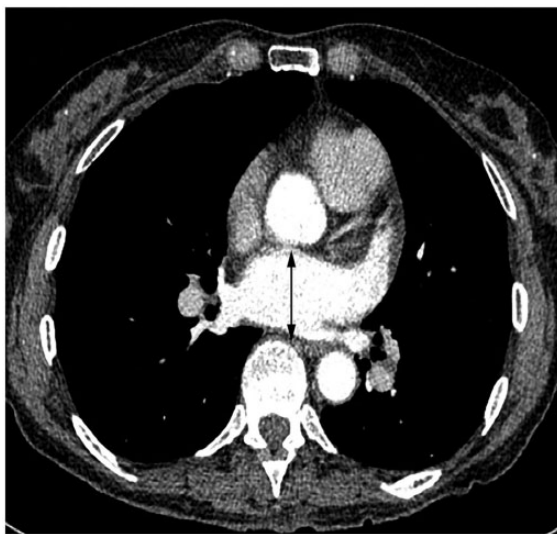


Creative Commons Non Commercial CC-BY-NC: This article is distributed under the terms of the Creative Commons Attribution-NonCommercial 4.0 License (<http://www.creativecommons.org/licenses/by-nc/4.0/>) which permits non-commercial use, reproduction and distribution of the work without further permission provided the original work is attributed as specified on the SAGE and Open Access pages (<https://us.sagepub.com/en-us/nam/open-access-at-sage>).

© The Author(s) 2018.  
Reprints and permissions:  
[sagepub.co.uk/journalsPermissions.nav](http://sagepub.co.uk/journalsPermissions.nav)  
[journals.sagepub.com/home/pul](http://journals.sagepub.com/home/pul)



Laboratory investigations showed normal inflammatory markers with C-reactive protein 1.3 mg/L (normal <3 mg/L) and erythrocyte sedimentation rate of 14 mm/h (normal <20 mm/h). Complete blood cell count, renal function, and liver enzymes were normal. Autoimmune investigations were also unremarkable with negative antinuclear, extractable nuclear antigen, and anti-neutrophil cytoplasmic antibodies. The remainder of her rheumatologic work-up including rheumatoid factor, anti-cyclic citrullinated peptide, and immunoglobulin G (IgG) subclasses were negative. Infectious work-up did not reveal any Hepatitis B and C, syphilis, or HIV.

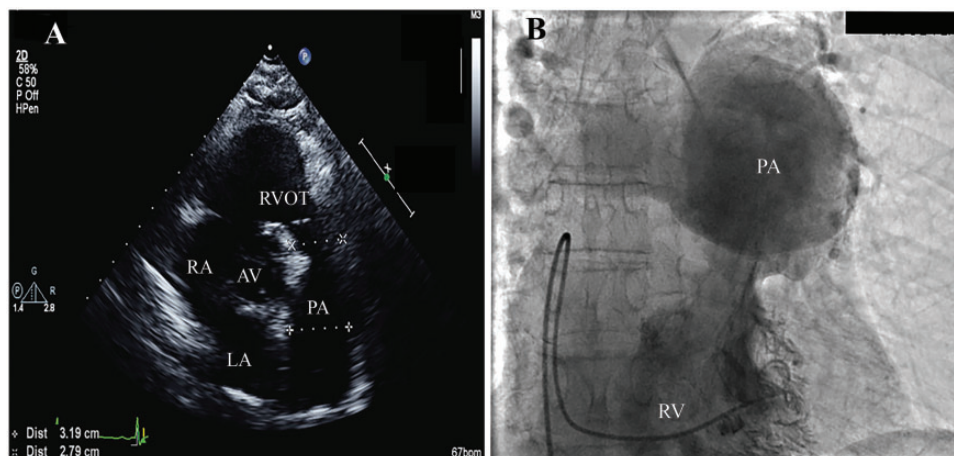


**Fig. 1.** Axial CT scan of the chest showing aneurysmal dilatation of the main pulmonary artery to 5.7 cm (double arrowheads).

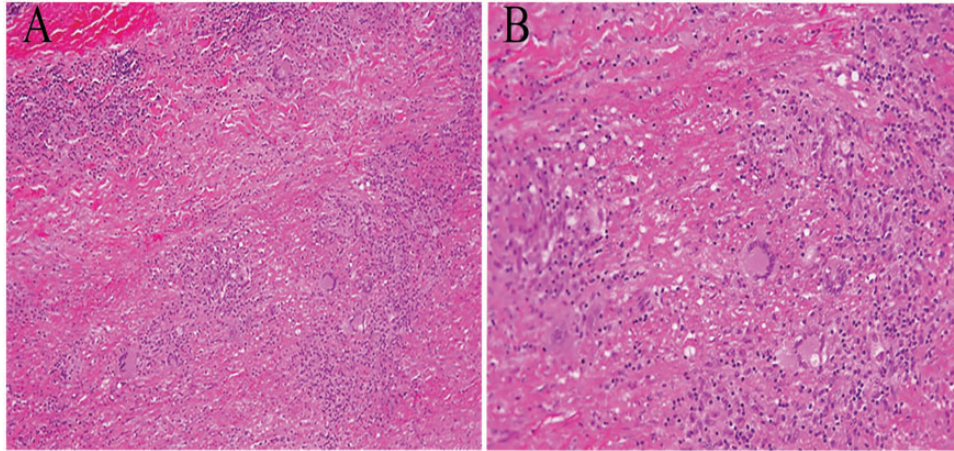
Transthoracic echocardiography demonstrated enlargement of the PA at 32 mm (Fig. 2a) with normal cardiac chambers sizes and preserved biventricular function. The maximum diameter of the aneurysm was not within the field of the echocardiogram. The pulmonary valve was structurally normal with no significant stenosis or regurgitation. The right ventricular systolic pressure was normal. Right and left heart catheterization provided direct confirmation of an aneurysm in the proximal main PA (Fig. 2b). There was no evidence of left-to-right shunting and no obstructive coronary disease. The pulmonary arterial pressures and hemodynamics were within the normal ranges. A repeat non-contrast CT of the chest showed an increase in dilatation of the PAA to 6.4 cm (from 5.7 cm) in a six-month interval.

The large size of the PAA and its rapid progression prompted a surgical assessment with resection of the PAA. Intraoperatively, the PAA was found to involve the main PA and its bifurcation. After the PAA resection, the PA bifurcation was reconstructed with an 18-mm Dacron and the main pulmonary trunk was replaced with homograft PA. The histopathology from the resected PAA showed extensive granulomatous vasculitis with numerous multinucleated giant cells and prominent lymphocytic infiltration (Fig. 3). Microbiology staining including special stains for fungus, acid-fast bacilli, and spirochetes as well as immunohistochemistry for IgG4 were negative. There was no evidence of fibrinoid deposition arguing against ANCA-associated vasculitis. A temporal artery biopsy and CT angiography of the abdomen and pelvis were completed to assess for involvement of other arteries. Both studies were normal.

In view of the histopathological findings from the main PA resection, a final diagnosis of isolated large-vessel vasculitis was made. We believe that her clinical picture presents a rare case of isolated PA vasculitis leading to aneurysmal



**Fig. 2.** (a) Parasternal short axis view measuring the proximal PA aneurysm at 3.2 cm (dotted line capped with +); (b) pulmonary angiogram performed during the right heart catheterization revealed significant enlargement of the main pulmonary trunk without any signs of pulmonary hypertension. AV, aortic valve; LA, left atrium; PA, pulmonary artery; RA, right atrium; RVOT, right ventricular outflow tract; RV, right ventricle.



**Fig. 3.** The histopathology from the resected PAA showing extensive granulomatous vasculitis causing patchy laminar medial necrosis. Numerous multinucleated giant cells and clusters of activated epithelioid macrophages are seen through all the layers of the pulmonary artery wall. Further findings include prominent lymphocytic infiltrate in the adventitia and media with marked thickening of the adventitia by dense collagen. A) 10X magnification B) 40X magnification. PAA: pulmonary artery aneurysm.

dilation of the main pulmonary trunk. Extensive cardiac, rheumatologic, and infectious work-up failed to show any systemic features of vasculitis or other disorders that may trigger secondary vasculitis. Given the absence of symptoms, normal inflammatory markers, and isolated vessel involvement treated with surgical resection, conservative management with serial monitoring was pursued. Follow-up chest CT showed intact surgical anastomosis with main PA diameter of 32 mm. The patient continues to do well one year after her PAA resection and is followed annually with repeat imaging and echocardiogram.

## Discussion

PAA is a rare vascular anomaly with an incidence of 1 in 14,000.<sup>1</sup> Proximal PAA which involves the pulmonary arterial trunk and bilateral main pulmonary arteries comprises the majority of the reported PAA cases.<sup>3</sup> A diameter of  $>4$  cm has been defined as aneurysmal dilatation of proximal PA.<sup>4</sup> Although PAAs are associated with many sequelae including thrombus formation or mechanical compression,<sup>5</sup> potential dissection or rupture remains the most catastrophic complication.<sup>6</sup> Various etiologies for PAA formation have been postulated based on case reports or series.<sup>2,8</sup> Congenital heart defects or infectious causes such as syphilis and tuberculosis encompass more than two-thirds of the reported PAA cases.<sup>7-9</sup> Other less common causes include degenerative vascular abnormalities (i.e. atherosclerosis), pulmonary hypertension (PH), or post-stenotic dilatation from pulmonic valve stenosis.<sup>10,11</sup> Systemic vasculitides may involve the large pulmonary arteries leading to PAA,<sup>12</sup> but this is rarely an isolated finding without evidence of vasculitis elsewhere.

PA vasculitis with secondary aneurysmal dilatation is reported in patients with Takayasu's arteritis,<sup>13</sup> giant cell arteritis,<sup>14</sup> and Behçet's or its forme fruste Hughes-Stovin

syndrome.<sup>15,16</sup> Isolated pulmonary vasculitis has only been reported in a few case reports.<sup>17-19</sup> Hagan et al. described two patients with isolated large-vessel pulmonary vasculitis who displayed chronic obstruction of pulmonary arteries as opposed to aneurysmal dilatation, and underwent pulmonary endarterectomy in addition to pharmacological immunosuppression.<sup>17</sup> In two other reports, the patients presented with pulmonary arterial hypertension secondary to localized pulmonary vasculitis involving the medium-sized vessels.<sup>18,19</sup> Both patients failed immunosuppressive therapy and were offered bilateral lung transplantation. Unlike our patient, in most of the reported cases significant respiratory symptoms with elevated inflammatory markers were observed.

The diagnostic workup of PA vasculitis includes CT or magnetic resonance angiography of pulmonary arteries.<sup>20</sup> Right heart catheterization with pulmonary angiogram can further assist in diagnosis by capturing the pulmonary hemodynamics and excluding PH and left to right shunting. Histopathologic analysis in the form of tissue biopsy is usually required to confirm the diagnosis given the lack of other systemic vasculitis features.

Treatment of single organ vasculitis including isolated PA vasculitis is not well-studied. In two previous reports of isolated pulmonary Takayasu's arteritis, satisfactory outcomes were obtained after surgical repair without other therapeutic interventions.<sup>21,22</sup> In other cases, either high dose immunosuppression or surgical repair followed by immunosuppression was pursued.<sup>17-19,23</sup> In our patient, the decision to proceed with surgery was mainly due to the severity and rapid extension of the PAA. Despite limited evidence, current recommendations call for surgical intervention for pulmonary trunk aneurysms  $>5.5$  cm.<sup>2</sup> Others have recommended resection of PAAs  $>6$  cm or in symptomatic patients regardless of the PA size given the risk of dissection or rupture.<sup>10</sup> In this case, the patient was



systemically well with absence of inflammatory markers, and thus the vasculitis diagnosis was unanticipated before the resection. Since she remained asymptomatic postoperatively with no residual aneurysmal changes and no extra-pulmonary manifestations of vasculitis, conservative management with serial annual imaging was selected.

## Conclusion

We describe a rare case of PAA as a result of isolated large vessel pulmonary vasculitis that presented without any inflammatory signs or PH. This case also highlights one of the first cases of isolated PA vasculitis managed with surgical intervention alone. However, long-term follow-up is required in the event of disease relapse and need for immunosuppressive therapy.

## Conflict of interest

The author(s) declare that there is no conflict of interest.

## Funding

This research received no specific grant from any funding agency in the public, commercial, or not-for-profit sectors.

## References

1. Deterling RA and Clagett OT. Aneurysm of the pulmonary artery: Review of the literature and report of a case. *Am Heart J* 1947; 34: 471–499.
2. Kreibich M, Siepe M, Kroll J, et al. Aneurysms of the pulmonary artery. *Circulation* 2015; 131: 310–316.
3. Boyd LJ and McGavack TH. Aneurysm of the pulmonary artery: A review of the literature and report of two new cases. *Am Heart J* 1939; 18: 562–578.
4. Brown JR and Plotnick G. Pulmonary artery aneurysm as a cause for chest pain in a patient with Noonan's syndrome: a case report. *Cardiology* 2008; 110: 249–251.
5. Sakuma M, Demachi J, Suzuki J, et al. Proximal pulmonary artery aneurysms in patients with pulmonary artery hypertension: complicated cases. *Intern Med* 2007; 46: 1789–1793.
6. Senbakkavaci O, Kaneko Y, Bartunek A, et al. Rupture and dissection in pulmonary artery aneurysms: incidence, cause, and treatment—review and case report. *J Thorac Cardiovasc Surg* 2001; 121: 1006–1008.
7. Arom KV, Richardson JD, Grover FL, et al. Pulmonary artery aneurysm. *Am Surg* 1978; 44: 688–692.
8. Theodoropoulos P, Ziganshin BA, Tranquilli M, et al. Pulmonary artery aneurysms: four case reports and literature review. *Int J Angiol* 2013; 22: 143–148.
9. Grelland R. Aneurysm of pulmonary artery. *Acta Medica Scandinavica* 1950; 137: 374–380.
10. Deb SJ, Zehr KJ and Shields RC. Idiopathic pulmonary artery aneurysm. *Ann Thorac Surg* 2005; 80: 1500–1502.
11. Bhandari AK and Nanda NC. Pulmonary artery aneurysms: echocardiographic features in 5 patients. *Am J Cardiol* 1984; 53: 1438–1441.
12. Lally L and Spiera RF. Pulmonary vasculitis. *Rheum Dis Clin North Am* 2015; 41: 315–331.
13. Lupi E, Sánchez G, Horwitz S, et al. Pulmonary artery involvement in Takayasu's arteritis. *Chest* 1975; 67: 69–74.
14. Dennison AR, Watkins RM and Gunning AJ. Simultaneous aortic and pulmonary artery aneurysms due to giant cell arteritis. *Thorax* 1985; 40: 156–157.
15. Seyahi E, Melikoglu M, Akman C, et al. Pulmonary artery involvement and associated lung disease in Behçet disease: a series of 47 patients. *Medicine (Baltimore)* 2012; 91: 35–48.
16. Emad Y, Ragab Y, Shawki AE-H, et al. Hughes–Stovin syndrome: is it incomplete Behçet's? *Clin Rheumatol* 2007; 26: 1993–1996.
17. Hagan G, Gopalan D, Church C, et al. Isolated large vessel pulmonary vasculitis as a cause of chronic obstruction of the pulmonary arteries. *Pulm Circ* 2011; 1: 425–429.
18. Riancho-Zarrabeitia L, Zurbano F, Gómez-Román J, et al. Isolated pulmonary vasculitis: case report and literature review. *Semin Arthritis Rheum* 2015; 44: 514–517.
19. Xia H, Jiang Y, Cai Y, et al. Isolated pulmonary vasculitis. *Circulation* 2015; 132: e235–e238.
20. Marten K, Schnyder P, Schirg E, et al. Pattern-based differential diagnosis in pulmonary vasculitis using volumetric CT. *AJR Am J Roentgenol* 2005; 184: 720–733.
21. Lie JT. Pathology of isolated nonclassical and catastrophic manifestations of Takayasu arteritis. *Int J Cardiol* 1998; 66(Suppl 1): S11–21.
22. Yamazaki I, Ichikawa Y, Ishii M, et al. Surgical case of isolated pulmonary Takayasu's arteritis. *Circ J* 2005; 69: 500–502.
23. Kitajima T, Marumo S, Shoji T, et al. Large vessel vasculitis with an isolated lesion of a single-lobe pulmonary artery. *Intern Med* 2016; 55: 1801–1805.